

Article

Unruptured anterior communicating artery aneurysm with co-existing blister aneurysms: case report and review of literature

Karthikeyan Y.R., Rashim Kataria, Virendra Deo Sinha
INDIA



DE GRUYTER
OPEN

Unruptured anterior communicating artery aneurysm with co-existing blister aneurysms: case report and review of literature

Karthikeyan Y.R., Rashim Kataria, Virendra Deo Sinha

Department of Neurosurgery, SMS Medical College, Jaipur, INDIA

Abstract: Blister aneurysms are a separate class of vascular malformations with a unique etiopathogenesis and clinical profile, elusive to radiological imaging and complex to manage. Unless identified and managed appropriately they often lead increased morbidity intra and post operatively. They are commonly reported in internal carotid artery. We are reporting a rare case of intraoperatively diagnosed blister aneurysm of the anterior cerebral artery, the management options and the importance of constant vigilance in cases where the aneurysm appears unruptured intraoperatively.

Key words: anterior communicating artery, unruptured aneurysm, blister aneurysm, A1 segment

Introduction

Blister aneurysms (BA) are a relatively common entity seen in the supraclinoidal internal carotid artery (ICA). Their occurrence in the anterior cerebral artery (ACA) is very rare and limited to case reports. BAs are etiopathologically different from the berry aneurysms and pose a great challenge in diagnosis and management. We are reporting a very rare case of co-existent anterior communicating artery (A-comm) saccular aneurysm with blister aneurysms of the anterior communicating artery and adjacent A1 segment along with the review of literature and management options of this complex clinical entity.

Case summary

A forty five year old lady presented to us with a history of sudden severe headache and trivial ground level fall. On examination the patient was conscious but drowsy. Neurological examination was unremarkable. The initial computed tomography brain showed blood in the basal cisterns and associated intraventricular hemorrhage. Emergency CT angiography was performed. [Figure 1] It revealed a single saccular anterior communicating artery aneurysm with the dome pointing towards the left and slightly posteriorly. Vasospasm was seen in bilateral A2 segment of ACA and the neck was 4mm in width. The patient was planned for emergency

clipping of the aneurysm. Right pterional approach was planned. Intra operatively, a single A-comm aneurysm with the above mentioned configuration was identified. There were no signs of rupture of the saccular aneurysm such as tit, surrounding hematoma, irregular dome or surrounding adhesions. It appeared unlikely to be the source of bleed. The saccular aneurysm was clipped. On careful evaluation two small blister aneurysms were found, one in the right A1 segment near A-comm and the other on the A-comm. These were surrounded by a small hematoma in the vicinity. [Figure 2] We considered this to be the source of bleeding. A small muscle patch was harvested from the temporal muscle and placed over the blister aneurysm and was secured with a fenestrated clip encompassing the right A1 and proximal right A2. Post-operative CT angiography brain showed normal distal flow bilaterally. [Figure 3] The patient underwent a satisfactory recovery post operatively.

Discussion

Blister aneurysms (BA) are typically described as hemispheric aneurysmal bulge protruding from non-branching sites of the intracranial arteries. The term “blister” was introduced in 1988 by Takashi. (1)The most common reported site of BA is aneurysms arising from non-branching sites from the dorsomedial wall of the internal carotid artery (ICA). The relative frequencies of BAs are ICA 91.6%, A-comm 2.8%, middle cerebral artery 1.9%, posterior cerebral artery 1.6%, basilar artery 1.6% and anterior cerebral artery 0.3%. (2)

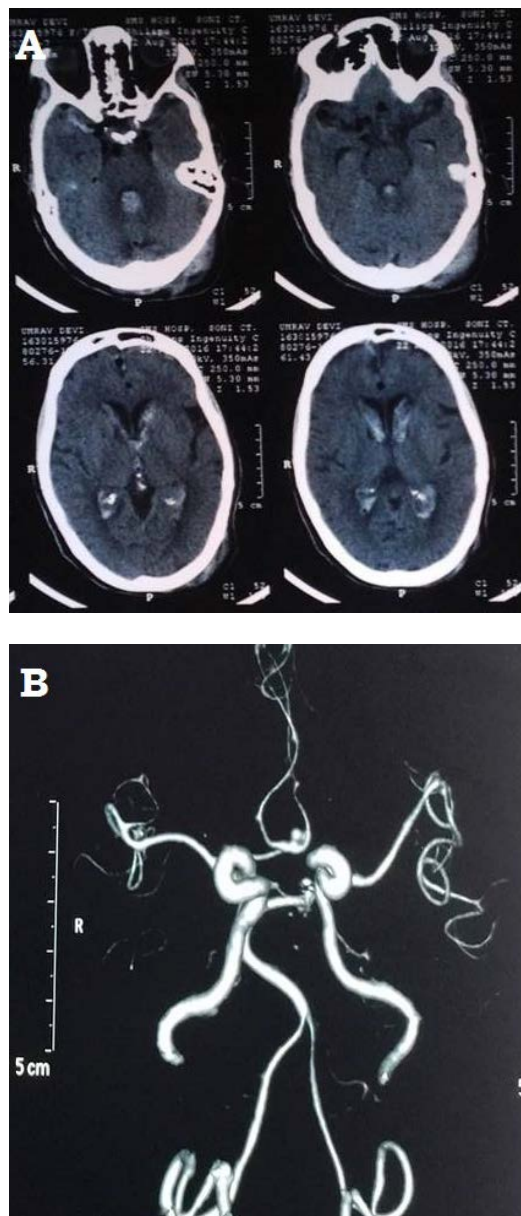


Figure 1 A - Computed tomography (CT) of brain showing intraventricular hemorrhage. **B** - Three dimensional CT angiography (right) showing superiorly projecting A comm aneurysm

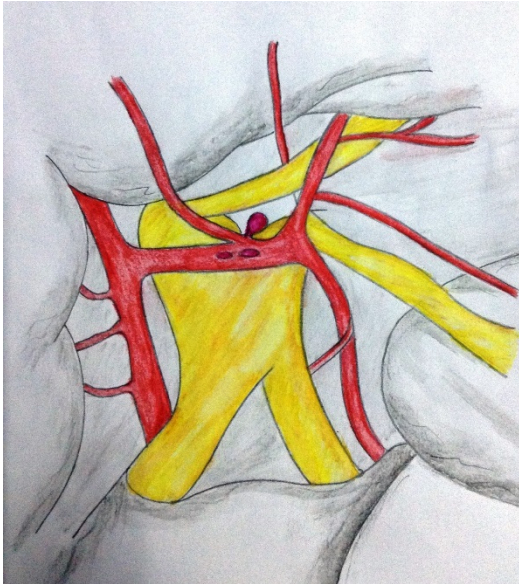


Figure 2 - Diagrammatic representation of intraoperative view of A-comm aneurysm on the dorsal aspect and the two blisters, one in the right A1 segment near A-comm and the other on the A-comm

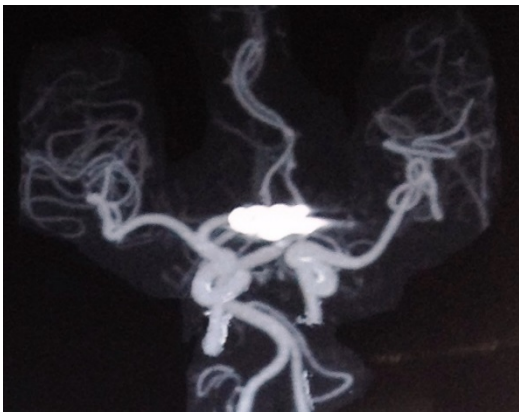


Figure 3 - Post-operative three dimensional CT angiography showing the clips in-situ and with distal flow in bilateral anterior cerebral artery

BAs exhibit rapid changes in size and morphology on angiograms. Other features characteristic of these aneurysms are preponderance of arterial hypertension,

atherosclerosis, ICA dissection, younger age and female sex.(3) Pathological studies have revealed focal wall defects covered by a thin layer of fibrous tissue and adventitia without any evidence of the usual collagenous layer.(3) The exact pathogenesis of these aneurysms are uncertain but the proposed mechanism is atherosclerotic weakening leading to wall changes, hemodynamic stress and possible dissection. These pathological features not only differentiate them from the routine saccular aneurysms but also explain their unpredictable behavior pre and intra operatively. This predisposes them to a high risk of premature rupture during surgery and associated development of large lacerations on the parent vessel with resultant poor outcome in many of these patients.

Because of their small size, fragile-thin wall and a broad-based neck these aneurysms are a real challenge to manage. Patients typically present with acute subarachnoid hemorrhage (SAH). The angiographic diagnosis of BA on conventional two dimensional digital subtraction angiography may be difficult because of their small size and irregular morphology. Repeat angiography often documents luminal changes or growth of these lesions. Their natural history remains unpredictable. BAs are often the cause of bleed in SAH of unknown etiology. Three dimensional digital subtraction angiography remains the gold standard investigation for diagnosis of these notorious lesions.

As these aneurysms are etiopathologically different from the saccular aneurysms their management is complicated and controversial. The standard clipping techniques are not

feasible in most cases and when possible they are risky and require expertise. Numerous therapeutic strategies have been used including direct clipping, clipping plus wrapping, wrapping alone, clipping with encircling graft clips, encircling silicone clip application, primary suturing of ICA, vascular staple clip closure of ICA and trapping with or without extracranial-intracranial bypass. (4) Over the past decade significant advances have been made in endovascular techniques (flow diverters, stents) which are gradually becoming the standard of care for the small but complicated aneurysms. Gonzales et al systematically reviewed 62 published series and they concluded that BAs are more aggressive than saccular aneurysms and have a higher incidence of complications irrespective of the technique used. (5) BAs are further complicated by regrowth and rebleeding after treatment. Though endovascular techniques have a low morbidity, postoperative antiplatelet therapy remains a major constraint.

One has to carefully look for BAs in every case where the saccular aneurysms do not show any signs of rupture during the surgery. We would also like to emphasize the importance of various surgical techniques mentioned above for intraoperatively identified BAs, which were not visualized in pre-operative imaging specially in facilities which lack the advanced endovascular techniques.

Constant vigilance for these lesions in all cases of saccular aneurysms, more so in the

absence of definite signs of rupture and their prompt management will lead to a better overall outcome. Though advanced endovascular techniques have become the procedures of choice, the importance of acquaintance with the open surgical techniques of management cannot be overemphasized. Hence the surgical techniques of management of these lesions are still relevant in current day practice.

Correspondence

Dr. Rashim Kataria
Associate Professor Neurosurgery
Department Of Neurosurgery
SMS Medical College, Jaipur
Mail: rashim_kat@yahoo.com
Contact: +91 9636261597

References

1. Chinchure SD, Gupta V, Goel G, Gupta A, Jha A. Subarachnoid hemorrhage with blister aneurysms: Endovascular management. *Neurol India* 62: 393-399, 2014.
2. Gonzalez AM, Narata AP, Yilmaz H, Bijlenga P, Radovanovic I, Schaller K, Lovblad KO, Pereira VM. Blood blister-like aneurysms: single center experience and systematic literature review. *Eur J Radiol* 83(1): 197-205, 2014.
3. Jha AN, Gupta V. Blister aneurysms. *Neurol India* 57(1): 2-3, 2009.
4. Peschillo S, Cannizzaro D, Caporlingua A, Missori P. A Systematic Review and Meta-Analysis of Treatment and Outcome of Blister-Like Aneurysms. *Am J Neuroradiol* 37(5): 856-861, 2016.
5. Sim SY, Shin YS, Cho KG, Kim SY, Kim SH, Ahn YH, Yoon SH, Cho KH. Blood blister-like aneurysms at nonbranching sites of the internal carotid artery. *J Neurosurg* 105: 400-405, 2006.