

Article

Efficacy of electromyography and nerve conduction velocity monitoring in surgical management of terminal lipoma in children

Ashraf El Badry, Mohamed Elsaeed, Ahmed Abdel Khalek, Azza Abdelazeez
EGYPT



DE GRUYTER
OPEN

DOI: 10.1515/romneu-2017-0030

Efficacy of electromyography and nerve conduction velocity monitoring in surgical management of terminal lipoma in children

**Ashraf El Badry¹, Mohamed Elsaheed², Ahmed Abdel Khalek³,
Azza Abdelazeez⁴**

¹Assistant professor of Neurosurgery Department

²Assistant professor of Neurology Department

³Professor of Radiology Department

⁴Assistant professor of Pathology Department

Faculty of Medicine, Mansoura University Hospital, EGYPT

Abstract: *Background:* the prognosis of Terminal lipomas is better than that of other sites and pathology especially their management nowadays became clearer with better surgical outcome due to advancement of surgical tools and neurophysiology study. *Objective:* to assess the outcome of excision of terminal lipomyelomeningocele and reconstruction of the neural tube. *Methods:* From 2002 to 2016, 32 cases of terminal lipomyelomeningocele in Mansoura university hospital, insurance hospital and El Ahrar specialized center, the age of the cases ranged between 10 days and 4,3 years underwent surgical management of total or near-total lipoma excision and neural tube reformation with minimum follow up of 6 months. *Results:* according to system which applied to show the success of the operations, Of the 32 patients, 9 cases represent (28.1%) showed total excision of the lipoma; 17 patients represent (53.1%) had 25 mm³ of lipoma or less and 6 patients represent (18.75%) had 26 mm³ of fat or more. The neurological and urological complications was about 25%, while other complications like cerebrospinal fluid leak, wound disruption and infection was 9.4%. The surgical morbidity was comparable with the published papers. *Conclusion:* the excision of terminal lipomyelomeningocele and recreation of the neural tube by monitoring throughout EMG & NCV with low surgical morbidity and better results than leaving them without management or surgical interference without neurophysiological monitoring.

Key words: terminal lipomyelomeningocele, lipoma, Reconstruction of neural placode. Abbreviations: DREZ, dorsal root entry zone; MRI, magnetic resonance imaging, CSF, cerebrospinal fluid.

Patients and methods

Patients

The prognosis Terminal (caudal in Chapman 3) lipomas had better than that of other types and locations of spinal lipomas, their surgical management established with no debate of its benefit (1, 4, 5, 15, 21). The principle of its management includes total/gross total excision of the lipoma; with separation of neural placode from the dura and reformation of neural tube.

From 2002 to 2016, 32 cases of terminal lipomyelomeningocele in Mansoura university hospital , insurance hospital and El Ahrar specialized center included in the study their age varied from 10 days to 4,3 years with a mean age of 3.5 months had total or gross total excision guided microscopically and with nerve stimulator, with minimum follow up of 6 months... There were 15 males and 17 females.

In the literature the lipomyelo – meningocele defined as a part of the distal conus and the fat protrudes outside through the dorsal bony defect, with sac filled by cerebrospinal fluid (CSF). (1, 15)

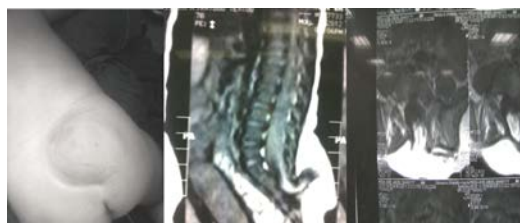

Figure 1 - Lipomyelomeningocele A, B MRI 1 tista sagittal and axial cuts T1 W show lipoma, cerebrospinal fluid surround part of the conus protrude out of the spinal canal through a dorsal defect

Surgical Technique

Embryological important notes

In the literatures in embryology of the spinal cord, McLone and his colleagues suggested that the gap present due to defect between the cutaneous and neural ectoderms during early separation, which lead to the paramedian mesenchyme to fill the space between neural folds and invade the central canal. (15, 17, 18)

As known the dorsal root ganglions generated from neural crest cells at the outer surface of the neural fold then its roots grow ventrolaterally but never traverse, the lipomatous stalk. (4, 8, 9)

Surgical principle

This technique guided by principles which described by Pang who was one of the leaders in management of spinal lipomas with its verities but modified according to facilities and learning curves (11, 12, 13), Longitudinal skin and soft-tissue incision then sharp dissection separating the subcutaneous lipoma from the skin and subcutaneous tissue till reaching the defect in the bony spinal canal and excision of the lipoma till the bony defect. The dissection begin one level above the rostral periphery of the lipoma, to move from normal anatomy to disturbed one which gives us better orientation of the last normal nerve root and DREZ before starting excision of lipoma. The lower extent not the same important like the upper one Then we made wide laminectomy to give full view till the lateral edges of the dura sac.

Then: excision of the Lipoma and separating it from the inner surface of the dura, opening the dura at upper end of the lipoma in the midline let us take better view and our dissection will be more skillful. The dural edges are retracted by sutures.

Next, the white fibrous band between lipoma and the tethered cord is identified. The DREZ and dorsal nerve roots are lateral to this line. Then dissection according to this line and more in the side of lipoma guided also by position of The DREZ and the neural placode.

We began excision of the lipoma at the proximal end where the normal anatomy present between lipoma, DREZ and nerve root then dissection along the white fibrous line. Cauterization usage is applied minimally to avoid injury to the DREZ and postoperative dysesthesia may appear.

After total resection of the lipoma and detaching of the placode from the inner dura we rule the placode on itself by suture to decrease adhesion between it and inner dura by making the contact surfaces smooth. The closure was by interrupted 6-0 nylon sutures without force.

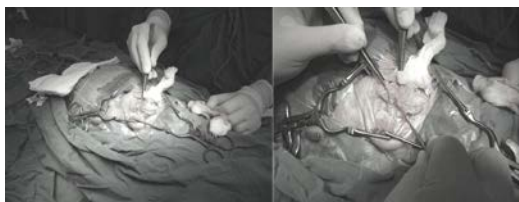

Figure 2 - A surgical exposure of lumbosacral lipoma, B lateral dissection of the lipoma

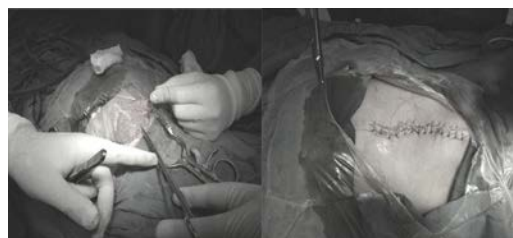


Figure 3 - Reconstruction of the placode and closure of the wound

Results

To achieve the success of the operations we must assess three elements: 1) the amount fat left 2) the state of reformation of neural tube and 3) presence of complications to these operations,

According to the amount of fat left: The amount fat left was assessed by postoperative magnetic resonance imaging (MRI) or C.T sagittal reformatting at 3 months. The results of the 32 patients was as follow, 9 cases represent (28.1%) showed complete removal of the lipoma with no residual; 17 patients represent (53.1%) showed 25 mm³ or less of fat left postoperatively, these cases showed multiple nerve fibers entangled with fat; and last 6 patients represent (18.75%) showed the amount of fat left was more than 26 mm³ of fat left due to the lipoma on the ventral surface or entangled with the neural placode.

The reformation of the neural tube and placode reconstruction is achieved the cord from the lipoma and inner dura with rolling it raw edges on itself to get smooth surface and the close the dura in water tight fashion.

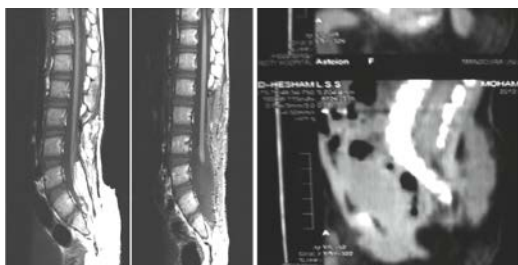

Figure 4 - Postoperative (A) sagittal MRI T1 W and postoperative (B) sagittal reformat CT of a lipomyelomeningocele revealing a blunt stump of the terminal conus after excision of the lipoma

TABLE 1

Show complications of total/gross total resection of lipomyelomeningocele

Complication	No. of cases	%
Loss of sensation	4	12.5
New weakness	3	9.4
voiding dysfunction	2	6.25
CSF leak	2	6.25
Pseudomeningocele	3	9.4
Wound infection	2	6.25
Overall complications	16	50.05

With obeying this principle the cord-sac ratio, represent free movement of the placode inside the created dural pouch which approved untethering of the cord on postoperative axial MRI or CT at the widest portion of neural tube reformation. So the 32 cases grouped in three categories: lower than (<30%) in the widest reformatted dural sacs, medium (between 30% and 60%) medium category, and high (>60%) in most tight sacs. 20 cases represent (62.5%) had ratio between cord and the sac less than

30%, 7 cases represent (21.9%) had ratios between 30% and 60%, and 5 cases represent (15.6%) had ratio more than 60%.

Complications

Table 1 showed nine cases represent (28.1%) experienced neurological complication from surgery. Only 3 patients (9.4%) developed motor weakness and 4 patients (12.5%) suffered sensory loss. 2 patients with had bladder dysfunction beside motor weakness. CSF leak or pseudomeningocele were seen in five cases, we reoperated in 3 cases of them. So overall surgical complication rate for our surgeries represent 50.5%.

Discussion

The study by Kulkarni from Necker-Enfants Malades, Paris In 2004, showed without any doubt that asymptomatic lipomas will be deteriorating by 43% in 10 years follow up 10-year (11).

The white plane which compact collagen fibers between the lipoma and neural placode is the crucial point in excision of terminal lipoma through it we can do dissection safe with aid of microscope and micro scissors.

Inspite of Arai and his colleagues (1) and Chapman (4), postulated that lipo - myelo meningocele carry poor prognosis, on the other hand we found it carry better prognosis if we dissect carefully and along the white line from the extra spinal lipoma extended to the intra spinal part guided by nerve stimulator to separate the lipoma form the cord.

One of the most important goals in this surgery is untethering of the cord from inner

dural surface with failure to accomplish this goal lead to recurrence of symptoms (4, 5, 14). Pierre-Kahn and his colleagues (14) and Xenos and his colleagues (5) were pioneers in surgically managing the lipomyelomeningocele reported failure of untethering the cord in 20% of their cases which lead to worse neurological condition of the cases as nerve roots entangled with fat but we overcome this obstacle by stressing on following the white line between fat and the cord and the nerve stimulation which let us know the good functioning roots from non-function one which we can cut it without worry about increase neurological deficit.

Reformation of the neural tube and reconstruction of the Neural Placode as done by McLone and his colleagues (15) we realized the presence of smooth surface of the placode by rolling its raw edges on itself making smooth surface between the cord and the inner dura made the untethering was accomplished and decrease the rate of recurrence.

In literature of Pierre-Kahn and his colleagues (4) showed only neurulation in 17% of the cases due to failure of total excision of the lipoma in most cases, and others (16) also had same results. In our partial resection group, we cannot made complete neurulation due to failure of getting raw edges of the neural placode on itself as consequence of incomplete excision of the lipoma. On the other hand, we were able reformation of neural placode and neural tube in 81.6% of our case due to complete or near complete lipoma excision. We found autologous fascia graft good alternative if needed, as Pierre-Kahn and his colleagues (15) did. The result also less

successive than described by Pang who spent more than 20 years in this subject (11, 13) may be due to less experience of using nerve stimulator and less experience with this surgical approach which built up from case to another.

In discussing the complications, most of papers in this subject showed partial excision as the safest policy to decrease the neurological complication which reported as 4% who had weakness; but most common was neuropathic pain by heat from electrical cautery near the DREZ and dorsal roots. We saw to decrease this complication by controlling the minor bleeding by oxidized cellulose or gel foam which worked as tamponade and lastly by low current electro cautery if needed in very limited situation.

CSF leaks (6.25%) and wound complications (6.25%) in our series was comparable with those in the published papers of the same issue which verified CSF leak range from 2% to 47% (4, 5, 6, 15, 16, 17, 18) and wound dehiscence and infection represented from 2% to 26% (5, 6, 7, 8, 15, 16), our strong point to decrease these complication was: good bony exposure cephalic and caudal so we could dissect from normal to abnormal anatomy with preservation of the dura to close the sac water tight then good anatomical closure with muscle flap if needed to strengthen the closure of the defect, fibrin glue was used in some cases but because it was not standardized in all cases we did not represent it as one of the main factors in decrease wound disruption and CSF leak.

Conclusion

The excision of terminal lipomyelomeningocele and recreation of the neural tube by monitoring throughout EMG & NCV with low surgical morbidity and better results than leaving them without management or surgical interference without neurophysiological monitoring.

Correspondence

Ashraf El Badry, M.D., IFAANS

Address: Department of neurological surgery

Mansoura university hospital, EGYPT

Email address: ashrafbadry@hotmail.com or

ashrafbadry@mans.edu.eg

Phone: +201111300033 or +201223477444

References

1. Arai H, Sato K, Wachi A: Surgical management in 81 patients with congenital intraspinal lipoma. *Child Nerv Syst*, 1992, 8:171.
2. Caldarelli M, McLone DG, Colins JA, Suwa J, Knepper PA: Vitamin A induced neural tube defects in a mouse. *Concepts Pediatr Neurosurg*, 1985, 6:161-171.
3. Chapman PH: Congenital intraspinal lipomas: Anatomic considerations and surgical treatment. *Childs Brain*, 1982, 9:37-47.
4. Chapman PH, Davis KR: Surgical treatment of spinal lipomas in childhood. *Pediatr Neurosurg*, 1993, 19:267-275.
5. Cochrane DD, Finley C, Kestle J, Steinbok P: The patterns of late deterioration in patients with transitional lipomyelomeningocele. *Eur J Pediatr Surg*, 2000, 10 [Suppl 1]:13-17.
6. Hoffman HJ, Taecholarn C, Hendrick EB, Humphreys RP: Management of lipomyelomeningoceles. Experience at the Hospital for Sick Children Toronto. *J Neurosurg*, 1985, 62:1-8.
7. James HE, Williams J, Brock W, Kaplan GW, U HS: Radical removal of lipomas of the conus and cauda equina with laser microneurosurgery. *Neurosurgery*, 1984, 15:340-343.
8. Kanev PM, Lemire RJ, Loeser JB, Berger MS: Management and long-term follow-up review of children with lipomyelomeningocele, 1952-1987. *J Neurosurg*, 1990, 73:48-52.
9. Koyanagi I, Iwasaki Y, Hida K, Abe H, Isu T, Akino M: Surgical treatment supposed natural history of the tethered cord with occult spinal dysraphism. *Child Nerv Syst*, 1997, 13:268-274.
10. Kulkarni HV, Pierre-Kahn A, Zerah M: Conservative management of asymptomatic spinal lipomas of the conus. *Neurosurgery*, 2004, 54:868-875
11. Pang D: Tethered cord syndrome: Newer concepts, in Wilkins RH, Rengachary SS (eds): *Neurosurgery Update II*. New York, McGraw-Hill, 1991, pp 336-344.
12. Pang D: Spinal cord lipomas, in Pang D (ed): *Disorders of the Pediatric Spine*. New York: Raven, 1995, pp 175-201.
13. Pang D: Spinal cord lipoma, in Batjer HH, Loftus C (eds): *Textbook of Neurological Surgery*. Baltimore, Lippincott Williams & Wilkins, 2002, pp 896-915.
14. Pierre-Kahn A, Lacombe J, Pichon J, Giudicelli Y, Renier D, Sainte-Rose C, Perrigot M, Hirsch J: Intraspinal lipomas with spina bifida: Prognosis and treatment in 73 cases. *J Neurosurg*, 1986, 65:756-761.
15. Pierre-Kahn A, Zerah M, Renier D, Cinalli G, Sainte-Rose C, Lellouch-Tubiana A, Brunelle F, Le Merrer M, Giudicelli Y, Pichon J, Kleinknecht B, Nataf F: Congenital lumbosacral lipomas. *Child Nerv Syst*, 1997, 13:298-335.
16. La Marca F, Grant JA, Tomita T, McLone DG: Spinal lipomas in children: Outcome of 270 procedures. *Pediatr Neurosurg*, 1997, 26:8-16.
17. McLone DG, Suwa J, Collins JA, Poznanski S, Knepper PA: Neurulation: Biochemical and morphological studies on primary and secondary neural tube defects. *Concepts Pediatr Neurosurg*, 1983, 4:15-2910.
18. McLone DG, Naidich TP: Spinal dysraphism: Experimental and clinical, in Holtzman RNN, Stein BM (eds): *The Tethered Spinal Cord*. New York, Thieme, 1915, pp 14-28.
19. McLone DG, Naidich TP: Laser resection of fifty spinal lipomas. *Neurosurgery*, 1986, 18:611-615.
20. Sutton LN: Lipomyelomeningocele. *Neurosurg Clin N Am*, 1995, 6:325-338.
21. Xenos C, Sgouros S, Walsh R, Hockley A: Spinal lipomas in children. *Pediatr Neurosurg*, 2000, 32:295-307.