

Article

Thoracic spine stab injury with pneumocephalus and pneumorrhachiasis: a unique case report and review of literature

Rakesh Kumar, Radhey Shyam Mittal, Ashok Gandhi
INDIA



DOI: 10.1515/romneu-2016-0085

Thoracic spine stab injury with pneumocephalus and pneumorrhachiasis: a unique case report and review of literature

Rakesh Kumar¹, Radhey Shyam Mittal², Ashok Gandhi³

¹Assistant professor, Department of Neurosurgery, King Georges Medical University, Lucknow, Uttar Pradesh, INDIA

²Professor and Head of Department, Department of Neurosurgery, Sawai Man Singh Medical Collage, Jaipur, Rajasthan, INDIA

³Associate professor, Department of Neurosurgery, Sawai Man Singh Medical Collage, Jaipur, Rajasthan, INDIA

Abstract: Trauma to skull base or sinus is the most common cause of pneumocephalus. There are only few published reports of traumatic pneumocephalus secondary to penetrating injury of upper spine, epidural anaesthesia and lumbar puncture. Till date only one case of pneumocephalus and pneumorrhachiasis after thoracic spine stab injury is reported in available English literature that too associated without any neurological deficit. To our knowledge, this is the first reported case of pneumocephalus and pneumorrhachiasis after thoracic spine stab injury with asymmetrical, incomplete spinal cord injury leading to neurological deficit in the patient. The management protocol of such injuries needs to be individualised for better outcome.

Key words: stab injury, thoracic spine, pneumocephalus, pneumorrhachiasis, spinal injury

Introduction

Stab injury is one of the most common varieties of civilian injuries. Pneumocephalus with pneumorrhachiasis and spinal cord injury after spine stab injury is a very rare entity. The subarachnoid space in the brain and spinal cord is continuous, thus air may ascend from the spine into the cranial subarachnoid space producing

pneumocephalus. Till date only one case of pneumocephalus and pneumorrhachiasis after thoracic spine stab injury is reported in available English literature that too associated without any neurological deficit. (1) The present paper reports a unique case of pneumocephalus and pneumorrhachiasis with spinal cord injury after thoracic spine stab injury associated with neurological deficit

along with review of literature. Patient was managed conservatively with good recovery.

Case report

A 25 year old gentleman was admitted to the department of neurosurgery with the history of assault. Patient had stab injuries over chest and back and developed weakness in lower limbs and retention of urine following this incident. There was no history of loss of consciousness, vomiting or ENT bleeding. On physical examination, his vitals were normal. On motor examination there was bilateral foot drop with right ankle and toes power grade zero. In left ankle and toe dorsiflexion was 0/5 and planter flexion was 3/5. Rest of the muscle groups power was 5/5. On sensory examination, there was approximate 50% loss of touch, temperature and pain sensation below L 3 dermatome in right and below L 4 dermatome in the left side. There was absent ankle jerks and planter was mute bilaterally. Superficial abdominal reflexes were present. There were sutured stab wounds over left anterior chest wall and back at D11 and D12 vertebra level. No CSF leak was noticed from the back wound. In Initial radiographs of chest and dorsolumbar spine no abnormality was detected. CT scan of chest and abdomen revealed bilateral minimal haemothorax. CT scan of dorsolumbar spine revealed mild anterior wedging of D 11 vertebra, fracture of left pars interarticularis and left pedicle of D12 vertebra without any displacement (figure 1a). On detailed observation of axial cuts of CT chest droplets of air were present intradurally

at D 12 level suggestive of pneumorrhachiasis (figure 1b). For further evaluation of spinal cord injury MRI of dorsolumbar spine was advised which revealed hyper intense area in spinal cord at upper border of D12 vertebrae and no cord compression. There was no air bubble seen in the MRI as contrast to the CT scan presentation which may be due to the resolution of air bubble by day 4 when MRI was taken (figure 2). Since patient complained of persistent headache and pneumorrhachiasis was also present, CT head was done which revealed pneumocephalus with presence of air in prepontine, perimesencephalic cisterns, left temporal and right frontal horn of lateral ventricle (figure 3a).

Patient was managed conservatively along with regular chest and limb physiotherapy. Broad spectrum antibiotics and anticonvulsants were also administered. Patient gradually improved and headache disappeared within 7 days. Repeat CT scan of head on 7th day showed resolved pneumocephalus (figure 3b). He was discharged from the hospital with assured follow-up. His motor weakness did not improve during the hospital stay although sensory dysfunction gradually improved and at the time of discharge he had decreased sensation below S1 dermatome.

Patient sensory deficit improved on four months follow-up. His bladder function and motor power in bilateral lower limbs improved significantly at fourteen months follow-up. The power in bilateral lower limbs at ankle and toes was grade 4/5. Patient was able to walk without support.

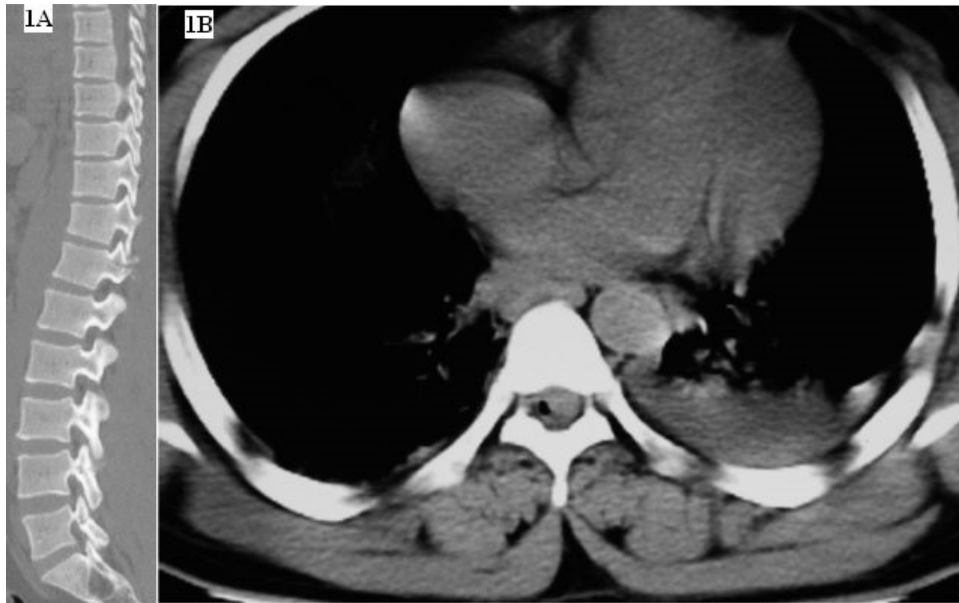

Figure 1 - Sagittal spinal CT image revealing undisplaced fracture of parsinterarticularis and pedicle of D12 vertebra (1a) and axial chest CT scan showing intradural droplet of air at D12 vertebra level (1b)

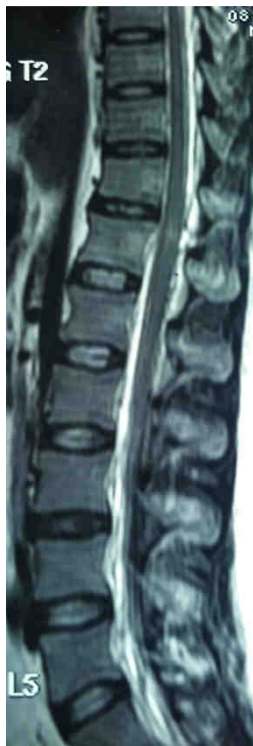

Figure 2 - MRI dorsolumbar spine showing hyper intense signal in spinal cord at upper border of D12 level without cord compression

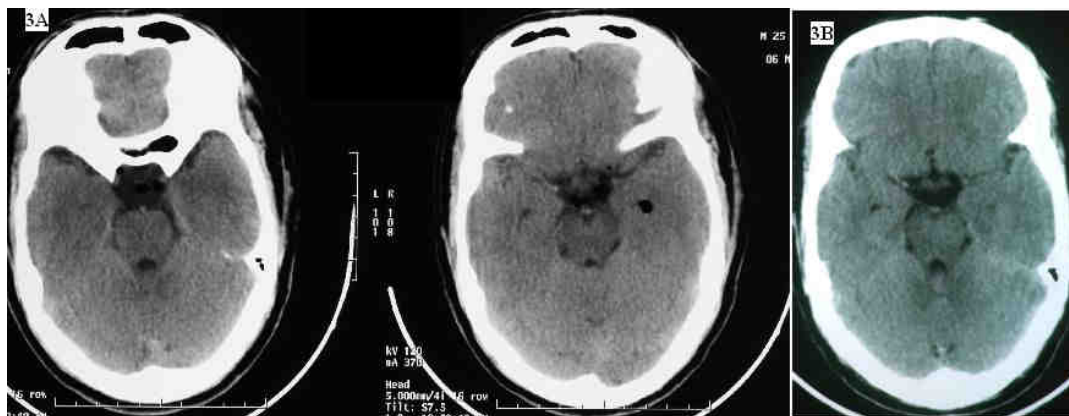


Figure 3 - Initial Axial plain CT head revealing pneumocephalus with presence of air in basal cistern and left temporal horn of lateral ventricle(3a) and repeat CT scan of head on 7th day showed resolved pneumocephalus(3b)

Discussion

Spinal cord injury following stab injury is a rare occurrence. Peacock et al (2) (1977) in his largest review of 450 cases of spinal stab injuries found knife as most common (84.2%) weapon used and thoracic segments (63.8%) are involved mostly. They found complete spinal cord injury in 20.9% of cases. Brown-Sequard type of hemisection was most common type (55.11%) in incomplete spinal cord injury. (3)

Lipschitz and Block (1962) (4) postulated three mechanism of spinal cord injury in stab injury. The spinal cord may be injured directly or indirectly by indriven bone fragments, by damaging the vascular supply to the spinal cord with resulting edema or by damaging the cord due to concussion or contusion resulting from counter coup spinal cord injury.

Traumatic pneumorrhachis is a rare finding. The subarachnoid space in the brain and spinal cord is continuous, thus air may

ascend from the spine into the cranial subarachnoid space producing pneumocephalus. (1) Pneumocephalus develops in about 78% of patients with traumatic pneumorrhachis. (1) Three case reports of pneumocephalus following penetrating injury of cervical spine, (3, 5, 6) and one case of pneumocephalus following penetrating injury to lumbar spine are reported in available English literature. (7) Till now, only one case of pneumocephalus and pneumorrhachiasis without neurological deficit after thoracic spine stab injury is reported. (1) To our knowledge, this is the first reported case of pneumocephalus and pneumorrhachiasis with spinal cord injury after thoracic spine stab injury associated with neurological deficit.

Entrance of air into the intracranial subarachnoid space is thought to be due to one of the following two mechanisms, first drop in intracranial pressure causing a vacuum effect which results in an influx of air with

respiration and coughing or secondly by a valve like effect at the wound site that allows air only to enter into subarachnoid space but not to exit. (3, 5) In the first reported case of a knife stab wound causing pneumocephalus, Naseem et al (1986) (6) also proposed that a drop in intracranial pressure from cerebrospinal fluid leak creates a vacuum that subsequently allows the influx of air into the subarachnoid space which causes pneumocephalus.

Pneumorrhachis is usually asymptomatic and is primarily a radiographic and not a clinical diagnosis. The presentation of pneumocephalus is often vague and nonspecific. The patient may complain of headache, nausea, vomiting, lethargy and altered state of consciousness and may show signs of meningism.

The diagnosis of pneumocephalus following spinal stab injury is often unsuspected and made only after a cranial CT scan. The initial management of spinal cord injury caused by stab wound consists of local wound debridement, primary closure of the wound and intravenous administration of antibiotics to prevent CNS infection. (8) Indications for operative intervention are retained foreign body, persistent CSF leakage, and sepsis. Stab wounds involving cauda equina roots require special attention and exploratory laminectomy is often indicated in such cases. Even after a delay of many years, operations on adherent and partially severed cauda equina roots may sometimes results in useful functional recovery. (9)

Complete spinal cord injury having poor prognosis, but in partial lesions, especially

with Brown-Sequard syndrome type of injuries good functional neurological recovery occurs usually. (2) In the largest reported series of 450 cases of stab injuries of spinal cord, 65.6% of cases has good recovery, in 17.1% cases recovery was fair and in 17.3% cases there was no significant recovery (2). No empiric guidelines for the treatment of pneumorrhachis and standards of care exist due to its rareness and the different etiopathogenesis. Therefore, the conditions causing pneumorrhachis has to be evaluated and the contributing causes have to be appropriately treated. Tension pneumorrhachis and pneumocephalus with nervous tissue compression may require intervention.

Treatment of pneumocephalus depends on the patient condition, the extent and progression of the air collection, and the etiology. Careful clinical monitoring and serial CT scanning of the brain following the procedure is recommended. Our patient had asymmetrical neurological involvement of the spinal cord without neural compression or cord laceration with small pneumocephalus that is why after thorough examination of the patient and evaluation of the CT and MRI scans, he was managed with conservative approach and had good recovery.

Conclusions

Stab injuries are one of the most common injuries which we come across in our day to day practice. Pneumocephalus and pneumorrhachiasis with spinal cord injury following stab injury in thoracic spine is a rare and very unusual presentation. Early and

accurate diagnosis based on clinical examination and radiology is essential for this rare injury. Because of the rareness of the case, management protocol of such injuries must be individualized for better outcome and better recovery of the patient.

Correspondence

Dr. Rakesh Kumar

*Mailing Address: 4kh 2, Shastri Nagar Jaipur,
Rajasthan, India 302016.*

Email Address – rksingh2226@gmail.com.

Phone Number – 91 –9984540111, 9667652170.

Fax number: 0141-2566484

References

1. Tejirian T., Gabikian P., Petrosyan M., Demetriades D. Pneumocephalus after penetrating thoracic trauma; case report and review of literature. *J. Trauma.* 2009;67:507-512.
2. Peacock WJ, Shrosbree RD, Key AG. A review of 450 stabwounds of the spinal cord. *S Afr Med J.* 1977;51(26): 961-964.
3. Bunc G, Roskar Z, Vorsic M. Pneumocephalus secondary to a neck stab wound without neurologic injury in a 13 year old girl. *Peadiatr Neurosurg.* 2001;34:239-241.
4. Lipschitz R, Block J. Stab wound of the spinal cord. *Lancet*, July. 1962;28:169.
5. Uppot RN, Vinay GK, Gould SW, Hirohiko I. Pneumocephalus and brown-sequard's neurologic injury caused by a stab wound to the neck. *AJR.* 1999;173:1504
6. Naseem M, Hood JD, Devasthali R. Traumatic pneumocephalus caused by stab wound to the neck. *AJNR* 1986;7:174—175.
7. Valente MA, Bender EA. Severe pneumocephalus after penetrating injury to the lumbar spine. *IJCRI* 2012;3(4):23-25.
8. Hwan ML, Nam HK, Chang II P. Spinal cord injury caused by a stab wound-A case report. *Yonsei Med J.* 1990;31(3): 280-284.
9. Landau B and Ransohoff J. *Journal of neurosurgery.* 1968;28:257.