

## Solitary plasmocytoma of the skull: case report and review of the literature

Luis Rafael Moscote-Salazar<sup>1</sup>, Hernando Raphael Alvis-Miranda<sup>2</sup>, Willem Guillermo Calderon-Miranda<sup>3</sup>, Zenen Antonio Carmona Meza<sup>4</sup>, Nidia Escobar Hernandez<sup>5</sup>, Marco Antonio Blancas-Rivera<sup>6</sup>, Amit Agrawal<sup>7</sup>

<sup>1</sup>Neurosurgeon, Universidad de Cartagena, Cartagena de Indias, COLOMBIA; <sup>2</sup>Resident of neurosurgery, Universidad de Cartagena, Cartagena de Indias, COLOMBIA; <sup>3</sup>Resident of radiology, Universidad Nacional Autonoma de Mexico, Hospital General Doctor Manuel Gea Gonzalez, MEXICO; <sup>4</sup>Chief Research, Universidad de Cartagena, Cartagena de Indias, COLOMBIA; <sup>5</sup>Chief of radiology, Hospital General Doctor Manuel Gea Gonzalez, MEXICO; <sup>6</sup>Physician, Universidad Nacional Autonoma de Mexico, MEXICO; <sup>7</sup>Professor of Neurosurgery, MM Institute of Medical Sciences & Research, Maharishi Markandeshwar University, Mullana-Ambala, Haryana, INDIA

**Abstract:** Solitary plasmacytoma and extramedullary plasmocytoma are tumors of malignant character composed of plasma cells, with a mean age of onset at 60 years. They can appear anywhere where the reticuloendothelial system is present. Usually these tumors lead to the development of multiple myeloma in a period of time ranging from 3 to 5 years. We present a rare case handled in our neurosurgery service associated with an unusually long period of evolution.

**Key words:** Solitary plasmacytoma, plasmocytoma, forehead mass

### Introduction

Multiple myeloma (MM) is defined as neoplastic proliferation of plasma cells that make monoclonal protein in most cases. The paraprotein can be found in serum or urine. These lesions extend to extramedullary areas where bone destruction occurs. One of the entities that may arise in the context of MM is plasmacytoma, correlating with a more aggressive course of the disease. Diagnosis is based on clinical symptoms, imaging findings, serum immunoglobulin electrophoresis, and

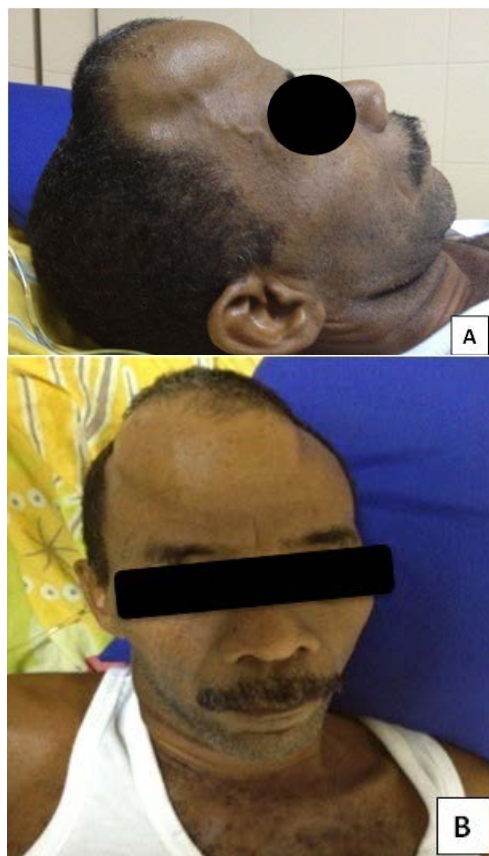lab studies demonstrating end organ damage (hypercalcemia, anemia, and renal insufficiency). Diagnosis is confirmed by histopathologic analysis following tissue biopsy or bone marrow aspirate. We present the case of a patient with a giant frontal lesion, which was consistent with a plasmacytoma associated with long period of evolution.

### Case report

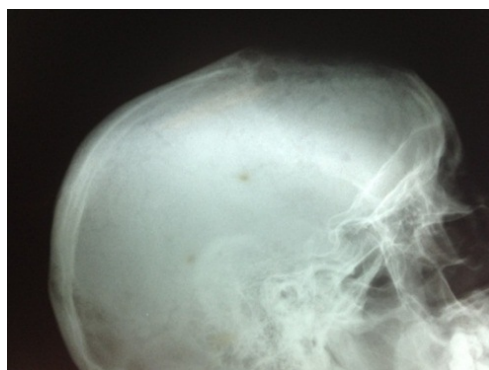Male patient, 47-yo, from rural area, with history of been working in palm oil production,

fishing and construction for several years. Is admitted to our institution referred from a first level care center, because of the presence of a large frontal lesion associated with head trauma 30 years ago, which was gradually increasing in size. The patient referred dyspnea on moderate exercise and fatigue. On examination, the patient was in regular conditional, afebrile, hydrated, hemodynamically compensated, normal vital signs, a lesion protrude in the medial frontal region, 15 x 15 cms (Figures 1A and B) soft at touch; no lymphadenopathy, cardiopulmonary, abdomen and extremities were normal. It was decided to perform skull radiography, head CT-scan (Figures 2, 3A, 3B).

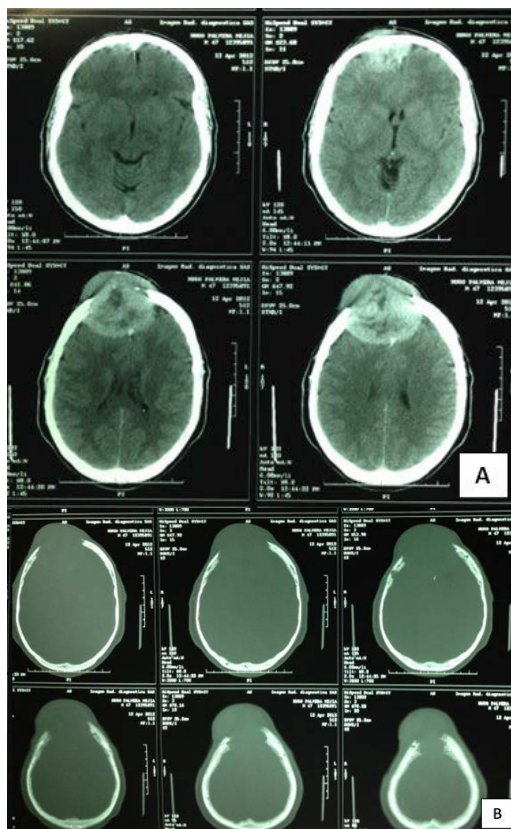
Images were evaluated, and we decided to perform frontal craniotomy with tumor resection. Patient developed mediate and immediate satisfactory postoperative course. During ICU stance the patient status declines, developing hyperazoemia. The pathology report was consistent with a lesion composed of plasma cells. The nephrology service establishes the diagnosis of renal failure; the patient progressed without improvement and died from respiratory complications.



**Figure 1** - Head deformation; A. Lateral view and B. Frontal view of the patient head, showing a large, oval frontal lesion



**Figure 2** - Lateral plain cranial radiography showing multiple bone lesions in the frontal area of the skull



**Figure 3** - Head CT-scan, A. axial slides showing a large, circular lesion located on the frontal pole, compromising frontal hemispheres bilaterally, but also the frontal bone, protruding through it, and bulking the scalp. B. Bone window, showing the large bone defect caused by the tumor

## Discussion

Plasmocytoma is a rare entity that arises from malignant proliferation of B-cell line (non-Hodking lymphoma). Malignant plasma cell tumors include: extramedullary plasmocytoma (EP); solitary plasmocytoma of the bone (SPB); multifocal form of multiple myeloma; MM; and plasmablastic sarcoma. Unlike MM, SPB is a localized disease of plasma cells in bone formation without

systemic complications. Intracranial plasmocytoma account for only 4% of all primary plasma cell tumors, with a conversion rate to MM occurring in approximately 50% of reported cases, (1) and in those patients with diagnosis of MM, intracranial EP as metastatic spread of MM occurs in 1% of reported cases. (2) SPB comprises 4% of all plasma cell malignancies, they are characterized by bone erosion, and EP arises in submucosal layer of tissues without bone involvement. Plasma cell neoplasms can histologically mimic a large variety of tumors (e.g., carcinomas, lymphomas, leukemia, plasma cell granulomas, sarcomas and histiocytic lesions). In fact, they are cytologically and immunophenotypically identical. The distinction between the various plasma cell neoplasms is based on clinical and radiological features. (3) Immunocytochemical study with antibodies to  $\kappa$  and  $\lambda$  light chains is a useful evaluation tool for a suspected plasmocytoma to distinguish it from a reactive proliferation. (3)

The diagnosis of SPB or EP is made by the presence of a single plasmocytoma in the bone or the soft tissue and the absence of clinical, histologic, and radiological evidence of multiple myeloma; (4) they have a mean age of presentation of about 10 years younger than those who develop MM. (4)

Most patients with plasma cell neoplasms present initially with vague symptoms, such as bone pain, anemia, or fatigue. The first rational approach for differential diagnosis of the SPB or EP is the exclusion of other plasma cell dyscrasias and, particularly dissemination of the disease into MM. This evaluation

requires complete blood count with white cell differential, erythrocyte sedimentation rate, serum calcium, phosphorous, blood urea nitrogen, creatinine, serum and urine protein electrophoresis, bone marrow biopsy, chest radiograph, and a radiographic skeletal survey. (5) Skeletal survey may detect lytic lesions, compression fractures (pathological), and osteopenia in areas with hemopoietically active bone marrow (vertebrae, ribs, femur, humerus, pelvis, sternum, and skull). (4–6) Bone marrow biopsy is required to detect malignant, plasmacytosis >10% is suggestive of MM.6 Regard the serum protein electrophoresis, it shows a sharp spike called the M component (M for monoclonal). When present, elevation of creatinine and uric acid is indicative of impaired renal function due to blockage of renal tubules by paraproteins and increased tumor load. The systemic search must persist for at least a year after the discovery of an intracranial plasmacytoma, especially if the mass is located in the skull base. (7)

### **Treatment**

Some difficulties limit the correct approach of treatment for these patients, especially for the small number of patients and the lack of controlled trials with statistically significant results, making that treatment of choice stills doubtful. Radiotherapy is the most accepted therapeutic strategy; other treatment choices are surgery, the combination of radiotherapy and surgery, and chemotherapy. (5) SPB and EP are optimally treated with complete surgical resection plus external radiation therapy. (7) Local control of solitary EP in the

head and neck seems to be improved when the dose to the clinical target volume is <45 Gy, a minimum dose of 45 Gy should be recommended. (8) Chemotherapy forms the mainstay of treatment of MM. The employment of chemotherapy (cyclophosphamide, vincristine, adriamycin, and dexamethasone) in combination with autologous peripheral blood stem cell transplant and interferons provides good quality of life, almost for 5 to 7 years. (9) For refractory or relapse cases while undergoing the above regimens, thalidomide and dexamethasone or high-dose dexamethasone is used.

Surgical treatment is limited to adjuvant therapy and bone complications. Currently there are supported minimally invasive procedures for prophylactic fixation of fractures, spinal cord decompression when indicated, and treatment of pathological fractures. (10) Gong et al., (11) reported the similar case of SPB in skull. CT scan revealed an 8 cm × 9 cm osteolytic lesion on the scalp of skull with a well demarcated margin. A cake-like mass was revealed at CT soft tissue window. The mass was completely excised.

The level of response to treatment, and in particular, the complete response, is associated with better long-term results. These patients should be followed every three months to assess the appearance of new signs or symptoms of disease; and note that survival solitary plasmacytoma is longer than multiple myeloma patients in the absence of diffuse abnormalities in the bone marrow, kidney lesions and calcium metabolism.

The main prognostic indicator for SPB and EP is the progression to MM, being the cranial base location the strongest predictor for that progression. (7) Tumoral recurrence varies between 10% and 22%. (12) Factors associated with high risk for local recurrence are the initial size of tumor (diameter >5 cm), age of patient (>60 years), the incompleteness of treatment, and an initial increase of serum proteins. (5)

## Conclusions

Plasmatic cell tumors are a rare disease, representing less than 1% of tumors of the head and neck. Usually they come from the brain parenchyma, or from dural or bone infiltration. Sometimes this type of injury is associated with MM. This last fact is the rationale for differential diagnosis of the SPB or EP is the exclusion of other plasma cell dyscrasias. Unlike MM, SPB and EP are localized disease of plasma cells without commitment systemic complications such as renal failure, hematological disorders, neurological and immunological. Pain and bone destruction with pathological fractures represent the most common clinical signs of this disease; therefore sometimes lab results are similar to MM as calcium disorders, renal dysfunction and increased beta-2 microglobulin; plasmacytoma therefore has a better prognosis than MM.

## Correspondence

Luis Rafael Moscote-Salazar, M.D.  
Neurological surgery, University of Cartagena  
E-mail: mineurocirujano@aol.com  
Cartagena de Indias, Colombia

## References

1. Cerase A, Tarantino A, Gozzetti A, Muccio CF, Gennari P, Monti L, et al. Intracranial involvement in plasmacytomas and multiple myeloma: a pictorial essay. *Neuroradiology* [Internet]. 2008 Aug [cited 2014 Sep 23];50(8):665–74. Available from: <http://www.ncbi.nlm.nih.gov/pubmed/18516599>
2. Fassas AB-T, Muwalla F, Berryman T, Benramdane R, Joseph L, Anaissie E, et al. Myeloma of the central nervous system: association with high-risk chromosomal abnormalities, plasmablastic morphology and extramedullary manifestations. *Br J Haematol* [Internet]. 2002 Apr [cited 2014 Sep 23];117(1):103–8. Available from: <http://www.ncbi.nlm.nih.gov/pubmed/11918539>
3. Singh AD, Chacko AG, Chacko G, Rajshekhar V. Plasma cell tumors of the skull. *Surg Neurol* [Internet]. 2005 Nov [cited 2014 Sep 23];64(5):434–8; discussion 438–9. Available from: <http://www.ncbi.nlm.nih.gov/pubmed/16253694>
4. Nofsinger YC, Mirza N, Rowan PT, Lanza D, Weinstein G. Head and neck manifestations of plasma cell neoplasms. *Laryngoscope* [Internet]. 1997 Jun [cited 2014 Sep 23];107(6):741–6. Available from: <http://www.ncbi.nlm.nih.gov/pubmed/9185729>
5. Abemayor E, Canalis RF, Greenberg P, Wortham DG, Rowland JP, Sun NC. Plasma cell tumors of the head and neck. *Am J Otolaryngol* [Internet]. 1988 Dec [cited 2014 Sep 23];17(7):376–81. Available from: <http://www.ncbi.nlm.nih.gov/pubmed/3230611>
6. Singh AD, Chacko AG, Chacko G, Rajshekhar V. Plasma cell tumors of the skull. *Surg Neurol* [Internet]. 2005 Nov 1 [cited 2014 Sep 23];64(5):434–8; discussion 438–9. Available from: <http://www.ncbi.nlm.nih.gov/pubmed/10>
7. Schwartz TH, Rhiew R, Isaacson SR, Orazi A, Bruce JN. Association between intracranial plasmacytoma and multiple myeloma: clinicopathological outcome study. *Neurosurgery* [Internet]. 2001 Nov [cited 2014 Sep 23];49(5):1039–44; discussion 1044–5. Available from: <http://www.ncbi.nlm.nih.gov/pubmed/11846895>
8. Tournier-Rangeard L, Lapeyre M, Graff-Caillaud P, Mege A, Dolivet G, Toussaint B, et al. Radiotherapy for solitary extramedullary plasmacytoma in the head-and-neck region: A dose greater than 45 Gy to the target volume improves the local control. *Int J Radiat Oncol Biol*

Phys [Internet]. 2006 Mar 15 [cited 2014 Sep 23];64(4):1013–7. Available from:

<http://www.ncbi.nlm.nih.gov/pubmed/16343803>

9. Segeren CM, Sonneveld P, van der Holt B, Baars JW, Biesma DH, Cornellissen JJ, et al. Vincristine, doxorubicin and dexamethasone (VAD) administered as rapid intravenous infusion for first-line treatment in untreated multiple myeloma. *Br J Haematol* [Internet]. 1999 Apr [cited 2014 Sep 23];105(1):127–30. Available from: <http://www.ncbi.nlm.nih.gov/pubmed/10233375>

10. Jagannath S, Kyle RA, Palumbo A, Siegel DS, Cunningham S, Berenson J. The current status and future of multiple myeloma in the clinic. *Clin Lymphoma*

*Myeloma Leuk* [Internet]. 2010 Feb [cited 2014 Sep 24];10(1):28–43. Available from:

<http://www.ncbi.nlm.nih.gov/pubmed/20223727>

11. Gong J-S, Kang W-Y, Zhu J, Xu J-M. A hole in the skull: CT manifestations of a solitary plasmacytoma in skull. *Quant Imaging Med Surg* [Internet]. 2012 Mar [cited 2014 Sep 23];2(1):61–2. Available from: <http://www.pubmedcentral.nih.gov/articlerender.fcgi?artid=3496502&tool=pmcentrez&rendertype=abstract>

12. Weber DM. Solitary bone and extramedullary plasmacytoma. *Hematol Am Soc Hematol Educ Progr* [Internet]. 2005 Jan [cited 2014 Sep 23];373–6. Available from: <http://www.ncbi.nlm.nih.gov/pubmed/16304406>