

Factors influencing the recurrence rate of operated chronic subdural hematomas

Toma Papacocea^{1,2}, Danil Adam^{1,2}, Raisa Croitoru², Ionut Rusu²,
Alexandru Papacocea³

¹“Carol Davila” University of Medicine and Pharmacy, Bucharest, Romania;

²Neurosurgical Department, Emergency “Saint Pantelimon” Hospital, Bucharest, Romania

³Neurosurgical Department, County General Hospital, Ploiesti, Romania

Abstract: In this study we are trying to establish a correlation between the surgical technique used for the treatment of chronic subdural hematomas and the risk of recurrence. Between 01.06.2008 and 31.05.2014, 123 patients with 138 chronic subdural hematomas (CSDH) were operated on and followed-up in our department. Among them, 16 hematomas (11,6%) recurred. Factors related to the patients (gender, age, location of the hematoma) are analyzed as possible predictors of recurrence. Several surgical techniques were used in the treatment of chronic subdural hematomas. Each of them is analyzed to find possibly connections with the recurrence risk of the size of the approach, the reposition of the bone flap, the suture of the dura and other aspects. There are obvious, statistically significant correlations between the risk of recurrence and some elements of the surgical technique employed.

Key words: chronic subdural hematoma, recurrence, surgical technique

Introduction

Chronic subdural hematomas (CSDH) represent a frequent encountered pathological condition in neurosurgery. Despite this fact, there still are, nowadays, controversies and unclear aspects concerning the best management of this particular type of intracranial hemorrhage (4,8).

Technically, a CSDH is located in the otherwise potential intradural space as a consequence of the disruption of the dural

border cell layer from the deep pachymeninges (11). Blood in this space provokes an inflammatory reaction, which results in an enveloping surrounding membrane (14)

Although some CSDHs evolve from acute subdural hematomas, most experimental models have failed to produce an enlarging CSDH from a solid clot. (13,18). Most of the time, there is no clear traumatic history that precedes the discovery of a CSDH. In the cases in which there is no trauma involved, other etiologies, such as coagulopathy, vascular

malformations, metastasis, meningiomas or inflammatory lesions must be considered (20).

Although spontaneous resolution of CSDH can occur, patients with a neurologic deficit should undergo surgical evacuation. The patients complaining of headache, but otherwise neurologically intact should be referred to a neurosurgical service, where they can be monitored with serial CT scans (15). The collection will often become smaller and disappear. Should there be an increase in the size of the CSDH and/or of the symptomatology, the patient should undergo surgical intervention (17).

The efficacy of the standard procedures for evacuation of a CSDH (twist drill, burr hole, craniotomy with or without irrigation and drainage of the subdural space) can be reflected by the recurrence rate of the CSDH after these procedures

Postoperative recurrence of CSDH still represents an important issue. Among published series, the recurrence rates usually vary between 3,7% and 21,5% (19). There are some factors that clearly influence recurrence, such as coagulopathy, brain atrophy, alcoholism, intracranial hypotension, bilateral surgery (5). The involvement of other factors is still debatable.

The aim of this study was to identify risk factors correlated with the recurrence of CSDH. We analyzed 2 categories of such presumptive risk factors: related to individual features of the patients (age, gender, bilaterality of lesions) and related to the operative technique.

Material and methods

This is a retrospective study conducted in the Neurosurgical Department of "Saint Pantelimon" Emergency Hospital from Bucharest, Romania encompassing patients operated on for CSDH between 01.06.2008 and 31.05.2014.

The inclusion criteria were:

Patients with uni- or bilateral CSDH with:

- at least 3 weeks of free interval after an identifiable trauma, if any
- CT- scan showing homogenous iso/hypodensity without signs of rebleeding or important layering by arachnoid septae
- intraoperative aspect of dark "motor oil" fluid

Cases with subacute SDH, or with fresh bleeding on the CT images, or CSDH complicated with thick septal or calcified membranes were excluded from this study, in an attempt to clear out recurrence risk factors related to the hematoma density and architecture.

According to the inclusion criteria listed above, there were 123 consecutive patients recruited in the study. Among them, 15 patients were operated on bilateral, so there were an overall of 138 CSDH operated on. There were 16 CSDH that recurred, giving an 11,6 % overall recurrence rate.

The gender distribution was 83 males versus 40 females, meaning a sex ratio of 2.1/ 1 M/W. Most of the patients (48) were more than 70 years old, 38 were between 60 and 69 years old and 37 were younger than 60.

Several surgical techniques were used for the operative treatment of the CSDH in our

department. We employed 4 main approaches with different technical variants of dural closure summarized below:

- A. burr-hole
- B. 2.5 cm large craniectomy
 - cross-shaped incision of the dura
 - bipolar coagulation used to shrink the dura to the full width of the bony opening
- C. 2.5 cm large craniotomy with trephine and re-employment of the bone flap
 - C1. without dural suture
 - C2. with partial dural suture
 - C3. with complete dural suture
- D. 4cm large craniotomy
 - D1. with partial dural suture
 - D2. with complete dural suture

Beside this technical differences between the variants exposed above, there were also some common steps always employed in the surgical treatment of CSDH in our department:

- the complete evacuation of the hematoma with abundant irrigation and aspiration
- coagulation of the outer membrane of the hematoma at the bony opening margins
- epidural non-aspirating drain for 36-72 hours postoperatively

The attitude concerning the inner membrane was not unitary: in 58 cases it was resected or coagulated and in 80 cases it was not touched.

Postoperatively, all patients were kept in bed-rest restriction with the head of the bed flat and mild overhydration until 24-48 hours after the drain was removed.

Results

We compared the recurrence rate between different categories of patients. Firstly, we analyzed the individual features of the patients in an attempt to observe any predisposition to recurrence related to gender or age. We found no significant differences, as one can see in figures 1 and 2, respectively.

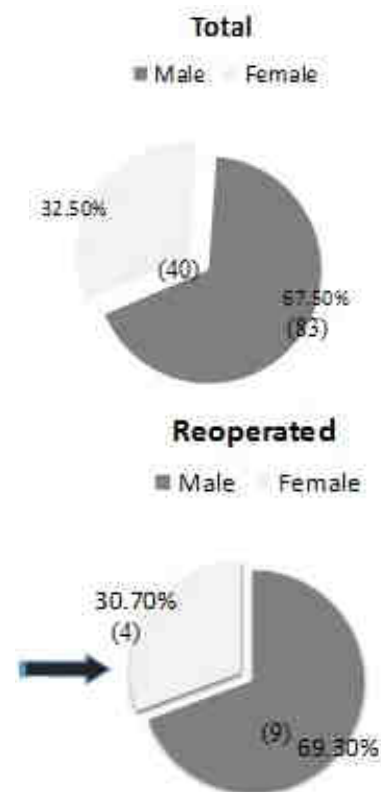


Figure 1 – Gender distribution

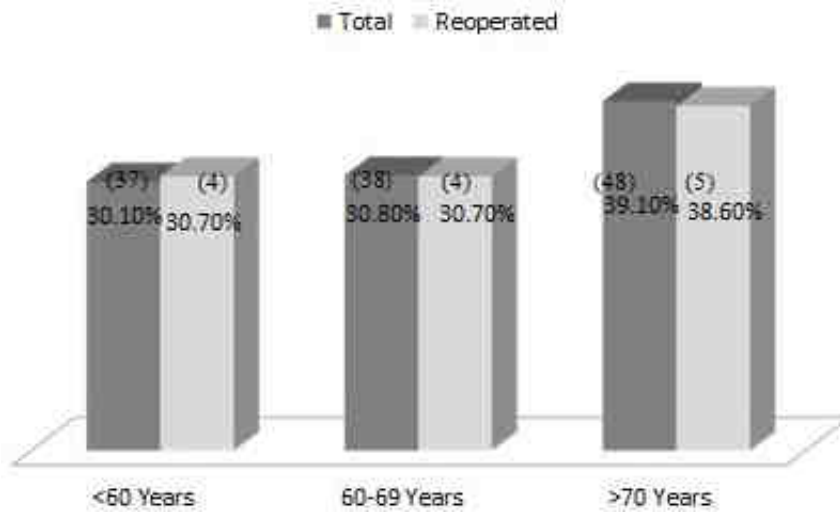


Figure 2 – Age distribution
 “St. Pantelimon” Emergency Hospital, Bucharest (Neurosurgical Department)

	Total	Recurrent SDH	Recurrence Rate
A	4	3	75%
B	16	1	6.25%
C.1	4	-	0%
C.2	6	-	0%
C.3	5	3	60%
D.1	5	2	3.7%
D.2	19	7	36.8%

Figure 3 – Results
 “St. Pantelimon” Emergency Hospital, Bucharest (Neurosurgical Department)

We also analyzed bilaterality of CSDH as a possible risk factor for recurrence and we found that, among the 15 cases of bilateral hematomas operated, 3 patients needed reoperation on both sides, giving a 20% recurrence rate, significant more than the average recurrence of the whole group (11,6%)

Afterwards, we compared the recurrence rates of each surgical variant presented above in the text. The results are exposed in figure 3.

It is obvious that there is a very high recurrence rate for variants A and C3, and also a high recurrence rate (RR) for variant D2. We can also observe that there is a low, under average recurrence rate for variants B and D1,

and an outstanding 0% RR for variants C1 and C2.

The controversial topic of touching or avoiding the inner membrane is illustrated in the table in figure 4 which shows that RR in cases when the inner membrane is resected or coagulated is much higher (17,2%) than in cases where this membrane is left alone (7,5%).

Resection/coagulation of the inner membrane	Yes	No
Total	58	80
Reccurent SDH	10	6
RR	17.2%	7.5%

Figure 4 – Inner membrane
“St. Pantelimon” Emergency Hospital, Bucharest
(Neurosurgical Department)

Discussions

A symptomatic recurrence means the reappearance of neurologic signs and symptoms together with a volume increase of the CSDH with mass effect on CT-scan within weeks to months after surgery (2). This situation must be distinguished from residual collections that are asymptomatic, do not demonstrate pressure effects on CT and can be followed with serial studies until their complete or nearly complete resolution without surgical intervention (3). A clinical improvement in the status of the operated patients can be obtained when the subdural pressure is reduced to close to zero, which usually occurs after 20% of the collection is removed (7). CT scans can show persistent fluid collection in 78% of cases on post-op day 10 and in 15% after 40 days (1), and it may take up to 6 months for complete resolution (5). It

is, therefore, recommended not to treat a persistent fluid collection unless it increases in size on CT or if the patient shows no recovery or deteriorates (6).

An ongoing debate concerns optimal surgical management of a CSDH. In this topic the meta-analysis by Weigel and colleagues is of great interest. This study is based on a review of 48 publications and covers a period of time between 1981 and 2001. The authors of this meta-analysis conclude that craniotomy is associated with the lowest recurrence rate but a higher morbidity rate compared to more limited approaches (twist drill and burr hole) (12,19).

In the patients included in this study we didn't use subdural drainage; data in the literature suggests that this maneuver can decrease the RR from 19% to 10% (9).

Conclusions

1. Individual factors like gender and age don't influence the RR.
2. Bilateral CSDH are more prone to recur than unilateral ones.
3. The single burr-hole technique without subdural aspirating drainage is associated with a high recurrence rate and should be avoided
4. The best technique for decreasing the risk of recurrence seems to be the 2.5 cm. craniotomy without any or only with partial suture of the dura.
5. The complete suture of the dura increases the risk of recurrence especially in smaller approaches and should be avoided.
6. A larger than 2.5 cm approach for uncomplicated CSDH brings no improvement of the RR.

7. There are no significant differences related to the RR between 2.5 cm craniectomy and craniotomy, but the cosmetic aspect should be taken into account.

8. The inner membrane of the CSDH shouldn't be touched during the operation in order to avoid a higher RR.

Correspondence

Toma Papacocea

"Carol Davila" University of Medicine and Pharmacy, Bucharest, Romania

E-mail: tpapacocea@hotmail.com

References

1. Adeolu AA, Rabiou TB, Adeleye AO: Post-operative day two versus day seven mobilization after burr-hole drainage of subacute and chronic subdural haematoma in Nigerians. *Br J Neurosurg* 26:743-746, 2012.
2. Berghauer Pont LM, Dippel DW, Verweij BH, Dirven CM, Dammers R: Ambivalence among neurologists and neurosurgeons on the treatment of chronic subdural hematoma: a national survey. *Acta Neurol Belg* 113:55-59, 2013.
3. Berghauer Pont LM, Dirven CM, Dippel DW, Verweij BH, Dammers R: The role of corticosteroids in the management of chronic subdural hematoma: a systematic review. *Eur J Neurol* 19:1397-1403, 2012.
4. Bozkurt G, Ahyan S, Akbay A, Palaoglu S. Treatment of chronic subdural hematoma by twist drill craniostomy with irrigation. *Turkish Neurosurgery* 2006; 16:19-24.
5. Cenic A, Bhandari M, Reddy K: Management of chronic subdural hematoma: a national survey and literature review. *Can J Neurol Sci* 32:501-506, 2005.
6. Chari A, Clemente Morgado T, Rigamonti D: Recommencement of anticoagulation in chronic subdural haematoma: a systematic review and meta-analysis. *Br J Neurosurg* 28:2-7, 2014.
7. Delgado PD, Cogolludo FJ, Mateo O, Cancela P, Garcia R, Carrillo R: Early prognosis in chronic subdural hematomas. Multivariate analysis of 137 cases *Rev Neurol* 30:811-817, 2000.
8. Ducruet AF, Grobelny BT, Zacharia BE, Hickman ZL, DeRosa PL, Anderson K, Sussman E, Carpenter A, Connolly ES, Jr.: The surgical management of chronic subdural hematoma. *Neurosurg Rev* 35:155-169, 2012.
9. Erol FS, Topsakal C, Faik Ozveren M, Kaplan M, Tiftikci MT: Irrigation vs. closed drainage in the treatment of chronic subdural hematoma. *J Clin Neurosci* 12:261-263, 2005.
10. Etminan N, Vergouwen MD, Ilodigwe D, Macdonald RL: Effect of pharmaceutical treatment on vasospasm, delayed cerebral ischemia, and clinical outcome in patients
11. Haines D, Harkey H, al-Mefty O: The subdural space: A new look at an outdated concept. *Neurosurgery* 32: 11-20, 1993
12. Ibrahim I, Maarrawi J, Jouanneau E, Guenot M, Mertens P, Sindou M. Evacuation of chronic subdural hematomas with the twist-drill technique: Results of a randomized prospective study comparing 48-h and 96-h drainage duration. *Neurochirurgie* 2010; 56:23-7.
13. Ito H, Yamamoto S, Komai T, Mizukoshi H. Role of local hyperfibrinolysis in the etiology of chronic subdural hematoma. *J Neurosurg* 1976; 45:26-31.
14. Jones S, Kafetz K. A prospective study of chronic subdural haematomas in elderly patients. *Age and Ageing* 1999; 28:519-21.
15. Lin X. Comparing twist-drill drainage with burr hole drainage for chronic subdural hematoma. *Chin J Traumatol* 2011; 14(3):170-173
16. Nakajima H, Yasul T, Nishikawa M, Kishi H, Kan M. The role of postoperative patient posture in the recurrence of chronic subdural hematoma: a prospective randomized trial. *Surg Neurol* 2002; 58:385-7.
17. Pruna V, Bucur N, Neacsu A, Andrei G, Sandu A, Gorgan M. Calcified chronic subdural hematoma - Case report *Romanian Neurosurgery Vol XV nr 2 pag 22-25*
18. Watanabe S, Shimada H, Ishii S: Production of clinical form of chronic subdural hematoma in experimental animals. *J Neurosurg* 37: 552-561, 1972
19. Weigel R, Schmiedek P, Krauss J: Outcome of contemporary surgery for chronic subdural hematoma: Evidence based review. *J Neurol Neurosurg Psychiatry* 74:937-943, 2003
20. Wilberger J. Pathophysiology of evolution and recurrence of chronic subdural hematoma. *Neurosurg Clin N Am* 2000; 11:435-438.