

## Tea Cup in the brain, a rare case of penetrating brain injury in pediatric patient

Arvind Sharma, S.K. Jain, Sanjeev Chopra

Department of Neurosurgery, S.M.S Medical College, Jaipur, Rajasthan, India

**Abstract:** Head injuries are very common in children. All over the world, the most common mechanism is fall. These injuries are more prevalent in developing countries due to lack of education, poverty, lack of standard and scientific ways to child upbringing. Penetrating injuries in pediatric patients is extremely uncommon and usually occur due to sharp objects like knife, screw driver, drills, nails. We are reporting a rare case of a child with penetrating head injury due to tea cup, very commonly used crockery in every house hold. To the best of our knowledge, no similar case has ever been reported in world literature. Our case also emphasized the need for educating people about child care.

**Key words:** penetrating, crockery, tea-cup

### Introduction

Head injuries due to fall from height are not uncommon in pediatric patients in developing countries. A variety of foreign bodies penetrating the cranium has described in literature like wooden stick, drill bits, electric socket, low and high velocity pallets, stone. But we are describing a very rare case of penetrating injury to cranium due to a tea-cup, a very common crockery item used in day today life.

### Case report

A four year old female child presented to us with history of fall from 10 feet of height in his house while playing. There was no history of

loss of consciousness, vomiting and seizures. His vitals was within normal range with pulse was 90 per minute and blood pressure was 100/70 millimeter of mercury. He was maintaining oxygen saturation at room air. His pupil was bilateral equal, round and regular and reacting to light. Child was conscious, actively playing and having left side hemiparesis with motor power 4/5. Child was able to identify his mother. On examination of scalp there was multiple lacerated wound over right parietal region with visible depressed bone fragment and penetrating foreign body. Non-contrast enhanced CT Scan of brain (Figure 1) done and showed right parietal depressed fracture with penetrating foreign body with under laying contusion of brain.

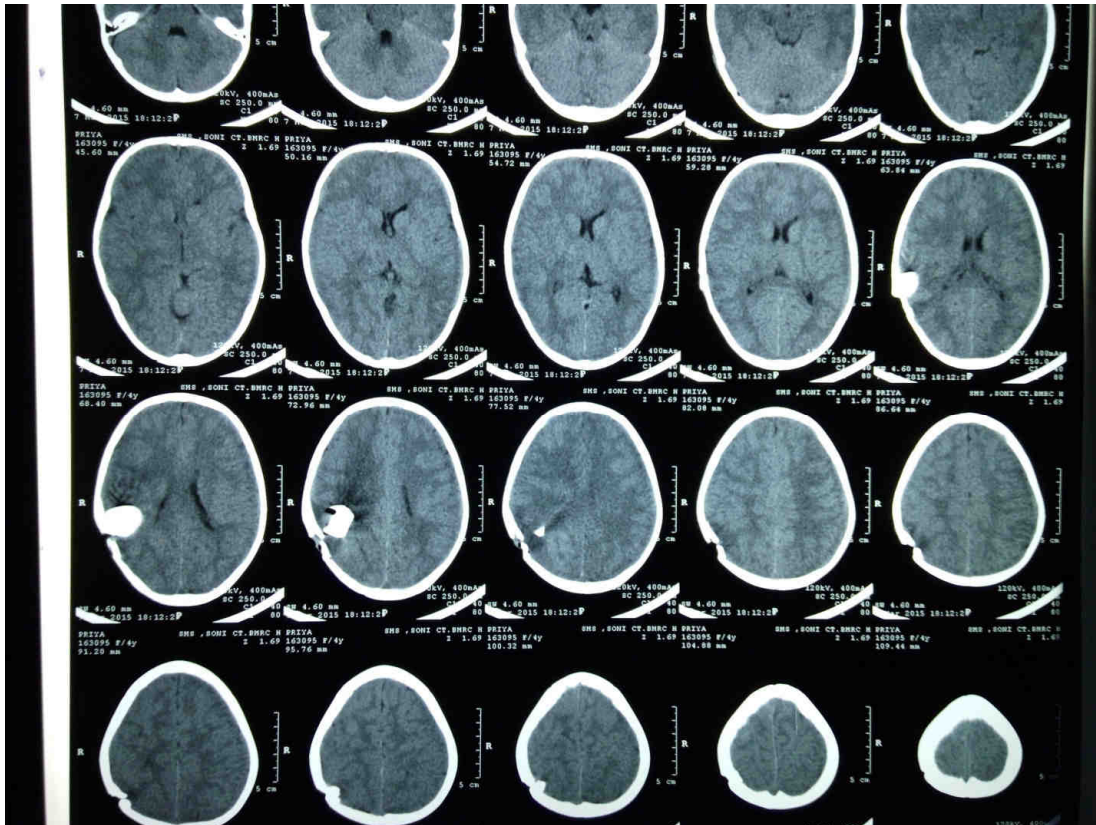


Figure 1 - NCCT Brain showing penetrating foreign body with under-laying contusion

No systemic injuries were noted. Patient was investigated and blood samples were drawn. Surgery was performed promptly with craniectomy done all around the penetrating object followed by removal of foreign body (Figure 2) without any side to side movement.

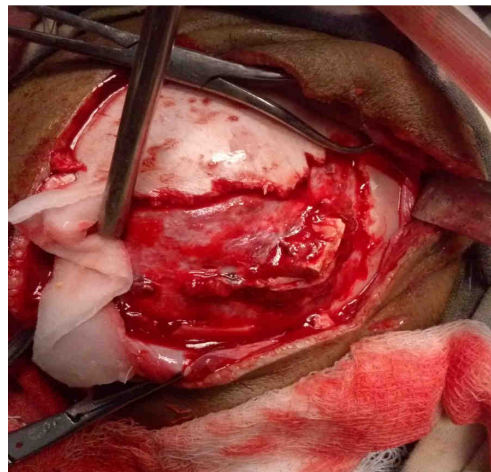


Figure 2 - showing penetrated piece of tea-cup in brain

All devitalized tissue and depressed bone segment taken out. There was a piece of tea-cup (a type of crockery used in kitchen to serve tea) that was taken out. There was a dural tear with underlying brain contusion, but no active bleeding from brain parenchyma. Wound toileting done and dural tear repaired using pericranial patch. Postoperatively patient did well with no neurologic deficit. Postoperative Non contrast enhanced CT scan of brain showed no residual foreign body or bone fragment. There was no hematoma but only residual contusion. Post operatively patient's left side weakness improved.

### **Discussion**

Head trauma is exceedingly common in children and the most common mode of injury is fall from height results in coup and countercoup injuries but penetrating injuries in pediatric patients are rare(2). Most of penetrating injuries caused by sharpnells and bullets. The most common is due to knife injury, although several cranio-cerebral perforating injuries have been reported, like those caused by nails, keys, pencils, pen metal poles, ice picks, chopsticks, and power drills(3,4,5,7,8,9). These penetrating foreign bodies may breach the dura and can cause damage to brain parenchyma and major vessels within hence these injuries may be fatal. Local bone thickness and angle of impact of penetrating object determines the severity of injury (1). Neurologic deficit might occurred if eloquent areas of brain are involved. In cases of non-eloquent part of brain involved without any major vascular injury, prognosis is relatively good. These

patients should be evaluated with x ray skull that can showed penetrating foreign body with bone defect in cranium. Non-contrast enhanced CT Scan of brain is investigation of choice and that may showed depressed bone fragment with underlying brain injury. CT angiography of brain should be performed whenever there is high suspicion of any major vascular injury. MRI of brain may be hazardous as penetrating object may be ferromagnetic and can cause additional damage to brain. Preoperative assessment should be done and any other systemic injuries should be rule out. There is high risk of infection and seizures hence surgical intervention should be done as early as possible. The aim of surgical management is prompt action with removal of any extradural or subdural hematoma, removal of foreign body and involved bone, evacuation of brain contusion or any devitalized tissue and proper dural closure to prevent brain fungus and CSF leak (6, 10). Postoperatively these patients should be treated with intravenous antibiotics and short course of antiepileptics & closely watch for sign and symptoms of intracranial infection. Contrast enhanced CT scan should be performed to rule out brain abscess whenever there is suspicion.

### **Conclusion**

Pediatric head injuries are very common in developing countries and most common mode of injury is fall. Penetrating head injury in children is very uncommon and mostly occurs due to shrapnel. These patients should be promptly evaluated and treatment should be given as early as possible. Our case is very

special as no case has been reported in world literature in which cause of injury was due to a tea-cup. Our case also emphasize the need to educate people in developing world about child care so that these type of injuries can be prevent.

### References

1. Aarabi B. History of the management of craniocerebral wounds. In: Aarabi B, Kaufman HH, Dagi TF, George ED, Levy ML, editors. *Missile Wounds of the Head and Neck*. Vol. 1. Park Ridge, Ill: American Association of Neurological Surgeons; 1999. pp. 281–92.
2. Atabaki SM. Pediatric head injury. *Pediatr Rev*. 2007;28:215–24.
3. Bakay L, Glausier FE, Grand W. Unusual intracranial foreign bodies: Report of five cases. *Acta Neurochir (Wien)* 1977;39:219–31.
4. Herring CJ, Lumsden AB, Tindall C. Transcranial stab wounds: A report of three cases and suggestions for management. *Neurosurgery*. 1988;23:658–62.
5. Jennifer K, Reza K. Penetrating head injury in children: A case report and review of the literature. *J Emerg Med*. 2001;21:145–50.
6. Kaufman HH, Schwab K, Salazar AM. A national survey of neurosurgical care for penetrating head injury. *Surg Neurol*. 1991;36:370–7.
7. Nakayama Y, Tanaka A, Arita T, Kumate S, Yoshinga S. Penetrating head injury caused by weed: Case report. *Brain and Nerve*. 1995;47:1192–94.
8. Pascual JM, Navas M, Carrasco R. Penetrating ballistic-like frontal brain injury caused by a metallic rod. *Acta Neurochirurgica*. 2009;151:689–91.
9. Salar G, Costella GB, Mottaran R, Mattana M, Gazzola L, Munari M. Multiple craniocerebral injuries from penetrating nails. *J Neurosurg*. 2004;100:963.
10. Trask TW, Narayan RK. Civilian Penetrating Head Injury. In: Narayan R, Wilberger J, Povlishock J 2nd, editors. *Neurotrauma*. New York, NY: McGraw Hill; 1996. pp. 868–89.