

Asymptomatic posterior cervical myelomeningocele with tethered cord in an adolescent: a rare form of spinal dysraphism with rare presentation

Gangesh Gunjan, Sumit Sharma, S.K. Jain, S. Chopra

Department of Neurosurgery, SMS Medical College & Hospital, Jaipur, Rajasthan, India

Abstract: Unlike lumbar spinal dysraphism, cervical spinal dysraphism with or without tethered cord are rare lesions. These lesions are generally asymptomatic at birth, but with progression of time symptoms develop. These may be associated with various other anomalies. Not much have been reported in literature about cervical myelomeningocele (MMC) in adults or adolescents. We report a case of a 17 years old adolescent boy with cervical myelomeningocele with tethered cervical cord, who was completely intact neurologically even at this age and was without any associated anomaly. He came to us only for cosmetic reasons. The tethering band, which was evident on imaging was confirmed intra-operatively.

Key words: cervical myelomeningocele, spinal dysraphism, tethered cord.

Introduction

Cervical meningocele and myelomeningocele are rare lesions accounting for 1-8% of all neural tube defects. Diagnosis of these lesions are obvious at birth: a mass protrudes from the posterior midline of the neck. Children with cervical MMC with tethered cord can be asymptomatic and thus the subtle features of cervical cord tethering or any other associated anomaly may be overlooked on imaging. If left untreated, the tethered cervical cord may cause gradual neurological deterioration with progression of time, with motor function in the upper extremities being primarily affected. In our

case the patient an adolescent, came only for cosmetic reasons and was neurologically intact; had we not done thorough pre-op evaluation and tried to remove the protruding posterior cervical midline mass, we would have landed the patient in trouble. In order to avoid any future neurological deficit, any cervical region mass mandates a thorough clinical and radiographic pre-op evaluation regardless of patient's age.

Case report

A 17 years old adolescent boy with rural background was admitted to our department with a mass lesion in the posterior cervical

region. It has been present there since his birth. He was asymptomatic and got admitted only for cosmetic reasons. Physical examination revealed normal findings except a partially spherical swelling over the nape of his neck in mid cervical region, 2.5 x 3.5cm x 2 cm in dimensions with an elevated nodule of 1x0.5cm. It was covered with full thickness skin and was compressible, non fluctuant, non tender and without any CSF leak. Neurological, orthopedic and urological evaluations were normal. MR imaging (Figure 1 & Figure 2) of the cervical spine was performed and high resolution T1, T2W serial sections obtained in the sagittal and axial planes. It showed spina bifida at C4 vertebral level and a heterogenous lesion in subcutaneous tissue at this level communicating with the spinal canal with evidence of focal bulge in posterior surface of cord at this level. A low-signal connection between the posterior bulge of the cord and the dorsal dural sac, which could represent the tethering stalk, was identified. CT scan of brain (Figure 3) was within normal limits. Excision of sac and C3 & C4 laminectomy with intradural exploration and detethering of cord was performed under general anesthesia. Whitish, fibrous tissues connecting the dorsal cervical cord to the sac of the myelomeningocele were present. These fibrous tissues were taut, further confirming the suspicion of tethered cord. The fibrous tissues on the dorsal cord were attached at the rostral end of the sac. All were subsequently excised and the spinal cord detethered. Histopathological examination revealed epidermis on the external aspect, which in

most part was thin and attenuated. The underlying tissue comprised of fibrocollagenous tissue with focal collection of meningotheial cells present irregularly in nest and cords with foci of psammomatous calcification. There were areas of glial tissue, small nerve twigs and blood vessels. Overall morphology suggestive of meningomyelocele.

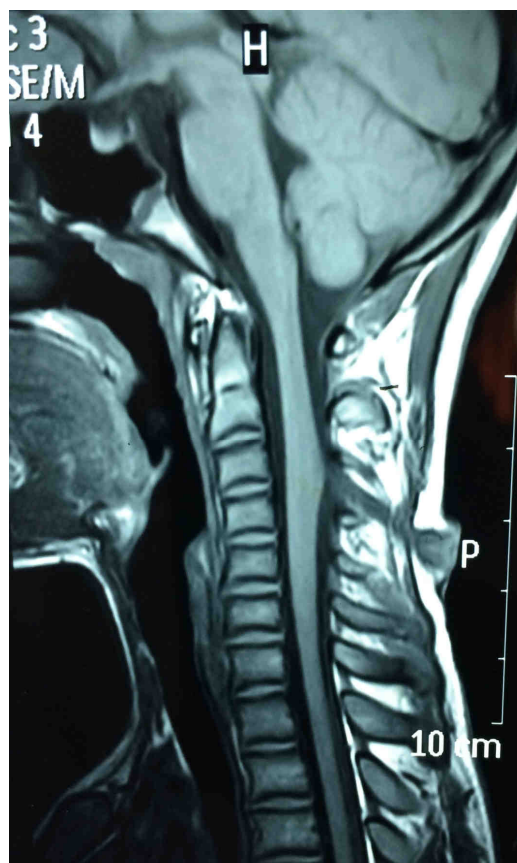


Figure 1 - T1W sagittal section of cervical spine

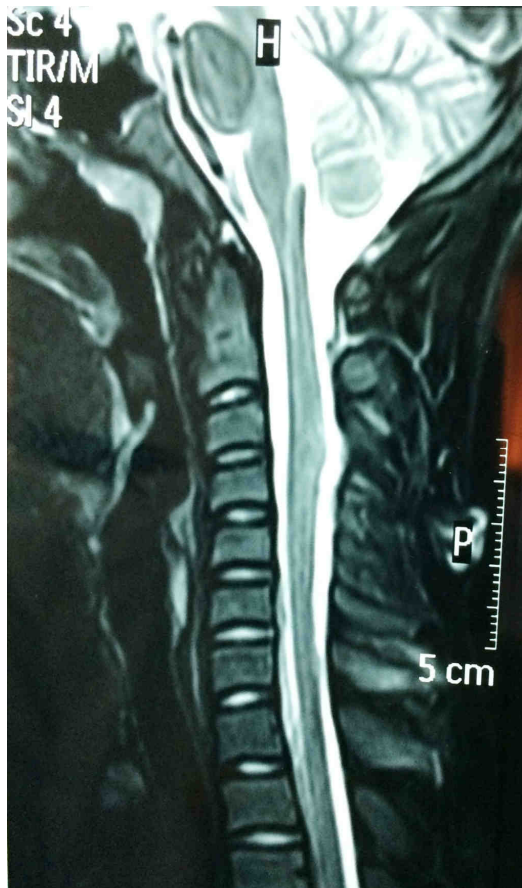


Figure 2 - T2W sagittal section of cervical spine showing the posterior cervical mass lesion with elevated dorsal cord surface and the connecting band

Discussion

Cervical meningocele and myelomeningocele are rare lesions that comprise only a small proportion of neural tube anomalies. Previous studies have reported that these rare entities account for approximately 1-8% of all neural tube defects [3, 4, 6, 7, 9, 10, 11, 12, 13]. Cervical dysraphism lesions are structurally distinct lesions than myelomeningoceles of the thoracic and lumbar regions [2, 5, 8]. The

neural placode is absent in cervical MMC. They are more limited and more protuberant and are usually covered by normal skin tissue to a certain extent of the defect excluding the dome of the cervical MMC, which is lined by squamous epithelium or with scar tissue [10]. Neural structures are not exposed through the defect and CSF leak is not usual [9]. However, tethering of the neural structures to nearby dural or intrasaccular structures may be present [7]. Neurological examinations in patients with cervical MMC are usually normal in newborns [2, 6, 8, 10, 12]. Although cervical MMC causes tethering of the spinal cord, neurological functions of the patients are generally preserved below the level of lesions [9]. If left untreated, the tethered cervical cord is likely to cause gradual neurological deterioration over the years, with motor function in the upper extremities being primarily affected. Posterior fossa distortions and hindbrain herniations if associated, may lead to intellectual dysfunctions [7]. In case of cervical MMC, the neurulation process is uneventful except for fusion of the two sides of the neural fold [3]. Imperfect closure of the neural tube and deficient separation of the cutaneous ectoderm from neural ectoderm results in dorsal myeloschisis [9]. Another theory regarding failure of closure is fusion of the cutaneous ectoderm properly while attachment of neural ectoderm to cutaneous ectoderm incurs maldevelopment of the skin [12]. Other anomalies associated with cervical MMC include hydromyelia, hydrocephalus, Chiari malformations, diastematomyelia, lipomyelomeningoceles, thickened filum terminale, Klippel-Feil syndrome and thoracic hemivertebra etc [1, 2, 4, 7, 8, 12].

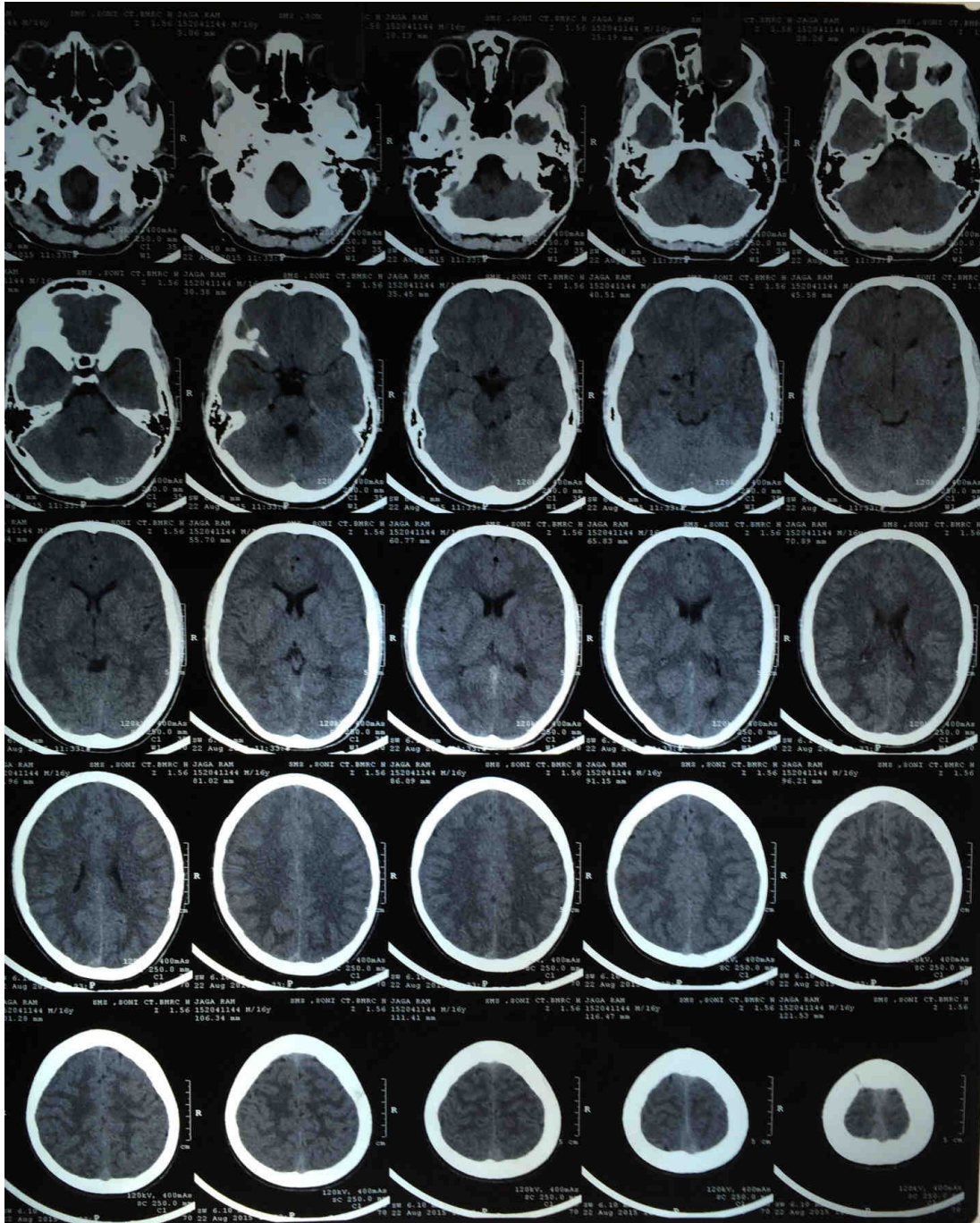


Figure 3 - CT Scan of brain of the same patient

Conclusion

Even adult patients with cervical MMC with a cervical tethered cord can be fully intact neurologically. A thorough preoperative evaluation clinically and radiologically is required. MRI is recommended for patients with cervical MMC to depict the morphological properties of the lesions and to detect any other associated cranial or spinal anomaly. Future neurological deterioration can be prevented if extensive surgical treatment with untethering of neural structures in and around the defect together with management of the associated anomaly is provided. We acknowledge that further long-term follow-up is needed to assess the natural history of the posterior cervical MMC with tethered cord more accurately.

Correspondence

Dr. Gangesh Gunjan

Department of Neurosurgery

SMS Medical College & Hospital

Jaipur, Rajasthan, India

PIN 302004

E mail: dr_gunjangangesh@yahoo.com

Phone no. +91 7727834367

References

1. Delashaw JB, Park TS, Cail WM, Vollmer DG: Cervical meningocele and associated spinal anomalies. *Childs Nerv Syst.* 3(3):165-169, 1987
2. Etus V, Sarisoy HT, Ceylan S: Surgical technique and outcome in cervical and thoracic myelomeningocele surgery clinical study. *Journal of Clinical Neuroscience* 13: 643-647, 2006
3. Habibi Z, Nejat F, Tajik P, Kazmi SS, Kajbafzadeh A-M: Cervical myelomeningocele. *Neurosurgery* 58: 1168-1175, 2006
4. Konya D, Dagcinar A, Akakin A, Gercek A, Ozgen S, Pamir MN: Cervical meningocele causing symptoms in adulthood. Case report and review of the literature. *J Spinal Disord Tech* 19: 531-533, 2006
5. Kasliwal MK, Dwarakanath S, Mahapatra AK: Cervical meningocele-an institutional experience. *Childs Nerv Syst* 23(11): 1291-1293, 2007
6. May D, Rilliet B, Berney J: Cervical meningocele and meningocele. Apropos of 4 cases. *Neurochirurgie* 38(6):347-352, 1992
7. Meyer-Heim AD, Klein A, Boltshauser E: Cervical myelomeningocele follow-up of five patients. *European Journal of Paediatric Neurology* 7: 407-412, 2003
8. Nishio S, Morioka T, Hikino S, Fukui M: Cervical (myelo)meningocele: Report of 2 cases. *J Clin Neurosci.* 8(6):586-7, 2001
9. Pang D, Dias MS: Cervical myelomeningoceles. *Neurosurgery* 33: 363-373, 1993
10. Salomao JF, Cavalheiro S, Matushita H, Leibinger RD, Bellas AR, Vanazzi E, Souza LAM, Nardi AG: Cystic spinal dysraphism of the cervical and upper thoracic lesion. *Childs Nerv Syst* 22: 234-242, 2006
11. Steinbok P, Cochrane D: The nature of congenital posterior cervical or cervicothoracic midline cutaneous mass lesions. *J Neurosurg* 75: 206-212, 1991
12. Steinbok P: Dysraphic lesions of the cervical spinal cord. *Neurosurgery Clinics of North America* 6(2): 367-376, 1995
13. Vogter DM, Culbertson JL, Schochet SS, Gabriele OF, Kaufman HH: "High Spinal Dysraphism" Case report of a complex cervical meningocele. *Acta Neurochir (Wien)* 84: 136-139, 1987