



Evaluation of the clinical efficiency of transforaminal epidural steroid injection in the treatment of sciatica

Zafer Gündoğdu¹, İbrahim Burak Atcı², Serdal Albayrak²,
Hakan Yılmaz³, Aykut Urfalıoğlu⁴

¹Elazig Education and Research Hospital, Department of Anesthesiology and Pain Medicine, Elazig, Turkey

²Elazig Education and Research Hospital, Department of Neurosurgery, Elazig, Turkey

³Duzce State Hospital, Department of Neurosurgery, Duzce, Turkey

⁴Kahramanmaraş Sutcu Imam University, Department of Anesthesiology and Pain Medicine, Kahramanmaraş, Turkey

Abstract: *Objective:* Evaluation of clinical efficiency of fluoroscopy-accompanied transforaminal epidural steroid injection in patients with symptomatic lumbar foraminal intervertebral disc herniation and foraminal stenosis. *Methods:* Fifty patients, who underwent fluoroscopic-guided epidural steroid injection between 19.12.2013 - 28.02.2014, were evaluated retrospectively. Pain levels of patients before the procedure, after 3 weeks and after 6 months were compared using visual analog scale (VAS). Fifty percent or more decrease, less than 50% decrease and no change in VAS were evaluated as sufficient response, insufficient response and unresponsiveness, respectively. The patients were asked whether they would undergo this process again and “Yes”, “Maybe” and “No” answers were evaluated for patient satisfaction score. *Results:* In 50 patients (32 female, 18 male), average pain levels were found to be 8.4 (VAS 7-9), 4.3 (VAS 1-9) and 4.4 (VAS 0-9) before the procedure, 3 weeks after the procedure and 6 months after the procedure, respectively. While thirty-seven (74%) of the patients were found to have sufficient response to treatment 3 weeks after the procedure, 10 (20%) patients were found to have insufficient response. There was no response to treatment in 3 (6%) patients. While thirty-five (70%) of the patients were found to have sufficient response to treatment 6 months after the procedure, 10 (20%) patients were found to have insufficient response. Six months after the procedure, there was no response to treatment in 5 patients (%10). Statistically significant improvement was observed when the pre and post-procedure VAS scores were compared. Forty (80%) patients gave the answer “Yes” to the question whether they would undergo this procedure again. *Conclusion:* We found that fluoroscopic guided transforaminal epidural steroid injection is effective in pain relief in patients with lumbar foraminal intervertebral disc herniation and foraminal

stenosis that are resistant to pharmacological and physical therapy and have no absolute indication for surgery.

Key words: Epidural steroid injection, lumbar disc herniation, transforaminal epidural steroid

Introduction

Nowadays, lumbar pain accompanied by radicular symptoms is one of the most serious medical and socio-economic problems. Lumbar intervertebral disc herniation and spinal stenosis are two leading frequent reasons of this condition, which causes serious limitations in the social life. Lumbar pain is a health problem that is experienced by 80% of the individuals in the society at least once during their lives [1,12]. Most of the patients have acute pain and their pains are mostly relieved by rest and medical treatment. In approximately 10% of the cases, the pain lasts more than 4-6 weeks and becomes chronic. Lumbosacral radiculopathy improves mostly with conservative treatment procedures (life style change, bed rest, exercise, anti-inflammatory drugs, muscle relaxants and opioids). Transforaminal epidural steroid injection is a frequently used, low-risk treatment option that is used in patients with no response to aforementioned treatment options and no surgical indication [1, 7, 12, 14].

In this retrospective study, we aimed to present the effectiveness of transforaminal epidural steroid injection (TFESI) under C-arm fluoroscopy guidance in patients with complaints of lumbar and leg pain that were due to lumbar foraminal intervertebral disc herniation and spinal foraminal stenosis and were unresponsive to conservative treatment options.

Material and Method

This study was performed by retrospectively investigating the records of the TFESI procedures that were implemented in the operation room through the guidance of C-arm fluoroscopy to patients, who applied to the Algology Clinic due to radiculopathy and lumbalgia related to lumbar foraminal intervertebral disc herniation and spinal foraminal stenosis and whose complaints did not reveal with conservative treatment and who did not have an indication for surgery. The data of the study were obtained from the file data of 50 patients, who had undergone TFESI treatment for a period of 3 months, covering the dates 19.12.2013-28.02.2014. The patients were within the age range of 28-79 years old. Local ethics committee approval was obtained. All of the patients were informed verbally and in written about the procedure and their approvals were obtained. The degree of epidural injection was determined following physical examination findings and the magnetic resonance imaging (MRI) or computed tomography (CT) images of the patients. In 50 patients, transforaminal epidural injection was performed between Lumbar 3-Sacral 1 vertebrae, starting from the level at which lumbar foraminal intervertebral disc herniation or spinal foraminal stenosis was observed. The age, gender, occupation, severity of the pain and radiological findings of

the patients were evaluated. The visual analog scale (VAS) was used for scoring the pain between 0-10. The VAS scores of patients were recorded before the intervention, 3 weeks after the intervention and 6 months after the intervention. Fifty percent or more decrease, less than 50% decrease and no change in VAS were evaluated as sufficient response, insufficient response and unresponsiveness, respectively. The patients were asked whether they would undergo this process again and "Yes", "Maybe" and "No" answers were evaluated for patient satisfaction score. Patients with spinal instability, local or generalized infection, bleeding diathesis, psychological problems and who did not consent were excluded. All the patients had no history of previous lumbar surgery. Chi-square test was used for statistical analysis of the data.

TFESI Implementation

Electrocardiography, pulse oximeter and arterial blood pressure monitoring following peripheral vascular access and isotonic sodium chloride infusion were performed. The patients were prone positioned in the operating room and a pillow was placed under the abdomen for flattening the lumbar curvature. Two Lt/min. oxygen, 2-3 mg Midazolam and 50 microgram Fentanyl were administered and sedoanalgesia was provided in order to decrease the anxiety and pain of the patients. The lumbar region was cleaned according to the rules of asepsis – antisepsis and was covered with sterile drapes. A 1-mg/kg dose of Lidocaine was applied as a local anesthetic into subcutaneous and deep tissues.

The nerve stimulator needle was advanced 10-15 cm to the implementation level through the guidance of C - arm fluoroscopy after the local anesthesia. Target vertebral foramen level was reached with 1.0-milliamper (ma) stimulator via safe triangle method (subpedicular approach). In the subpedicular approach, the agents are injected at the exit zone as the distal site of the nerve root. In this approach, gauge spine needle is progressed toward the subjacent pedicle and inferolateral to the pars interarticularis (safe triangle) for the superior intervertebral foramen. When the tip of the needle reached the inferolateral border, the C-arm was rotated for lateral view; and the needle was gradually advanced towards the anterior and superior aspects of the intervertebral foramen. The current was then decreased to 0.3 ma when muscle contraction was seen. Then the needle was retracted 1 mm and its position was verified by visualizing the spread of the contrast agent (Iohexol 14 mg/ml) to the nerve root and the anterior epidural area (Figure 1, Figure 2). In case of a vascular leakage, the needle was retracted and positioned again. Afterwards, a 2-5 cc mixture of 80 mg Triamcinolone, 40 mg Lidocaine and 2 ml saline was injected to the foramen. After the procedure, the patients were monitored in the Algology Clinic Service for 3-4 hours for probable complications. A bed rest of approximately one week and a salt-free diet were recommended to the patients. The patients were discharged after being asked for a three-week and six-month follow-up controls.

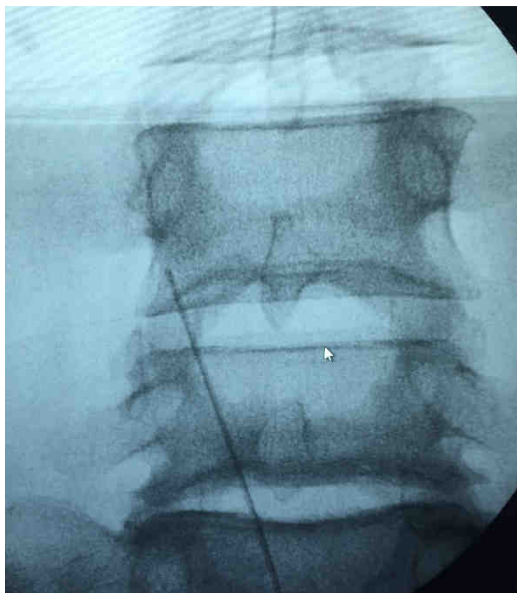


Figure 1 - Advancing the peripheral nerve stimulator needle to the L4-L5 level through the guidance of C - arm fluoroscopy for right foraminal stenosis

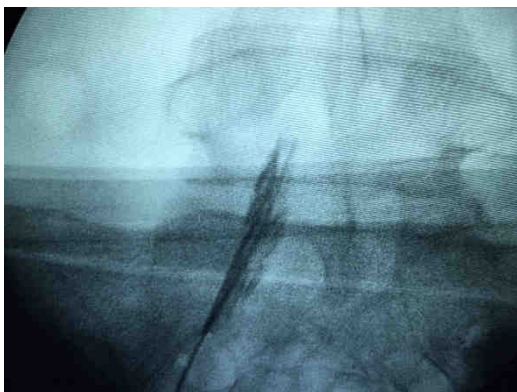


Figure 2 - Visualizing the spread of the contrast agent to the S1 nerve root and the anterior epidural area

Results

The patients had diagnoses of lumbar intervertebral disc herniation and spinal stenosis. The mean age of the patients was 51.36 years, ranging between 28 and 79. There

were 32 female and 18 male patients, with a F/M ratio of 1.76. The mean age of female patients was 51 years and the mean duration of complaint was 37 months. The mean age of male patients was 52 years and the mean duration of complaint was 36 months. All female patients (96.9%), except 1 (3.1%), were housewives. Of the male patients, 8 (44.4%) were workers and the remaining (55.6%) was retired or was not working.

A total of 60 transforaminal epidural steroid injections were performed. Injections were made between L3- S1 vertebrae. Forty patients had single level injection, whereas 10 patients had multiple level injections during the same session. The patients who underwent multiple level injections were the ones with lumbar intervertebral disc herniation and spinal stenosis at more than one level. All the patients had lumbar MRI or CT scans before the procedure. Of all 50 patients, levels of foraminal intervertebral disc herniation and foraminal stenosis were as follows; 7 at L3 - 4 levels, 18 at L4 - 5 levels, 15 at L5 - S1 levels, 5 at L4 - 5 + L5 - S1 levels, 3 at L3 - 4 + L4 - 5 levels and 2 at L3 - 4 + L5 - S1 levels. The procedure levels were L4 - 5 for 26 (43.3%) patients, L5 - S1 for 22 (36.6%) patients and L3 - 4 for 12 (20%) patients (Table 1).

The levels of pain of the patients were measured before, 3 weeks and 6 months after the procedure and were compared using visual analog scale (VAS). The mean pain score of patients was found to be 8.4 (VAS range 7-9) before the injection, 4.3 (VAS range 1-9) 3 weeks after the injection and 4.4 (VAS range 0-9) 6 months after the injection (Graph 1). Fifty percent or more decrease, less than 50%

decrease and no change in VAS were evaluated as sufficient response, insufficient response and unresponsiveness, respectively. While thirty-seven (74%) of the patients were found to have sufficient response to treatment 3 weeks after the procedure, 10 (20%) patients were found to have insufficient response. There was no response to treatment in 3 (6%) patients (Graph 2). While thirty-five (70%) of the patients were found to have sufficient response to treatment 6 months after the procedure, 10 (20%) patients were found to

have insufficient response. Six months after the procedure, there was no response to treatment in 5 patients (10%) (Graph 3). Statistically significant improvement was observed when pre and post-procedure (3-week and 6-month) VAS scores were compared ($p < 0.05$). When post-procedure 3-week and 6-month VAS scores were compared, even though there was an increase in VAS scores, the difference between these values was considered as statistically insignificant ($p > 0.05$).

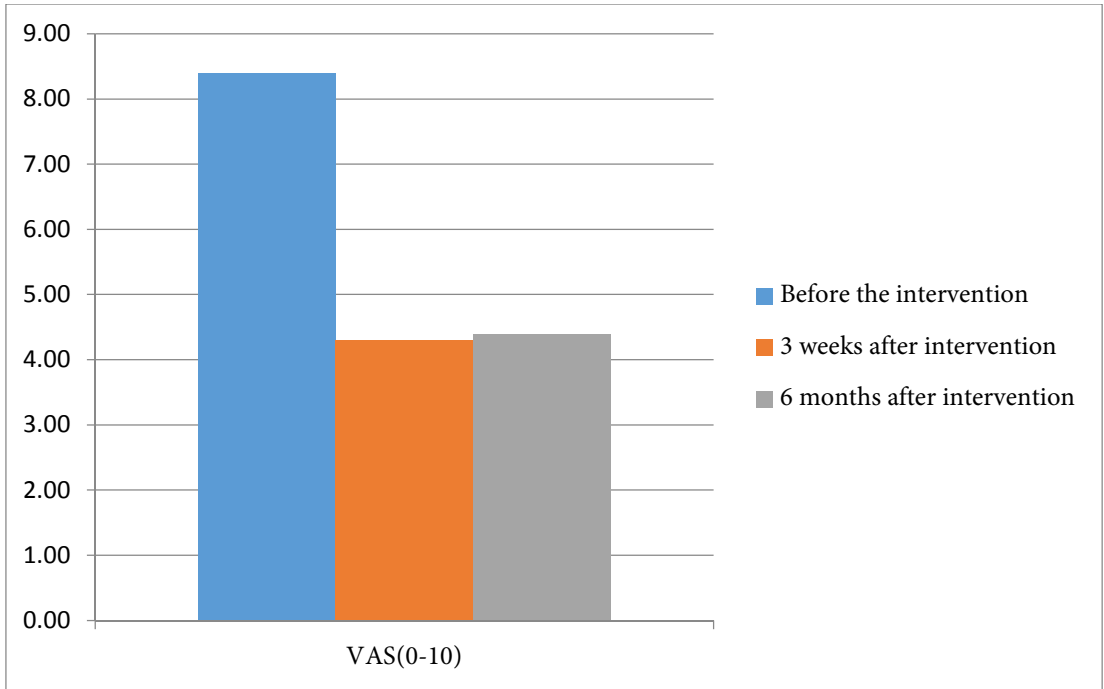
TABLE 1**The levels of transforaminal epidural steroid injection**

Injection Levels	The number of patients
L4-5	26
L5-S1	22
L3-4	12

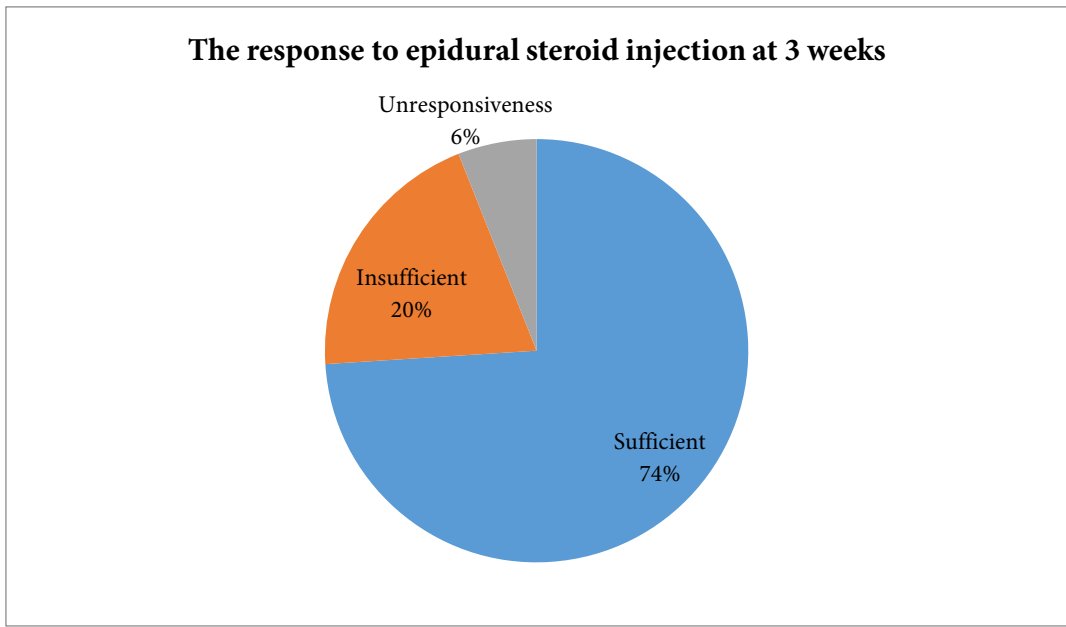
TABLE 2**The VAS scores of patients before, 3 weeks and 6 months after the intervention**

Patient Number	VAS- before intervention	VAS- 3 weeks after intervention	VAS- 6 months after intervention
1	9	2	0
2	8	8	8
3	9	9	9
4	8	3	4
5	9	4	5
6	8	7	8
7	9	2	8
8	9	8	3
9	8	1	3
10	9	2	2
11	7	1	3
12	8	3	2
13	9	3	3
14	8	3	3
15	9	3	4
16	7	3	3

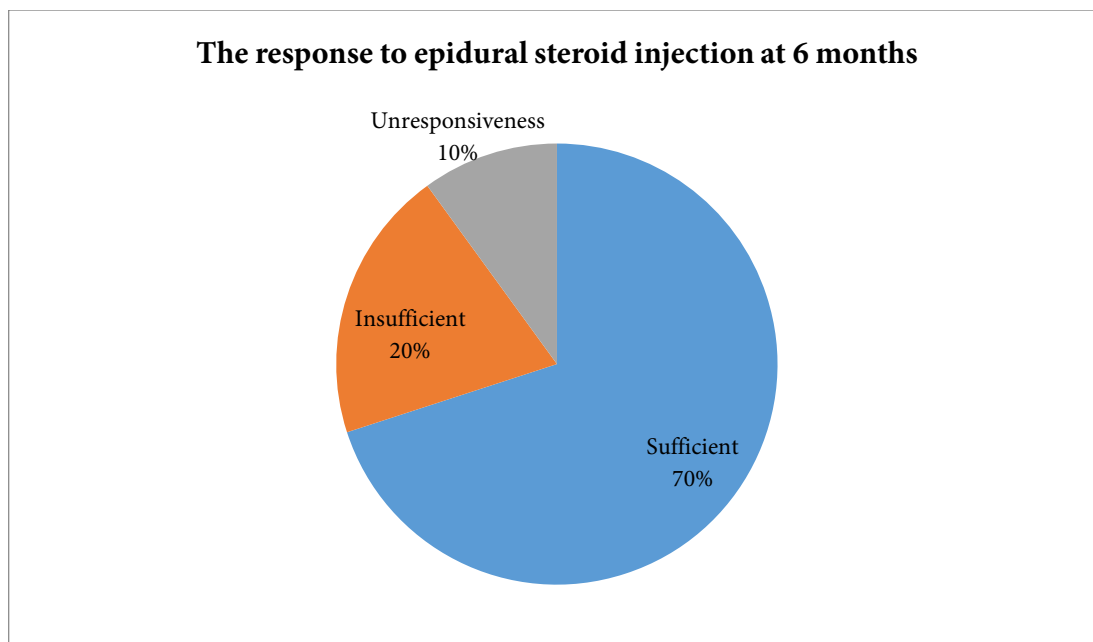
17	8	4	4
18	9	4	4
19	8	4	4
20	9	4	3
21	8	4	4
22	7	3	5
23	9	8	8
24	8	6	4
25	9	6	4
26	8	4	4
27	8	3	3
28	8	6	1
29	8	3	3
30	9	4	4
31	8	3	4
32	9	3	4
33	9	4	4
34	8	4	4
35	9	4	6
36	8	4	1
37	8	4	4
38	9	4	8
39	8	4	4
40	9	7	4
41	8	4	4
42	9	6	7
43	9	7	2
44	9	3	3
45	9	4	8
46	8	4	4
47	9	4	7
48	8	8	8
49	8	7	8
50	9	4	7



Graph 1 - Mean pain scores of patients before the injection, 3 weeks after the injection and 6 months after the injection



Graph 2 - The response to epidural steroid injection at 3 weeks



Graph 3 - The response to epidural steroid injection at 6 months

The patients were asked whether they would undergo this process again and “Yes”, “Maybe” and “No” answers were evaluated for patient satisfaction score. Forty patients (80%) gave the answer “Yes” to the question, 5 (10%) patients gave the answer “No” and 5 (10%) patients gave the answer “Maybe”.

In 4 of 10 patients with insufficient response at the end of 6 months and in 3 of 5 patients with no response to treatment at the end of 6 months, control MRI revealed indication for surgery, so surgery was planned for those patients.

Technical success was achieved in all of the injections evaluated in the study and no complication such as dural puncture, epidural hematoma and intra-arterial injection was seen.

Discussion

In the treatment of lumbar disc herniation and spinal stenosis, epidural steroid injection is an alternative treatment method that is implemented increasingly [4, 6]. The effectiveness of the corticosteroids in the treatment of pain is by decreasing the inflammation, which is related to mechanical compression, ischemia and chemical irritation of the nerve root. The corticosteroids damages pla2 cascade and decrease formation of arachidonic acid metabolites, prostaglandins and leukotrienes that ease pain formation [6]. These inflammatory mediators cause intraneural edema and venous congestion. Since the corticosteroids directly affect the mesodermal elements, the arachnoid tissue and the fibrous tissue, local injection is more effective than the systemic injection. Because

the corticosteroids have the membrane stabilization effect on the nerve, they may obstruct the ectopic discharge. The corticosteroids slow down the conduction in the C fibers. Besides, they also have local anesthetic effects. The epidural steroid injection can be performed through caudal, interlaminar and transforaminal routes [4, 6].

In fact, the history of transforaminal epidural block is not new. In 1952, Robecchi and Capra implemented S1 sacral transforaminal steroid injection for lumbar pain. Lievre implemented sacral transforaminal injection in 1953 as well. In 1971, Macnab has published the diagnostic value of selective nerve infiltration in radiculopathy in USA. Lumbar transforaminal injection has been commonly implemented since that time [1, 3].

It is thought that the radicular symptoms are caused by mechanical irritation of the nerve root by the disc material rather than a mechanical pressure to the nerve root. Regarding this, the local implementation of corticosteroids to compressed and inflamed nerve root seems to be the most appropriate method for the treatment of radiculopathy [8].

The aim of the lumbar transforaminal epidural block is to directly reach to the nerve root. It is believed that the selective effectiveness of the drug is increased by applying steroid in high concentration to the region of the pain. Contrary to the traditional methods, a much higher tissue concentration is provided with much lesser steroid with the transforaminal approach. However, there are some disadvantages such as intravascular injection, intraneural injection and nerve

injury [10, 13, 15]. In our study, we applied a mixture of 3-5 cc mixture of 80 mg triamcinolone, 40 mg lidocaine and 2 ml saline to the target area.

The lumbar transforaminal epidural bloc must certainly be implemented under the guidance of fluoroscopy. This fact provides the safety of the transforaminal epidural steroid injection. Even though the lumbar transforaminal epidural steroid injection seems to be easily implemented, the anatomical properties of the region should be well known for a successful implementation and the operation should be done by following the rules [1, 12].

In the study by Rosenberg et al., it was determined that the lumbar pain is seen mostly around the age of 60 and more in women than in men [11]. Similarly, the mean age of female patients was 51 and the mean age of male patients was 52 in our study, and female/male ratio was 1.77. In a study by Bottwin et al., the most affected levels were L5-S1, L4-5 and L3-4, respectively. In our study, mostly involved levels were as follows; L4-5, L5-S1 and L3-4 [5].

Manchikanti et al., compared three methods of epidural steroid injection in patients having lumbar pain [9]. In this retrospective study on 225 people, even though it was demonstrated that all of the three methods are effective in providing pain control, they obtained more effective results for a longer period in caudal and transforaminal routes. In a study by Joon Woo Lee et al., fluoroscopy-guided transforaminal injection was applied to 248 patients, who were diagnosed having single level nerve root

pressure related to lumbar disc herniation or spinal stenosis [8]. The pain levels before the injection and 2 week after the injection were compared. A decrease of 50% or more in the pain score was considered as a successful response and a successful response was achieved in 76.8% of the patients.

In a study by Abdulkadir et al., 37 patients were examined retrospectively and the VAS scores of the patients at the 3rd week and at the 6th month were evaluated [2]. Of the patients, 84.6% were found to have successful response at the 3rd week and 78% were found to have successful response at the 6th month. In our study, a sufficient response was obtained in 37 patients (74%) and an insufficient response was obtained in 10 patients (20%) at the 3rd week. No response was seen in 3 (6%) patients. While 35 (70%) patients had a sufficient response, 10 patients (20%) had insufficient response at 6th month after the injection. No response was seen in 5 (10%) patients at 6th month after the injection.

In a study by Vad et al., 48 patients from two separate treatment groups were monitored during 16 months [15]. The success rate was found to be 84% in the transforaminal anterior epidural steroid injection group, whereas it was 48% in the placebo group. In a study by Botwin et al., on patients who underwent fluoroscopy-guided transforaminal anterior epidural steroid injection, they found that there was at least a 50% decrease in VAS scores of 75% of the patients during a 6-week follow up period [5].

Conclusion

In this study, we aimed to present the effectiveness of fluoroscopy-guided transforaminal epidural steroid injection (TFESI) in patients with symptomatic lumbar foraminal intervertebral disc herniation and foraminal stenosis. We found that fluoroscopic guided transforaminal epidural steroid injection is effective in pain relief in patients with lumbar foraminal intervertebral disc herniation and foraminal stenosis that are resistant to pharmacological and physical therapy and have no absolute indication for surgery.

Competing interests

The authors declare that they have no competing interests.

Correspondence

Hakan Yilmaz

Department of Neurosurgery, Duzce State Hospital, Duzce, Turkey.

Phone: 0506 621 18 29

E-mail: dr_hakanyilmaz@hotmail.com

References

1. Abdi S, Datta S, Trescot AM, Schultz DM, Adlaka R, Atluri SL, et al. Epidural steroids in the management of chronic spinal pain: a systematic review. *Pain Physician* 2007; 10:185-212.
2. Abdulkadir A, Suleyman D, Oguz K, Mehmet O, Tarik P, Ercan K. Assessment of the effectiveness of lumbar transforaminal epidural steroid injection for low back pain. *Agri* 2011; 23(3):114-118.
3. Bosscher HA, Gitlin MG, Kaye AD. Epidural steroids. In: Raj PP, editor. *Textbook of regional anesthesia*. Philadelphia: Churchill Livingstone; 2002.p.687-702.
4. Boswell MV, Hansen HC, Trescot AM, Hirsch JA. Epidural steroids in the management of chronic spinal pain and radiculopathy. *Pain Physician* 2003; 6(3):319-34.

5. Botwin KP, Gruber RD, Bouchias CG, Torres-Romas FM, Sanelli JT, Freeman ED, et al. Fluoroscopically guided lumbar transforaminal epidural steroid injections in degenerative lumbar stenosis: An outcome study. *Am J Phys Med Rehabil* 2002; 81:898-905.
6. Buenaventura RM, Datta S, Abdi S, Smith HS. Systematic review of therapeutic lumbar transforaminal epidural steroid injections. *Pain Physician* 2009; 12:233-51.
7. Karaeminogullari O, Aydinli U. Degenerative lumbar spinal stenosis. *Journal of Turkish Association of Orthopaedics and Traumatology* 2004; 3:3-4.
8. Lee JW, Kim SH, Lee IS, Choi JA. Therapeutic effect and outcome predictors of sciatica treated using transforaminal epidural steroid injection. *AJR* 2006; 187:1427-31.
9. Manchikanti L, Pakanati RR, Pampati V. Comparison of three routes of epidural steroid injections in low back pain. *Pain Digest* 1999; 9:277-85.
10. Manchikanti L. Transforaminal lumbar epidural steroid injections. *Pain Physician* 2000; 3(4):374-98.
11. Rosenberg SK, Grabinsky A, Kooser C, Boswell MV. Effectiveness of transforaminal epidural steroid injections low back pain: a one year experience. *Pain Physician* 2002; 5(3):266-70.
12. Schaufele MK, Hatch L, Jones W. Interlaminar versus transforaminal epidural injections for the treatment of symptomatic lumbar intervertebral disc herniations. *Pain Physician* 2006; 9:361-366.
13. Smuck M, Fuller BJ, Yoder B, Huerta J. Incidence of simultaneous epidural and vascular injection during lumbosacral transforaminal epidural injections. *Spine J* 2007; 7(1):79-82.
14. Suslu H, Atar E, Arslan G, Alatli I, Altun M, Abraz S. Efficiency of the transforaminal epidural steroid treatment in chronic low back pain. *The Journal of Kartal Training and Research Hospital* 2008; 19(2): 67-72.
15. Vad VB, Bhat AL, Lutz GE, Cammisa F. Transforaminal epidural steroid injections in lumbosacral radiculopathy: A prospective randomized study. *Spine* 2002; 27:11-16.