

## Spontaneous intracranial hemorrhage – ruptured lobar arteriovenous malformations: report of two cases

A. Tascu<sup>1</sup>, C. Pascal<sup>2</sup>, S.M. Florea<sup>2</sup>, St.M. Iencean<sup>3</sup>

<sup>1</sup>“Carol Davila” University of Medicine and Pharmacy, Bucharest

<sup>2</sup>First Neurosurgical Clinic, “Bagdasar-Arsen” Clinical Hospital, Bucharest

<sup>3</sup>“Grigore T. Popa” University of Medicine and Pharmacy Iasi

**Abstract:** Brain arteriovenous malformations (AVMs) are lesions thought to be primarily congenital in origin, consisting of fistulous connections of abnormal arteries and veins, without normal intervening capillary beds and no cerebral parenchyma between vessels. In the pediatric population, AVMs represent the most common cause of spontaneous intracranial hemorrhage (ICH), with a high recurrent bleeding risk. The aim of this paper is to report 2 cases of ruptured lobar AVMs in children, presenting with spontaneous ICH. Due to the patients’ neurological status, the only imaging examination performed preoperatively was a CT scan, showing intraparenchymal hemorrhage. Thus, there was no MRI/angiographic examination to prove the existence of a brain AVM prior to the surgical interventions. Also, the cerebral angiography performed after the surgery showed, in both patients, no signs of residual vascular malformations. Therefore, the diagnosis of AVM was certified by macroscopic and microscopic pathological findings, with no brain imaging suggestive of a vascular malformation.

**Key words:** brain AVM, pediatric, intracranial hemorrhage

### Introduction

Arteriovenous malformations (AVMs) are vascular lesions constituted by abnormal intracranial vessels, both arteries and veins, connected between them, with no capillary bed interposed (1, 2). There are 3 typical morphological structures composing an AVM: feeding arteries, draining veins and a vascular nidus formed by a tangle of numerous

AV shunts with no brain tissue included (1, 3-6). AVMs are considered to have congenital origins, but reports of de novo cases were also recorded in the neurosurgical literature (1-2, 7-9). Although the most common age at diagnostic for patients is 20 to 40 years old (1-2, 12-14), 3 to 20% of patients with AVMs are children and this pathology causes 30 to 50% of intracranial spontaneous hemorrhage in the

pediatric population (9-11, 15).

The main imaging diagnostic techniques in AVMs are computed tomography (CT), magnetic resonance imaging (MRI) and catheter angiography, from which the most useful in ruptured malformations is CT scan, as it offers information on the mass effect and displacement of cerebral structures caused by the blood clot (1, 2, 15).

Arteriovenous malformations are classified, according to the Martin-Spetzler scale (Table 1) in V grades, based on size, location and pattern of venous drainage, and it has been widely adopted as it has proven to be a good predictor of surgical morbidity risk (15, 19, 20).

There are 5 main options to treat AVMs, proposed by Drake in 1979 and still present in the brainsurgeons treatment planning: expectant behavior, surgery, endovascular treatment, radiotherapy or a combination of preceding options (2, 21). The last of the five points appear to increase chances of obliteration and decrease risk of bleeding (2, 15, 22).

**TABLE 1**  
**Martin Spetzler Grading scale for AVMs**

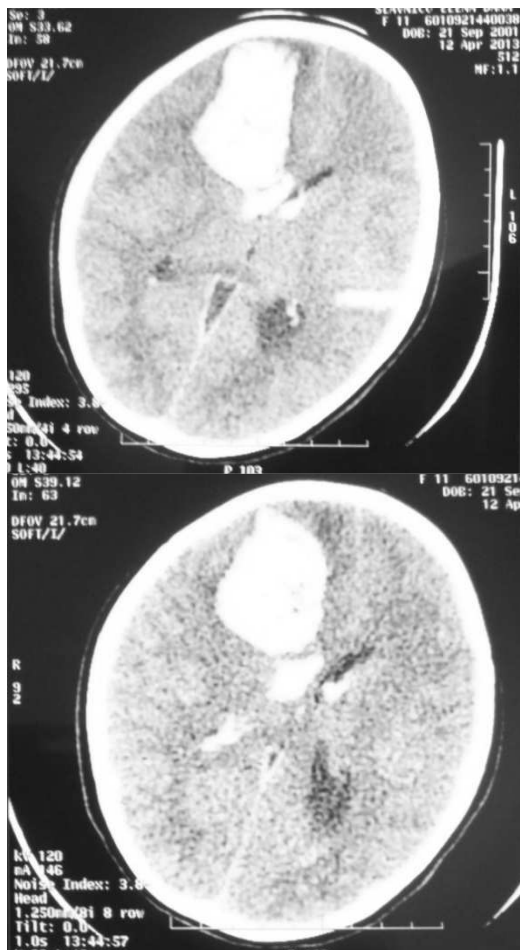
CHARACTERISTIC	POINTS
<b>AVMs size</b>	
◦ Small (<3cm)	1
◦ Medium (3-6cm)	2
◦ Large (>6cm)	3
<b>Location</b>	
◦ Non-eloquent site	0
◦ Eloquent site*	1
<b>Pattern of venous drainage</b>	
◦ Superficial	0
◦ Deep drainage component	1
*sensorimotor, language, visual cortex, hypothalamus, thalamus, internal capsule, brain stem, cerebellar peduncles, cerebellar nuclei	

### Case 1

History and examination: an 11 year old girl presented at the Emergency Department with headache, nausea/vomiting, that started during the morning, followed by grand mal seizures and coma – Glasgow Coma Scale of 5 points. The neurological examination showed left hemiplegia and no pupillary reflexes. Due to acute respiratory failure, the girl needed orotracheal intubation and mechanical ventilation. Patient's parents reported no trauma history.

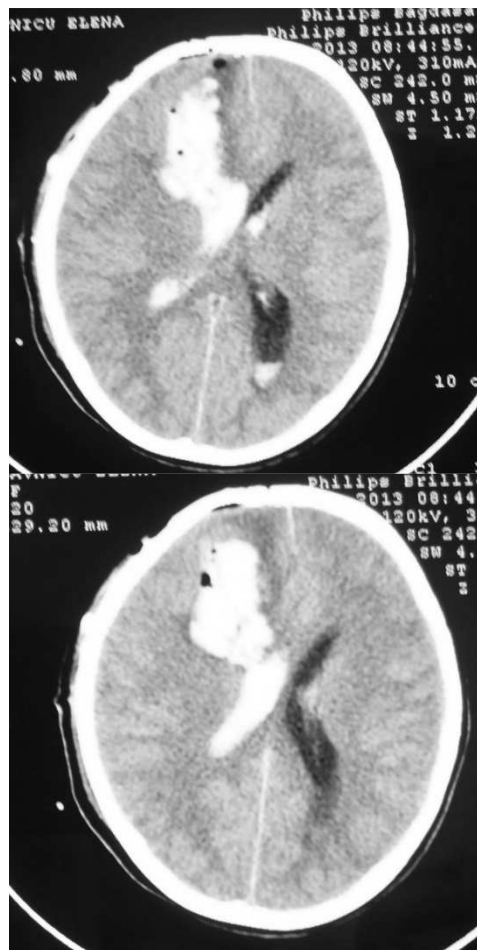
Imaging: we performed an emergency computed tomography (Figure 1) that revealed the presence of a large right frontal hematoma that exerted a significant mass effect over the midline structures, accompanied by intraventricular bleeding.

Operation: considering the patients' neurological status and the CT scan aspect, we opted for life saving clot evacuation surgery. During the procedure, there were no anatomical signs of an arteriovenous malformation. Patient's neurological status improved postoperatively, reaching a Glasgow Coma Scale of 8 points 24 hours after the intervention. She was also able to breathe on her own, through the intubation tube. A control CT scan (Figure 2) showed a new bleeding, and a new surgical intervention had to be performed. After the blood clot evacuation, the surgical team was able to see a drainage vein with arterialized blood, arterial vessels and a nidus of aprox 1,5 cm, aspect consisting with an arteriovenous malformation. The AVM was dissected, excised and then sent for histopathological analysis. The histological examination confirmed the presence of an AVM.



**Figure 1** - CT scan at admission, showing a large right frontal hematoma and intraventricular hemorrhage, with significant midline shifting

Postoperative course: the patient's neurological status improved after the second surgical intervention and the control CT scan performed 2 days after the operation (Figure 3) showed complete evacuation of the hematoma and no signs of an arteriovenous malformation. At discharge, the patient presented no neurological deficits.



**Figure 2** - CT scan 24 hours postoperatively revealed a new blood clot that needed surgical intervention

Follow-up: at the 1 month postoperatively the catheter cerebral angiography showed no signs of a residual AVM (Figure 4).

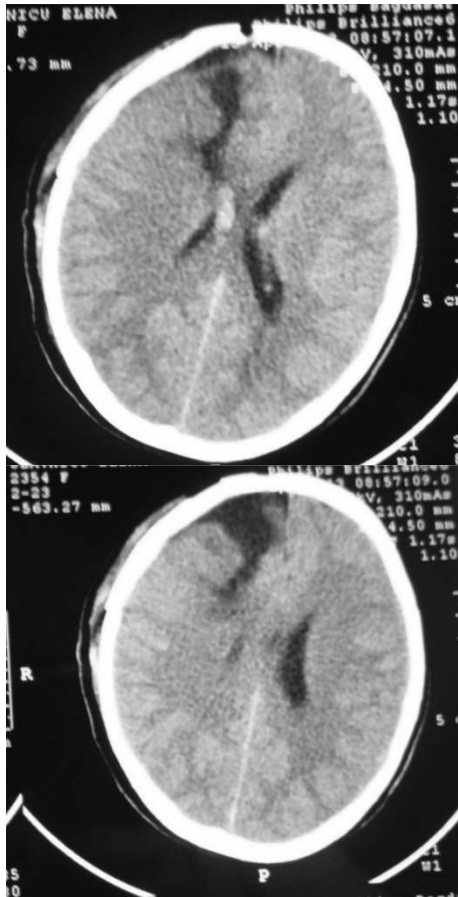


Figure 3 - CT scan aspect 2 days after the second intervention

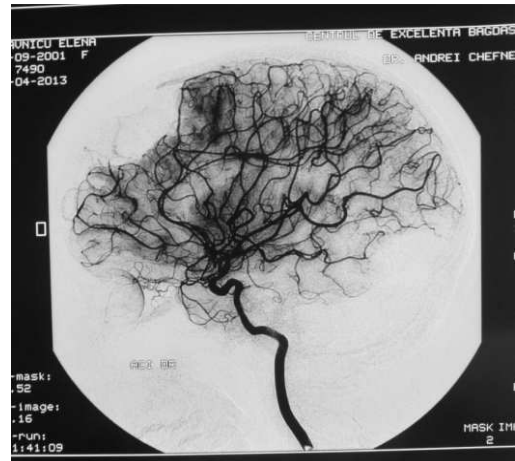
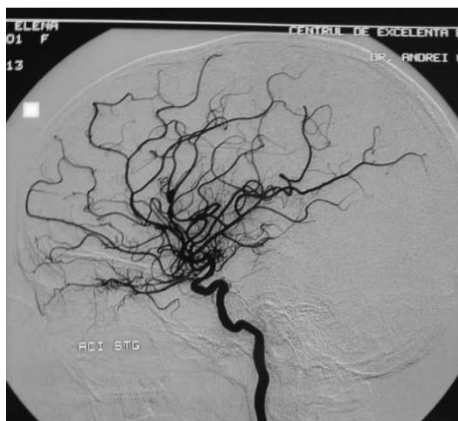

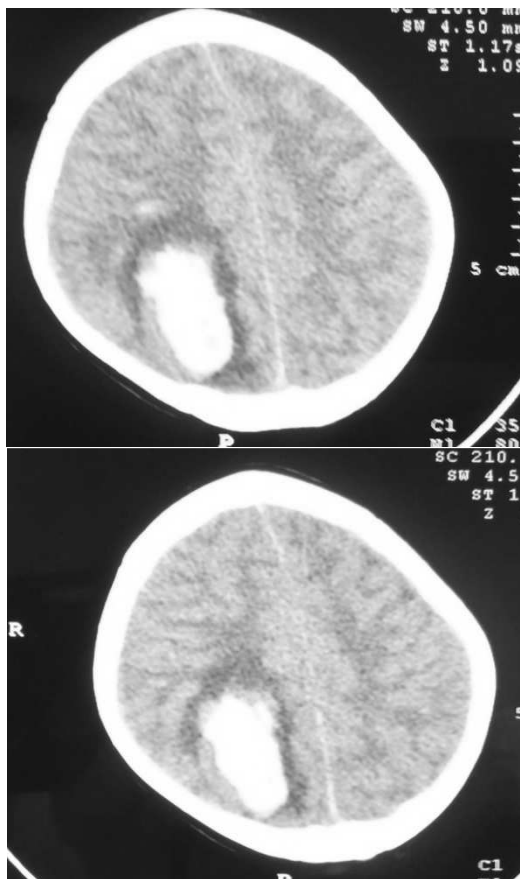
Figure 4 - Angiography performed 1 month after the acute episode

### Case 2

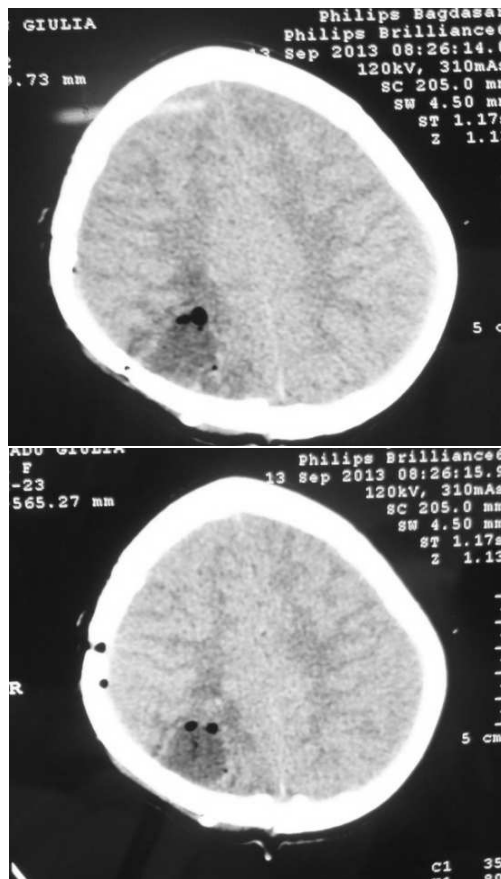
History and examination: a 9 year old girl presented with symptoms of increased intracranial pressure that started with headache, 2 days before admission, followed by nausea and vomiting. The patient's level of consciousness was decreased at 10 points on the Glasgow Coma Scale. The neurological examination showed slow reactive pupils, bilateral Babinski sign and globally increased osteotendinous reflexes. Family reported no traumatic events.

Imaging: CT scan at admission (Figure 5) showed a right parietal-occipital hematoma, with midline shifting to the left side.

Operation: emergency surgical intervention to evacuate the hematoma was requested. At first, there were no signs of an AVM, but after the blood clot was evacuated, during hemostasis, as the clot's mass effect decreased, we discovered an arterialised vein, further dissection revealing an arteriovenous malformation that was completely excised, with no incidents. The piece was sent for histological examination that confirmed the presence of a racemous hemangioma.



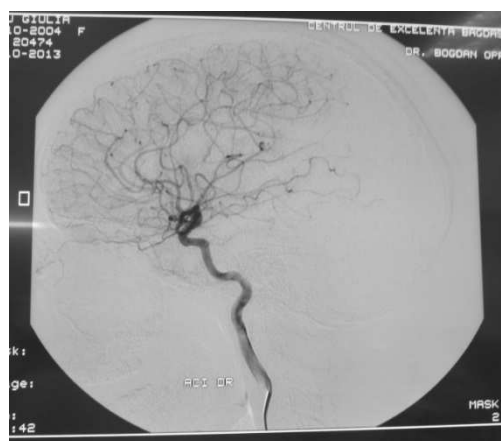**Figure 5** - CT scan at admission showing a blood clot with mass effect on the surrounding structures

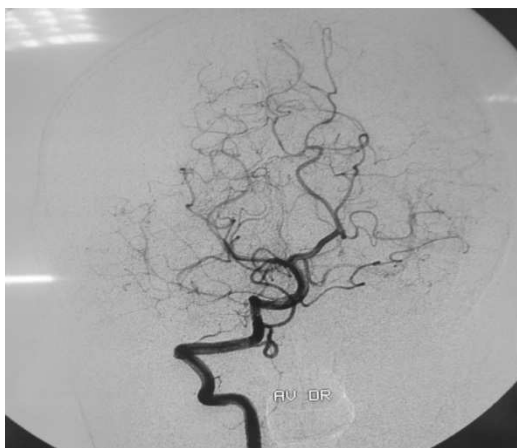


**Figure 6** - Postoperative control CT scan

Postoperative course: the patient's postoperative course was uneventful, and his symptoms completely resolved after surgery. Postoperative CT scan (Figure 6) showed the complete evacuation of the blood clot.

Follow-up: the patient presented at the 1 month follow-up with no neurological deficits. We performed a catheter angiography that showed no signs of residual vascular malformation (Figure 7)





**Figure 7** - Angiographic control, 1 month after the neurosurgical intervention

## Discussions

The most common form of clinical presentation in children with AVMs is intracerebral hemorrhage, followed by first time seizure (less common), intracranial hypertension or focal neurological symptoms (1, 2, 15, 16). In young children (<2 years old), large AVMs may clinically present as high-output heart failure (1-2, 15, 17, 18). Spontaneous ICH in children must be considered a ruptured vascular malformation until proven otherwise.

We reported 2 clinical cases of children presenting with altered neurological status and symptoms of increased intracranial pressure due to intracerebral hemorrhage, with no recent traumatic events. Intraoperative findings proved that the bleeding source was a ruptured arteriovenous malformation, the only evidence sustaining this diagnosis being the histological examinations.

There are multiple imaging techniques to diagnose an AVM. On CT scan, AVMs appear

as serpiginous iso/hyperintense vessels that enhance contrast strongly. CT scan is mostly useful for showing acute hemorrhage, a mass effect or displacement of normal structures. Magnetic resonance imaging (MRI) is superior in sensitivity and specificity to the CT scan, showing size, location, previous symptomatic /asymptomatic hemorrhage, as well as changes like mass effect, edema or ischemia of the surrounding tissue. Cerebral angiography, in addition to details offered by CT/MRI, allows the identification of feeding and draining vessels, along with other associated vascular abnormalities. However, it may be negative after an acute hemorrhage or spontaneous AVM thrombosis. Another useful imaging tool could be computed tomography angiography (CTA), that can guide the surgeon in emergency surgery performed on patients with ruptured vascular malformations. Still, it is not as detailed as MRI or catheter angiography and it can also be a source of false negatives, especially in important bold clots with significant mass effect (1, 2, 15).

Due to the altered general and neurological status in the 2 cases presented, the surgical intervention for decompression of the hematoma had to be performed in emergency, with no time for further imaging investigations that could come useful for the surgical team.

The particularity of these cases was the lack of anatomical evidence of an AVM at first, followed by the ulterior identification of the vascular malformation. Local anatomical and pressional changes, induced by the presence of the blood clot, may alter the blood circulation

inside the arteriovenous malformation and 'hide' it from the surgeons view. Also, after the malformation ruptures, small blood clots that obliterate the AV shunts may form within the malformation, and temporarily interrupt the blood flow inside, making it difficult to be identified. The fact that, in both cases, the malformation became visible after the hematoma evacuation, together with the premise that all spontaneous intracerebral hemorrhages are arteriovenous malformations until proven otherwise, suggests the importance of continuously inspecting the operating wound after the clot removal.

Complete excision of the malformation is the key to completely cure it, especially since the postoperative patient's complications (such as rebleeding, seizures, edema, stroke or vascular thrombosis) depend almost entirely on the extent of resection (15, 23, 24). In both cases, hematoma evacuation and complete excision of the malformation lead to patient's full recovery, despite the severely altered consciousness state and neurological deficits at admission.

Another factor to be taken into consideration when operating on children with ruptured AVMs, is the functional outcome, as the pediatric population has a better capacity to completely/mostly recover postoperatively, compared to adults (15, 25-27). If the surgical intervention fails to completely remove the vascular lesion, multimodality treatment should be taken into consideration, since it appears to improve obliteration and decrease rebleeding rate (1, 2, 15, 22). An angiographic control should be obtained

during follow-up, to certify the complete obliteration of the vascular malformation.

## Conclusions

Whenever a brain surgeon faces spontaneous intracerebral hemorrhage in children the first thought should be a ruptured vascular malformation. During hemostasis, even if there are no signs of a patent AVM while evacuating the hematoma, we should look for anatomical features suggestive of an AVM, since the local alterations caused by the blood clot could have temporarily obliterated the malformation and 'hide' it from surgeon's view.

## References

1. Youmans Neurological Surgery, 6th ed., Elsevier Saunders, PA, 2011.
2. Schmidek & Sweet Operative Neurosurgical Techniques: indications, methods and results, 6th ed., vol. 2, Elsevier Saunders, PA, 2012.
3. Awad IA, Robinson JR Jr, Mohanty S, et al. Mixed vascular malformations of the brain: clinical and pathogenetic considerations, *Neurosurgery*, 1993; 33:179-188.
4. Gao E, Young WL, Ornstein E, et al. A theoretical model of cerebral hemodynamics: application to the study of arteriovenous malformation. *J Cereb Blood Flow Metab.* 1977; 17:905-918.
5. Gault J, Sarin H, et al. Pathobiology of human cerebrovascular malformations: basic mechanisms and clinical relevance. *Neurosurgery.* 2004; 55:1-17.
6. Kader A, Young WL, Pile-Spellman J, et al. The influence of hemodynamic and anatomic factors on hemorrhage from cerebral arteriovenous malformations. *Neurosurgery.* 1994; 34:801-808.
7. Gonzalez LF, Bristol RE, Porter RW, Spetzler RF. De novo presentation of an arteriovenous malformation. Case report and review of literature. *J of Neurosurgery* 2005; 102:726-729.

8. Minakawa T, Tanaka R, Koike T, Takeuchi S, Sasaki O. Angiographic follow-up study of cerebral arteriovenous malformations with reference to their enlargement and regression. *Neurosurgery* 1989; 24: 68-74.
9. Bristol RH, Albuquerque FC, Spetzler RF, Rekate HL, McCougall CG. Surgical management of arteriovenous malformations in children. *J of Neurosurgery* 105:88-93, 2006
10. Celli P, Ferrante L, Palma L, Cavedon G. Cerebral arteriovenous malformations in children and in adults. *Surg Neurol* 22:43-49, 1984
11. Smith ER, Butler WE, Ogilvy CS. Surgical approaches to vascular anomalies of the child's brain. *Curr Opin Neurol* 15:165-171, 2002
12. Humphreys RP, Hoffman HJ, Drake JM, Ruthka JT. Choices in the 1990s for the management of the pediatric cerebral arteriovenous malformations. *Pediatr Neurosurg* 1996; 25:277-285.
13. Kiris T, Sencer A, Sahinbas M, Sencer S, Imer M, Izgi N. Surgical results in pediatric Spetzler-Martin grades I-III intracranial arteriovenous malformations. *Childs Nerv Syst* 2005; 21:69-74.
14. Mori K, Murata T, Hashimoto N, Handa H. Clinical analysis of arteriovenous malformations in children. *Childs Brain* 1980; 6:13-25.
15. Intracranial arteriovenous malformations: Stieg PE, Batjer HH, Samson D, Informa Healthcare USA Inc, NY, 2007
16. Fullerton HJ, Achrol AS, et al. Long term hemorrhage risk in children versus adults with brain arteriovenous malformations. *Stroke* 2005; 36:2099-2104.
17. Hofmeister C, Stapf C, Hartmann A et al. demographic, morphological and clinical characteristics of 1289 patients with brain arteriovenous malformations. *Stroke* 2000; 31:1307-1310.
18. Celli P, Ferrante L, Palma L, Cavedon G. Cerebral arteriovenous malformations in children. *Acta Neurochir (Wein)* 1984; 142:145-158.
19. Hamilton MG, Spetzler RF. The prospective application of a grading system for arteriovenous malformations. *Neurosurgery* 1994; 34:2-7.
20. Spetzler RF, Martin NA. A proposed grading system of arteriovenous malformations. *J Neurosurg* 1986; 65:476-483.
21. Drake C. Brain arteriovenous malformations. Considerations for and experience with surgical treatment in 166 cases. *Clin Neurosurg*. 1979; 26:145-208
22. Darsaut TE, Guzman R, Marcellus ML, et al. Management of pediatric intracranial arteriovenous malformations: experience with multimodality therapy. *Neurosurg*. 2011; 69:540-556
23. Heros RC, Korosue K, Diebold PS. Surgical excision of cerebral arteriovenous malformations; late results. *Neurosurg* 1990; 26:570-578.
24. Yes Hs, Tew JM, Gartner M. Seizure control after surgery on cerebral arteriovenous malformations. *J Neurosurg* 1993; 78:12-18.
25. Sanchez-Mejia RO, Chennupati SK, Gupta N et al. Superior outcomes in children compared with adults after microsurgical resection of brain arteriovenous malformations. *J Neurosurg* 2006; 105:82-87.
26. DiRocco C, Tamburrini G, Roolo M. Cerebral arteriovenous malformations in children. *Acta Neurochir (wein)* 2000; 142:145-158.
27. Meyer PG, Orliaguet GA, Zerah M, et al. Emergent management of deeply comatose children with acute rupture of cerebral arteriovenous malformations. *Cn J Anaesth* 2000; 47:758-766.