

Recurrent extraventricular anaplastic ependymoma with scalp metastasis

Amit Agrawal¹, K.V. Murali Mohan², Vissa Santhi³, Kishor V. Hegde⁴, Umamaheswara Reddy V.⁵

Narayana Medical College Hospital, Chinthareddypalem, Nellore, Andhra Pradesh (India)

¹Professor of Neurosurgery, Department of Neurosurgery

²Associate Professor of Pathology, Department of Pathology

³Professor of Pathology, Department of Pathology

⁴Professor of Radiology, Department of Radiology

⁵Assistant Professor of Radiology, Department of Radiology

Abstract

Extraneural metastasis from anaplastic ependymoma is uncommon. In a study from Memorial Sloan Kettering Cancer Center where the authors reviewed 81 ependymomas cases (between 1956 and 1989) there were only five (6.2%) cases had extraneural metastases. We present a case of anaplastic ependymoma with scalp metastasis and discuss the possible mechanism of spread. In majority most of the cases of metastatic extracranial ependymoma patients have underlying progressive intracranial disease. Although these patients receive standard treatment for the primary tumor (Gross total resection and radiotherapy) and the management options for recurrences includes re-excision, focal re-irradiation, stereotactic radiosurgery, or craniospinal radiotherapy for metastatic disease the long term outcome is not favorable.

Key words: Anaplastic ependymoma, scalp metastasis, brain tumors.

Introduction

Anaplastic ependymomas probably arises from radial glial cells of the ventricular zone and is a relatively uncommon tumor which have a propensity for local recurrence with rarer incidence of extraneural metastasis (the lungs, lymph nodes, pleura, mediastinum, liver, diaphragmatic muscle, and bone). (1-6) Scalp metastasis from anaplastic ependymoma is extremely rare. (5, 6) We present a case of anaplastic ependymoma with scalp metastasis and discuss the possible mechanism of spread.

Case report

45 year gentleman a case of recurrent left parietal anaplastic ependymoma who was operated on three occasions (First time in December 2010, 2nd time in June 2012 and 3rd time in April 2013) presented with multiple scalp swelling, headache and vomiting. Preciously the tumor was managed with near total resections and he received radiotherapy and chemotherapy after the previous

surgeries. He had residual right hemiparesis after at the second time of surgery which was pressing. There was no history of fever, loss of consciousness or seizures. His general and systemic examination was normal. Neurologically he was conscious, alert and oriented to time place and person. He had mild aphasia and grade 3/5 weakness of right upper and lower limbs. There was patchy loss of hair over scalp. There were multiple hard, non-tender nodules over the scalp and along the previous craniotomy incisions site (Figure 1). MRI brain showed extensive recurrence of the tumor. Post-contrast images showed that the tumor was extending along the trajectory of the incision and extending extracranially into the subgaleal plane (Figure 2).

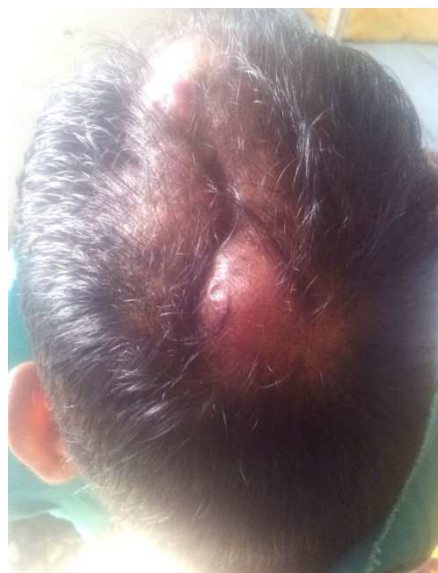

Figure 1 - Clinical photograph showing multiple scalp nodule near to the surgical incision site

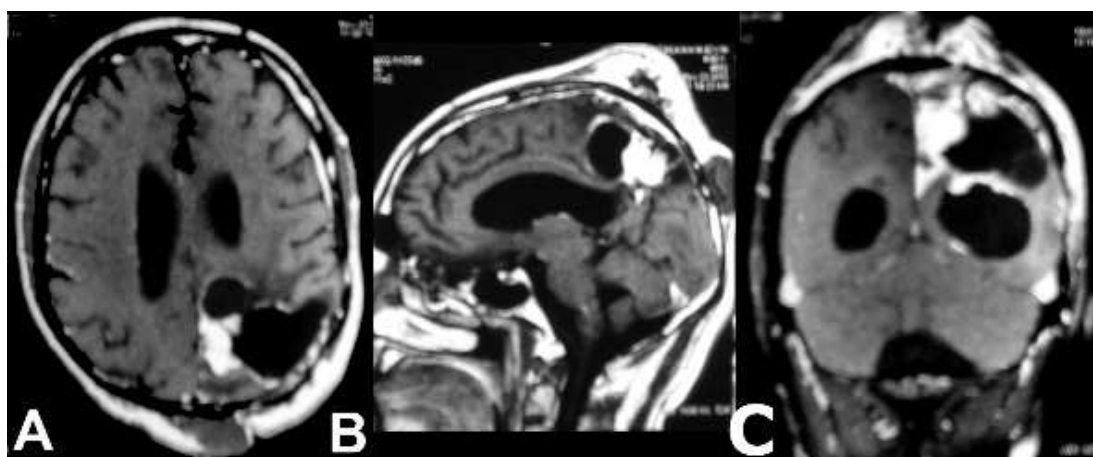


Figure 2 - Post contrast MRI T1W axial, sagittal and coronal images showing (A) recurrent tumor cyst in left parieto-occipital region with enhancing nodule, (B) in addition to the enhancing nodules in the cyst cavity there is large enhancing lesion in scalp and (C) multiple enhancing lesion are better visualized on coronal image

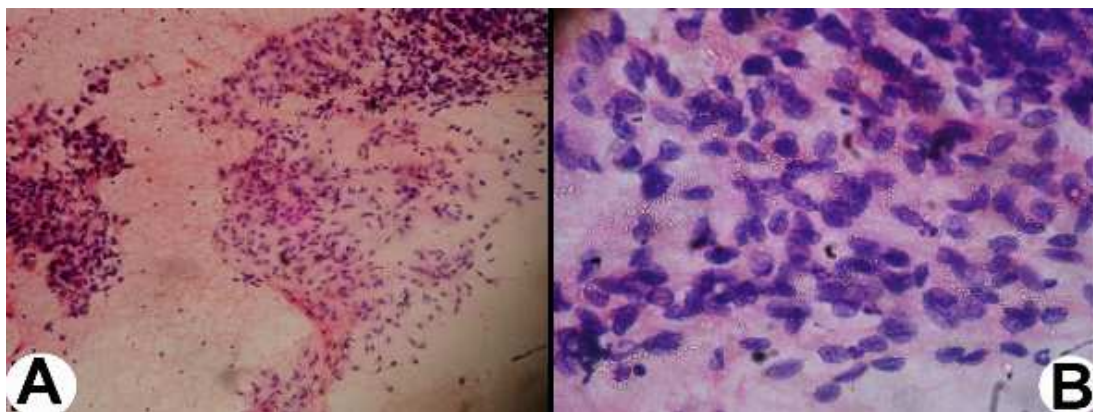


Figure 3 - (A) Sheets of tumor cells having round to oval nuclei with moderate amount of cytoplasm in the hemorrhagic background (H&E,X100) and (B) Tumor cells having round to oval nuclei with most of them showing nuclear grooving. Cells have moderate amount of cytoplasm and indistinct cell borders (H&E, X400)

The patient underwent fine needle aspiration cytology (FNAC) of the scalp lesions which showed sheets of tumor cells having round to oval nuclei with moderate amount of cytoplasm in the hemorrhagic background, most of them showing nuclear grooving and cells had moderate amount of cytoplasm and indistinct cell borders (Figure 3).

Discussion

In a study from Memorial Sloan Kettering Cancer Center where the authors reviewed 81 ependymomas cases (between 1956 and 1989) there were only five (6.2%) cases had extraneural metastases. (4) In other reports articles most of the cases of metastatic extracranial ependymoma also had underlying progressive intracranial disease (resulting in poor outcome). (4, 5, 7) Because of their proximity to the ventricular spaces ependymoma are prone to leptomeningeal dissemination. (5) It has been hypothesized that craniotomy and shunt placement disrupts

the blood-brain barrier and promotes vascular seeding to distant sites in some but not all cases. (4, 8, 9) As was seen in present case proximity of the recurrent tumor to the surgical site suggests surgical seeding and scalp metastasis. (5) All the patients received standard treatment for the primary tumor (Gross total resection and radiotherapy) and the management of recurrences included re-excision, focal re-irradiation, stereotactic radiosurgery, or craniospinal radiotherapy for metastatic disease with good survival rates (5-year survival in up to 50% of patients). (3, 6, 10, 11) Although chemotherapy has been found to delay progression in some cases and provides palliative relief, but has not been shown to increase survival. (11-14)

Correspondence:

Dr. Amit Agrawal (MCh)
Professor, Department of neurosurgery
Narayana Medical College Hospital
Chinthareddypalem
Nellore-524003

Andhra Pradesh (India)
 Email- dramitagrawal@gmail.com
 Mobile- +91 8096410032

References

1. Fischer C, Haque SS, Huse JT, et al. Extraneural ependymoma: distant bone, lung, liver, and lymph node metastases following bevacizumab. *Pediatric blood & cancer* 2013;60:143-145.
2. Kinoshita M, Izumoto S, Kagawa N, Hashimoto N, Maruno M, Yoshimine T. Long-term control of recurrent anaplastic ependymoma with extracranial metastasis: importance of multiple surgery and stereotactic radiosurgery procedures--case report. *Neurologia medico-chirurgica* 2004;44:669-673.
3. Donepudi SK, Tennant PA, Samant S. Anaplastic Ependymoma Metastatic to the Neck. *LARYNGOSCOPE* 2009;119:S66-S66.
4. Newton HB, Henson J, Walker RW. Extraneural metastases in ependymoma. *Journal of neuro-oncology* 1992;14:135-142.
5. Chao MM, Packer RJ, Mysers JS, Rood BR. Isolated extracranial recurrence of anaplastic ependymoma. *Pediatric blood & cancer* 2011;56:317-318.
6. Davis MJ, Hasan F, Weinreb I, Wallace MC, Kiehl TR. Extraventricular anaplastic ependymoma with metastasis to scalp and neck. *Journal of neuro-oncology* 2011;104:599-604.
7. Ferracini R, Manetto V, Poletti V, Giangasparo F. A cerebral ependymoma with extracranial metastases. *Tumori* 1984;70:389-392.
8. Duffner PK, Cohen ME. Extraneural metastases in childhood brain tumors. *Annals of neurology* 1981;10:261-265.
9. Rubinstein LJ. Development of extracranial metastases from a malignant astrocytoma in the absence of previous craniotomy. Case report. *Journal of neurosurgery* 1967;26:542-547.
10. Merchant TE, Boop FA, Kun LE, Sanford RA. A retrospective study of surgery and reirradiation for recurrent ependymoma. *International journal of radiation oncology, biology, physics* 2008;71:87-97.
11. Zacharoulis S, Moreno L. Ependymoma: an update. *Journal of child neurology* 2009;24:1431-1438.
12. Bouffet E, Capra M, Bartels U. Salvage chemotherapy for metastatic and recurrent ependymoma of childhood. *Child's nervous system : ChNS : official journal of the International Society for Pediatric Neurosurgery* 2009;25:1293-1301.
13. Messahel B, Ashley S, Saran F, et al. Relapsed intracranial ependymoma in children in the UK: patterns of relapse, survival and therapeutic outcome. *European journal of cancer (Oxford, England : 1990)* 2009;45:1815-1823.
14. Reni M, Gatta G, Mazza E, Vecht C. Ependymoma. *Critical reviews in oncology/hematology* 2007;63:81-89.