

Giant Cavernous Malformation in the child. Case presentation

Rajendra Shrestha¹, Reeka Pradhan², You Chao¹

¹Department of neurosurgery, West China Hospital, Sichuan University

²International Medical School, Tianjin Medical University, China

Abstract

Cerebral cavernous malformations (CCMs) are rare lesions that occurs 5 to 13% of all intracranial vascular malformations, develop in 0.02-0.13% of the population. Extra axial cavernous Malformations are even more rare and estimated to be 0.4 to 2% of all the intra cranial cavernous hemangiomas. CCMs that are greater than six cm in size have been described as “giant” in the literature. We report ten year-old male who presented with right lower limb weakness and recurrent seizure disorder. The computed tomography and the magnetic resonance imaging scans demonstrated giant vascular malformation (10CM x 8CM x 6CM) on left parietal lobe. Surgical excision of a giant cavernous malformation (GCM) was performed with good surgical skills. To the best of our knowledge, such large GCMs are extremely rare lesion seen in neurosurgical practice.

Key words: cavernous malformation, cavernoma, child, surgery

Introduction

The cavernous malformation (CM), also known as cavernous hemangioma, cavernoma, angioma and cavernous angioma, a well circumscribed, benign vascular hamartoma consisting of irregular thick and thin walled sinusoidal vascular channels located within the brain but

lacking intervening neural parenchyma, large feeding arteries or large draining veins. Even though there are many names for this phenomenon in world literature, most of these lesion are small and only become clinically significant when they induce seizures, hemorrhage or neurological deficit (2, 7). These lesions have been diagnosed more frequently in the pediatric population. We report a case of giant cavernous malformation (GCMs) (10CM x 8CM x 6CM) associated with seizure and hemiparesis which, according to the best of our knowledge, has not been documented previously in the literature.

Case Report

A ten year-old-male presented with right lower limb weakness for five years. He was diagnosed with a case of vascular malformation in local hospital a couple of years back but was denied surgical intervention due to fearfulness. He had developed recurrent seizure over the course of two months and referred to our hospital for further management. On admission, patient vitals and parameter were within normal. Neurological examination revealed that his right lower leg had grade 4 Medical Research Council (MRC). His upper limbs were normal. Bladder and bowel function were not affected. Computed tomography (CT) scan revealed mixed density lesion on left parietal region (figure 2A).

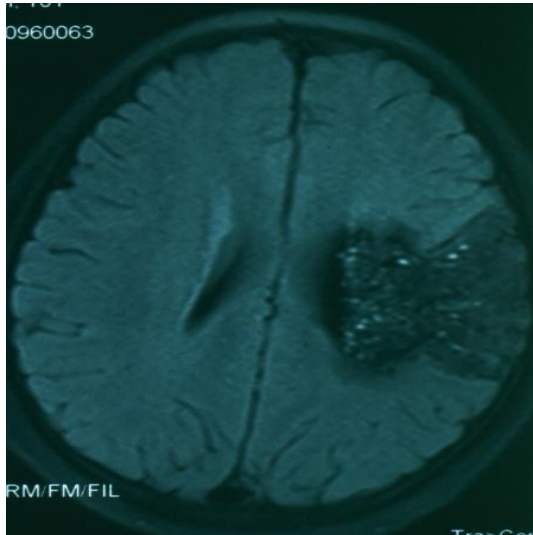
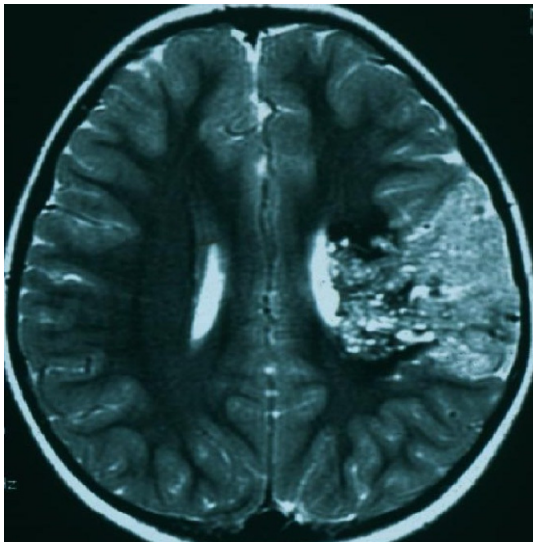
**A****B**

Figure 1 Axial image T1 (A) and T2 (B) - weighted MRI showing GCMs a mixed signal mass with areas of T2 hypo-intensities suggestive of haemosidren and/or calcification

The magnetic resonance imaging (MRI) scans demonstrated vascular malformation on left parietal lobe (figure 1A, B). DSA did not illustrate any lesion (figure 2B). After admission, left temporo-parietal craniotomy was done and it was found that the dura was not tense, with no signs of a high intracranial pressure as there was no outward brain swelling.

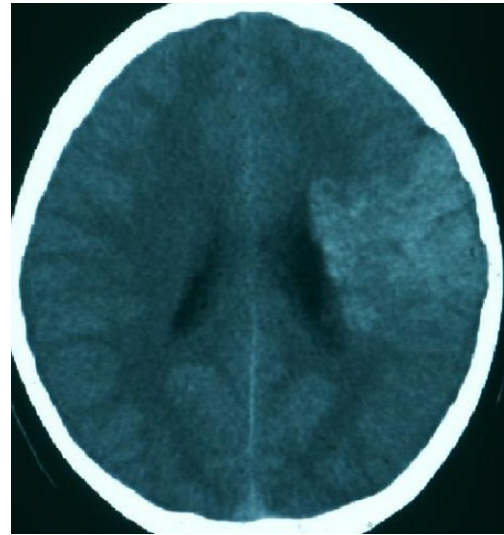
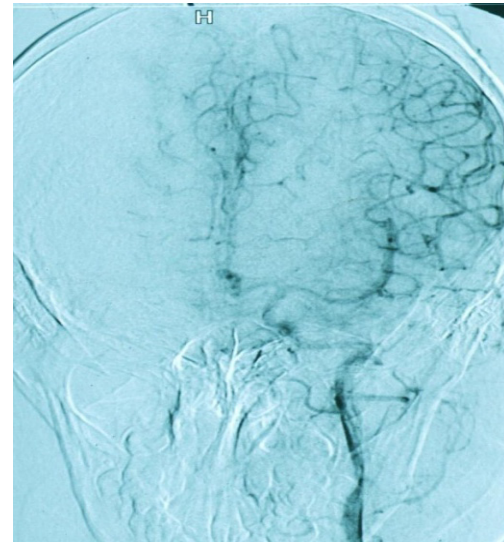
**A****B**

Figure 2 (A) Computed tomography (CT) scanning showing a mixed density lesion in the left parieto-temporal region (B) Cerebral Angiogram of the left carotid artery, no evidence of lesion

After opening dura, 10cm x 8cm x cm blue-purple colored mulberry-like lesion tumor down to reach the lateral ventricle was revealed (Figure 4A). Tumors and brain tissue along the border excised and maintained hemostasis carefully. A complete resection tumor was performed without complication and sent for histopathological examination. Post

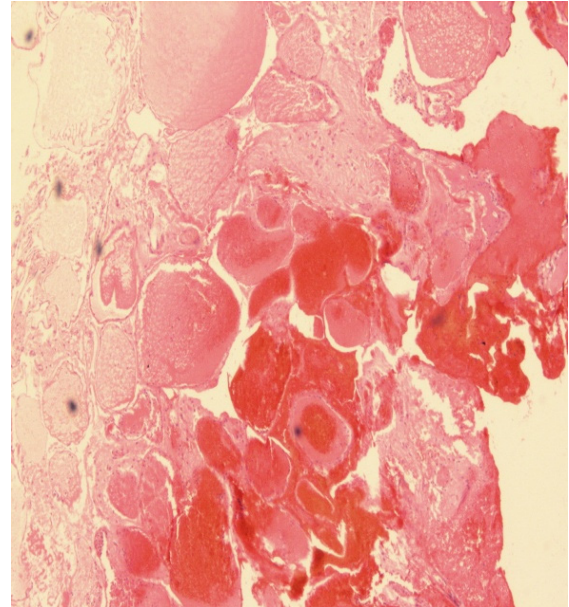
operative event was uneventful and HPE revealed Cavernous malformation (figure 4B). And patient transferred to rehabilitation centre. Patient did not notice seizure and also good recover in his right lower limb after one month of follow up CT scan (figure 3).

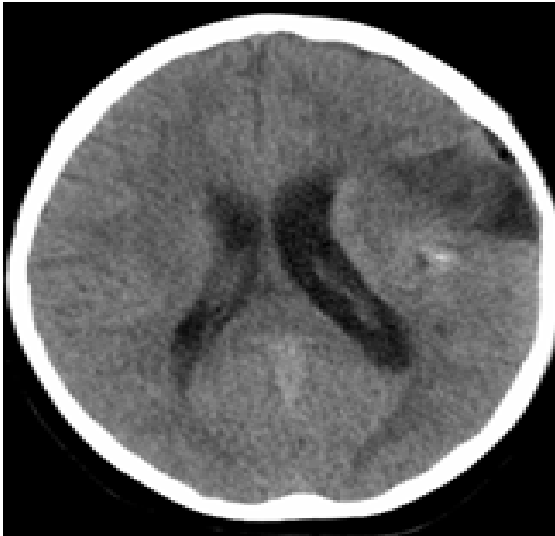
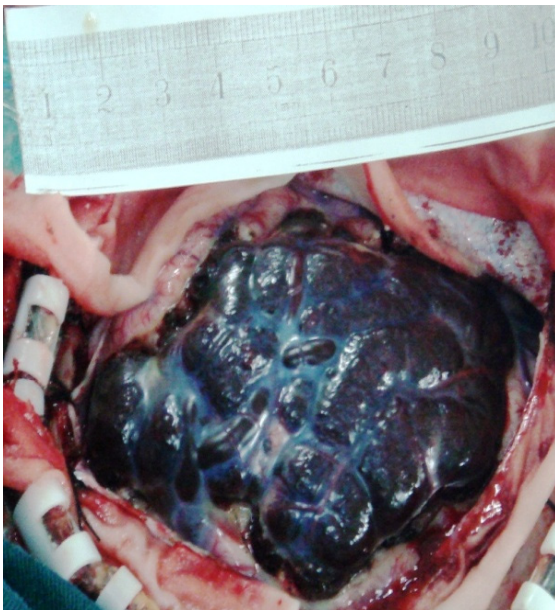
Figure 3 After one month of follow-up, plain CT scan showing complete excision of the giant CCM



A



B

Figure 4 (A) Per-operative picture showing GCMs (10cm x 8cm x 6cm **(B)** Histopathological examination of the GCMs (H&E stain) showing thin walled vascular channels and various organizing thrombi within the cavernous vascular spaces (H&E, ×50)

Discussion

The first comprehensive studies of CMs were by Cushing and Bailey (1928) and Dandy (1928) who described a few cases of epilepsy in which large cavernoma were found during exploratory operation, usually for suspected tumour. These lesion natural history and management are being discussed since 1980 in the English literature 8. To date, only a small number of cases have been reported. CMs comprise 5-13% of CNS vascular malformation; develop in 0.02-0.13% of the population. CMs are found throughout the central nervous system in which 48-86% are supratentorial, 4-35% brainstem, 5-10% basal ganglia. They can occur in two types: a sporadic and hereditary. The latter may be transmitted as an autosomal dominant trait which is characterized by multiple lesions. However, the former one, sporadic, is more

common as single lesion (7). CMs vary in size from a few millimeters to a few centimeters. According to the Lawton et al. CMs can be defined as giant CMs when cavernoma with diameter greater than six cm (5). They are rare in the literatures as we couldn't find such a big size in literature till date.

Differential diagnoses include meningioma, arteriovenous malformation, metastasis, infection, and other tumors. The presence of large amounts of hemoglobin degradation products such as methemoglobin, hemosiderin and ferritin around the malformation, seen both pathologically and radiologically with MRI, provides evidence of multiple previous episodes of microscopic hemorrhage (3). CT often reveals a hyperdense lesion that enhances little or not at all with contrast administration. These lesions are not visible on angiography and represent the largest percentage of angiographically occult vascular malformations. They usually have little to none of either surrounding edema or mass effect. MRI is the diagnostic tool of choice owing to its sensitivity and specificity for these lesions. (1, 9, 10, 13)

The clinical presentations of these lesions are variable ranging from headaches to fatal hemorrhage. Usual size lesions are usually revealed as incidental findings during investigations for unrelated symptoms. The usual symptoms of a cavernoma are seizure, acute onset of a severe headache, progressive neurologic deficit, hemorrhage and hydrocephalus (7, 9, 12). Our case is more interesting as such giant CMs not yet present in literature. In our best knowledge, the growth mechanism for these lesions acute or chronic massive hemorrhage, intraluminal thrombosis with recanalization and organization, angiogenesis proliferation with new

capillaries, immunohistochemical demonstrated proliferation, nidus growth by new caverns formation, vascular smooth muscle proliferation (3, 4, 8).

The treatment of CM still represents a challenge which lesions and in what patients an operation is indicated, because the natural history of these lesions is relatively poorly understood. Surgical extirpation of such a lesion is relatively straightforward because there is usually a gliotic plane with evidence of hemosiderin from old hemorrhage around it. Bleeding is much less of a problem with cavernous malformations than with arteriovenous malformations even GCMs, because there are never large feeding vessels or draining veins. Gamma knife surgery shows some promise role by reducing the size of the lesion especially in locations like deep in the brain, brainstem and basal ganglia⁶. Microsurgical resection is the state of the art treatment in all patients whose CM is symptomatic, isolated, and localised in non-eloquent regions of the brain (3, 4, 11, 12). Our rare case of GCM was also completely removed by microsurgical treatment with rewarding outcome.

Conclusion

Microsurgical resection is ideal treatment since the cavernoma is well circumscribed and lacks attachment to the surrounding brain. However, prompt diagnosis and treatment of large intracranial tumors require sound knowledge of neuroanatomy, neuroradiology and good surgical skills.

References

1. Becker DH, Townsend JJ, Kramer RA, Newton TH: Occult cerebrovascular malformations. A series of 18 histologically verified cases with negative angiography. *Brain* 102:249–287, 1979.
2. Delcurling Jr O, Kelly Jr DL, Elster AD, Craven TE:

An analysis of the natural history of cavernous angiomas. *J Neurosurg* 1991, 75: 702-8.

3. Dong Wuk Son, Sang Weon Lee, Chang Hwa Choi: Giant Cavernous Malformation: A Case Report and Review of the Literature; *J Korean Neurosurg Soc* 43: 198-200, 2008.

4. Kim DS, Park YG, Choi JU, Chung SS, Lee KC: An analysis of the natural history of cavernous malformations. *Surg Neurol* 48 : 9-17, discussion 17-18, 1997.

5. Lawton MT, Vates GE, Quinones-Hinojosa A, McDonald WC, Marchuk DA, Young WL: Giant infiltrative cavernous malformation: clinical presentation, intervention, and genetic analysis: case report. *Neurosurgery* 55 : 979-980, 2004.

6. Liu KD, Chung WY, Wu HM, Shiao CY, Wang LW, Guo WY, Pan DH: Gamma knife surgery for cavernous hemangiomas: An analysis of 125 patients. *J Neurosurg* 102 [Suppl]:81 - 86, 2005.

7. Mark S. Greenberg (2010): *Handbook of Neurosurgery* Seventh edition; New York: Thieme, Page 1106-1107.

8. M. Gorgan, Angela Neacsu, Narcisa Bucur, V. Pruna et. Al: Update on the natural history of infratentorial

cavernous malformations; *Romanian Neurosurgery* (2011) XVIII 4.

9. Ratul Raychaudhuri, H. Huntington Batjer, Issam A. Awad: Intracranial cavernous angioma: a practical review of clinical and biological aspects; *Surgical Neurology* 63 (2005) 319 - 328.

10. Rigamonti D, Drayer BP, Johnson PC, Hadley MN, Zabramski J, Spetzler RF. The MRI appearance of cavernous malformations (angiomas). *J Neurosurg* 1987;67:518 - 24.

11. Samii M, Eghbal R, Carvalho GA, Matthies C: Surgical management of brainstem cavernomas. *J Neurosurg* 95:825 - 832, 2001.

12. S. Bigi, A. Capone Mori, M. Steinlin, L. Remonda, H. Landolt, E. Boltshauser, Cavernous malformations of the central nervous system in children: presentation, treatment and outcome of 20 cases: *European journal of paediatric neurology* 15 (2011) 109 - 116.

13. Tomlinson FH, Houser OW, Scheithauer BW, Sundt Jr TM, Okazaki H, Parisi JE. Angiographically occult vascular malformations: a correlative study of features on magnetic resonance imaging and histological examination. *Neurosurgery* 1994;34:792 - 9 [discussion 799-800].