

Modern methods of endovascular approach to cerebral arteriovenous malformations

N.C. Florestean¹, A.V. Ciurea²

¹PhD. Student UMF “Carol Davila”, Bucharest, Emergency Department, “Bagdasar Arseni” Clinical Emergency Hospital;

²Neurosurgical Clinic, “Bagdasar Arseni” Clinical Emergency Hospital, Bucharest, Romania

Abstract

The article is a review of major historical events in the development of the methods of endovascular approach of arteriovenous malformations (AVM) starting with the first cerebral angiography performed on a dog in 1926, Serbinenko's embolization techniques of cerebral vascular lesions using detachable balloons in 1974, ending with January 1991 when the first embolization with GDC (Guglielmi detachable coils) was done on a brain aneurysm. It's considered that there are approximately 1,100 patients diagnosed with cerebral arteriovenous malformation treated with GDC each month.

Key words: endovascular, embolization, arteriovenous malformations, detachable coils.

Immediately after the discovery of X rays in 1895, in Vienna, Hascheck and Lindenthal visualized blood vessels by injecting an opaque substance into dead bodies (1). In 1926, Moniz (2) performed the first angiography in dogs by injecting a solution of lithium Bromide and Strontium obtaining the first image of cerebral circulation.

The first electrothermic thrombosis of a cerebral aneurysm was achieved by a

transorbital insertion of a silver wire introduced through a special needle, the wire was heated to 80 ° C for 40 seconds.

In 1960, Mullan and his colleagues (3) studied different methods to induce aneurism thrombosis. In a preliminary study, they achieved a complete thrombosis in dogs by inserting small electrodes directly into the vessel wall and applying an electric current. Subsequently, these authors have reported the treatment of 10 cerebral aneurysms by producing electro thrombosis. Under fluoroscopic guidance, thrombosis was initiated by passing an electric current through a needle electrode inserted into the aneurysm.

Gallagher described his method called 'pilojection' which consists in introducing horse and dog hair in the aneurysmal sac (4).

Luessenhop and Velasques, in the early 1960s, showed that navigation and catheterization through the cerebral vessels would be easier and without complications if there were used approximately equal pressures to the systolic blood pressure (5).

In 1966, for navigation in cerebral arteries Frei (6) used special catheters which had micro magnets inserted at their tip and which could be guided by an external magnetic field.

Yasargil, who had experience both in cerebral angiography and in stereotactic therapy tried to inject iron particles in the cerebral vessels and to guide them towards by using stereotactic magnets. This attempt failed due to technical reasons. A student of Yasargil, John Alksne, used both iron particles and a combination of acrylic mixture and micro particles of iron (7). Hilal in 1974 also used the magnetic directed catheters (8).

The first stage of endovascular treatment of cerebral AVM was to occlude the feeder vessel to the cerebral AVM (Figure 1). This treatment was successful in some cases (in the occlusion of internal carotid artery-ICA- with detachable balloons just proximal to the AVM or by occlusion of both vertebral arteries (VA) in post cranial fossa AVMs). These occlusions are preceded by vascular occlusion tests.

Cerebral artery occlusion test with non detachable balloons aims to assess the tolerance of these vessels to that occlusion. The goal is to treat huge AVMs-C that can not be selectively obliterated. It also evaluates the arterial supplantation provided by Willis polygon (ICA test occlusion). An intravenous heparin bolus injection of 5000 IU is administered at the beginning of the test. Two arterial ways are used: either the femoral way or the carotid way of the AVM-C side and a femoral way to study the supplantations (Figure 2).

Hemispheric cerebral blood flow on each side is measured by the ICA injection of isotope (xenon 133). Middle cerebral artery (MCA) blood flow velocity is also measured bilaterally with a transcranial Doppler. These data once obtained, the balloon is inserted in the intracavernous segment of ICA. Then the balloon is inflated in order to obtain ICA occlusion. This procedure should not exceed 30 minutes.

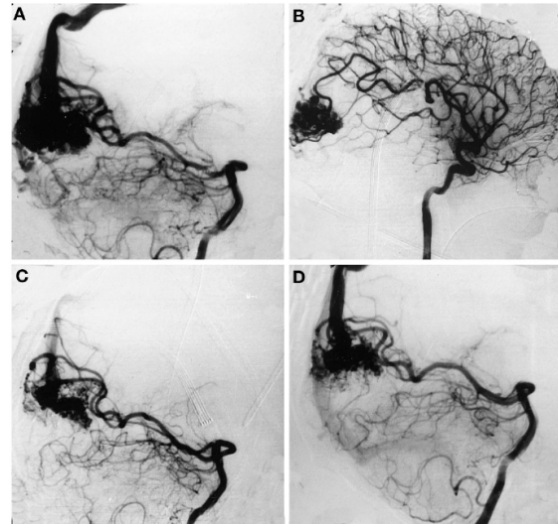


Figure 1 AVM-C occipital (A, B), partial embolization (C) - control after two months (D) (15)

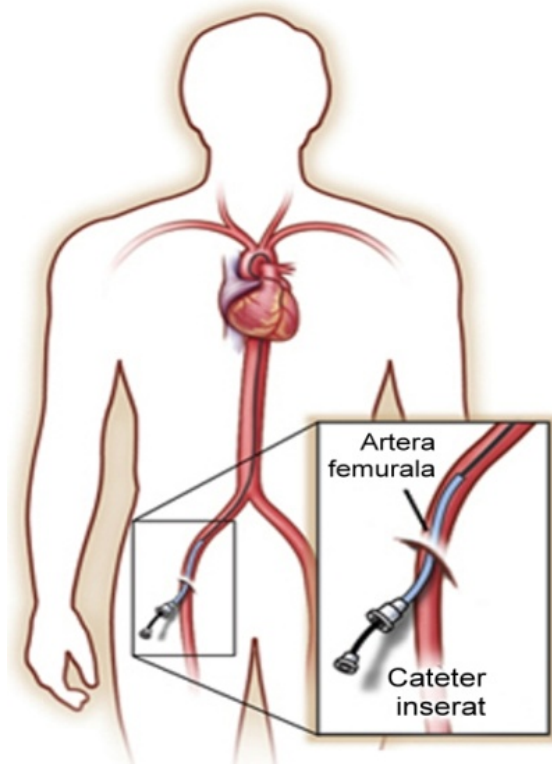


Figure 2 The femoral approach

During occlusion the following parameters should be observed:

- clinical tolerance (sensory, kinaesthetic and superior functions);
- Doppler examination (Figure 3) is performed for three or four times within 30 minutes (a bigger asymmetry than 25% between the two hemispheres in MCA blood flow velocity is not allowed);
- blood flow is measured at 2, 10 and 20 minutes by xenon 133 injection in controlateral ICA occlusion;
- the study of arterial supplantations through angiography.

If the mentioned criteria are not fulfilled, the test is rendered negative. The balloon is deflated and a temporo-Sylvian anastomosis is performed. The interval between test repeating and performing temporo-Sylviene anastomosis is between 15 days and 1 month.

The test with diamox (acetazolamide) can be used in order to study the cerebral circulation, and especially the collateral circulation. The acetazolamide is a carbonic anhydrase inhibitor that inhibits the conversion of carbonic acid to CO₂ and H₂O in the brain causing acidosis and decreased pH. These transformations lead to vasodilatation, but the acetazolamide does not cause low general blood pressure.

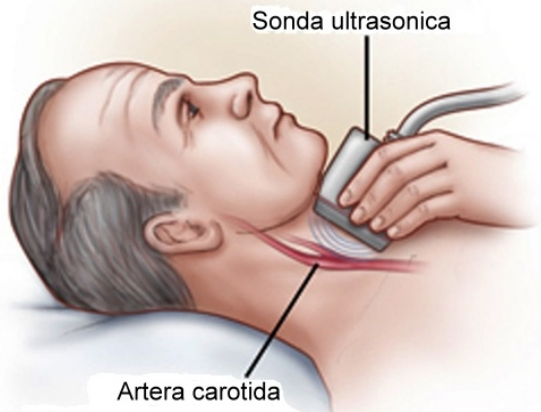


Figure 3 Carotid Doppler- ECHO

The test was initially used to assess cerebral circulation in patients with carotid stenosis for revascularization procedures. Tomography with 133 Xe is performed in order to obtain the basic cerebral blood flow (CBF). Then 1 mg of diamox is injected intravenously and tomography is repeated after 15-20 minutes. The two CT scans are compared. Response to diamox varies from one patient to another. Patients with normal collateral circulation have a normal response to acetazolamide without blood redistribution. This test can be used to study the brain areas surrounding the AVM-C. (15)

ALLOCK maneuver is also performed. It consists of injecting the VA while ICA is being occluded in turn; the size of posterior communicating artery is observed (if it is > 1mm in diameter; bilateral VA occlusion is possible). A study by Fox in 1987 (9) performed in 68 patients, showed that only 13.2% had transient ischemic attacks and there was only a case of stroke.

The second stage of development in endovascular treatment of cerebral vascular lesions is the selective occlusion of cerebral AVMs. In 1974, Serbinenko (10) published in the Journal of Neurosurgery the endovascular treatment method with detachable balloons. The idea of using balloons in endovascular treatment came after observing children who were holding helium-filled balloons in the Red Square in Moscow during the May 1 demonstration. Serbinenko used latex balloons which were obtained by melting rubber bands (11). During this period, endovascular treatment method for cerebral vascular lesions with detachable balloons has become the standard method. In time, the main disadvantages of this method became apparent. Thus, hyper selective

catheterization of cerebral vessels is difficult due to the impossibility of using guide wire. The balloon can not take the irregular shape of an ordinary aneurysmal sac. By using detachable balloons for occlusion of cerebral aneurysms there occur very often complications consisting of aneurysmal rupture and their recanalization (water-hammer effect). Detachable balloons are currently used in the occlusion of vessels with giant, fusiform aneurysms.

Hilal and Solomon (12) introduced pushable platinum coils in AVM-C (push-them-out-the-end). The big disadvantage of these coils is that they can not be retrieved.

While introducing electric current through an electrode in an experimental aneurysm in 1980, Guido Guglielmi observed its accidental detachment. Together with Ivan Sepetka, engineer for Target Therapeutics, they built GDC (Guglielmi detachable coils). In March 1990, at UCLA (University of Columbia Los Angeles), after the failure of a detachable balloon occlusion of a carotid-cavernous fistula caused by a ruptured cavernous sinus aneurysm, two venous GDC were used for the first time, which led to permanent occlusion of the fistula. In the same place, at UCLA, in January 1991 (13) the first GDC embolization of cerebral aneurysm was performed, and in 1995 United States Food and Drug Administration approved the use of GDC. By 2000, over 60,000 worldwide patients with cerebral aneurysms and cerebral arteriovenous malformations were treated with GDC and it is assumed that approximately 1,100 patients are treated with GDC every month (Figure 4).

Future development of endovascular treatment of cerebral AVM will probably know two ways of evolution. The first way would be to develop imaging techniques, especially the endoluminal ones (endoscopy, angiography) with real-time streaming. The second way of development would be to find an ideal embolization agent (14) with the following qualities: it must adjust itself to AVM-C shape, not affect the nutritional vessel, absorb the energy transmitted to AVM-C walls through pulses and prevent the further growth of AVM-C (Figure 5).

Study

In the period January 1, 2000 - December 31, 2009 a total of 426 patients with cerebral arteriovenous malformations [AVM] were hospitalized in the Neurosurgery I Clinic of the "Bagdasar - Arseni" Emergency Hospital. All the cases were investigated in the clinic with a view to setting up a good quality positive diagnosis by brain CT scan with contrast substance or MRI with brain angio-MRI.

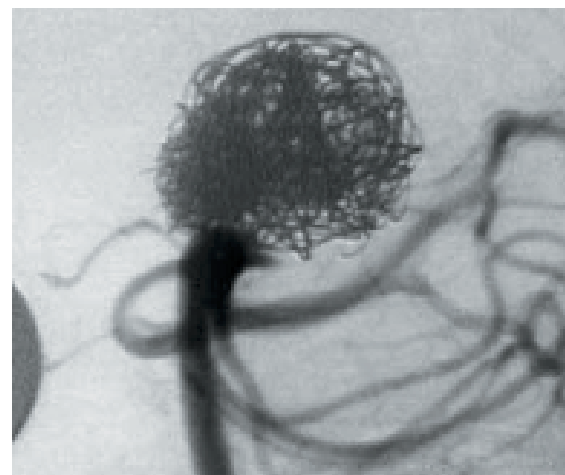


Figure 4 embolization with GDC (14)

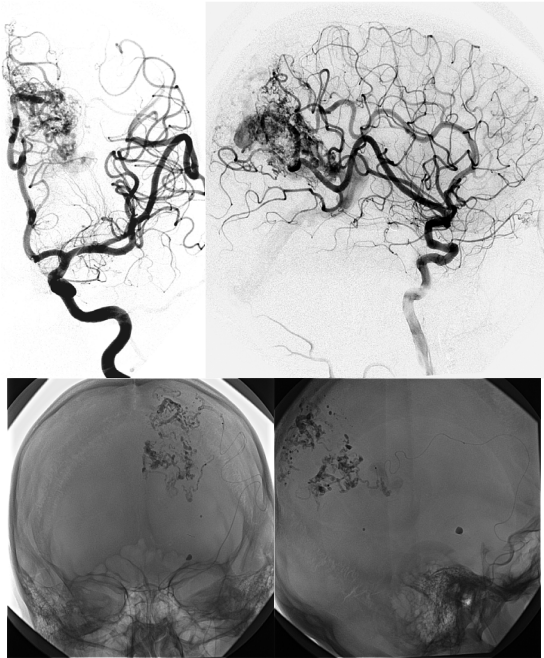


Figure 5 left parietal AVM-C multistage cyanoacrylate embolization (16)

In order to evaluate the angioarchitecture and the hemodynamics of the nidus, and to determine the opportunity of the surgical, endovascular treatment indication by embolization or Gamma-Knife radiosurgery of the AVMs, all the patients were investigated by carotid bilateral and vertebral digital subtraction angiography (DSA) (the so-called "four vessels angiography"). The patients diagnosed with cavernous vascular malformation following CT investigation and brain MRI, undertook cerebral angiography only in the case of suspected association of cavernoma with a vascular malformation.

We excluded from the study the cases with super-acute evolution (massive intraparenchymatous brain hemorrhages, intraventricular hemorrhages or massive hemorrhages of the brain trunk) in which the time elapsed from admission to the death only allowed for urgent resuscitation

and hemodynamic stabilization to be applied, and did not allowed one of the therapy methods specific for vascular malformation to be applied.

Because one of the declared purposes of the study is to establish the therapeutic behavior and to determine the efficiency of the multimodal treatment of cerebral arterio - venous malformation, we only kept in the study group the patients in whom at least one of the established active treatment methods were applied: micro-surgery treatment, endovascular treatment or Gamma-knife or the more reserved attitude of observation and surveillance of the lesions in asymptomatic or oligosymptomatic selected cases.

Thus, the criteria of inclusion and the exclusion in the study were established:

Inclusion criteria:

- clinical and paraclinical diagnosis (CT and/or brain MRI) of cerebral arteriovenous malformation;

- assessment of angioarchitecture and hemodynamics by carotid bilateral and vertebral digital subtraction angiography (DSA);

- hospitalization in the period 01.01.2000 – 31.12.2009.

Exclusion criteria:

- the patients in whom, irrespective of the reasons (death in short time of admission, discharge upon demand or refusal of the treatment etc.), none of the active treatment methods was applied: micro-surgery treatment, endovascular treatment or Gamma-knife treatment, or passive treatment: observation;

- the patients in whom the post-procedural follow-up period was less than 6 months;

- the patients who never appeared in the post-procedural control.

Following the application of the above criteria, a group of 375 patients who meet all the six inclusion and exclusion criteria resulted.

Out of the 375 patients, in comparison to the 246 patients who undertook surgery, the remaining 129 patients benefited of multimodal treatment or other alternative therapy as follows:

- 46 patients (35.66%) benefited of stereotactic radiosurgery;
- 53 patients (41.08%) benefited of embolization;
- 19 patients (14.73%) were followed up clinically and paraclinically;
- 11 patients (8.53%) benefited of multimodal treatment, out of which
 - 4 patients (3.1%) received surgery and then radiotherapy by Gamma-Knife for the residual nidus;
 - 5 patients (3.8%) were treated by embolization in the first phase and then they were irradiated by stereotactic method;
 - 2 patients (1.5%) needed a complex, sequential treatment: embolization -

surgery - Gamma-Knife or surgery - embolization - Gamma-Knife. (Figure 6)

We divided the study period in two: the patients treated with complementary therapies before putting into operation of the Centre of Excellence in Neurosurgery of "Bagdasar - Arseni" Emergency Hospital and the afterward period. Thus, we have obtained excellent results for the patients treated before and after the opening of the Center as follows:

- out of all the 57 cases treated by stereotactic radiosurgery 5 patients benefited in the period January 2000 - October 2004 (in clinics abroad), and the remaining 52 patients were treated in our hospital;
- out of the 60 patients treated by embolization, in the Neurosurgery I clinic, there were sent to clinics abroad 9 cases, and the remaining 51 patients were treated by embolization with coils or particles with Glubran within the Center of Excellence in Neurosurgery within our hospital.

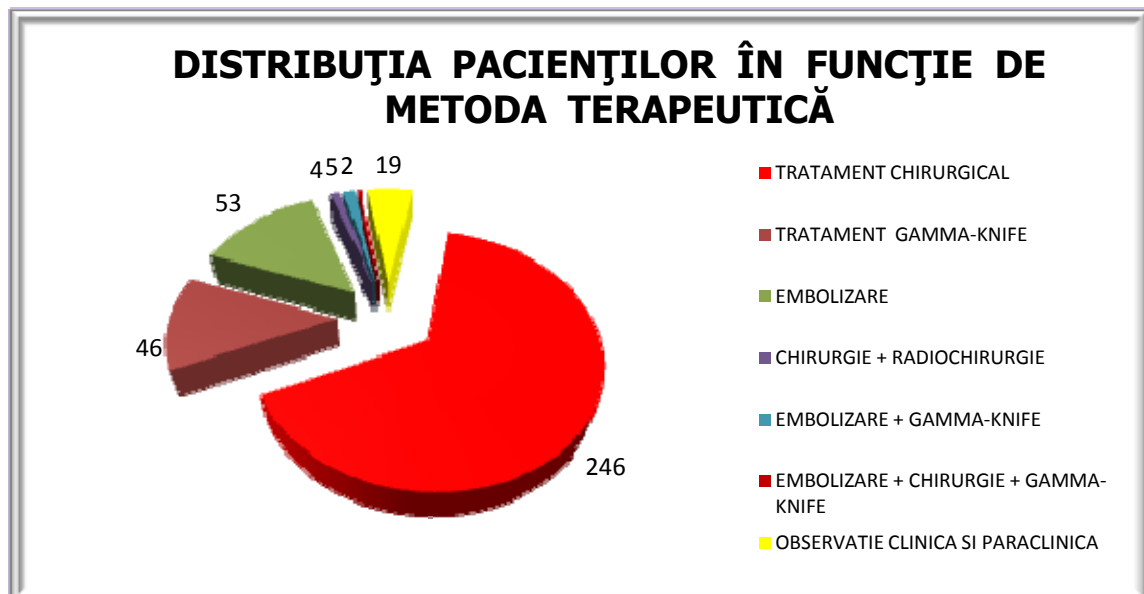


Figure 6

So that we have a rate of 8.77% of patients who were treated by stereotactic radiosurgery method were sent to for treatment to clinics abroad, in the first period of 58 months, and 91.23% of the patients treated in the Center of Neurosurgery within our hospital in 62 months, in the second period.

From among the patients treated in the Neurosurgery Clinic I of the hospital by the method of embolization of the arteries that nourish the cerebral arteriovenous malformations we notice that about 15% of patients were treated abroad, as compared with the remaining 85% of the cases treated in our hospital, in the same periods of time.

We have a mortality of 5.84% with a morbidity of 41.6% in the first phase of the study (January 2000 - October 2004) and in the second phase (November 2004 - December 2009) we have a mortality 3.9% with a mortality of 21.8%.

Clinical Case

The patient D.C., aged 21 years, appeared in 2003 in our clinic with headache and commemorative crises of loss of conscience with onset about six months ago, for additional specialty investigations.

Brain CT scan reveals paraventricular space replacement process in the left occipital horn that comes to contrast upon administration, without other cerebro-ventricular tomodensitometric changes that raises the suspicion of a vascular malformation (Figure 7).

Decision is made to perform a "4 vessels" cerebral angiography, which shows a left parietal arterio-venous malformation with nidus of about 5 cm with multiple artery afferences from the left pericallous artery (which shows increased caliber due to flow rate arteriopathy), left posterior cerebral artery (also this with an increased caliber),

left parietal-occipital artery, without other intranidal changes. The superficial venous drainage is made in the parietal portion of the SSS by a main pedicle represented by a cortical sinuous and tortuous dilated vein and by 2-3 secondary pedicles represented by 2-3 cortical veins with normal caliber, and the deep venous drainage is made in the right sinus via Galen's ampoule through a very dilated sinuous and tortuous vein. The malformation also injects itself from right ICA through a pedicle from the right anterior communicating artery and it shows a minimum displacement to the right of the median axis of the vascular tree (Figure 8).

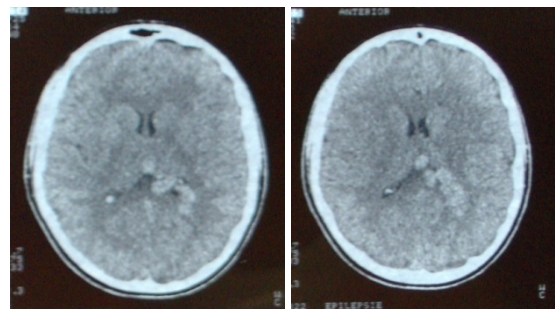


Figure 7 Tomographic aspect of a left parietal-occipital cerebral arteriovenous malformation

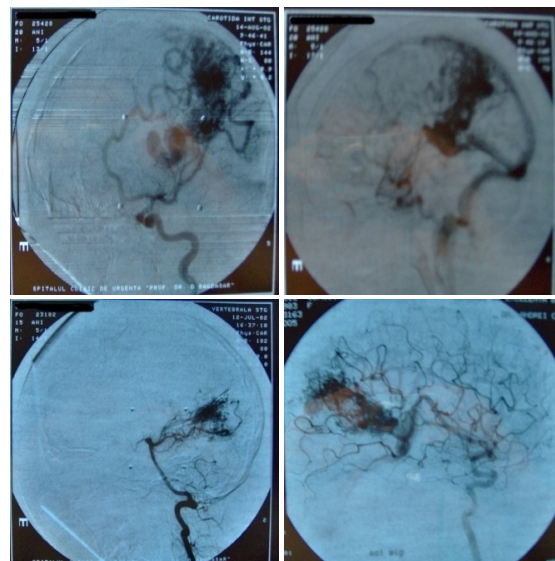


Figure 8 Angiographic aspect of left parietal-occipital cerebral AVM

The diagnosis of Martin-Spetzler left parietal-occipital arterial-venous malformation grade IV is put, due to its location in an eloquent area, the size of the nidus and due to the superficial and deep complex drainage.

Due to the major risks presented by the neurosurgical intervention, the assessment of the malformation is decided, with a view to embolizing it.

In February 2004 the first embolization is practiced with bioactive coils in a clinic abroad (Interballcan Medical Center in Salonio-Greece) (Figure 9).

In February, May and November 2005 the multi-stadialization of the embolization with Glubran particles is continued in the Center of Excellence in Neurosurgery of the "Bagdasar - Arseni" Emergency Hospital (Figure 10).

Unfortunately, after all the four embolization, a rest of the nidus of the arteriovenous malformation of about 1.5 cm remains, as revealed on brain MRI (Figure 11), so it is decided irradiation by Gamma-Knife in July 2008. The patient is neurologically improved under anticonvulsant therapy.

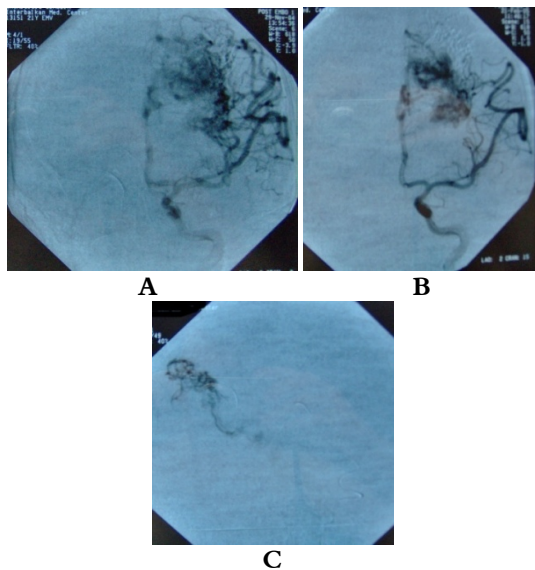


Figure 9 A. Preembolization; B. Postembolization; C. Intraembolization

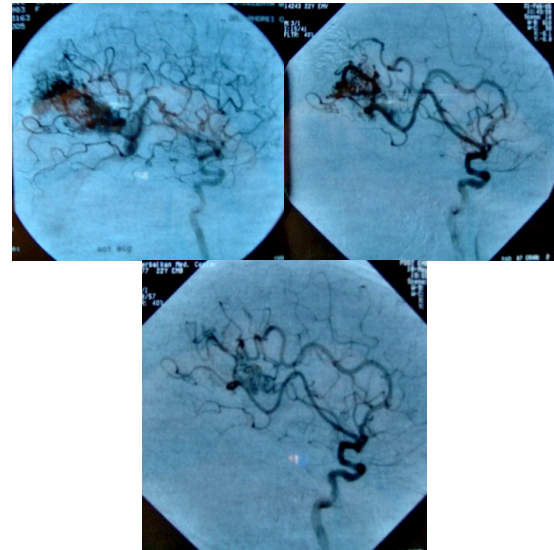


Figure 10 Successive images after the three embolizations

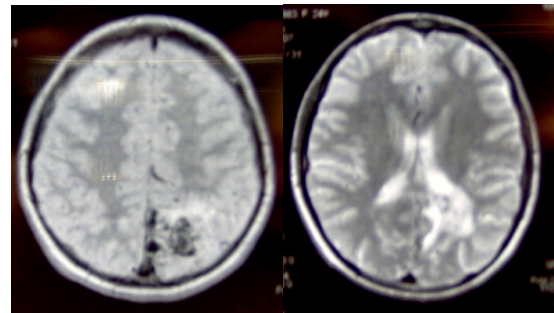


Figure 11 MRI image of the nidal rest of parieto-occipital brain AVM

Conclusions

We notice a marked increase in the addressability to modern techniques of treatment by embolization and stereotactic radiosurgery - Gamma-Knife, after the opening of the Center of Excellence in Neurosurgery equipped according to the European standards, it being the sole center of this kind in this country, with significant decrease in the morbidity and mortality.

The analysis of the presented study, related to the cerebral arteriovenous malformations, the casuistry of Neurosurgery Clinic I, reflects the current

situation in the Romanian health system and in the Romanian neurosurgery in the treatment of cerebral arteriovenous malformations, the "Bagdasar-Arseni" Emergency Hospital being the only center in this country where there are met all the conditions for application of the three active therapies currently practiced anywhere in the world, in MAV-C treatment: microsurgical treatment, endovascular therapy and the Gamma-Knife stereotactic radiosurgery, as monotherapy or as multimodal approach.

References

1. Alksne, J.F., Stereotactic thrombosis of intracranial aneurysms. *N Engl J Med*, 1971. 284(4): p. 171-4.
2. Constantinovici, A., Ciurea, AV., *Tratamentul malformatiilor arterio-venoase ale SNC. Ghid practic de neurochirurgie*. 1998
3. Fox, P.L., G.M. Chisolm, and P.E. DiCorleto, Lipoprotein-mediated inhibition of endothelial cell production of platelet-derived growth factor-like protein depends on free radical lipid peroxidation. *J Biol Chem*, 1987. 262(13): p. 6046-54.
4. Frei, E.H., et al., The POD and its applications. *Med Res Eng*, 1966. 5(4): p. 11-8.
5. Gallagher, J.P., Obliteration of intracranial aneurysms by pilojection. *Jama*, 1963. 183: p. 231-6.
6. Guglielmi, G., et al., Electrothrombosis of saccular aneurysms via endovascular approach. Part 2: Preliminary clinical experience. *J Neurosurg*, 1991. 75(1): p. 8-14.
7. Haschek, E., Lidenthal, OT., Ein Beitrag zur praktischen verwerthung der photographie nach rontgen. *Wien Klin. Wschr.*, 1896. 9: p. 63-64.
8. Hilal, S.K., et al., Magnetically guided devices for vascular exploration and treatment. *Radiology*, 1974. 113(3): p. 529-40.
9. Hilal, S.K. and R.A. Solomon, Endovascular treatment of aneurysms with coils. *J Neurosurg*, 1992. 76(2): p. 337-9.
10. Luessenhop, A.J. and A.C. Velasquez, Observations on the Tolerance of the Intracranial Arteries to Catheterization. *J Neurosurg*, 1964. 21: p. 85-91.
11. Moniz, E., L'encephalographie arterielle: son importance dans la localisation des tumeurs cerebrales. *Rev Neurol (Paris)*, 1927. 2: p. 72-89.
12. Mullan, S., P.V. Harper, and Y. Gerol, An experimental study in the use of a rapidly decaying beta source (Pd109) in the production of deep cerebral lesions. *Am J Roentgenol Radium Ther Nucl Med*, 1960. 84: p. 108-12.
13. Purdy, P.D., et al., Arteriovenous malformations of the brain: choosing embolic materials to enhance safety and ease of excision. *J Neurosurg*, 1992. 77(2): p. 217-22.
14. Serbinenko, F.A., Balloon catheterization and occlusion of major cerebral vessels. *J Neurosurg*, 1974. 41(2): p. 125-45.
15. Serbinenko, F.A., [Balloon occlusion of saccular aneurysms of the cerebral arteries]. *Vopr Neurokhir*, 1974(4): p. 8-15.