

## Ruptured intracranial aneurysm associated with bilateral carotid occlusive diseases and venous angioma: a case report

A. Chiriac, J. Baldauf<sup>1</sup>, H.W. Schroeder<sup>1</sup>, Z. Faiyad, A.Șt. Iencean, I. Poetă

Clinic of Neurosurgery, “Gr.T. Popa” University of Medicine and Pharmacy Iasi, Romania

<sup>1</sup>Klinik für Neurochirurgie, Ernst-Moritz-Arndt-Universität Greifswald, Germany

### Abstract

Coexistence of a ruptured intracranial aneurysm with an internal carotid arteries carotid artery occlusion, a contralateral internal carotid artery stenoses and a intracranial venous angioma is infrequent and it suppose a complicate diagnosis and therapeutic management of either disease. We report a case who underwent a first successful microsurgical clipping of the intracranial aneurysm followed by a right carotid artery angioplasty with stenting after two months.

### Introduction

A patient with coexistence of ruptured intracranial aneurysm, a carotid artery occlusion, an opposite carotid artery stenoses and brain venous angioma is a very rare clinical situation. Ito M. and collaborators describe in there article a similar case but with multiple aneurysms. This special clinical situation is rarely found due to specialist attention focused on one of the two types of injuries, but also as a result of angioCT use as first intent of imaging exploration detrimental to femoral catheter angiography. Thus, many specialists do not perform a complete cerebral angiographic exploration for suspected stenosis and / or carotid occlusion, and most of neurosurgical centers use angioCT

exploration for diagnosis and interventional planning of intracranial aneurysms. Coexisting of a ruptured intracranial aneurysm and a stenosis and / or carotid occlusion is a special situation where the therapeutic needs it requires a high performs. The extremely low number of these situations and the relatively results obtained led us to present this case.

### Case presentation

Pacient T. D., male, 45 years old describe onset of symptoms by sudden sleep violent headache followed by nausea, vomiting. The patient had initial addressed to Suceava Hospital, where the symptoms were initially interpreted as heatstroke. So he was sent at home with medication treatment. Because over the next seven days the headache persists the patient carry out a cerebral CT-scan which shows a SAH (Figure 1). He is directed to Neurosurgery Iasi.

On admission he was in grade II (Hunt & Hess Scale). First, a cerebral angioMRI was performed, reveling a possible anterior communicating artery aneurysm as source of subarachnoid hemorrhage. Due to, an unclear image a femoral catheter angiography was performed next day. Cerebral angiography exposed an occlusion of left internal carotid artery (Figure 4A), a

70% stenosis of right internal carotid artery, a T-insular venous anomaly and confirmed the AntCoA aneurysm. Cross filling was good, being provided from both carotid and vertebral territory through the anterior and posterior communicated segment (Figure 2 A, B, C).

After 7 days of standard treatment the patient was submitted to surgery. Aneurysm was approached through a right pterional craniotomy with sylvian fissure dissection, carotid and suprachiasmatic cisterns opening, a minimum gyrus rectus resection and highlighting of A1, A2, bilateral recurrences. Aneurysm is looking extremely thin, polilobate, brittle fragile except the two main lobes.

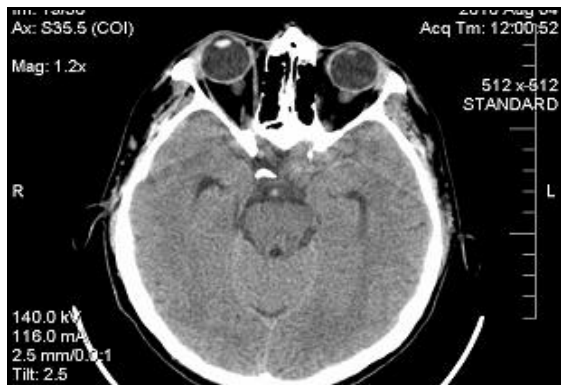


Figure 1 CT cerebral showing a SAH

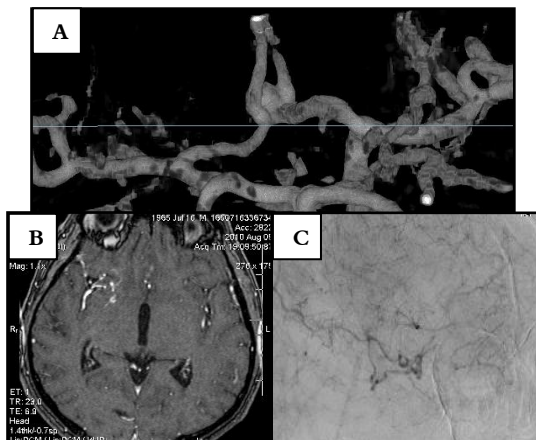

Figure 2 A 3D reconstruction of AngioMRI showing an ACoA aneurysm; B CE MRI and C DSA

It has buds adjacent to the neck. The difficult dissection of the lateral aneurismal lobe, which is oriented to the left and adherent especially to left recurrent artery, cause a small bleeding of it. Finally, a good obliteration of the aneurysm was achieved by using a lateral angulated Yasargil clip with maintaining patency in all vessels exposed. The aneurysm was clipped with temporary clip control on both A1, lasting for less five minutes. Post-operative course was good with no neurological events (Figure 3).

Concerning the stenosis of right internal carotid artery the decision was to treated conservatively.

The patients suffer a jacksonian seizure followed by a left hemiparesis two months later. The patient was hospitalized and a new cerebral CT scan and angiography was performed. No signs of ischemic lesions were documented and a carotid angioplasty and stenting has been suggested.

The procedure was performed by o right femoral access using an 8Fr sheath. First, an umbrella filters was placed 10 cm above carotid bifurcation as embolic protection device. An 8/30 mm tapered Xact Carotid Stent (ABBOTT) was used for stenotic portion dilatation of carotid artery. Afterwards, the umbrella filters was retracted and a control injection was performed. The patient was discharge at home 3 days later.

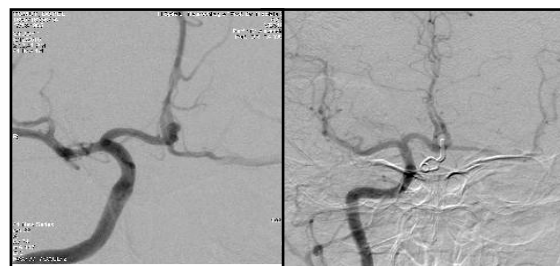
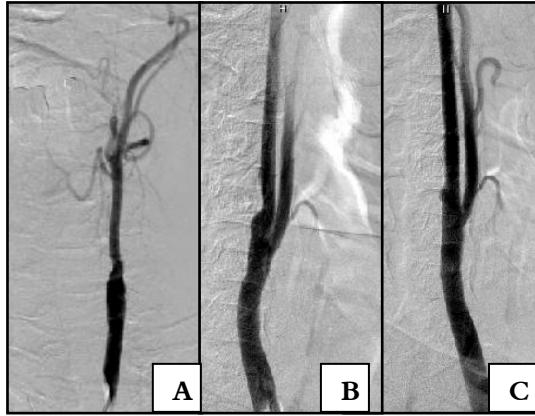
Figure 3 DSA pre and post microsurgical clipping of ACoA aneurysm



**Figure 4** DSA showing **A** left ICA occlusion; **B** right ICA stenosis; **C** right CA dilated with stent

The neurological symptomatology remitted completely two weeks later (Figure 4 B, C).

### Discussion

Ruptured intracranial aneurysm coexisting with this type of bilateral stenotic and / or occlusive carotid lesions is a rare situation that raises a therapeutic issue. Presence of this situation was appreciated by Navaneethan SD and collaborators at 3% of total patients with intracranial aneurysms(5). The decision of initially intracranial aneurysm clipping before carotid dilation involves the risk of stroke because of decreased blood flow due to spasm, or to necessity of using temporary clips to control the final positioning of definitive clip on the aneurysm neck. On the other hand, stent carotid dilation before aneurysm clipping involves a risk of aneurysm rupture (specially to already ruptured aneurysm) due to increased flow in the territory of aneurysm location, or due to the need to initiate an antiplatelet therapy and maintained anticoagulation. Thus, the decision on which of the two treatments should be applied first, a balancing between the risk of a stroke and

the outbreak of an aneurysm rupture should be made. In case of diagnosed unruptured aneurysms to a patient who suffered a stroke a carotid stent dilation is recommended followed by a microsurgical aneurysm clipping. If the patient is addressed for the cause of aneurysmal subarachnoid hemorrhage is preferable to achieve a first microsurgical clipped aneurysm and a carotid stenting thereafter(5).

Another option in this situation is represented by the achievement in the same therapy endovascular sessions a coil aneurysm occlusion and carotid stenting. Even if the endovascular therapy allows a safety and definitive exclusion of intracranial aneurysms, this technique requires advancing of different microcatheters and wires through the carotid axis. It is well known the serious embolic complications risks of this maneuvers in the presence of a severe carotid stenosis. However, despite the increased use of these procedures, the informations regarding their influence in clinical practice are poor of clinical evidence.

Another theory newly disputed was the influence of different type of carotid stenotic disease on the aneurysmal development and rupture. It was stated that influence of stenotic ICA anomalies in the pathogenesis of intracranial arterial aneurysms is due to increased of hemodynamic stress on the side opposite to the carotid lesion. The combination of the hydrodynamic theory, suggested by Spallone and Cantore study, with other possible factors, might lead to a better understanding of the mechanism underlying development of human cerebral arterial aneurysms. In their series of 76

aneurysm patients, stenotic ICA anomalies were mostly either located or more pronounced on the side opposite the aneurysm (in 22 as opposed to 11 on the same side,  $p < 0.004$ )(7).

Also, Shumann and col. have presented in their article the role of xenon/CT cerebral blood flow (CBF) measurements as diagnostic tool in a case of bilateral ICA stenosis associated with asymptomatic ipsilateral infraclinoidal ICA aneurysm. The CBF measurements including testing of the cerebrovascular reserve capacity (CRC) have demonstrated a compromise of CBF within the anterior circulation of the affected side(6).

Despite that, guidelines of intracranial aneurysm and carotid stenosis diagnosis and treatment are well known, a major impact on these points of view could be noted due to interdisciplinary implication (neurosurgeons, vascular surgeons, interventional cardiologists, interventional radiologists, neurologists). The usually investigation by Eco-color Doppler and Cerebral CT doesn't allow the necessary informations needed for carotid intervention. On the other hand, femoral catheter angiography is not a common alternative, due to its great invasivity and iatrogenic risk of complex examinations. The increased sensitivity and specificity of head and neck Angio MRI, plus its non invasive characteristic had a significant diagnostic impact in these special situations. In these cases, the MRI pattern allows

defining sufficient information for procedure planning.

## Conclusions

The incidental presence of bilateral ICA occlusion daises and intracranial aneurysm need a careful attention for treatment planning. Optimal and safety application of new diagnosis and treatment techniques to such complex vascular conditions can lead to an excellent outcome for these patients.

## References

1. Bidziński J., Bonicki W., Kolity G. V. Zaręba A. (1989) Ruptured intracranial aneurysm associated with spontaneous occlusion of internal carotid artery, *Acta Neurochirurgica*, Vol. 100, Nu. 1-2:43-45;
2. Espinosa G., Dzieciuchowicz L., Grochowicz L. (2009) Endovascular Treatment of Carotid Stenosis Associated with Incidental Intracranial Aneurysm, *Annals of Vascular Surgery*, Vol. 23, (5):688.e1-688.e5;
3. Ito M, Sato K, Tsuji O, Wachi A, Naito S. (1994) Multiple aneurysms associated with bilateral carotid occlusion and venous angioma: surgical management risk-case report. *J Clin Neurosci*. Vol. 1(1):62-8;
4. Liang-Der Jou, H. Shaltoni, H. Morsi, M. Mawad (2010) Hemodynamic relationship between intracranial aneurysm and carotid stenosis: review of clinical cases and numerical analyses, *Neurological Research*, Vol. 32 (10):1083-9;
5. Navaneethan SD, Kannan VS, Osowo A, Shrivastava R, Singh S. (2006) Concomitant intracranial aneurysm and carotid artery stenosis: A therapeutic dilemma., *South Med J.*, 99(7):757-8;
6. Shumann M. U., Mirzai Sh., Samil M., Vorkapic P. () Xenon/CT CBF measurements as valuable diagnostic tool in a case of bilateral occlusive cerebrovascular disease associated with intracranial aneurysm, *Acta Neurologica Scandinavica*, Vol. 93 (s166):104-109;
7. Spallone A., Cantore G. (1981) The role of extracranial carotid abnormalities in the genesis of cerebral aneurysms, *J Neurosurg*. Vol. 55(5):693-700.