



# Cerebral pilocytic astrocytoma with spontaneous intratumoral haemorrhage in the elderly - a rare entity. A case report and review of the literature

Amit Narang, Varun Aggarwal, Divya Kavita, Chandni Maheshwari, Prajjwal Bansal

\* Baba Farid University of Health Sciences. Faridkot. Punjab, INDIA

## ABSTRACT

Pilocytic astrocytomas (PA) are histologically are low-grade tumours, commonly found in the paediatric and young adult population. Although cases of adult and elderly pilocytic astrocytomas are described in the literature, they are quite uncommon. The rate of PAs with spontaneous bleeding is very less, with a high occurrence in children than in adults, moreover, that is in cerebellar PAs. Cerebral PAs with intratumoral haemorrhage in the older age group is extremely rare. We present a case of a 60-year female presenting with acute neurological compromise resulting from an acutely haemorrhagic Left temporal pilocytic astrocytoma. She was managed surgically with evacuation of tumoral haemorrhages, as well as resection of the tumour. Postoperatively the patient made a remarkable recovery.

## INTRODUCTION

Pilocytic astrocytoma (PA) is commonly a paediatric central nervous system glial tumour. Adult occurrence is rare, especially in elderly population. [6,2] The most common sites of PAs origin are cerebellum, optic chiasma, hypothalamus, and to a lesser extent, cerebral hemispheres, brain stem and spinal cord.[6] Reports of tumours with intratumoral haemorrhage in elderly population are extremely rare. Here we present a 60 years old female who presented with left temporal intratumoral bleed mimicking Intracerebral haemorrhage.

## CASE SUMMARY

Ours is a 60-year-old female who was a known case of hypertension and was poorly compliant to anti-hypertensive medications. She had complaint of sudden onset of altered sensorium and slurring of speech. There was no history suggestive of Trauma. Patient was taken to a nearest clinic and was managed conservatively on the line of Intra Cerebral Hemorrhage (ICH), and was discharged after seven days. Three days after the discharge patients attendants brought the patient

---

**Keywords**  
 astrocytoma,  
 cerebral pilocytic  
 astrocytoma,  
 elderly population,  
 intratumoral hemorrhage,  
 tumor excision

---



Corresponding author:  
**Varun Aggarwal**

Guru Gobind Singh Medical College  
 and Hospital Faridkot, Punjab,  
 India

drvarunaggarwal86@gmail.com

**Copyright and usage.** This is an Open Access article, distributed under the terms of the Creative Commons Attribution Non-Commercial No Derivatives License (<https://creativecommons.org/licenses/by-nc-nd/4.0/>) which permits non-commercial re-use, distribution, and reproduction in any medium, provided the original work is unaltered and is properly cited.

The written permission of the Romanian Society of Neurosurgery must be obtained for commercial re-use or in order to create a derivative work.

ISSN online 2344-4959  
 © Romanian Society of  
 Neurosurgery

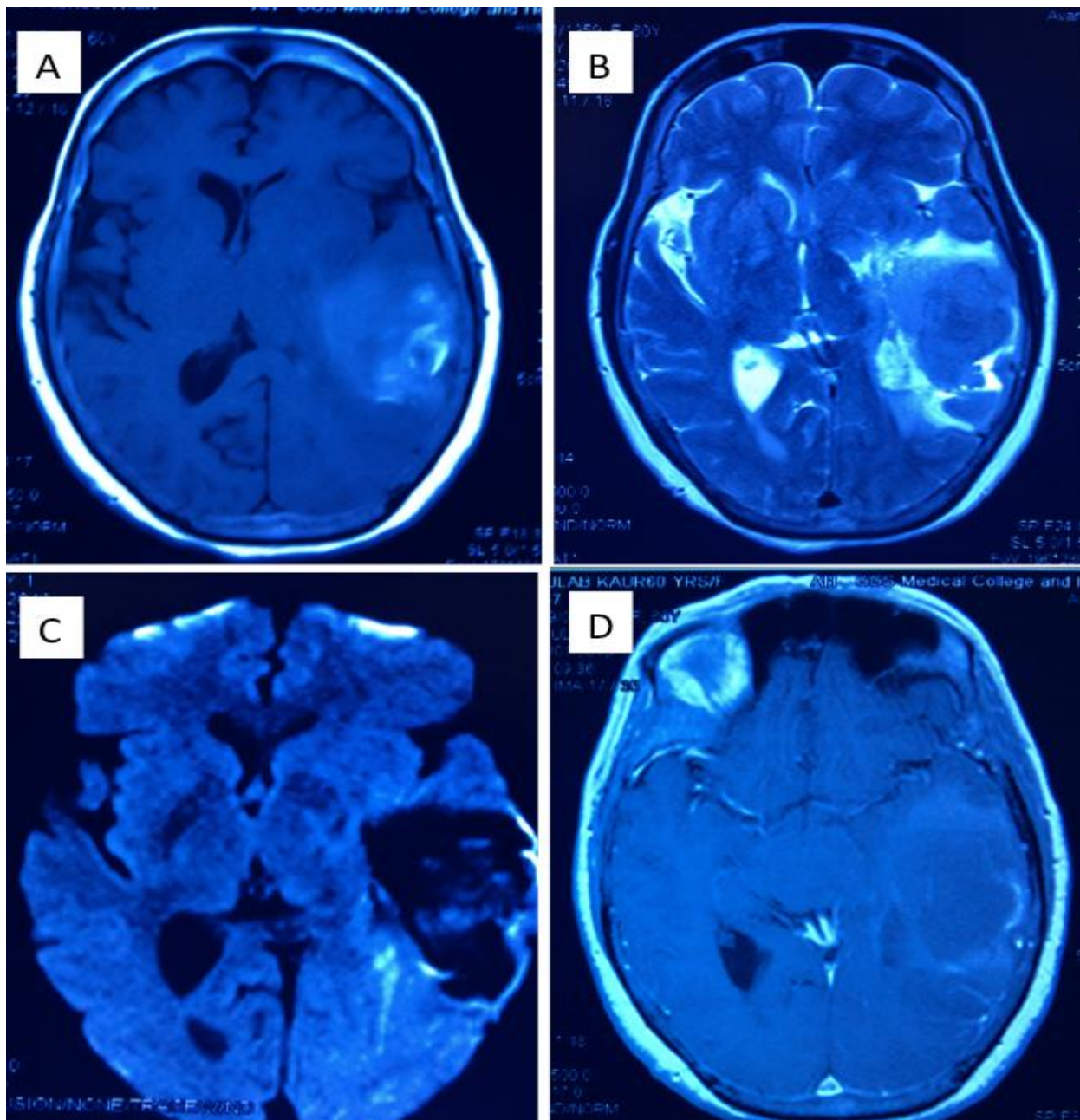


First published  
 June 2019 by  
 London Academic Publishing  
[www.lapub.co.uk](http://www.lapub.co.uk)

to our hospital for second opinion. On presentation her GCS was E3V3M5. Contrast MRI Brain was done which was suggestive 48 x 34 mm altered signal intensity lesion in left temporoparietal cortex with vasogenic edema and with mass effect in the form of midline shift of 6.4 mm towards right. The lesion was hypointens on T2, T1 with marginal T1 hyperintensities, hyperintens on flair and intens blooming in gradient images. In post contrast studies subtle marginal enhancement noted. By enlarge, radiological features were suggestive of left Temporal ICH with mass effect. [Fig-1]. Patient was taken up for surgery. Left frontotemporal craniotomy and eva-

uation of intracerebral hematoma was done. Intraoperatively brain was bulging and there was large hematoma in Rt temporal lobe, brain tissue all around the hematoma was greyish, soft and suckable this tissue was excised all around and was sent for biopsy. Post operatively NCCT was done suggestive of complete evacuation of ICH with reduced mass effect [Fig-2]. Histopathology was suggestive of pilocytic astrocytoma (WHO grade I). Patient improved significantly and discharged on 5<sup>th</sup> Post op day with GCS E4V4M6.

FIGURE 1. A -T1, B -T2, C- DW, D- post contrast MRI showing lesion in left temporal lobe



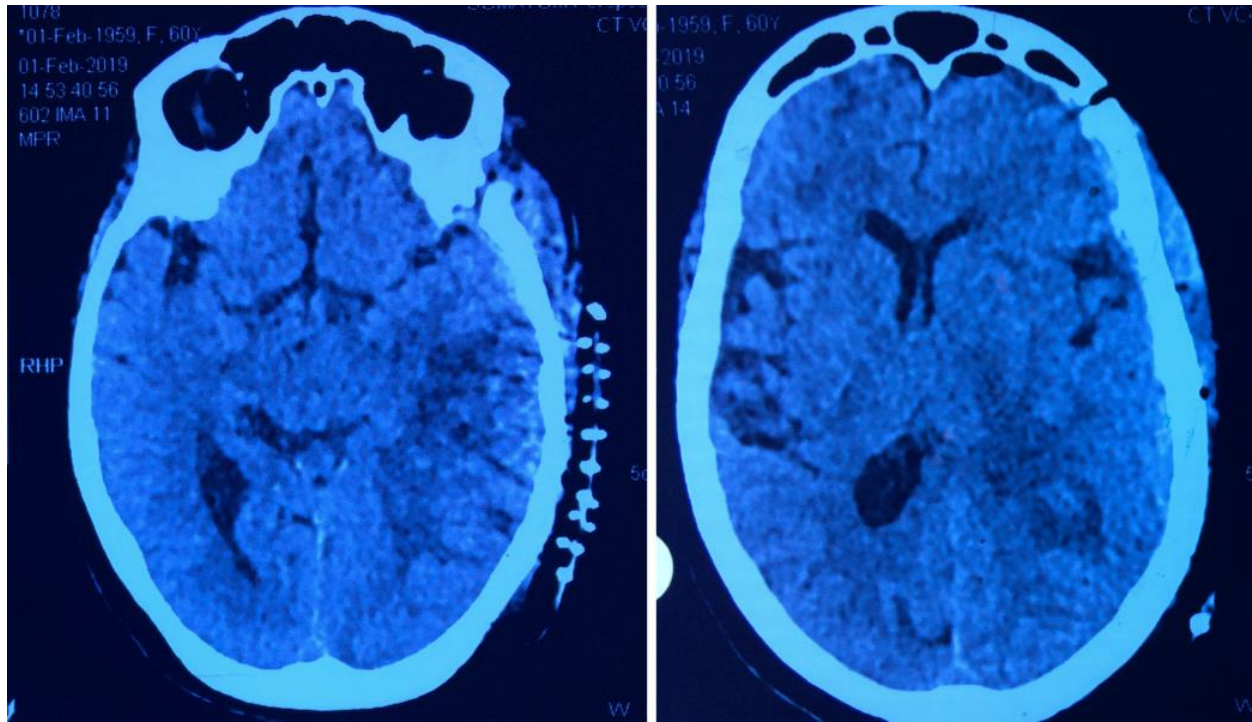


FIGURE 2. First post op day NCCT head showing Complete evacuation of hematoma and reduced mass effect

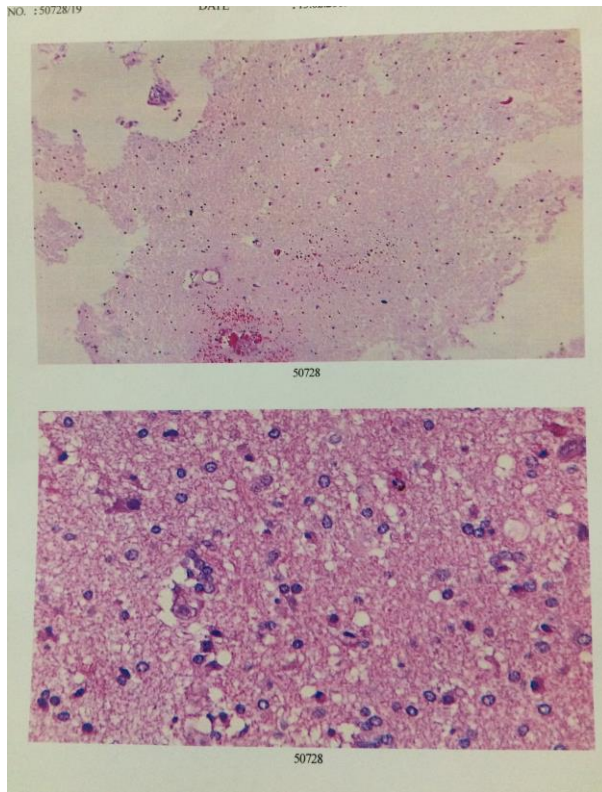


FIGURE 3. Histopathology was suggestive of low grade astrocytic tumor with abundant eosinophilic granular bodies- pilocytic astrocytoma (WHO grade I)

#### DISCUSSION

PA is a histological subtype of astrocytomas, which accounted for approximately 15% of central nervous system (CNS) tumours. PAs are considered World Health Organization (WHO) grade I tumours, which have relatively distinct histological appearance and well demarcated boundaries. [1,5]. This tumour has much higher occurrence among children and adolescents than elderly. Common age group for PAs is 5 to 14 years, followed by 0 to 4 years and 15 to 19 years, however, pilocytic astrocytoma rarely occur over the age of 60. [2]

Patients having a pilocytic astrocytoma may present with sensory motor deficit, gait disturbance, headaches, cranial nerve deficits and hydrocephalus, depending on the exact location. The most common sites of these tumour origin are cerebellum, optic chiasma, hypothalamus, and to a lesser extent cerebral hemispheres, brain stem and spinal cord. [1] Most of glial tumours, such as high-grade astrocytomas, oligodendrocytes, and mixed astrocytomas, have propensity for intratumoral bleeding. However, intratumoral hemorrhage is very rare among patients with PA. [6]

The rate of PAs with spontaneous bleeding is approximately 8%, with a high occurrence in children than in adults, which is mostly in cerebellar PA [6].

Relatively limited amount of literature is available on PAs with intratumoral haemorrhage in older age group. Although vascular necrosis and tumour invasion are the primary causes of bleeding in high-grade gliomas, the mechanisms underlying low-grade gliomas remains unclear. [3] Previous literature have demonstrated that spontaneous bleeding in PAs is due to interaction of various factors, which includes specific pathological changes in vascular structures of tumour, such as proliferation of vascular endothelial cells, hyaline degeneration and interstitial degeneration. Sun S. et al [6] suggested in their study, the vascular histology of bleeding tumour reveals a poorly developed capillary bed and thin vessel walls. Bleeding tumour blood vessels, although rich in collagen have fewer elastic fibres and poor compliance, which can escalates the chances of tumour rupture. As reported previously the reticular vessels are more prone to rupture, which suggests an association between tumour capillary type and bleeding tendency.[4] In addition, intratumoral bleeding is associated with tumour growth, intratumoral vascular invasion, rupture of an encased aneurysm and coagulopathies. Notably, higher arterial pressure and acute intracranial hypertension are also the predisposing factors. Previous studies also suggest that calcification may contribute to intratumoral bleeding. [6,4]. It has been found that the spontaneous bleeding of PAs is also associated with tumour VEGF expression.[7]

The patient in our case report developed spontaneous intratumoral hemorrhage, but the cause of bleeding is still not clear. Therefore, we speculate that intratumoral bleeding may be attributed to tumour vascular abnormalities and hypertension.

PAs patients with intratumoral bleed leading to raised intracranial tension requires emergency neurosurgical care. Surgery is the preferred the treatment for PAs with hemorrhage, which permits simultaneous removal of tumor and hematoma. Tumors that occurred in the brain stem or visual pathway usually cannot be completely removed by surgery, though the residual tumors may cease to grow, or grow slowly, or even regress. Therefore, a long-term follow-up is required for patients with complete and partial resection. The patients treated with subtotal resection may require post op chemotherapy and radiotherapy, but it is still a

matter of debate. The prognosis of patients with PAs is generally good. The location of the tumour and the extent of the resection can play an important role in the prognosis of PAs patients. Reoperation may be considered for most patients with recurrent PAs. Patients with partial resection of tumour can have a higher risk of recurrence. [8] literature suggests that a longer follow-up period is required for PAs patients with intratumoral haemorrhage.

## CONCLUSION

Based on the collective results from the present clinical experience and other related studies, we suggest that cerebral PAs with spontaneous intratumoral haemorrhage is extremely rare, especially in elderly patients over the age of 60 years. We agree with the literature that to completely remove the tumour and hematoma; surgery is probably the most effective treatment option. Long-term follow-up after surgical treatment of PAs with intratumoral haemorrhage is crucial to identify and treat the recurrence if any.

## REFERENCES

1. Bornhorst M, Frappaz D, Packer RJ. Pilocytic astrocytomas. *Handbook Clin Neurol* 2016;134:329–44.
2. Cyrine S, Sonia Z, Mounir T, et al. Pilocytic astrocytoma: a retrospective study of 32 cases. *Clin Neurol Neurosurg* 2013;115:1220–5.
3. Kapoor A, Savardekar A, Tewari MK, et al. Spontaneous hemorrhages in pediatric supratentorial pilocytic astrocytomas. Malignant presentation of a benign entity. *Childs Nerv Syst* 2015;31:1617–20.
4. Kim MS, Kim SW, Chang CH, et al. Cerebellar pilocytic astrocytomas with spontaneous intratumoral hemorrhage in adult. *Korean Neurosurg* 2011;49:363–6.
5. Ostrom QT, Gittleman H, Liao P, et al. CBTRUS statistical report: primary brain and central nervous system tumors diagnosed in the United States in 2007–2011. *Neuro Oncol* 2014;16:1–63.
6. Sun S, Zhou H, Ding ZZ, Shi H. Cerebellar pilocytic astrocytomas with spontaneous intratumoral hemorrhage in the elderly: A case report and review of the literature. *Medicine (Baltimore)*. 2018 Aug;97(31).
7. Wilson MP, Johnson ES, Hawkins C, et al. Hemorrhagic presentations of cerebellar pilocytic astrocytomas in children resulting in death: report of 2 cases. *Neurosurg Pediatr* 2016;17:446–52.
8. Ye JM, Ye MJ, Kranz S, et al. A 10 year retrospective study of surgical outcomes of adult intracranial pilocytic astrocytoma. *J Clin Neurosci* 2014;21:2160–4.