

Intramedullary Tumors - Clinical, Radiological and Histological Correlations

S.C. Craciunas¹, M.R. Gorgan, Carmen M. Cirstea², Mariana Aschie³

¹Neurosurgery Department IV, Bagdasar-Arseni Hospital, Bucharest, Romania

²Hoglund Brain Imaging Center, Neurology and Physical Therapy and Rehabilitation Science Departments, Kansas University Medical Center Kansas City, USA

³Department of Pathology, Ovidius University, Constanta, Romania

Abstract

Intramedullary spinal cord (SC) tumors are relatively rare tumors, accounting for only 2% to 4% of central nervous system tumors. These tumors are generally slow-growing tumors that could benefit from surgical removal. A pre-surgery identification of the tumor histology might improve the surgical management of the tumor and also properly predict the functional outcome after surgery. The neuroimaging techniques, provide crucial information about tumors anatomy. By adding the medical history of the present illness and detailed clinical examination, the imaging data might however be extremely helpful in the prediction of tumor histology. This will allow an appropriate surgical management of these lesions and provide pertinent predictors of the functional outcome post-surgery. Therefore, the surgeon can set the patient's expectations at a realistic level.

The present study is a prospective study, aiming to use combined clinical and imaging data to predict the intramedullary SC tumor histology. The primary

objective is to identify the pathognomonic clinical and imaging pattern for each tumor type.

The study was conducted in the Neurosurgery Clinic Emergency Clinic Hospital Bagdasar-Arseni between 2006 and 2009. A total of 36 patients (19 females/17 males) participated. All patients were evaluated for motor, sensory, sphincter, walking and balance functions. MRI assessment was used to determine the presence of an intramedullary SC tumor as well as its characteristics.

All histological types have a long history of symptoms, which depends of locations in longitudinal plane. All intramedullary tumors presented spinal cord dilatation on MRI. We confined the clinico-radiological characteristics of each histological type, strongly correlated with histopathological analysis, extensively presented in the paper.

By combining a careful medical history, clinical examination and MRI data, we could predict with a reasonable accuracy in preoperative stage the histological type of an intramedullary tumor.

Keywords: astrocytoma, ependymoma, intramedullary tumor, spinal cord tumor

Introduction

Although the intramedullary spinal cord (SC) tumors are relatively rare tumors, accounting for only 2% to 8.5% of central nervous system tumors, thousands of patients are annually affected (Fehlings and Craciunas 2010; Craciunas 2010). Hemangioblastoma and glial tumors represent more than 90% of intramedullary spinal cord tumors, with ependymomas accounting for 35% to 40% of these tumors. These entities are generally slow-growing tumors that could benefit from surgical removal. However, their histology, e.g., benign or malignant, has a particular clinical significance. Further, this significance depends on the tumor's location. For instance, a high cervical area WHO grade I tumor potentially has a worse prognosis compared to a thoraco-lumbar WHO grade III tumor due to high functional and surgical risks associated to the cervical location. Therefore, a pre-surgery identification of the tumor histology might improve the surgical management of the tumor and also properly predict the functional outcome after surgery.

The neuroimaging techniques, e.g., magnetic resonance imaging (MRI), which have undergone spectacular development in recent years, provide crucial information about tumors anatomy. By adding the medical history of the present illness and detailed clinical examination, the imaging data might however be extremely helpful in the prediction of tumor histology. This will allow an appropriate surgical management of these lesions and provide pertinent predictors of the functional outcome post-surgery. Therefore, the surgeon can set the patient's expectations at a realistic level.

The present study is a prospective study, aiming to use combined clinical and imaging data to predict the intramedullary SC tumor histology. The primary objective is to identify the pathognomonic clinical and imaging pattern for each tumor type. Specifically, we analyzed: (i) demographic data, e.g., age, gender, (ii) history of the present illness, e.g., the duration of the symptoms until diagnosis, (iii) clinical symptoms, such as the type of neurological dysfunction: motor, sensory, sphincter function, gait, and/or balance; and the degree of functional impairment, as evaluated by McCormick and ASIA classification, and (iv) imaging data: lesion location, lesion size on the sagittal plan, e.g. number of vertebral segments affected, cyst formation (intratumoral, polar, bulbar), syringomyelia, intensity of T1-, T2-, or T1-Gd-weighted signal, filling with contrast, and other imaging features, such as edema, infiltrative appearance.

Material and methods

Participants

The study was conducted in the Neurosurgery Clinic Emergency Clinic Hospital Bagdasar-Arseni between 2006 and 2009.

A total of 36 patients (19 females/17 males) participated. Patients were included whether (i) they were diagnosed with intramedullary SC tumor, (ii) aged between 18 and 75 years, and (iii) able to perform a MRI examination. Explicit exclusion criteria were: (i) previous surgery, chemo-, or radio-therapy for an intramedullary tumor, (ii) major cognitive dysfunction, limiting the ability to provide a detailed history, (iii) pre-existing neurological disorders, (iv) history of SC injury, (v) presence of systemic diseases, such as liver

failure, metabolic disorders, uremia, transplantation, uncontrolled diabetes, (vi) substance or alcohol abuse, and (vii) treatment with neuroleptics or antiepileptics.

Medical history was focused on the type of the symptoms onset (acute / subacute / insidious), the duration between symptoms onset and diagnosis, and intensity of the symptoms (as evaluated by a self-reported questionnaires).

Clinical Measurements

Immediately after the diagnosis of intramedullary SC tumor, all patients completed a neurological examination comprised of motor, sensory, sphincter, walking and balance functions. Functional assessment was completed by using McCormick classification (see Table 1).

TABLE 1
McCormick grades

Grade	Description
I	Neurologically normal, mild focal to no functional deficits of the involved limb, mild spasticity or reflex abnormality, normal gait
II	Mild to moderate limb sensorimotor deficit, mild to moderate gait difficulty, severe pain or dysesthetic syndrome impairing the quality of life. However, the patient function and walk independently
III	More severe neurological deficit, with the patient requiring a cane or brace to walk, or with significant bilateral upper extremity impairment; the patient may or may not be able to function independently
IV	Severe deficit, with the patient requiring a wheelchair, cane or brace, with bilateral upper extremity impairment; the patient is usually dependent

MRI measurements

MRI assessments were performed for diagnosis. Basically, the imaging assessment was used to determine the presence of an intramedullary SC tumor as well as its characteristics, e.g., extent, location, presence or not of cysts and/or fluid cavity, contrast loading, and presence of the cleavage plane between the tumor and the surrounding tissue.

Histological analysis

Conventional histological analysis was sufficient to diagnose in most cases. However, for an accurate diagnosis, immunochemistry was added in seven cases and electron microscopy and molecular/genetic tests in one case.

Statistical analysis

Statistical analysis was focused on one outcome (tumor histology) and five variables: demographic, neurological and imaging data, type of symptoms onset and symptoms duration. Spearman correlations were used to analyze relationships between outcome and variables. Significant correlations were considered at $p < 0.05$ (SPSS 18.0, SPSS Inc. Chicago, IL).

Results

Demographic characteristics

In our sample, we found two peaks in age distribution, at 20-29 yrs and 40-59 yrs, with a mean age of diagnosis of 40.5 yrs (range between 18 and 72). We focus the present study on the adult patients (aged more than 18 yrs), although the frequency of intramedullary tumors is almost equal or even higher in pediatric than in adult population (Kothbauer 2007; Gepp Rde et al. 2010; Adam et al. 2010; Harrop et al. 2009; McGirt, Chaichana, Atiba, Attenello,

Yao, et al. 2008). With regard to the gender, we did not find any gender dominance.

42% of our patients have been diagnosed with ependymoma and 22% with astrocytoma (see Table 2). However, the high incidence of ependymoma in our series (42%) is due to the exclusion of pediatric patients from our group, where the astrocytoma is the most frequent intramedullary tumor. The rest of 36% patients presented cavernoma, hamartoma, oligodendroglioma, ganglioglioma, hemangioblastoma, and metastasis (see Table 2).

TABLE 2
Distribution by tumor histology

Tumor histology	# cases
Ependymoma	15
Astrocytoma	8
Cavernoma	4
Hamartoma	3
Ganglioglioma	2
Hemangioblastoma	2
Oligodendroglioma	1
Metastasis	1

In our patients, 86% of tumors were classified WHO grade I and II, 11% grade III, and 3% grade IV. Further, the tumors were located particularly at the thoracic level, followed by the cervical level. With regard to tumor length, the majority of tumors extended over one to two vertebral levels.

Clinical results

Intramedullary SC tumors produced a clinical picture consistent with their location. Local pain (spinal) is a common occurrence.

In our patients, the first symptom was paresthesia in 50%, pain in 36%, motor deficit in 11%, and proprioception disturbance in 3% (see Figure 1).

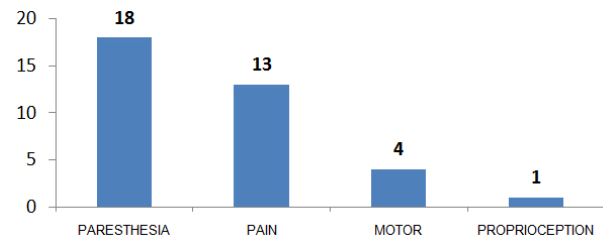


Figure 1 Intramedullary Tumors – First Symptom

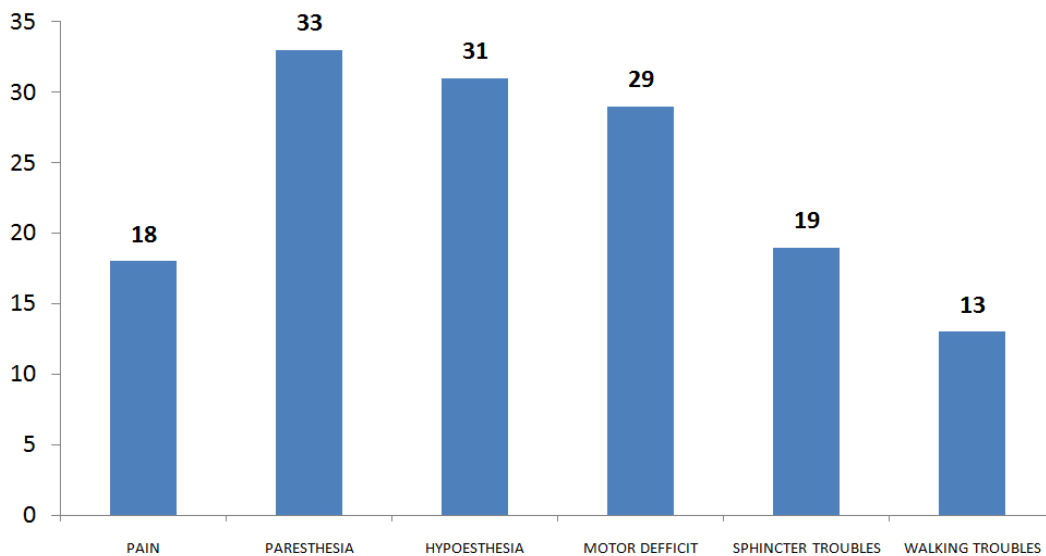


Figure 2 Intramedullary Tumors – Signs and symptoms on admission

Regarding the interval between symptoms onset and diagnosis, the average time was 20 months, ranging between 0.5 and 240 months. The case with the rapid presentation at the hospital (2 weeks) was due to a progressive cauda equina syndrome generated by a metastatic lung adenocarcinoma. In contrast, the case with the longest interval between symptoms onset and diagnosis (240 months) was a T8-T9 thoracic ependymoma.

On admission (see Figure 2), the sensitive (both objective and subjective) and motor deficits dominated the clinical features in our patients. However, motor deficits were mostly mild to medium (ASIA C in 6 cases, D in 23, and E in 7).

Sphincter disturbances occurred in 53% of cases. In more than half of them were mild disturbances, such as uncontrolled emission of urine in small quantities or mild urinary retention.

Thirteen patients presented walking impairment (see Figure 2). Of these, nine patients (70%) were non-ambulatory.

As functional impairment, 39% of patients were McCormick I, 39% McCormick II, and 22% McCormick III, and no McCormick IV.

MRI findings

Spinal cord expansion at tumor's level was presented in all cases. Although the "cap sign" is not pathognomonic, we noticed this feature in 87% of our cases with ependymoma and in 50% of those with hemangioblastoma. However, this feature was absent in our patients with astrocytoma. (See Figure 3)

Small areas of hypointensity on T1- and T2-weighted images are reflective for

calcifications. We met this feature in only 3% of our cases (dermoid cyst). (See Figure 4)

Intratumoral hypointensities could be interpreted as abnormal vascular flow, corresponding to intratumoral vessels. We noticed these characteristics especially in both cases with hemangioblastoma.

The tumor cysts were present in 15 patients (42%). All these patients were diagnosed with glial tumors (astrocytoma, ependymoma, ganglioglioma or oligodendroglioma). Polar cysts were present in eight cases (22%), of which five were ependymoma. Further, both cases with ganglioglioma also showed polar cysts. In the present study, none of our patients showed bulbar cysts.

Syringomyelia was present in 39% of cases. Three out of the four cases with hamartoma presented syringomyelia.

In 20 out of 35 cases, we found peritumoral edema, more notable in patients with hemangioblastoma and ependymoma.

In most tumors (33 out of 36 cases), we found varied degrees of contrast enhancement. However, in three cases (pilocytic astrocytoma, subependymoma and cavernous hemangioma), we found no contrast enhancement.

Discussion

Clinical results

Local pain is a common occurrence in intramedullary tumors. This was the most frequent symptom in our series. Unlike extramedullary tumors, pain is rarely nerve root type (Harrop et al. 2009; Garces-Ambrossi et al. 2009; Fehlings and Mercier 2009; Yang, Yang, and Hong 2009).

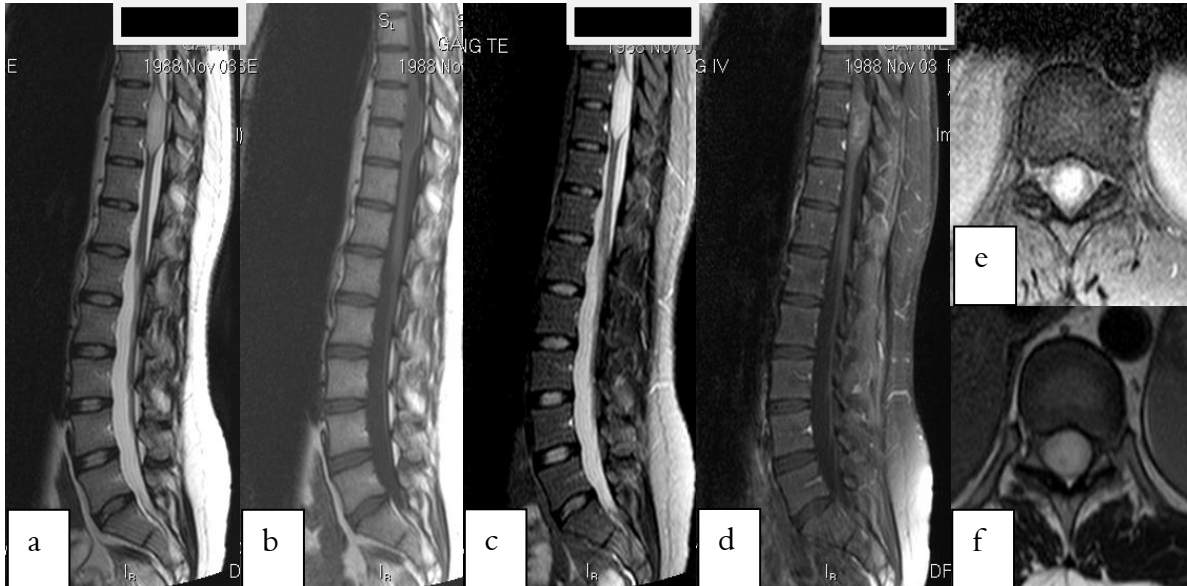

Figure 3 Ependymoma T9-T10 - Sagittal T2(a), T1(b), STIR(c), T1-Gd(d), Axial T2(e), T1-Gd(f) – to note specific aspects: hyperdense in T2, hypodense in T1, contrast enhancing mass central located in spinal cord

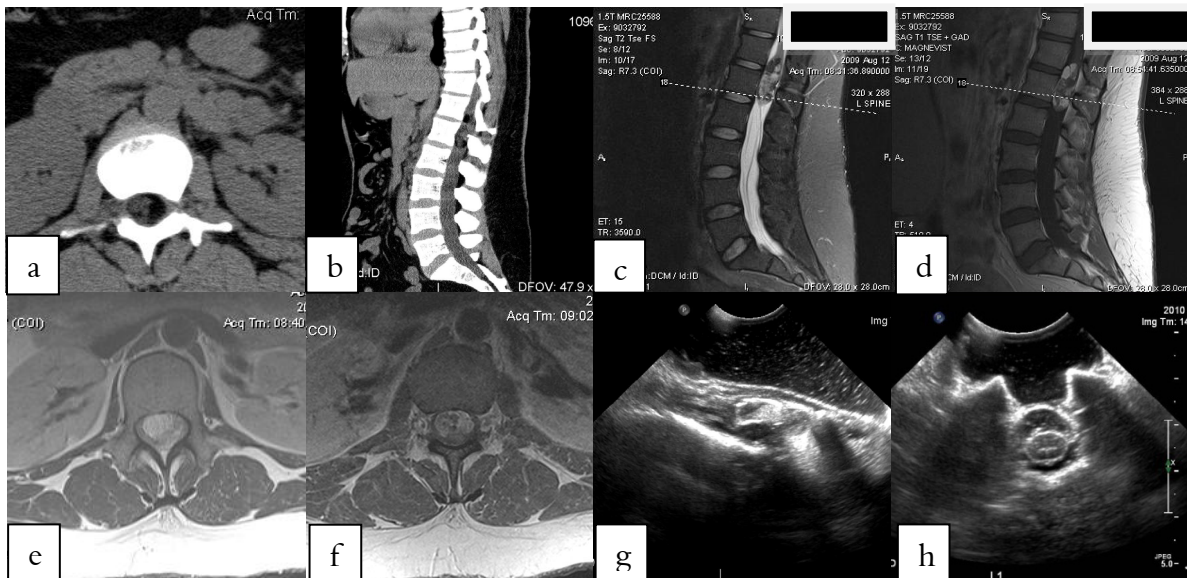

Figure 4 Dermoid cyst T12-L1 – axial CT(a), sagittal CT(b), sagittal T2(c), sagittal T1-Gd(d), axial T1(e,f), intraoperative ultrasonography (g,h) - inhomogeneous aspect, calcifications present. (Thanks to Dr. Michael Fehlings – University of Toronto, for allowing us to present the case)

Since the intramedullary tumors are often developed in the central canal region, there is frequently noticed an early involvement of spino-thalamic tracts, with the sparing of the posterior columns (Jallo,

Freed, and Epstein 2003; Bowers and Weprin 2003; Wang and Liu 1999; Koerbel et al. 2002; Maira et al. 2001; Clemenceau and Lopez 2001). Subsequently, these patients develop burning pain involving

large areas of the body. A typical clinical picture is a segmental, dissociated-type sensibility impairment, affecting the sensitivity for pain and temperature (Raco et al. 2005; Shrivastava et al. 2005; Brotchi 2004; Antoniadis et al. 2005). Pain is typically funicular-type, and can be triggered by a variety of stimuli, including motion and skin irritation. Lhermitte sign is also frequently seen in these patients (Yang, Yang, and Hong 2009; Sun et al. 2009; Manzano et al. 2008; Berhouma et al. 2009; Taricco et al. 2008; McGirt, Chaichana, Atiba, Attenello, Yao, et al. 2008; Nakamura et al. 2008; McGirt, Chaichana, Atiba, Attenello, Woodworth, et al. 2008). As these tumors grow in size, the pyramidal tracts might be affected. Consequently, motor deficits and spasticity may occur in the proximal and then distal affected limb. This is a clinical characteristic of intramedullary tumors (Gepp Rde et al. 2010; Sun et al. 2010; Adam et al. 2010; Garces-Ambrossi et al. 2009; Fehlings and Mercier 2009; Harrop et al. 2009; Yang, Yang, and Hong 2009). Intramedullary tumors located in conus and cauda equina often present as early symptom the genital and sphincter dysfunctions (Gepp Rde et al. 2010; Sun et al. 2010; Adam et al. 2010; Garces-Ambrossi et al. 2009; Fehlings and Mercier 2009; Harrop et al. 2009; Yang, Yang, and Hong 2009). In addition, these entities can exhibit signs and symptoms of autonomic nervous impairment in conjunction with motor and sensitive deficits. If the lateral horn is involved, Horner's syndrome or thermoregulatory and vasomotor dysfunction can occur (Gepp Rde et al. 2010; Sun et al. 2010; Adam et al. 2010; Garces-Ambrossi et al. 2009; Fehlings and Mercier 2009; Harrop et al. 2009; Yang, Yang, and Hong 2009; Sun et al. 2009;

Manzano et al. 2008; Berhouma et al. 2009; Taricco et al. 2008; McGirt, Chaichana, Atiba, Attenello, Yao, et al. 2008; Nakamura et al. 2008; McGirt, Chaichana, Atiba, Attenello, Woodworth, et al. 2008; Sala et al. 2007).

The clinical course of these tumors is most often an insidious process. In our patients, only one case presented neurological deterioration over 2 weeks, the rest of them having a slow progression of symptoms. Patients tend to adapt and compensate the symptoms and as a result they are diagnosed at a relatively advanced stage. However, an acute neurological deterioration can be detected when intratumoral hemorrhage occurs (Gepp Rde et al. 2010; Sun et al. 2010; Adam et al. 2010; Garces-Ambrossi et al. 2009; Fehlings and Mercier 2009; Harrop et al. 2009; Yang, Yang, and Hong 2009; Sun et al. 2009; Manzano et al. 2008; Berhouma et al. 2009; Taricco et al. 2008; McGirt, Chaichana, Atiba, Attenello, Yao, et al. 2008; Nakamura et al. 2008; McGirt, Chaichana, Atiba, Attenello, Woodworth, et al. 2008; Sala et al. 2007).

Therefore, the typical history of symptoms was a gradual and slow progression, without remission of symptoms. This is an important finding that can be used to differentiate between the intramedullary tumors and inflammatory demyelinating syndromes. The latter rapidly develop significant deficits in days or weeks and then show some variability in terms of intensity and location of symptoms. In contrast, an acute onset of symptoms in intramedullary tumors occurs only in rare cases, usually associated with intratumoral hemorrhage or tumors with high malignancy. (see Table 3)

TABLE 3. INTRAMEDULLARY TUMORS - DEMOGRAPHIC AND CLINICAL CHARACTERISTICS

TUMOR	AGE	GENDER	LENGTH	LONGITUDINAL	TRANSVERSAL	ONSET-PRESENTATION INTERVAL	CLINIC	BONE CHANGES
CAVERNOMA	37	F	Usually one segment	T C-cervical, T-thoracic-L-lumbar	Non-specific	Long	P	Non-specific
HAMMARTOMA, EPIDERMOID AND DERMOID CYSTS	No predominant age	N/A	Usually small	TL	Non-specific	Long	Can associate skin and subcutaneous features	Spina bifida
METASTASIS	Aged patients	N/A	2-3 segments	C(45%) T(35%) L(8%)	Non-specific	Short, usually under 1 month	M - almost all P-70%, S-50%	Non-specific
OLIGODENDROGLIOMA	Rare in pediatric age	Slight male predominance	Non-specific	T, CT, TL	Non-specific	Long	Non-specific	Scalloping frequently
GANGLIOGLIOMA	19	N/A	Long, can involve the whole cord	T, C Sometimes holocord	Eccentric	1 mo - 5 y	Non-specific	More recurrent than other IMT
HEMANGIOBLASTOMA	35	N/A	Usually small	T(50%) C(40%)	Superficial. 50% can have extramedullary component	38	S - predominant (especially)	Non-specific
ASTROCYTOMA	Adult: 29 Predominant age in	M	4-7	T (67%), C (49%)	Eccentric	5	P+S(53.6%)	Scoliosis
EPENDYMOMA	40	N/A	2-4	C, CT Myxopapillary - conus	Central	37	R(67%), S(52%), M(46%)	Scoliosis (1.6%)

MRI findings

There are many radiological techniques available for the diagnosis of spinal pathology such as: standard radiological views, computed tomography (CT), myelography, spinal arteriography and MRI. Traditional imaging modalities (conventional radiological views and CT) often fail to indicate the true extension of intramedullary neoplasms, being able to detect these entities only when the massive tumor growth occurred. Myelography, acquired both by conventional radiology or CT, shows an intramedullary mass blocking (completely or partially) the migration of the contrast agent into the intrathecal space. MRI provides a non-invasive method to identify abnormalities associated with these tumors such as cystic formations, syringo/hydromyelia, bleeding and swelling had become a routine in the evaluation of intramedullary spinal masses. In our series, all patients underwent MRI for diagnosis and preoperative management. We used other imaging techniques only for confining the anatomy/location of the lesion with supplemental accuracy.

Currently, MRI is the modality of choice for the evaluation of intraspinal masses. MRI evaluation should include T1, T2 and T1-Gd weighted sequences, in both sagittal and axial planes. Contrast agent enhancement is particularly important in determining the solid portion of intramedullary neoplasms and cysts associated with identification and other items that can often change the differential diagnosis (Sze et al. 1990; Adam et al. 2010; Garces-Ambrossi et al. 2009; Fehlings and Mercier 2009; Harrop et al. 2009).

Although MRI is a very powerful diagnostic tool, its ability to predict tumor histology was considered limited in the

past. For instance, in a series of 171 patients with intramedullary tumors (Brotchi et al. 1991), MRI aspects were correlated with the tumor histology in only 70% of cases. In particular, the MRI differentiation between astrocytoma and ependymoma was difficult.

There are three major MRI characteristics for the intramedullary tumors. First, the expansion of the SC (Takemoto et al. 1988; Adam et al. 2010; Garces-Ambrossi et al. 2009; Fehlings and Mercier 2009; Harrop et al. 2009; Yang, Yang, and Hong 2009; Sun et al. 2009; Manzano et al. 2008; Berhouma et al. 2009) can be used to differentiate between neoplastic and non-neoplastic entities. Specifically, an absence of SC expansion suggests rather a non-neoplastic (e.g., demyelinating disease, sarcoidosis, amyloid angiopathy, pseudotumors, arteriovenous fistulae, spinal cord infarction, cystic myelomalacia) than neoplastic etiology (Lee et al. 1996; Andrews et al. 1988; Dillon et al. 1989; Adam et al. 2010; Garces-Ambrossi et al. 2009; Fehlings and Mercier 2009; Harrop et al. 2009; Yang, Yang, and Hong 2009; Sun et al. 2009; Manzano et al. 2008; Berhouma et al. 2009). Obviously, this differentiation is critical for surgical management. Explicitly, if there is a high probability for a lesion to be a neoplasm, extensive tumor resection should be recommended. In contrast, if a lesion is likely a non-neoplasm entity, a biopsy rather than a surgical approach would be indicated. Subsequently, these patients avoid the risks of aggressive surgery with significantly lower postoperative morbidity (Lee et al. 1996; Adam et al. 2010; Garces-Ambrossi et al. 2009; Fehlings and Mercier 2009; Harrop et al. 2009; Yang, Yang, and Hong 2009; Sun et al. 2009; Manzano et al. 2008; Berhouma et al. 2009). For example,

in a series of 212 patients with intramedullary masses, nine (4%) had non-neoplastic lesions confirmed on the MRI images, e.g., no SC expansion (Lee et al. 1996). Second, most intramedullary spinal neoplasms show contrast enhancement (Parizel et al. 1989; Dillon et al. 1989; Sze et al. 1988; Goy et al. 1986; Bydder et al. 1985; Froment 1996; Adam et al. 2010; Garces-Ambrossi et al. 2009; Fehlings and Mercier 2009; Harrop et al. 2009; Yang, Yang, and Hong 2009; Sun et al. 2009; Manzano et al. 2008; Berhouma et al. 2009). Therefore, in evaluating a patient suspected to have such pathology, it is mandatory to obtain contrast-enhanced images in at least two plans. This is essential for both diagnosis and treatment approaches. However, the absence of contrast enhancement does not exclude a neoplasm (Froment 1996) and caution is recommended in the interpretation of this MRI characteristic. Finally, cystic formations are elements relatively common for the intramedullary tumors. We found cystic entities in almost half of cases, especially in glial tumors. There are two basic types of cysts, tumoral and non-tumoral. Cysts located at the poles of solid portion of tumor are usually simple reactive dilations of the central canal (syringomyelia) or they originate in the fluid produced by the neoplasm (Epstein and Epstein 1982; Harrop et al. 2009; Yang, Yang, and Hong 2009; Sun et al. 2009; Manzano et al. 2008; Berhouma et al. 2009). Approximately 60% of all intramedullary tumors show polar cysts. These cystic cavities can be spontaneously decompressed following tumor resection or can be aspirated by the surgeon during resection (Epstein, Farmer, and Schneider 1991; Harrop et al. 2009; Yang, Yang, and Hong 2009; Sun et al. 2009; Manzano et al.

2008; Berhouma et al. 2009). These formations are part of the cystic tumor, and therefore will not load contrast (Epstein, Farmer, and Schneider 1991). In contrast, tumor cysts are contained within the tumor and often shows peripheral contrast enhancement (Froment 1996; Waldron and Cha 2006). These entities tend to be observed more frequently in astrocytoma than in ependymoma (Epstein, Farmer, and Schneider 1991; Waldron and Cha 2006). Identifying the contrast-enhancing solid portion of tumor (including the tumor cyst) is vital because current neurosurgical techniques allow laminectomy/laminotomy limited only to these areas, with consequent decreased surgical morbidity.

Intramedullary tumor MRI characteristics

Topography: The standard radiological views may be useful in precisely determining the level of spinal lesion, especially if vertebral anomalies are present. If this is not possible, imaging studies should include anatomical structures that allow the identification of the level. For instance, using a wide field imaging (e.g. antenna array of 512) allows the location of the two poles of the tumor by counting the vertebrae from the sacral-iliac joint or odontoid process. A central location within the spinal canal favors the diagnosis of ependymoma, while eccentric location suggests a diagnosis of astrocytoma, hemangioblastoma or lipoma (Adam et al. 2010; Harrop et al. 2009; Manzano et al. 2008; Waldron and Cha 2006; Bowers and Weprin 2003; Hoshimaru 2001). Our results were consistent with those reported in the literature.

Signal characteristics: MRI allows differentiating solid and cystic portions of tumors and demonstrates the presence or

absence of swelling and signal changes following contrast loading.

The solid portions of most intramedullary tumors are hypointense or isointense on T1-weighted images and isointense or hyperintense on T2-weighted image. These signal abnormalities are generally well defined and can have either homogeneous or heterogeneous appearance. For example, a clear hyperintensity on T1-weighted image suggests the presence of sub-acute blood (from 3-5 days to a month after bleeding) while a hypointensity on T2-weighted images with margins more or less defined on T1 reflects hemosiderin, characteristic feature of chronic bleeding (months to years after bleeding). Another example is the "cap sign", a hypointensity on both poles of the solid tumor that was histologically and intra-operatively correlated with areas of chronic hemorrhage. In our sample, this feature were consistently present in ependymoma cases.

Cystic formations represent a common feature associated with solid portion of intramedullary tumor and several types of cysts have been reported (Adam et al. 2010; Harrop et al. 2009; Manzano et al. 2008; Waldron and Cha 2006; Bowers and Weprin 2003; Hoshimaru 2001). The majority of our patients presented cysts. Intratumoral cysts usually have a different signal from that of CSF due to the high-protein or blood content, e.g., low signal on T1 and high signal on T2-weighted images. They have a well-defined contour and their walls load the contrast substance after injection (Adam et al. 2010; Harrop et al. 2009; Manzano et al. 2008; Waldron and Cha 2006; Bowers and Weprin 2003; Hoshimaru 2001). Polar cysts can be present at both upper and lower poles of

the tumor, with a signal similar with that obtained from CSF, e.g., low T1 signal and high T2 signal. However, there are some varieties of the signal acquired from these cysts. Further, these cysts are characterized by: (i) appearance to be under tension, (ii) often round shape, and (iii) walls that do not load the contrast substance. Syringomyelia cavities, associated with intramedullary tumors, have their terminal portions often filiform and satellite cysts may coexist even if the communication with the syringomyelic cavity is not always visible. These cysts also appear to be under tension, but their walls do not have specific characteristics and do not exhibit contrast enhancement. Finally, bulbar cysts have a convex appearance and a signal similar to CSF. They are usually located under the floor of the fourth ventricle, far from the tumor and communicate with the subjacent syringomyelic cavity. After tumor removal and the subsequent opening of the cyst cavity and drainage of the syringomyelic cavity, these cysts gradually regress and disappear in a several months (Adam et al. 2010; Harrop et al. 2009; Manzano et al. 2008; Waldron and Cha 2006; Bowers and Weprin 2003; Hoshimaru 2001). (See Table 4)

Peritumoral edema is another feature of the intramedullary tumors that can be identified on MRI images, such as a hyperintensity on T2-weighted images. Peritumoral edema can be extensive, especially in hemangioblastoma, and disappears after tumor resection (Adam et al. 2010; Harrop et al. 2009; Manzano et al. 2008; Waldron and Cha 2006; Bowers and Weprin 2003; Hoshimaru 2001). (See Table 4).

The capability of these lesions to uptake or not the contrast substance is essential for diagnosis. For instance, contrast

enhancement of the cystic walls suggests a neoplastic nature. For the solid portion of the tumors, the regular appearance is moderately to very intense uptake of the contrast substance (particularly in hemangioblastoma) (Waldron and Cha 2006).

Another important feature of the contrast loading is the homogeneity of the uptake, varying from homogeneous loading in ependymoma to heterogeneous in astrocytoma (Adam et al. 2010; Harrop et al. 2009; Manzano et al. 2008; Waldron and Cha 2006; Bowers and Weprin 2003; Hoshimaru 2001). Similar finding was also found in our series. Further, the rate of loading and unloading of the contrast substance may offer an idea about the tumor histology, e.g., slower load in astrocytoma than ependymoma (Adam et al. 2010; Harrop et al. 2009; Manzano et al. 2008; Waldron and Cha 2006; Bowers and Weprin 2003; Hoshimaru 2001). (See Table 4)

Although MRI examination remains the most valuable investigation in SC pathologies, the clinical and laboratory data may improve its value in the diagnosis of nonspecific pathologies, such as metastatic melanoma, lymphoma and sarcoidosis. However, it is clearly that in some cases, the final diagnosis can be only derived from the histological exam.

For instance, in the case of intramedullary SC tumors, MRI cannot provide an accurate assessment of the infiltrative nature of these. The SC dilatation or abnormal MRI signal within the SC are not pathognomonic for intramedullary tumors. MRI signal change in some extramedullary spinal lesions, e.g., enteric cysts, is another example of the MRI limitation to distinguished from SC

intramedullary masses. One solution for this limitation is the MRI acquisition on multiple planes. However, the differential diagnosis between intra- and extramedullary tumors can be difficult when intramedullary tumor is partially exofitic. Furthermore, SC enlargements are present in other pathologies, such as syringomyelia fluid, multiple sclerosis, vascular malformations and post-irradiation myelopathy. Therefore, these pathologies should be excluded.

Differential diagnosis between hydrosyringomyelia and intramedullary tumors is difficult by using myelography of myelo-CT alone. In contrast, MRI diagnosis of intramedullary cavities filled with fluid, on the sagittal and axial images, is relatively a common clinical practice.

Another MRI limitation is in the differential diagnosis between multiple sclerosis (MS) and intramedullary tumor. For example, a MS' plaque in the acute stage is characterized by a focal intramedullary lesion on T2-weighted images accompanied by an SC enlargement. Clinical context and signs of intracranial demyelination on T2 images (particularly an increased periventricular signal) significantly helps the diagnosis. Finally, the lack of the intramedullary contrast several weeks after the baseline MRI evaluation confirms the diagnosis of MS.

Images of vascular structures could be sometimes misleading. Although it is relatively easy to diagnose an intramedullary hematoma, this does not exclude the possibility of an intratumoral hemorrhage. A longitudinal MRI evaluation will provide required information to avoid the failure of diagnosis. Specifically, a structure with a long vascular nidus, visualized on myelography and MRI (particularly in T2-

weighted images) suggests a spinal medullar angioma. Vascular structures may be more visible in hemangioblastoma, but this entity is characterized by a nidus loading intense contrast. Perimedular venous drainage of dural fistulas can be associated with extensive hyper-intense areas on T2, but with no significant increasing in spinal cord dimensions. Spinal arteriography is used to confirm the diagnosis.

In post-radiation myelopathy, the focal loading after contrast administration may raise difficulties in interpretation. History of disease in the area where the radiation has been applied, the clinical course and the characteristic changes in bone matrix are useful diagnostic indices. Further, the decisive argument in favor of post-radiation myelopathy is the absence of SC enlargement, although a potential enlargement can occur in the acute phase followed by a regression. Furthermore, this regression might continue, and an atrophy of SC can be documented on subsequent MRI evaluations.

Despite all our efforts, we still account a major problem, the distinction between astrocytoma and ependymoma. This distinction is critical for tumor resectability, such as subtotal resection or biopsy for astrocytoma and total resection for ependymoma. Astrocytoma, a long tumor with edges poorly demarcated, is frequently located at the thoracic level. These tumors are eccentric, show moderate and partial heterogeneous contrast enhancement, and

can present intra-tumoral cysts. In contrast, ependymoma are usually less extensive and well-defined tumors localized particularly at the cervical level. These tumors show intense and homogeneous contrast enhancement, and are often presenting large cysts and cap sign.

We need to mention the technical limitations of a MRI evaluation. For example, the artifacts related to CSF motion are one of the common limitations. Using effective techniques for flow compensation however eliminates this. Another example is the difficulty to achieve accurate spatial reconstruction in patients with severe spinal deformity. For this, a GE-3D sequences can provide a valuable volumetric image acquisition. Finally, the slice thickness must be reduced as much as possible (3mm or less) to avoid partial volume effects and the acquisition in different planes may help to precisely characterize the tumor.

Conclusions

In summary, by combining MRI features of intramedullary tumor with medical history and clinical examination the tumor histology could be predicted with a reasonable accuracy. This is important in neurosurgical practice, allowing an appropriate surgical management of these lesions and providing pertinent predictors of the functional outcome post-surgery.

TABLE 4. INTRAMEDULLARY TUMORS - IMAGING FEATURES

TUMOR	T1	T2	CONTRAST	CYSTS	SYRINGOMYELIA	EDEMA	OTHER MRI FEATURES
CAVERNOMA	Hyper	Hypointensity ring	No	No	Non-characteristic	Non-characteristic	Various age hemorrhages
HAMMARTOMA, EPIDERMOID AND DERMOID CYSTS	Heterogeneous	Heterogeneous	Non-homogeneous	Non-specific	Non-specific	Inconstant	Calcifications possible
METASTASIS	Central hyposignal area	Hyper	Intense	Rare	Rare	Adjacent lesion Intense	Non-specific
OLIGODENDROGLIOMA	Iso + foci of Hyper (methB)	Hyper + foci hypo (hemostein)	Inhomogenous	Non-specific	Frequent	Non-specific	Calcifications possible
GANGLIOGLIOMA	Mixt appearance, "salt and pepper"	Hyper	Inhomogeneous, 15% non-enhancing	More frequent than astrocytoma and	As other IMT's	Rare	Calcifications possible
HEMANGIOBLASTOMA	Hyper Iso	Hyper + flow artifacts	Intense enhancing node	Usually present	Frequent	Might be present, but not	Well-confined, localized on dorsal spinal cord surface
ASTROCYTOMA	Hypo Iso	Hyper	Almost always present	Frequent	Frequent	Frequent	Poor defined borders, infiltrative
EPENDYMOMA	Hypo Iso	Hyper Iso	Intense	78-84%	9-50%	>60%	Well-confined, cleavage plan, "cap sign"

References

1. Adam, Y., J. Benezech, A. Blanquet, J. M. Fuentes, J. Y. Bousigue, B. Debono, E. Duplessis, C. Espagno, J. Y. Plas, J. P. Lescure, J. Destandau, J. P. Hladky, P. Grunewald, K. Mahla, J. Remond, and E. Louis. 2010. [Intramedullary tumors. Results of a national investigation in private neurosurgery]. *Neurochirurgie* 56 (4):344-9.
2. Andrews, B. T., P. R. Weinstein, M. L. Rosenblum, and N. M. Barbaro. 1988. Intradural arachnoid cysts of the spinal canal associated with intramedullary cysts. *J Neurosurg* 68 (4):544-9.
3. Antoniadis, G., M. Engelhardt, W. Borm, H. P. Richter, and S. A. Rath. 2005. [Spinal intramedullary tumors. When is surgical treatment indicated?]. *Nervenarzt* 76 (2):186-92.
4. Berhouma, M., K. Bahri, S. Houissa, I. Zimmel, N. Khouja, L. Aouidj, H. Jemel, and M. Khaldi. 2009. [Management of intramedullary spinal cord tumors: surgical considerations and results in 45 cases]. *Neurochirurgie* 55 (3):293-302.
5. Bowers, D. C., and B. E. Weprin. 2003. Intramedullary Spinal Cord Tumors. *Curr Treat Options Neurol* 5 (3):207-212.
6. Brotchi, J. 2004. [Surgical treatment of intramedullary tumors. Experience with 316 cases]. *Bull Mem Acad R Med Belg* 159 (5-6):335-9; discussion 339-41.
7. Brotchi, J., O. Dewitte, M. Levivier, D. Baleriaux, A. Vandesteene, C. Raftopoulos, J. Flament-Durand, and J. Noterman. 1991. A survey of 65 tumors within the spinal cord: surgical results and the importance of preoperative magnetic resonance imaging. *Neurosurgery* 29 (5):651-6; discussion 656-7.
8. Bydder, G. M., J. Brown, H. P. Niendorf, and I. R. Young. 1985. Enhancement of cervical intraspinal tumors in MR imaging with intravenous gadolinium-DTPA. *J Comput Assist Tomogr* 9 (5):847-51.
9. Clemenceau, S., and M. Lopez. 2001. [Intramedullary tumors]. *Rev Prat* 51 (11):1206-10.
10. Craciunas, S ; Aschie, M ; Iliesiu, A ; Bani-Ahmed, A ; Cirstea, C. 2010. Intramedullary spinal cord tumors: neuroimaging features predict histopathology. Society for Neuroscience 40th Annual Meeting, San Diego, US, 2010.
11. Dillon, W. P., D. Norman, T. H. Newton, K. Bolla, and A. Mark. 1989. Intradural spinal cord lesions: Gd-DTPA-enhanced MR imaging. *Radiology* 170 (1 Pt 1):229-37.
12. Epstein, F., and N. Epstein. 1982. Surgical treatment of spinal cord astrocytomas of childhood. A series of 19 patients. *J Neurosurg* 57 (5):685-9.
13. Epstein, F. J., J. P. Farmer, and S. J. Schneider. 1991. Intraoperative ultrasonography: an important surgical adjunct for intramedullary tumors. *J Neurosurg* 74 (5):729-33.
14. Fehlings, M. G., and S. C. Craciunas. 2010. Editorial: High-grade intramedullary astrocytomas: what is the best surgical option? *J Neurosurg Spine* 12 (2):141-2; discussion 142-3.
15. Fehlings, M. G., and D. Mercier. 2009. Factors predicting the resectability of intramedullary spinal cord tumors and the progression-free survival following microsurgical treatment. *J Neurosurg Spine* 11 (5):588-9; discussion 590.
16. Froment, A. 1996. [Role of patient in the medical decision]. *Therapie* 51 (3):283-6.
17. Garces-Ambrossi, G. L., M. J. McGirt, V. A. Mehta, D. M. Sciubba, T. F. Witham, A. Bydon, J. P. Wolinsky, G. I. Jallo, and Z. L. Gokaslan. 2009. Factors associated with progression-free survival and long-term neurological outcome after resection of intramedullary spinal cord tumors: analysis of 101 consecutive cases. *J Neurosurg Spine* 11 (5):591-9.
18. Gepp Rde, A., J. M. Couto, M. D. da Silva, R. T. da Silva, and E. A. Neri. 2010. Intramedullary tumors in children: analysis of 24 operated cases. *Arq Neuropsiquiatr* 68 (3):396-9.
19. Goy, A. M., R. S. Pinto, B. N. Raghavendra, F. J. Epstein, and Kricheff, II. 1986. Intramedullary spinal cord tumors: MR imaging, with emphasis on associated cysts. *Radiology* 161 (2):381-6.
20. Harrop, J. S., A. Ganju, M. Groff, and M. Bilsky. 2009. Primary intramedullary tumors of the spinal cord. *Spine (Phila Pa 1976)* 34 (22 Suppl):S69-77.
21. Hoshimaru, M. 2001. [Diagnosis and microsurgical treatment of intramedullary spinal cord tumors]. *No Shinkei Geka* 29 (3):207-14.
22. Jallo, G. I., D. Freed, and F. Epstein. 2003. Intramedullary spinal cord tumors in children. *Childs Nerv Syst* 19 (9):641-9.
23. Koerbel, A., C. E. Tatsui, D. M. Prevedello, R. A. Hanel, C. V. Grande, L. F. Ditzel, J. C. Araujo, and A. Antoniuk. 2002. [Prognostic factors in the treatment of intramedullary spinal cord tumors]. *Arq Neuropsiquiatr* 60 (3-B):818-22.
24. Kothbauer, K. F. 2007. Neurosurgical management of intramedullary spinal cord tumors in children. *Pediatr Neurosurg* 43 (3):222-35.
25. Lee, M., A. R. Rezai, D. Freed, and F. J. Epstein. 1996. Intramedullary spinal cord tumors in neurofibromatosis. *Neurosurgery* 38 (1):32-7.
26. Maira, G., P. Amante, L. Denaro, A. Mangiola, and C. Colosimo. 2001. Surgical treatment of cervical intramedullary spinal cord tumors. *Neurol Res* 23 (8):835-42.
27. Manzano, G., B. A. Green, S. Vanni, and A. D. Levi. 2008. Contemporary management of adult intramedullary spinal tumors-pathology and

- neurological outcomes related to surgical resection. *Spinal Cord* 46 (8):540-6.
28. McGirt, M. J., K. L. Chaichana, A. Atiba, F. Attenello, G. F. Woodworth, and G. I. Jallo. 2008. Neurological outcome after resection of intramedullary spinal cord tumors in children. *Childs Nerv Syst* 24 (1):93-7.
29. McGirt, M. J., K. L. Chaichana, A. Atiba, F. Attenello, K. C. Yao, and G. I. Jallo. 2008. Resection of intramedullary spinal cord tumors in children: assessment of long-term motor and sensory deficits. *J Neurosurg Pediatr* 1 (1):63-7.
30. Nakamura, M., K. Ishii, K. Watanabe, T. Tsuji, H. Takaishi, M. Matsumoto, Y. Toyama, and K. Chiba. 2008. Surgical treatment of intramedullary spinal cord tumors: prognosis and complications. *Spinal Cord* 46 (4):282-6.
31. Parizel, P. M., D. Baleriaux, G. Rodesch, C. Segebarth, B. Lalmand, C. Christophe, M. Lemort, P. Haesendonck, H. P. Niendorf, J. Flament-Durand, and et al. 1989. Gd-DTPA-enhanced MR imaging of spinal tumors. *AJR Am J Roentgenol* 152 (5):1087-96.
32. Raco, A., V. Esposito, J. Lenzi, M. Piccirilli, R. Delfini, and G. Cantore. 2005. Long-term follow-up of intramedullary spinal cord tumors: a series of 202 cases. *Neurosurgery* 56 (5):972-81; discussion 972-81.
33. Sala, F., A. Bricolo, F. Faccioli, P. Lanteri, and M. Gerosa. 2007. Surgery for intramedullary spinal cord tumors: the role of intraoperative (neurophysiological) monitoring. *Eur Spine J* 16 Suppl 2:S130-9.
34. Shrivastava, R. K., F. J. Epstein, N. I. Perin, K. D. Post, and G. I. Jallo. 2005. Intramedullary spinal cord tumors in patients older than 50 years of age: management and outcome analysis. *J Neurosurg Spine* 2 (3):249-55.
35. Sun, J. J., Z. Y. Wang, J. C. Xie, Z. D. Li, C. C. Ma, B. Liu, and J. Z. Zhao. 2010. [Comparative analysis between multi-segments intramedullary spinal cord congenital tumors and benign ependymomas]. *Beijing Da Xue Xue Bao* 42 (2):183-7.
36. Sun, J., Z. Wang, Z. Li, and B. Liu. 2009. Microsurgical treatment and functional outcomes of multi-segment intramedullary spinal cord tumors. *J Clin Neurosci* 16 (5):666-71.
37. Sze, G., G. Krol, R. D. Zimmerman, and M. D. Deck. 1988. Intramedullary disease of the spine: diagnosis using gadolinium-DTPA-enhanced MR imaging. *AJR Am J Roentgenol* 151 (6):1193-204.
38. Sze, G., G. K. Stimac, C. Bartlett, W. P. Dillon, V. M. Houghton, W. Orrison, F. Kashanian, and H. Goldstein. 1990. Multicenter study of gadopentetate dimeglumine as an MR contrast agent: evaluation in patients with spinal tumors. *AJNR Am J Neuroradiol* 11 (5):967-74.
39. Takemoto, K., Y. Matsumura, H. Hashimoto, Y. Inoue, T. Fukuda, M. Shakudo, Y. Nemoto, Y. Onoyama, T. Yasui, A. Hakuba, and et al. 1988. MR imaging of intraspinal tumors--capability in histological differentiation and compartmentalization of extramedullary tumors. *Neuroradiology* 30 (4):303-9.
40. Taricco, M. A., V. M. Guirado, R. B. Fontes, and J. P. Plese. 2008. Surgical treatment of primary intramedullary spinal cord tumors in adult patients. *Arq Neuropsiquiatr* 66 (1):59-63.
41. Waldron, J. S., and S. Cha. 2006. Radiographic features of intramedullary spinal cord tumors. *Neurosurg Clin N Am* 17 (1):13-9.
42. Wang, Z., and A. Liu. 1999. [Differential diagnosis and operative timing of intramedullary spinal cord tumors]. *Zhongguo Yi Xue Ke Xue Yuan Xue Bao* 21 (2):88-93.
43. Yang, S., X. Yang, and G. Hong. 2009. Surgical treatment of one hundred seventy-four intramedullary spinal cord tumors. *Spine (Phila Pa 1976)* 34 (24):2705-10.