

A rare case of severe craniocerebral trauma with penetrating head injury

A. Iordache¹, J.M. Kaya², J.R. Alliez², B. Alliez²

¹MD, PhD student in Neurosurgery, “Gr.T. Popa” University of Medicine and Pharmacy, Iasi

²Service de Neurochirurgie, Hopital Nord, Marseille

Abstract

Penetrating head injury remains an important issue even in modern neurosurgery. Less frequent than other neurosurgical diseases, they may still pose some management problems. The authors present one extremely rare case of suicide attempt by penetrating head injury with harpoon at a male middle aged patient associated with iatrogenous pneumothorax. Operated with a simple occipital craniectomy, the patient had a pretty good recovery with minimal neurological deficit (facial paresis).

Keywords: harpoon, penetrating head injury

Head injuries represent only a small percentage of cranio-cerebral traumas; however, they come into prominence through their clinical gravity and often through the atypical therapeutic strategies they require. Out of the total head injuries, the number of autolytic attempts is relatively small, most of them being represented by aggressions or road accidents.

Next, we are going to present the case of a patient aged 58, C.I., who was taken from home with a GCS (Glasgow coma scale) of 7; the clinical examination presents a harpoon (approximately 1.5 meters long)

which penetrates the skull base through the oral cavity. The patient has a history of chronic alcoholism, depression and multiple antolytic attempts by drug intoxication, also being under specific psychiatric treatment. According to therapeutic protocol, the ambulance doctor tried during the transportation to intubate the patient without any success. On admission to the intensive care unit, the patient has a GCS of 6 and a reduction in bilateral vesical murmur with a SaO₂ of 65%. The patient undergoes a tracheostomy.

Case presentation

The patient had a full-body scan and a cerebral angiography. Both the clinical examination and the CT exam, together with the ultrasound examination show a traumatic pneumothorax, and the cerebral angiography shows the presence of a metallic foreign body (the patient had no cerebrovascular lesions).

The drainage of pneumothorax had been done in emergency and after that it could be seen an improvement in the O₂ saturation level (96%). After that, it has been decided on the emergency neurosurgical intervention.

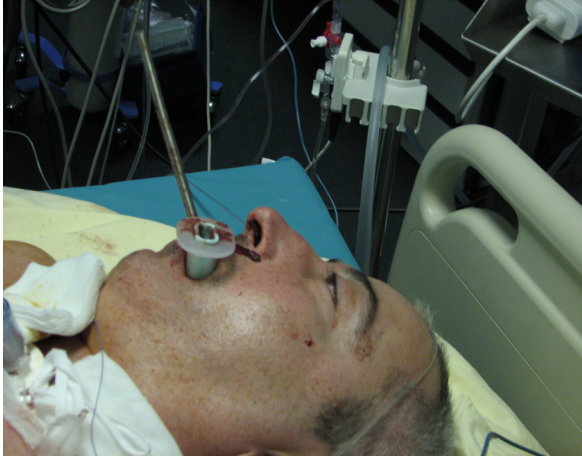

Figure 1 Harpoon penetrating the oral cavity

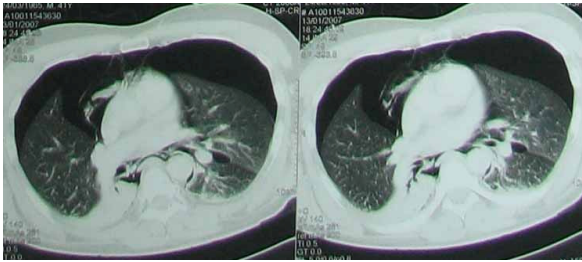
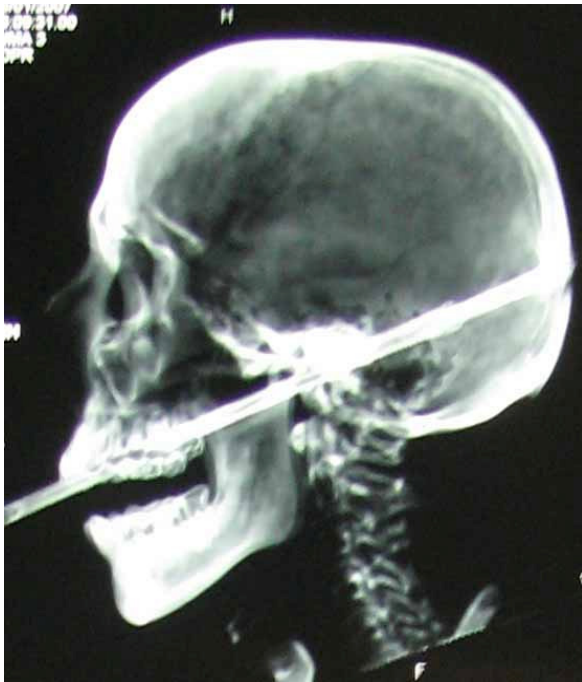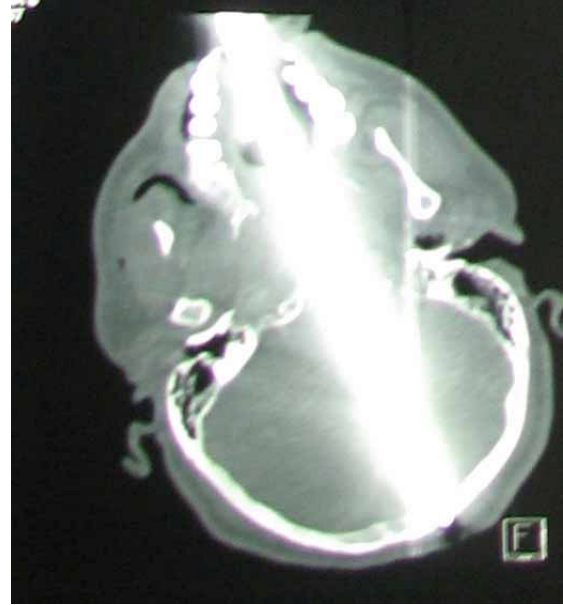


Figure 2 Bilateral traumatic pneumothorax



A



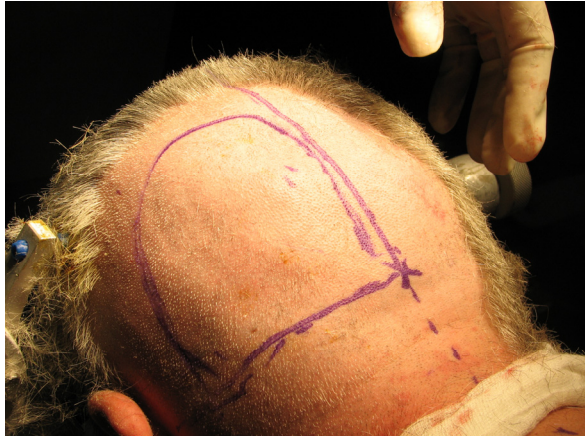B

Figure 3 Metallic object with upward, posterior trajectory, situated left paramedian, which crosses the pharynx, the clivus and the occiput – numerous artefacts

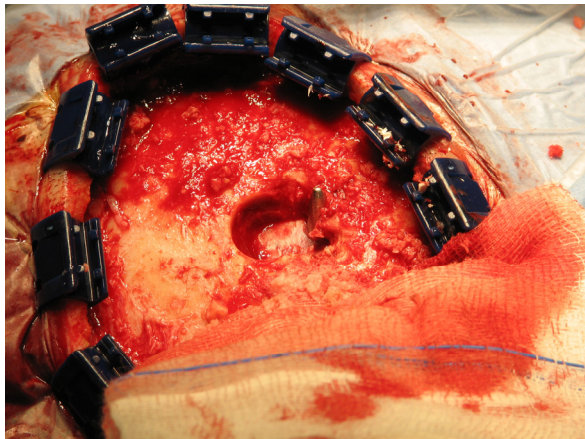
The surgical intervention could be undergone only after cutting off another 2 cm from the harpoon which protrudes at the oral cavity level. It was chosen a left paramedian approach to allow both a supra and subtentorial approach. It was practiced a paramedian semicircular cutaneous flap (Figure 4A). A minimum fracture site is identified on the left occipital. It was practiced the drilling to the occipital bone (Figure 4B) near the harpoon tip and afterwards the end of the harpoon was released. What follows next is the axis traction in one direction in order to prevent further brain injuries caused by the harpoon's socket piece (Figure 4C).

The postoperative evolution is marked by the presence of a cerebellar syndrome marked by ataxia and dysarthria (possibly due to the interception of superior cerebellar peduncle) but also by the presence of facial nerve paralysis on the left side.

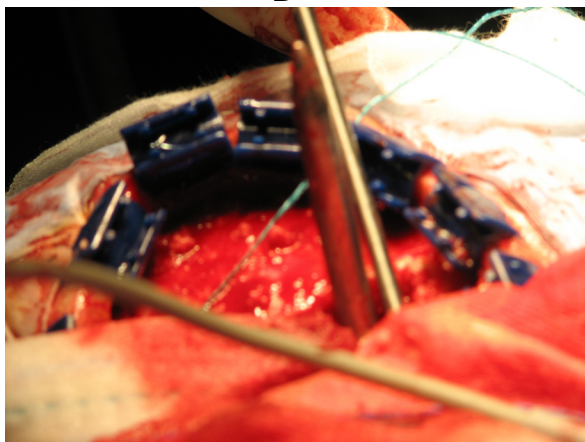
Afterwards, the cerebellar disorders present a significant improvement; however, the patient still had central facial paralysis after 6 months.



A



B

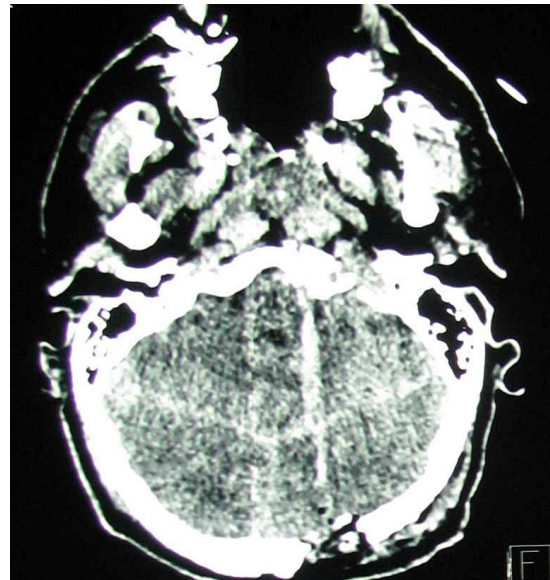

C

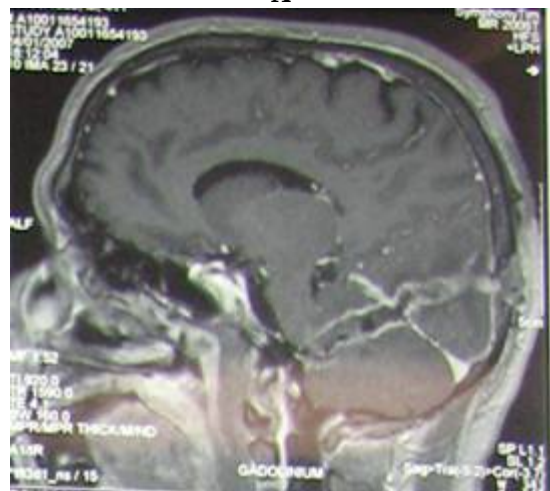


D

Figure 4 Left paramedian approach



A



B

Figure 5 A Craniocerebral CT after 2 weeks; B Brain MRI after 4 months

CT and MRI exams after 2 weeks and 4 months respectively show disabling injuries and left paramedian scars without vascular lesions or blood collections on the foreign body trajectory.

Cranio-cerebral injuries by a harpoon lance are very serious most of the time. They are most of the time the result of accidental injuries – especially fishing. The case we have presented so far – transfixiant wound occipital bone clivus by a harpoon lance for suicidal purpose represents an extremely rare case (after a long bibliographical research in the field), if not a unique case. The patient showed no vascular or infectious complications as a result of the injury.

The patient demonstrated good evolution in the surgical context but the prognosis remains questionable due to his mental illness and suicidal history, even in conditions where the patient would remain under psychiatric supervision for a long time.

In such case, similar to gunshot wounds, the essential of the management is to remove the foreign object with minimum of injury, associated with the excision of the necrotic brain tissue surrounding the trajectory of the foreign body and eventually the blood clots. Good haemostasis is compulsory and watertight suture of the duramater is necessary eventually with duraplasty in order to avoid secondary dural fistula – a common complication of the lesions in the posterior fossa. In the presented case there was no need for duraplasty because of the minimal laceration of the dura (only the tip of the harpoon was penetrating the dura) and was no need to remove bone fragments because there was only a minimal extrusive fracture of the occipital bone. In this case anterior

CSF fistula was prevented by the early intubation with pharyngeal tenting, immediately after the removal of the foreign body.

These kind of penetrating head injuries are quite rare though we had another case at a paediatric patient, with a less good result at long term. In the paediatric patient the mechanism was also trans pharyngeal penetration, but accidental.

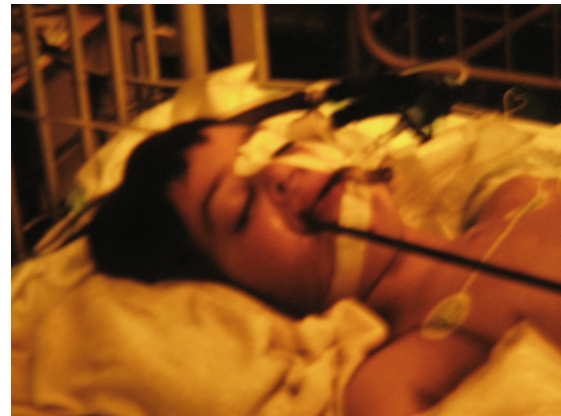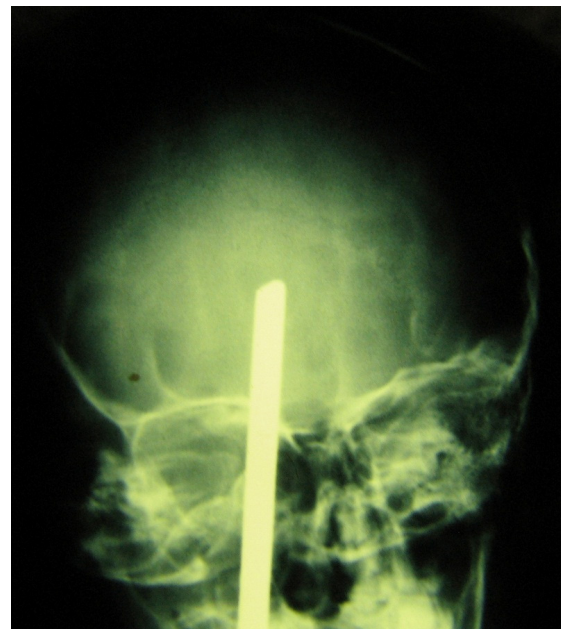
**A****B**

Figure 6 Transpharyngeal intracranial penetrating harpoon in a paediatric patient

References

1. Camperon F., Borne G., Graille R., Cristau P. - Orbito-cranio-cerebral injury by an underwater harpoon lance - *Presse Med.* 1967;75(48):2465-6
2. Fernandez-Melo R., Moran A.F., Lopez-Flores G., Bouza-Molina W., Garcia-Maeso I., Benavides-Barbosas J. - Penetrating head injury from harpoon. Case report; *Neurocirugia (Astur)*. 2002;13(5):397-400.
3. Gutierrez A., Gil L., Sahuquillo J., Rubio E. - Unusual penetrating craniocerebral injury - *Surg Neurol.* 1983; 19(6):541-3.
4. Hefer T., Joachims H.Z., Loberman Z., Gdal-On M., Progas Y.; Harefuah - Facial injury by fishing harpoons - *Harefuah.* 1994;127(9):295-8, 360
5. Janeke S. - An unusual craniofacial injury. A case report - *Afr Med J.* 1984 4;66(5):190;
6. Lopez F., Martinez-Lage J.F., Herrera A., Sanchez-Solis M., Torres P., Palacios M.I., Poza M. - Penetrating craniocerebral injury from an underwater fishing harpoon - *Childs Nerv Syst.* 2000;16(2):117-9;
7. Roman F., Salgado-Pineda P., Bartres-Faz D., Sanchez-Navarro J.P., Martinez-Lage J., Lopez-Hernandez F., Bargallo N., Junque C. - Orbito-cranio-cerebral injury by an underwater harpoon lance - *Presse Med.* 1967, 18;75(48):2465-6.
8. Rocca A., Casu G., Sechi C.S. - Penetrating craniocerebral injuries. Report of two unusual cases - *J Neurosurg Sci.* 1987;31(1):19-21;
9. Windle-Taylor P.C. - Transorbital injury from a harpoon involving the paranasal sinuses - *J Otorhinolaryngol Relat Spec.* 1978;40(5):278-84