

Cranio-cerebral gunshot wounds

C. Majer¹, G. Iacob²

¹Neurospinal Hospital Dubai, EAU

²Neurosurgery Clinic, Universitary Hospital Bucharest, Romania

Abstract

Cranio-cerebral gunshots wounds (CCGW) are the most devastating injuries to the central nervous system, especially made by high velocity bullets, the most devastating, severe and usually fatal type of missile injury to the head.

Objective: To investigate and compare, using a retrospective study on five cases the clinical outcomes of CCGW. Predictors of poor outcome were: older age, delayed mode of transportation, low admission CGS score with haemodynamic instability, CT visualization of diffuse brain damage, bihemispheric, multilobar injuries with lateral and midline sagittal planes trajectories made by penetrating high velocity bullets fired from a very close range, brain stem and ventricular injury with intraventricular and/or subarachnoid hemorrhage, mass effect and midline shift, evidence of herniation and/or hematomas, high ICP and/or hypotension, abnormal coagulation states on admission or disseminated intravascular coagulation. Less harmful effects were generated by retained missiles, bone fragments with CNS infection, DAI lesions and neuronal damages associated to cavitation, seizures.

Material and methods: 5 patients (4 male and 1 female), age ranged 22-65 years, with CCGW, during the period 2004-2009, caused by military conflict and accidental firing. After initial resuscitation all patients

were assessed on admission by the Glasgow Coma Scale (GCS). After investigations: X-ray skull, brain CT, Angio-CT, cerebral MRI, SPECT; baseline investigations, neurological, haemodynamic and coagulability status all patients underwent surgical treatment following emergency intervention. The survival, mortality and functional outcome were evaluated by Glasgow Outcome Scale (GOS) score.

Results: Referring on five cases we evaluate on a retrospective study the clinical outcome, imagistics, microscopic studies on neuronal and axonal damage generated by temporary cavitation along the cerebral bullet's track, therapeutics, as the review of the literature. Two patients with an admission CGS 9 and 10 survived and three patients with admission CGS score of 3, with severe ventricular, brain stem injuries and lateral plane of high velocity bullets trajectories died despite treatment.

Conclusion: CCGW is the most devastating type of missile injury to the head. Aggressive intensive care management in combination with early management with less aggressive meticulous neurosurgical technique, has significantly reduced the mortality and morbidity associated with these injuries, but they still remain unacceptably high. Primary prevention of these injuries remains important, the patient must be monitored closely for possible

complications.

Keywords: crano-cerebral gunshot wounds (CCGW), high velocity bullets, neuronal damage, cavitation, DAI lesions

Cranio-cerebral gunshot wounds (CCGW) produce devastating injuries to the central nervous system structures, such as tangential, perforating and penetrating (1) (2) (3), especially by high velocity bullets crossing in the lateral, midline, sagittal (2-6), which are the most severe and usually fatal type of missile injury to the head.

Material and methods

Five patients (4 male and 1 female), age ranged 22-65 years, with CCGW, during the period 2004-2009, caused by military conflict and accidental firing, underwent emergency intervention in Dubai – 4 cases and Romania – 1 case. Transportation was initial made by ambulances with low equipment; after resuscitation, assessed by the Glasgow Coma Scale (GCS) all patients were evacuated by plane. Assessed on admission by the Glasgow Coma Scale (GCS) two patients has a CGS of 9, respectively 10 and three patients has a CGS score of 3.

X-ray skull and CT in bone window demonstrated in all patients bone defects, different fractures types, intact or fragmented missiles, pneumocephalus (fig. 1). Cerebral CT scan revealed multilobar injuries made by penetrating high velocity bullets, mass effect and midline shift, evidence of herniation and/or hematomas. Brain stem and ventricular injury with intraventricular and subarachnoid hemorrhage were described in two cases, also retained missiles, bone fragments. The lethal wounds were bitemporal, temporo-

occipital; less aggressive in frontal, parietal wounds without dural venous sinus tears. In two cases were the missile trajectory traverses through the middle cerebral artery, cerebral angiography was performed, to exclude development of a possible pseudoaneurysm or dural sinus tear. Also cerebral MRI, SPECT (Figure 1) was performed three weeks after shooting in two survived cases with neuronal damages associated to cavitation, seizures, ischemia, DAI lesions. Baseline investigations, neurological, haemodynamic and coagulability status were performed in all cases. Compatible blood transfusion, treatment of coagulopathy and shock, antibiotics and anticonvulsant were used; intracranial pressure monitoring was performed in 4 patients placed intraparenchymal cavities created after blood clots evacuation.

Results

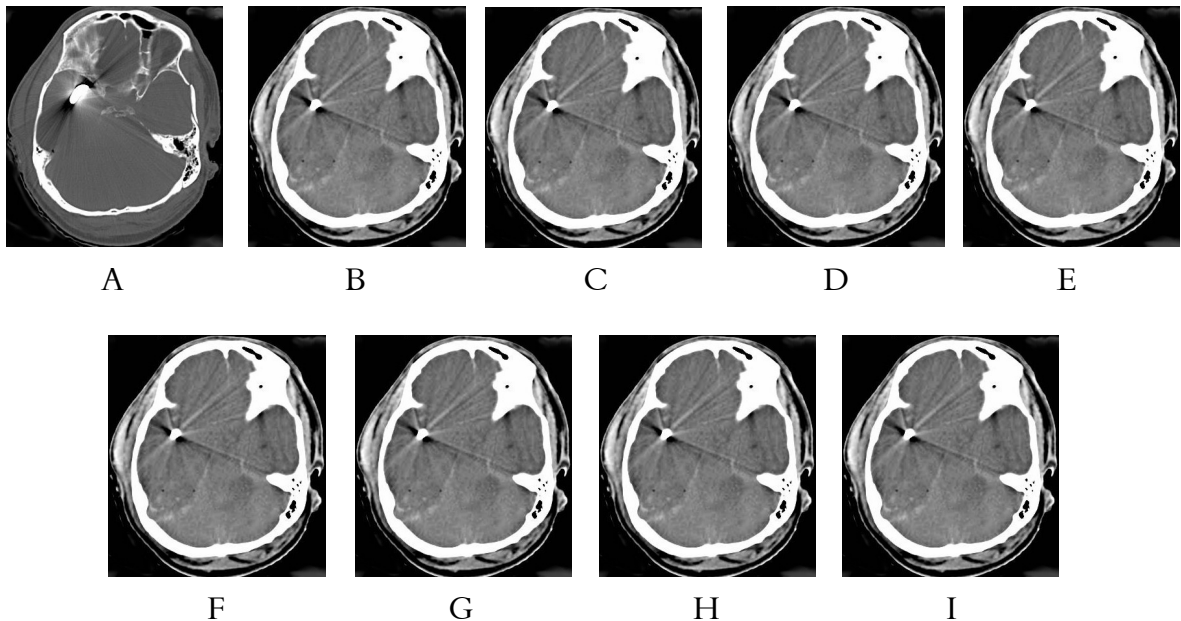
All patients underwent surgical treatment including primary closure of the wounds, debridement of skin, hairs, necrotic tissues, removal of hematomas, accessible and visible missiles and bone fragments, haemostasis, duraplasty. No attempts were made to chase any indriven inaccessible bone and missile fragments, in order to avoid additional insult to injured brain. In two cases bullets were intact (20 and 30 mm length, 10 and 14 mm in diameter, 10 and 16 g in weight), but three others deformed, mushroomed and fragmented. Therapy with broad spectrum antibiotics, anticonvulsants, mannitol was started to all patients. Three patients with bitemporal, temporo-occipital injury died in the first 48 hours postoperatively despite emergency intervention and surgical treatment by early respiratory arrest. In this

cases brain swelling with midline shift were seen resistant to therapy. For two patients with moderate hemiparesis a rehabilitation program was started. One year after, their medical condition improved, but unable to gain initial activities; continuing anticonvulsant therapy with depakine for seizures, without another postoperative complications.

A forensic neuropathologist reconstruction of brain injuries was made for the three patients who died based on: macroscopic findings referring on entrance and exit wounds, the missile track and secondary changes correlated to CT reconstruction. Microscopic evaluation of the zones of cellular and axonal destruction around the permanent track corresponding to the temporary cavity were performed on three cases. We found that the most dangerous trajectories of high velocity bullets were bitemporal and temporo-occipital; also areas of hemorrhagic

extravasations surrounding the permanent track, extended about 24–28 mm radially, nerve cells and astrocyte destructions, broken axons into fragments.

Illustrative case: P.C. aged 25 years old was cranio-cerebral gun shot with high velocity bullets fired by a sniper, in Afganistan, on 18.07.2007. The patient developed immediate deep coma and dilated pupils, he was intubated and mechanical ventilated. Transferred to Dubai on 19.07.2007 at admission he presented: GCS 3, bilateral mydriasis, no reflexes, intubated, mechanical ventilated, with Dopamine and cephalosporines infusion. The patient was explored: cerebral CT, cerebral angio CT, SPECT.; an ICP monitoring and a radical debridement of entry point was performed. Despite all medical aids he died on 19.07.2007. A postmortem detailed reconstruction of his brain injuries was performed.



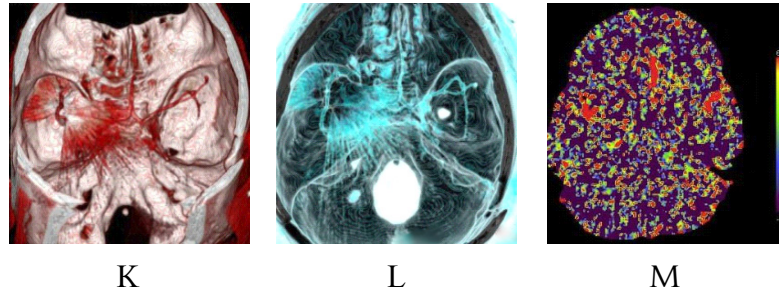


Figure 1 A-B cerebral CT scan showing missile in right temporal area; **C** cerebral CT scan with missile in parieto-occipital area; **D** CT scan shows the skull fracture underlying cerebral contusion and an intrusive parietal bone fragment, **E-G** axial cerebral CT scan showing haemorrhagic missile tracks with adjacent small cerebral contusions; **H-I** temporo-parietal peritentorial bullet on axial and coronal reconstruction cerebral CT scan **K-L** angio-CT scan 3D shows metallic bullets in both hemispheres, no pseudoaneurysm or dural sinus tear, **M** SPECT with severe cerebral ischemia

Discussions

Cranio-cerebral gunshot wounds (CCGW) are the most devastating injuries in humans, affecting central nervous system structures, representing a real concern to the community as a whole (1) (2) (6). CCGW could be: penetrating - in which a projectile breaches the cranium but does not exit it, made by low-velocity bullets as air rifle, projectiles, nail guns used in construction devices, stun guns used for animal slaughter, shrapnel produced during explosions, but also perforating - in which the projectile passes entirely through the head, leaving both entrance and exit wounds, by high-mass and velocity metal-jacket bullets fired from military weapons, or guns fired from a very close range as in aggression or suicide attempts (2) (3) (6-12) (14).

Approximately 2 million traumatic brain injuries occur each year and an approximate 50% of all trauma deaths are secondary to traumatic brain injury and gunshot wounds to the head caused 35% of these mortalities (1) (4). The magnitude of this problem in the United States (4) (6-8): 230 million fire arms in circulation, generating > 700000

injured cases each year, in peaceful time, by firearm-related violence, 24000 deaths, representing the fourth leading cause of death in the United States and the leading cause of death in persons aged 1-44 years. This magnitude is similar with all American losses during Vietnam conflict (4); a injury from firearms made the victim of a gunshot wound to the head 35 times more likely to die than is a patient with a comparable nonpenetrating brain injury.

Cranio-cerebral head injuries (1) (4) (7) are known since 1700 BC in Egyptian papyrus referring to 4 cases of depressed skull fractures treated by anointing the scalp wound with grease, leaving the wound unbandaged, providing free drainage of the intracranial cavity. Hippocrates (460-357 BC) performed trephination for contusions, fissure fractures, and skull indentations. Galen's experience in 130-210 AD treating wounded gladiators led to recognition of a correlation between the side of injury and the side of motor loss. Thought for the centuries incurable, cranio-cerebral head injuries had a high mortality rate: about 76% in Homer's era around 700 BC, 73,9% in the Crimean war

and 71,7% in the American Civil war (4). In the 17th century, Richard Wiseman assesses that deep wounds had a much worse prognosis than superficial ones, recommended the evacuation of subdural hematomas and the extraction of bone fragments – cited by (4). Important advances in the management of cranio-cerebral injuries in the mid-19th century who dramatically reduced the incidence of local and systemic infections, as well as mortality were related to the work of: Louis Pasteur (1867), Robert Koch (1876) in bacteriology and Joseph Lister (1867) in asepsis (3) (4) (6). Using Harvey Cushing's measures (1-3) (9-13) since the first world war as: aggressive and meticulously initial debridement all devitalized tissue, removing metal and bone fragments of missile track, exploring the intradural space, watertight closure of dural lacerations was advocated to reduced the rate of infections, abscess formation and the mortality rate dropped from 56% to 28% (9) (13). During World War II despite CCGW made by high muzzle velocity missiles with very high mass, low-velocity shrapnel wounds, extensive destruction of tissues, the mortality rate was lower: 14% with the advent of antibiotics and 9,7% in Vietnam War (1-3) (7-10). CCGW has been changed from one uniquely military to broadly civilian concern in several countries firearms (see Irak, Yemen a.s.o) considered part of the personality of men, present in hands of most of population and used for many purposes as parties, social conflicts, protecting farms and for entertainments (9). However a higher mortality rate are in military CCGW(1-3) (8) (11) (12) justified especially by differences in wound ballistics. The new military medicine history has noticed a higher mortality rate:

26% Iraq-Iran war and Lebanon war – despite CT scanning, respectively 32% with bullets and 10,6% with shrapnells in the last Yugoslav Civil war, generated by improvements in weapons technology, especially by the use of snipers (2) (8).

After the bullet penetrates the outer and inner tables of the skull, it crosses whole brain structures crushing tissues and a percussion wave is transmitted throughout the brain, causing temporary cavitation, radial tissue displacement, shearing, compression and stretching of cerebral tissue (15). The intracranial effect varies from isolated soft tissue to an "explosive" type of injury with comminuted fractures of the skull or bullet fragments generating laceration of the brain (1) (3) (11), also widespread destruction of neuronal cell membranes, which depends on the physical properties of the projectile, but also by its ballistics (12) (15-18). The enhanced effects of temporary cavitation is generating an enlarged zone of disintegrated tissue, high intracranial pressures expressed morphological by cortical contusion zones, indirect skull fractures and perivascular haemorrhages remote from the tract. Varying degrees of cavitation in the brain occur along the bullet's path, usually several times larger than the diameter of the bullet (1) (3) (5) (17) (18). In addition to the primary destruction of brain tissue readily visible at autopsy (permanent track), gunshot wounding to the brain creates a pulsating temporary cavity due to radial expansion along the bullet's track. Surrounding the permanent track, extended about 20 mm radially, a mantle-like zone of astrocyte destruction was found within an area of hemorrhagic extravasation. (18); nerve cells are shrunken; axons had been broken into tiny fragments (19), exhibiting

varicose changes and clumping. The extent of traumatic bleeding could be remarked along the track from entry point to exit point by the temporary cavitation - a destruction zone of ca. 3.6 cm around the permanent track, loss of glial fibrillary acid protein expression by astrocytes in the white matter. (17) (18)

After CCGW frequently seen effects are: neurodeficits, brain swelling with ICP rise, CSF leaks with severe infections, carotico-cavernous fistulas, pseudoaneurysms correlated with morbidity and mortality (3)(9-12). Many CCGW are incompatible with life, but moderately injured patients more frequently are resuscitated and benefit from aggressive treatment of secondary mechanisms of injury. There is considerable variability among neurosurgeons currently as to what constitutes appropriate treatment of CCGW (3) (4) (10): Raimondi and Samuelson (1970) noted the difference in wound ballistics and offered a classification scheme based on initial neurologic assessment. Arendall and Meirowsky 1983 found that high mortality associated with penetrating wound of air sinuses can be reduced by prompt and radical debridement, Kaufman (14) appreciate the surgical debridement performed, the use of ICP monitoring and various medical therapies, Helling et al 1992 found that early surgical intervention seemed to result in better survival, Gonul 1997, Singh 2003 acute or delayed CSF leak highly correlated with intracranial infection (9) (12) Antibiotics are no substitute for early surgical debridement, a lower mortality rate reflects early triage and survivability decisions as much as treatment effectiveness (3) (13)

CCGW treatment comprised of four stages: immediate saving of life by the use

of various medical therapies, ICP monitoring, prevention of infection, preservation of the nervous tissue, restoration of anatomical structures, with radical debridement (4) (9). Duration of antiepileptics and antibiotics remains controversial, as does the use of hyperventilation, hypothermia, and steroids (9) (12). Use of jugular bulb catheters and transcranial Doppler is institution-dependent (9).

There are several predictors of poor outcome in CCGW, correlating with morbidity and mortality (1-6) (8-15): advanced age, high velocity missiles or handguns fired from a very close range as in suicide attempts, admission CGS score 3 and 4 (with mortality rates near 90% and rare satisfactory outcome), bilateral fixed dilated pupils with opac cornea, delayed and poor mode of transportation, apnea at admission, associated injuries to chest, abdomen and great vessels generating massive bleeding, haemodynamic instability (hypotension), postoperative rise in ICP, abnormal coagulation states on admission or even DIC, CT visualization of diffuse brain damage, bihemispheric, bitentorial, multilobar missile track with lateral > midline sagittal planes trajectories made by high velocity bullets fired from a very close range, brain stem and ventricular injury, ventricular and subarachnoid haemorrhage, vasospasm, mass effect and midline shift, evidence of herniation and/or hematomas greater than 15 ml.

Less harmful effects are generated by retained missiles, bone and hair intraparenchymal fragments with CNS infection, DAI lesions, pneumocephalus, and neuronal damages associated to cavitation, seizures (3) (9) (10) (13).

Conclusions

Aggressive intensive care management in combination with early management with less aggressive, meticulous, neurosurgical technique, when appropriate, already has significantly reduced the mortality and morbidity associated with these injuries, but they still remain unacceptably high .

Primary prevention of cranio-cerebral gunshot wounds remains important, the patient must be monitored closely for possible complications. With the increasing numbers of firearms and firearm-related violence in our society, discussing the issues of violence with patients and offering appropriate intervention becomes the duty of all health care providers.

References

1. Federico C Vinas - Penetrating Head Trauma: Multimedia, May 27, 2009
2. Antic B., Spaic M. – Penetrating Craniocerebral Injuries from the former Yugoslavia Battlefields, *Ind. J. Neurotrauma (IJNT)*, 2006, 3, 27-30
3. Iacob M., Iacob G. – Plagi craniocerebrale prin arma de foc, *Simpozionul de Neurochirurgie Cluj Napoca 1987*
4. Shaffrey M.E. et al. - Classification of civilian craniocerebral gunshot wounds: a multivariate analysis predictive of mortality, *J Neurotrauma*. 1992 Mar; 9, Suppl 1:S279-85.
5. Izci Y., Kayali H., Daneyemez M., Koxsel T. – Comparison of clinical outcomes between anteroposterior and lateral penetrating craniocerebral gunshot wounds, *Emerg. Med. J.* 2005, 22, 409-410
6. Rosenfeld J.V. – Gunshot injury to the head and spine, *J. Clin. Neurosci* 2002, 9, 9-16
7. Marshall L.F., Marshall S.B., Sean G.M. – Modern neurotraumatology: a brief historical review, in *Youmans Neurological Surgery*, Editor: Winn H.R., 5th Edition Saunders, 2004, 5019-5024
8. Spaic M., Branislav A. – The lost race, *Indian Journal of Neurotrauma* 2009, 6, 1, 1-4
9. Rashid B.A et al. – Analysis of 3794 civilian craniocerebral missile injuries – Results from 20 years of Kashmir conflict, *Pan Arab Journal of Neurosurgery*, 2010, 14,1, 24-32.
10. Meirowsky A.M. – Secondary removal of retained bone fragments in missile wounds of the brain, *J.Neurosurg.* 1982, 57, 617-621
11. Bakir A. et al. – High Velocity Gunshot Wounds to the head: analysis of 135 patients, *Neurol. Med. Chir (Tokyo)* 2005, 45, 281-287
12. Erdogan E., Gonul E., Seber N. – Craniocerebral gunshot wounds, *Neurosurg Q.* 2002, 12, 1-18
13. Gonul E., Baysefer A., Kahraman S. Et al. – Causes of infections and management results in penetrating craniocerebral injuries, *Neurosurg. Rev.* 1997, 20, 177-181
14. Kaufman H.H. – Civilian gunshot wounds to the head, *Neurosurg.* 1993, 32, 962-964
15. Karger B. – Penetrating gunshots to the head and lack of immediate incapacitation, *Wound ballistics and mechanisms of incapacitation, Int. J. Legal Med.* 1995, 108,(2), 53-61
16. Kim K.A., Wang M.Y., McNatt S.A. et al. - Vector Analysis Correlating Bullet Trajectory to Outcome after Civilian Through-and-Through Gunshot Wound to the Head: Using Imaging Cues to Predict Fatal Outcome, *Neurosurgery*, 2005: 737-747
17. Oehmichen M., Meissner C., Konig H.G., Gehl H. R. – Gunshot injuries to the head and brain caused by low velocity handguns and rifles; A. review, *Forensic science international, Congrès European Congress of Neuropathology No7, Helsinki, Finlande, 2004, vol. 146, nr.2-3, 111-120.*
18. Oehmichen M., Meissner C., Konig H.G. – Brain Injury after Gunshot Wounding: Morphometric Analysis of Cell Destruction Caused by temporary Cavitation, *Journal of Neurotrauma*. 2000, 17(2): 155-162.
19. Francisc A., Majer C., Iacob G. – Diffuse axonal injuries: clinical, neuroimaging and microscopic features- literature review, *Romanian Journal of Legal Medicine*, 2008, XVI, 3, 172-180