

## Giant extracranial liposarcoma – Case report

V. Pruna, Narcisa Bucur, Angela Neacsu, A. Giovani,  
Anca Buliman, M. Gorgan

First Neurological Clinic, Fourth Department of Neurosurgery  
Clinic Emergency Hospital “Bagdasar-Arseni” Bucharest

### Abstract

*Objective:* Anaplastic liposarcoma of the head is an extremely rare entity. Seventy-seven cases of head and neck liposarcomas have been reported in the world literature since 1911. Radical surgery is the form of treatment advised.

*Clinical presentation:* Authors report the case of a 62 years old female patient admitted in our institution for a giant extracranial tumor (122/88 mm), developed insidiously over a period of 3 years and neglected. The patient agreed surgery only for the epicranial tumor. The lesion was completely removed. Postoperative outcome was excellent concerning this tumor, although the histopathological result was not that great: high anaplastic liposarcoma.

*Conclusion:* Liposarcoma of the scalp is rare. Diagnosis is made histologically. The histopathologic variant influences clinical behavior and prognosis. The treatment of choice is wide surgical excision.

**Keywords:** giant tumors, anaplastic liposarcoma, surgical technique

Liposarcoma is a malignant mesenchymal neoplasm that arises from adipose tissue, most commonly in the retroperitoneum and lower extremities. Liposarcoma of the head and neck is rare, representing 5% to 9% of cases in large

series (2). Common sites of occurrence in the head and neck region include the larynx, hypopharynx, oral cavity, orbit, scalp and soft tissues of the neck. Liposarcomas rarely arise from a preexisting lipoma. Liposarcoma tumors are the most radiosensitive soft-tissue tumors.

The gross appearance of the tumor depends on the histologic type, degree of vascularity, presence of necrosis, and amount of mature fat and fibrous tissue. The tumor appears as a smooth, lobulated, or nodular mass, and in most instances, it is well encapsulated. However, the appearance of an encapsulated tumor may be misleading, because daughter nodules are often present around the main mass. Complete excision is not always possible because of the close association of the tumor with vital structures; therefore, the recurrence rate is high.

### Case presentation

Authors report the case of a 62 years old female patient admitted in our institution for a giant extracranial tumor, insidiously developed over a period of 3 years and neglected. She decided to undergo surgery for esthetic consideration in first place, neurological status being normal.

A giant epicranial medial-occipital mass (122/88 mm) (Figure 1) and two other masses: left parietal (25/20 mm), and left

cerebellopontine angle (18/12 mm) was seen on CT scan (Figure 2). On IRM cerebral the lesions was isodense in T1 and T2 weighted (Figure 3).

The patient agreed surgery only for the epicranial tumor, for cosmetic reason. The lesion was completely removed; care must be tacked to avoid excessive scalp removal or potential necrosis, and a good hemostasis was performed for prevent bleeding.

Postoperative outcome was excellent concerning this tumor, the wound healed normally. But the histopathological result was not that great: high anaplastic liposarcoma, with large necrotic, mixomatous and undifferentiated areas associated with fibrosarcomatous cells.

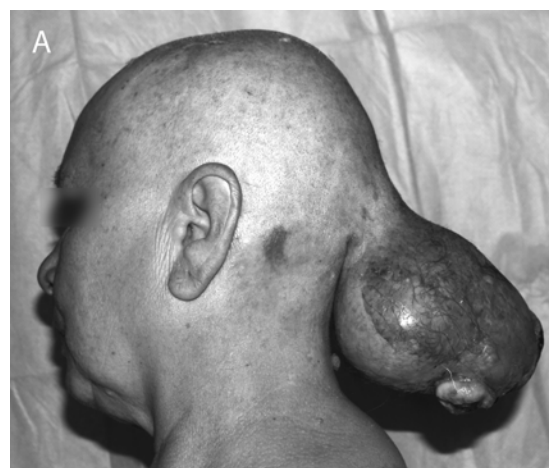
The case remains in observation for the other two intracranial tumors and the patient referred to oncologist.

## Discussion

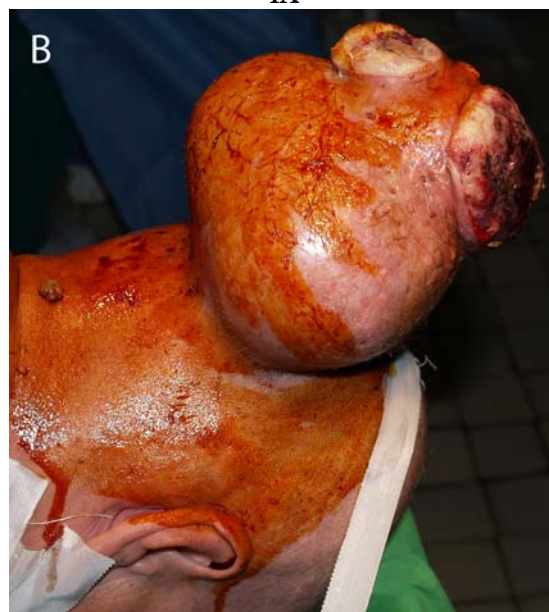
Liposarcoma can easily be misdiagnosed clinically; its relatively indolent course lead to often mistakes for lipoma (7), cyst or benign soft tissue tumors. Nonetheless, many authors report difficulty in distinguishing these entities (3) and therefore histopathology is required for an appropriate diagnosis (11).

The histologic characteristics that distinguish liposarcoma from intramuscular lipoma include the presence of cellular pleomorphism, mitotic activity, lipoblasts, and vascular proliferation (5). Currently, the World Health Organization distinguishes the four variants proposed by Enzinger and Weiss based on developmental stage of the lipoblasts and overall degree of cellularity and pleomorphism. These four entities are described as well-differentiated, myxoid, round-cell and pleomorphic. The WHO

also recognizes a fifth variant, dedifferentiated, to describe changes occurring within well-differentiated liposarcoma that correspond with more aggressive clinical behavior and poor outcome (9). Patients with well-differentiated and myxoid type tumors have higher 5-year survival rates and lower recurrence rates than patients with pleomorphic and round-cell types.

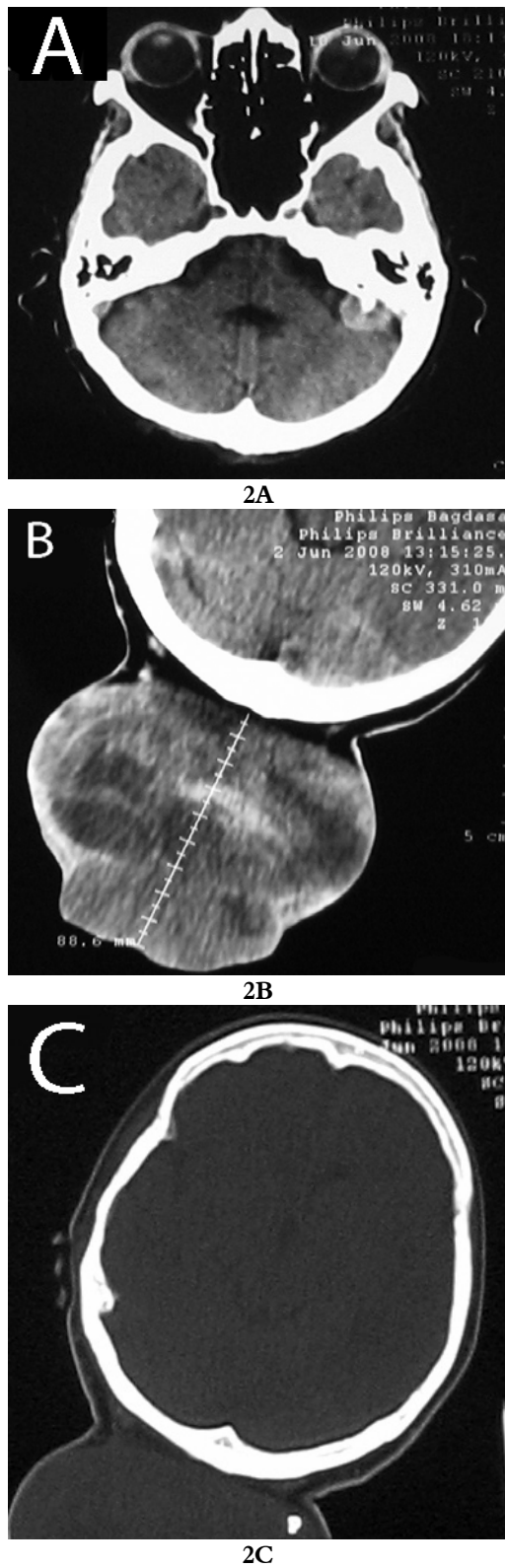


1A

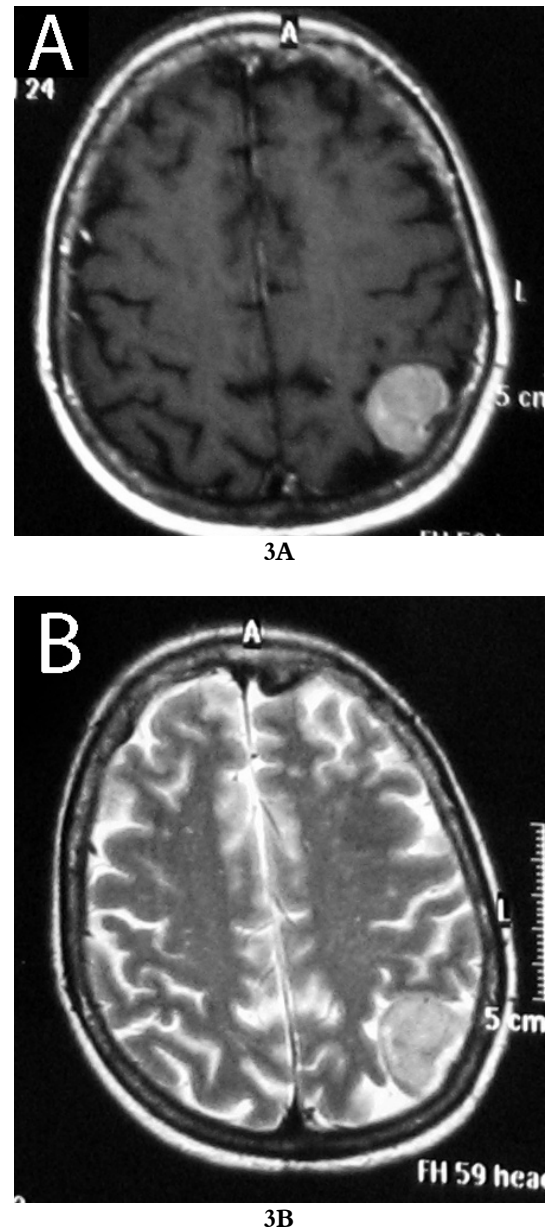


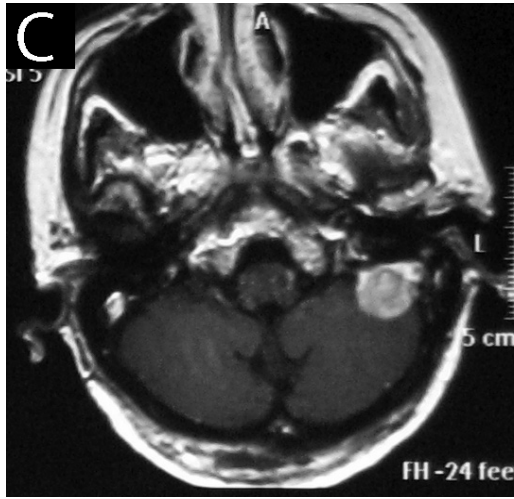
1B

Figure 1 A, B Preoperative photographs

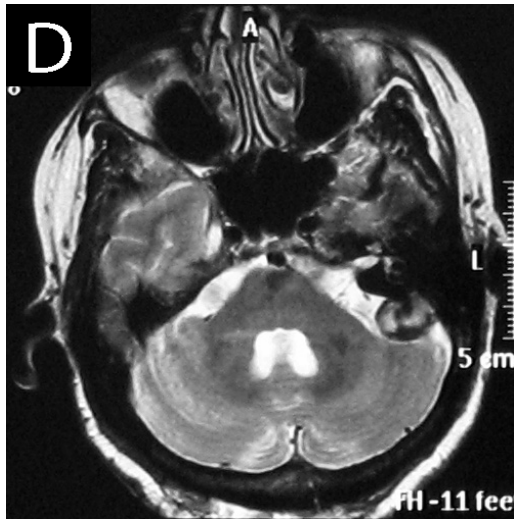


**Figure 2** CT brain. **A** intracranial tumor plated on the rear face of the left temporal cliff, 18/12 mm; **B**, **C** shows a giant epicranial occipital tumor mass (122/88 mm), spontaneous homogeneous, well defined, without reactive changes of the bone.

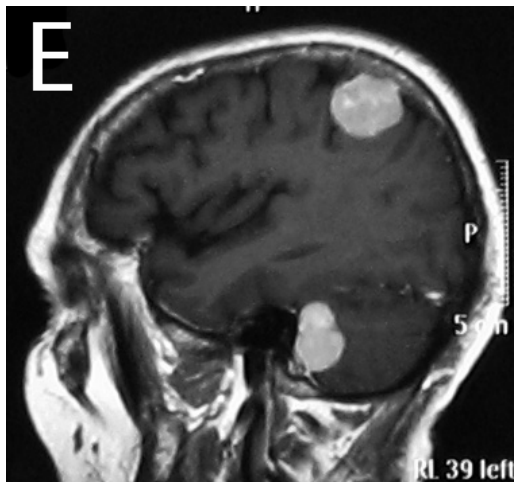




3C

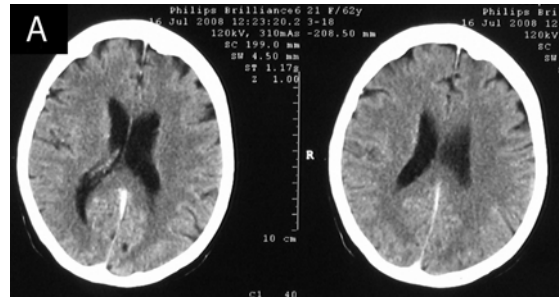


3D

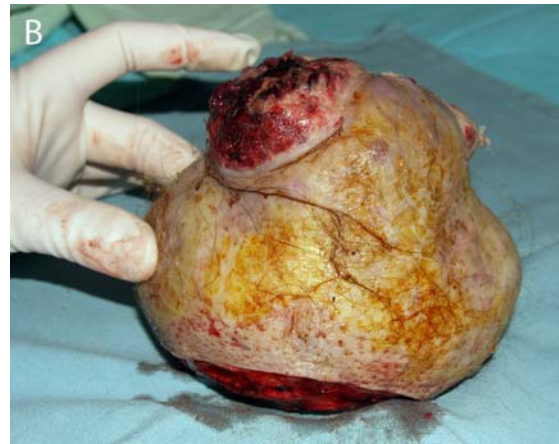


3E

**Figure 3** IRM cerebral shows 2 lesions: left parietal (25/20 mm) and rear face of the temporal cliff (18/12 mm). A, C, axial T1 weighted image; B, D, axial T2 weighted image; E, sagittal T1 weighted image.



4A



4B

**Figure 4** Postoperative pictures. A, CT scan; B, Postoperative photograph of the lesion.

The incidence of metastasis is also correlated with histologic type.

Wide surgical excision is the treatment of choice for liposarcoma. Recurrence rate increases from 17% to 80% with incomplete excision (8), as may occur when tumors are mistakenly believed to be benign lipomas (4). Although grossly these tumors appear to be encapsulated, they extend by infiltration; the likelihood of nearby satellite nodules necessitates wide excision (1). Lymph node dissection is not indicated unless there is concrete evidence of

metastasis, since the likelihood of nodal metastases in this disease is so rare (9).

Nonsurgical treatment modalities are of limited use in liposarcoma. The use of radiation therapy or chemotherapy remains controversial (10).

Prognosis of liposarcoma is influenced by three factors: histologic variant, adequacy of surgical excision, and location of the tumor (10). Golledge et al (6) found a relatively favorable prognosis for liposarcoma of the scalp, face and larynx as compared with the oral cavity, pharynx and neck. The role of tumor size in prognosis is unclear.

### Conclusion

In conclusion, liposarcoma of the scalp is rare. Diagnosis is made histologically. The histopathologic variant influences clinical behavior and prognosis. The treatment of choice is wide surgical excision. The scalp region represents a risk factor to the patient because the diagnosis is usually made late.

### References

1. Collins BT, Gossner G, Martin DS, Boyd JH: Fine needle aspiration biopsy of well differentiated liposarcoma of the neck in a young female. A case report. *Acta Cytol* 43:452-456, 1999.
2. Enterline HT, Culberson JD, Rochlin DB, Brady LW: Liposarcoma. A clinical and pathological study of 53 cases. *Cancer* 13:932-950, 1960.
3. Evans HL, Soule EH, Winkelmann RK: Atypical lipoma, atypical intramuscular lipoma, and well differentiated retroperitoneal liposarcoma: a reappraisal of 30 cases formerly classified as well differentiated liposarcoma. *Cancer* 43:574-584, 1979.
4. Fusetti M, Silvagni L, Eibenstein A, Chiti-Batelli S, Hueck S: Myxoid liposarcoma of the oral cavity: case report and review of the literature. *Acta Otolaryngol (Stockh)* 121:759-762, 2001.
5. Garavaglia J, Gnepp DR: Intramuscular (infiltrating) lipoma of the tongue. *Oral Surg Oral Med Oral Pathol* 63:348-350, 1987.
6. Golledge J, Fisher C, Rhys-Evans PH: Head and neck liposarcoma. *Cancer* 76:1051-1058, 1995.
7. Larson DL, Cohn AM, Estrada RG: Liposarcoma of the tongue. *J Otolaryngol* 5:410-414, 1976.
8. McCulloch TM, Makielski KH, McNutt MA: Head and neck liposarcoma. A histopathologic reevaluation of reported cases. *Arch Otolaryngol Head Neck Surg* 118:1045-1049, 1992.
9. Newlands SD, Divi V, Stewart CM: Mixed myxoid/round cell liposarcoma of the scalp. *Am J Otolaryngol* 24:121-127, 2003.
10. Pack GT, Pierson JC: Liposarcoma; a study of 105 cases. *Surgery* 36:687-712, 1954.
11. Wescott WB, Correll RW: Multiple recurrences of a lesion at the base of the tongue. *J Am Dent Assoc* 108:231-232, 1984.