

Endoscopic endonasal transsphenoidal approach in the management of sellar and parasellar lesions: alternative surgical techniques, results, complications (Part II)

Ligia Tataranu¹, M. Gorgan¹, V. Ciubotaru¹, Anica Dricu²,
Adriana Dediu¹, B. Ene¹, D. Paunescu¹, Andra Albert¹, V. Pruna¹

¹Neurosurgical Clinic, “Bagdasar-Arseni” Clinical Emergency Hospital, Bucharest, Romania

²University of Medicine and Pharmacy, Craiova, Romania

Abstract

The endoscopic endonasal transsphenoidal approach is a minimally invasive surgical technique for the removal of sellar and parasellar lesions. It allows panoramic vision of the surgical target and surrounding structures, with minimal trauma and a low complication rate. The procedure has been gaining in popularity in recent years. There are now surgical instruments intentionally conceived to respond to the specific characteristics of the neuroendoscopy.

The widespread use of the endoscope in transsphenoidal surgery has recently contributed to the extension of the approach superior, inferior or lateral. This expansion carries significant potential for the resection of skull base lesions. For selected patients, the various techniques of the endoscopic endonasal transsphenoidal approach are valid alternatives to transcranial approaches. Macroadenomas, suprasellar or even intraventricular craniopharyngiomas, tuberculum sellae or even planum sphenoidale meningiomas and clival tumors become accessible for removal via an endoscopic approach.

The authors review the main alternative

surgical techniques of the endoscopic endonasal transsphenoidal approach. They also present the results and the complications of the endoscopic transsphenoidal surgery. Due to an improvement and refinement of the surgical procedures, the endoscopic endonasal transsphenoidal approach can be considered a good choice for the excision of the sellar and parasellar lesions.

Keywords: craniopharyngioma, endoscopy, meningioma, minimally invasive surgery, parasellar lesion, pituitary tumor, sellar lesion, transsphenoidal surgery.

Endoscopic endonasal transsphenoidal surgery was developed in the past decade under minimally invasive strategy. This endoscopic approach of the sellar and parasellar lesions introduces various advantages compared with the transsphenoidal microsurgical approach. The endoscope is used as a unique optical device. A wide view of the surgical field is obtained through angled scopes. The standard procedure is performed through a parasseptal route, via an anterior sphenoidotomy, without the traditional mucosal incision. It does not require the

use of a transsphenoidal retractor or of an intraoperative fluoroscopic C-arm. Also, postoperative nasal packing have been proved unnecessary. Postoperative discomfort is minimal and the complication rate is low. The reduction in hospital stay significantly reduced the cost of patient's management. Endoscopic endonasal transsphenoidal surgery have been proved to be safe and effective.

The operative technique is now standardized. Standard endoscopic endonasal transsphenoidal approach uses a parasseptal route (between the middle turbinate and nasal septum) (Figure 1). The approach of the sphenoid rostrum is made between nasal septum and lateral luxated middle turbinate. The vomer and the nasal septum are detached from the sphenoid rostrum and moved contralaterally (Figure 2). Sometimes, the fracture of the vomer bone can be difficult.

However, changes in the standard technique are necessary in selected cases to optimize the surgical resection in minimally invasive conditions and to preserve anatomic structures [1]. One could use a minimal approach (hemisphenoidotomy), an extended or a bilateral approach (Table 1). In this paper, we present variations of the standard endoscopic procedure designed to customize it for different lesions.

1. Alternative surgical techniques of the endoscopic endonasal transsphenoidal approach

1. 1. Transseptal approach

Deep-transseptal approach is an alternative technique. The septal mucosa is incised medial to middle turbinate and the

cartilaginous septi is separated from the vomer. The contralateral septal mucosa is dissected from the contralateral surface of the vomer towards the sphenoidal rostrum. The vomer is removed and an anterior sphenoidotomy is performed. The mucosa from the ipsilateral part of the vomer is detached together with the vomer [2] (Figure 3).

1.2. Minimal approach

Particularly, in small intrasellar tumors developed in the inferior half of the sella turcica, the endoscopic approach can be minimal. Only a hemisphenoidotomy ipsilateral to the lesion is performed, the anterior wall of the sphenoid sinus is removed until the midline is reached, and then a partial opening of the sellar floor is performed [1, 3] (Figure 4). This technique is simpler when the interior septa of the sphenoid are absent or deviated, which is true for 75% of the cases [4].

This approach can be performed in GH-secreting or PRL-secreting microadenomas with a lateral location, but not in ACTH-secreting microadenomas, because they are often multifocal [1].

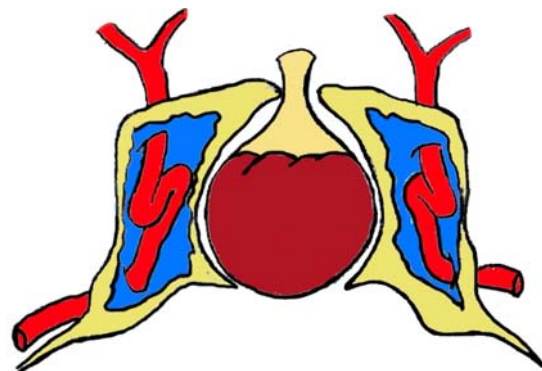


Figure 1 Standard opening of the sphenoid sinus and the sellar floor for the resection of a pituitary macroadenoma

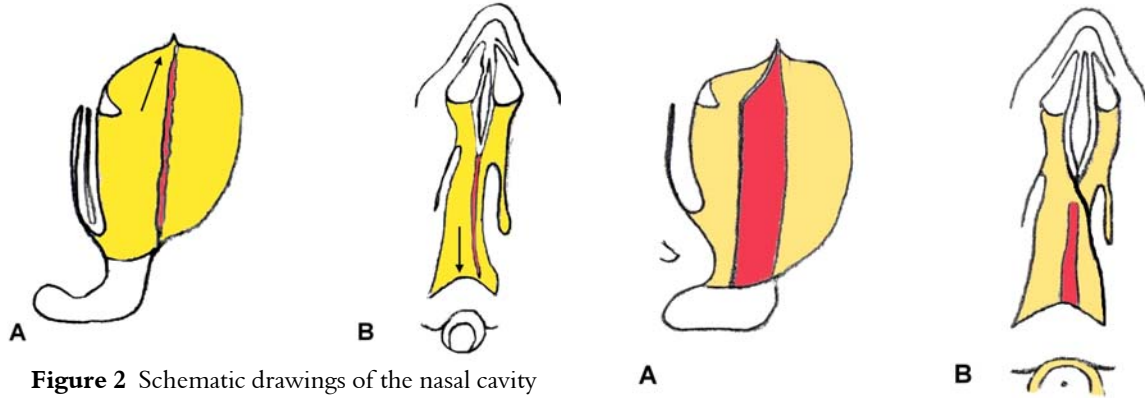


Figure 2 Schematic drawings of the nasal cavity depict coronal (A) and axial views (B) of a parasseptal approach to the sella. The nasal septum and vomer are detached from the rostrum of the sphenoidal sinus and an anterior sphenoidotomy hole is made (of approximately 1.5 cm in diameter)

Figure 3 Schematic drawings of the nasal cavity depict coronal (A) and axial views (B) of a deep-transseptal approach to the sella

Table 1 Alternative surgical techniques of the endoscopic endonasal transsphenoidal approach

Alternative surgical techniques of the endoscopic endonasal transsphenoidal approach		
Nr.	Approach Type	Surgical Route
1	Standard Approach	Endoscopic, unilateral, endonasal transsphenoidal route
2	Minimal Approach	Endoscopic, unilateral, endonasal transsphenoidal route with hemisphenoidotomy
3a	Extended Approach	Endoscopic, unilateral, transnasal transethmoidal transsphenoidal route
3b	Extended Approach	Endoscopic, endonasal transsphenoidal route with planum sphenoidale opening
3c	Extended Approach	Endoscopic, unilateral, endonasal transsphenoidal route with clival fenestration
3d	Extended Approach	Endoscopic, unilateral, transnasal, transethmoidal transsphenoidal route, with superior turbinectomy
4	Bilateral Approach	Endoscopic, bilateral, endonasal transsphenoidal route

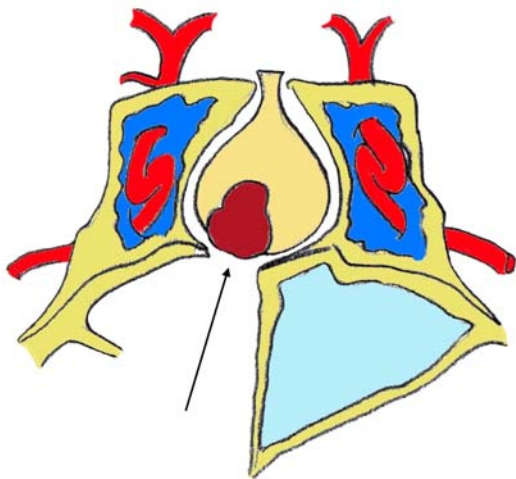


Figure 4 Hemisphenoidotomy performed via an endonasal ipsilateral approach for the resection of a laterally located microadenoma

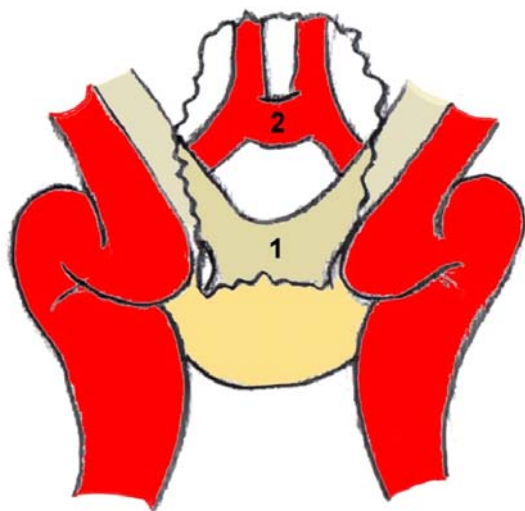


Figure 5 Opening of the superior part of the anterior sellar wall, extending to the posterior part of the planum sphenoidale. The optic chiasm (1) and the anterior communicating artery complex (2) are visible after opening of the dura

1.3. Extended approaches

The endoscopic endonasal transsphenoidal approach can be extended superior, inferior or lateral.

Superior extended approach is used for lesions developed in the posterior part of

the planum sphenoidale (meningiomas of the tuberculum sellae or small meningiomas of planum sphenoidale) and for lesions with a prechiasmatic extension (craniopharyngiomas and Rathke's cleft cysts) [1, 5]. The patient's head is slightly hyper extended. The anterior wall of the sellar floor and the posterior part of the planum sphenoidale (1 – 1.5 cm) are removed with a micro drill or micro punches. The dura is incised starting from the anterior sellar wall and extending to the posterior portion of the planum sphenoidale, after coagulation and sectioning of the superior intercavernous sinus. The prechiasmatic region is exposed (Figures 5, 6). The main challenge is the difficulty of obtaining a reliable watertight closure of the enlarged base opening.

Inferior extended approach is indicated in clival tumor (clival chordomas) [1, 6]. The patient's head is slightly flexed. Fenestration of the clivus, in the absence of any pathological lesion arising in or extending into this region, seems to be very difficult, because of rich vascularization from the dorsal meningeal artery and the basilar venous plexus and the presence of the paraclival internal carotid artery. When pathological lesions arising in or extending into the clivus are present, lesion removal is easier because of the displacement of these vascular structures [1] (Figure 7).

Lateral extended approach is performed in sellar lesions with important extension to the cavernous sinus, usually pituitary adenomas. If only the medial aspect of the cavernous sinus compartment is the site of the parasellar development of the lesion, then it is possible to treat the lesion from the contralateral nostril, by using the standard endoscopic procedure [1].

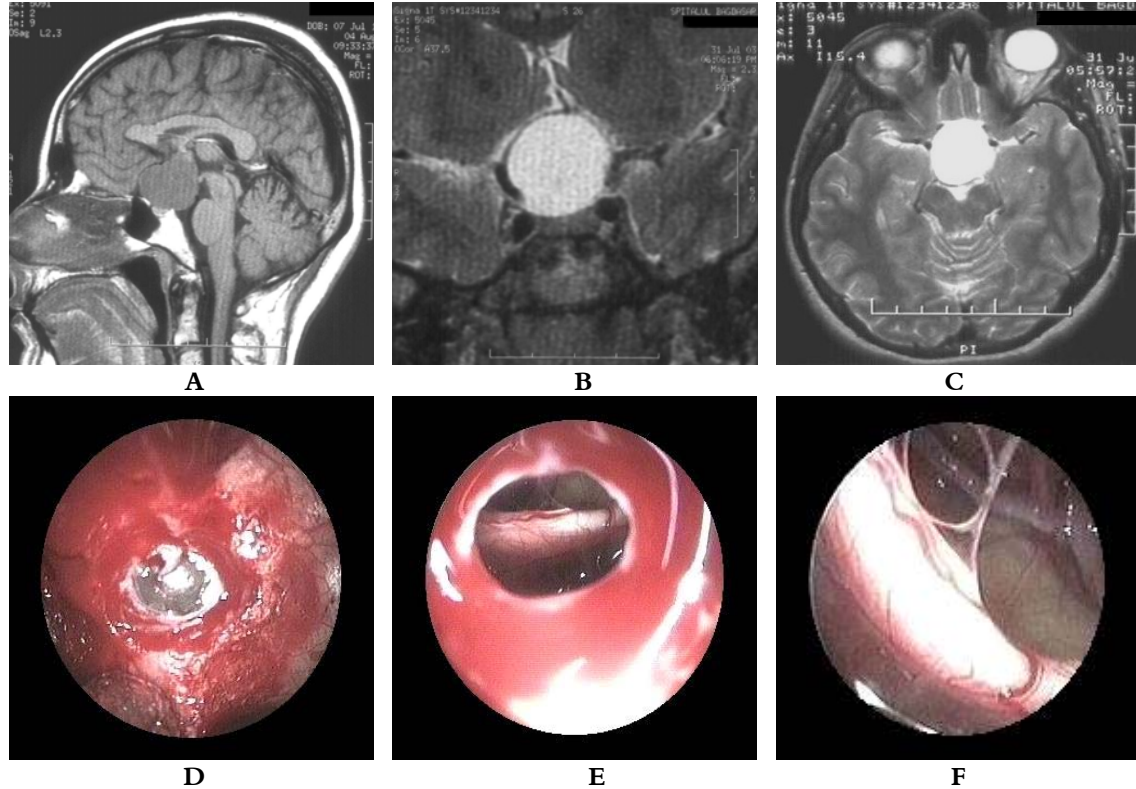


Figure 6 Cystic suprasellar craniopharyngioma. A, B, C – MRI images (in coronal view on observe anterior cerebral artery). D, E, F – Endoscopic views (superior extended endoscopic endonasal transsphenoidal approach). D – The capsule of the craniopharyngioma is visualized after opening of the sellar dura. E – The optic chiasm is visible. F - The optic chiasm and anterior cerebral artery complex are directly visible

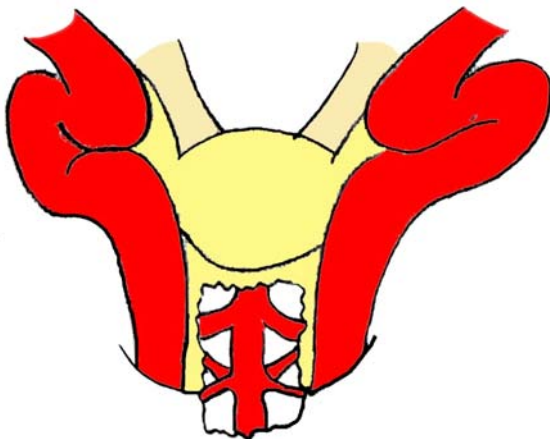


Figure 7 Opening of the lower part of the anterior sellar wall, extending to the upper clivus.

Fenestration exposes the basilar tip, the posterior cerebral arteries, the superior cerebellar arteries and the IIIrd cranial nerves

If the lateral aspect is also involved, it is necessary to extend the anterior sphenoidotomy, with removal of the superior turbinate, to expose the lateral wall of the sphenoid sinus. The removal of the superior turbinate must be performed with regard for the lateral lamella of the cribriform plate to avoid CSF leak. Additional room can be obtained with removal of the posterior ethmoid cell, with a limited maxillectomy and partial removal of the medial aspect of the pterygoid process [1] (Figure 8).

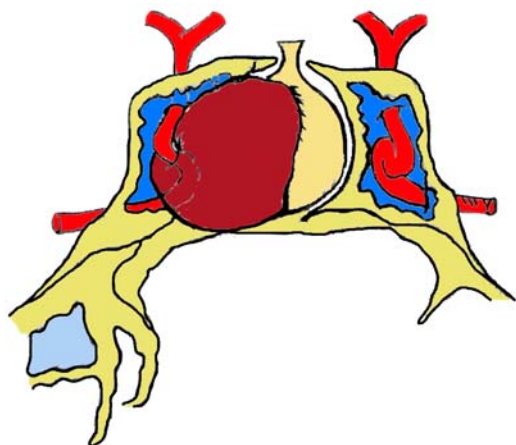


Figure 8 Lateral extended approach, with excision of the superior turbinate and opening of the posterior ethmoid cells, for removal of a lesion extending into the ipsilateral cavernous sinus. The dotted line indicates the commonly used sphenoidotomy by this route

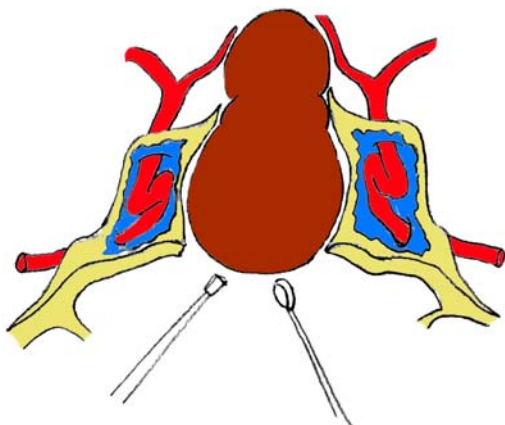


Figure 9 The bilateral approach can be indicated for the convergent action of instruments, especially to visualize and to reach the contralateral suprasellar region

1.4. Bilateral approach

Bilateral approach is used when the nostrils are very narrow (in children), when the combined actions of more than two instruments could facilitate bleeding control or lesion removal, when an opposite working angle of two instruments inside the sella could provide enhanced surgical effectiveness [1]. In these cases, it is

necessary to perform an extended anterior sphenoidotomy (Figure 9).

2. Results of the endoscopic endonasal transsphenoidal approach

The endoscopic endonasal transsphenoidal approach has the same efficiency as the microsurgical transsphenoidal approach. This procedure is a safe and effective method, with a low rate of complication and morbidity [7-10]. Minimal postoperative discomfort, quick recovery and short hospital stays of the patient have been noted [11-13].

Jho (2002) reports 200 patients treated with the endoscopic endonasal transsphenoidal approach [13]. Amongst them 160 had pituitary adenomas, 10 had skull base meningiomas, 8 had clival chordomas, and additional 22 had other skull base pathologies. 55 patients had previously undergone surgical treatment, radiation treatment or both. Amongst the 160 patients with pituitary adenomas, 37 (37.5%) patients had microadenomas and 123 (62.5%) patients had macroadenomas. Amongst the 90 patients with hormone-nonsecreting adenomas, 71 (79%) patients underwent gross total removal. Amongst the 38 patients with prolactinomas, prolactin levels normalized after surgery in 25 (68%) patients. Of 18 patients with Cushing's disease, 13 (72%) had normal postoperative levels of cortisol. Amongst the 13 patients with acromegaly, 11 (84%) had normalized postoperative levels of IGF-1. Postoperative complications included deterioration of anterior pituitary function in 11%, CSF leak in 6%, meningitis in 1.2%, temporary diabetes insipidus in 4%, permanent diabetes insipidus in 3%, and sinusitis in 1.2%. One patient who had a large calcified recurrent fibro sarcoma died

after surgery from bilateral occlusion of the internal carotid arteries. The length of the hospital stay was less than one day in 75% of the patients [13].

Cappabianca et al. (2002) studied 100 patients who underwent an endoscopic endonasal transsphenoidal approach [7]. Amongst the 87 pituitary adenomas, total resection of the tumor was performed in 51 patients, subtotal resection in 20 patients (80%) and a partial resection in 16 patients. 4 craniopharyngiomas was totally resected, one intrasellar arachnoid cyst was evacuated and in two clivus chordomas was performed a biopsy. Two patients with sphenoidal sinusitis and three patients with spontaneous CSF leak underwent endoscopic treatment successfully [7]. The authors consider the endoscopic endonasal transsphenoidal approach less traumatic than transsphenoidal microsurgery. The hospital stay was reduced to two days in 40% of the cases [7].

Traditional transsphenoidal surgery had proved to be a reasonably safe procedure when performed by experienced surgeons. Although the mortality rate is low, usually below 1%, morbidity is not negligible and complications still occur [8, 10, 14-16]. In 1997, Ciric et al. presented the results of a study on the complications of transsphenoidal microsurgery. The study is based on personal experience and data submitted by 958 neurosurgeons from the United States who responded to a detailed questionnaire. The authors assigned each respondent to one of three groups based on the number of transsphenoidal operations performed (<200, 200-500, >500), and the results show the percentage of operations resulting in complications decreases as experience increases [10]. The results are presented in Table 2.

3. Complications of the endoscopic endonasal transsphenoidal approach

Complications of the endoscopic endonasal transsphenoidal approach were divided into groups according to the anatomical structures and the system that may be involved. The following categories are defined: nasofacial, sphenoid sinus, sella turcica, parasellar, suprasellar and endocrine complications [8].

3. 1. Nasofacial complications

The most common complication is epistaxis and it is often delayed. The bleeding derives from the small branches of the sphenopalatine artery usually in acromegalic patients with nasal mucosa hypertrophy. The incidence of the epistaxis is reduced in endoscopic transsphenoidal approach (1.3%) as compared to the transsphenoidal surgery (3.4%) [8, 10]. The treatment of delayed postoperative bleeding from the sphenopalatine artery requires an anterior and/or posterior nasal packing for two days [17]. Posterior packing provides compression of the posterior aspect of the middle turbinate, which in turn compresses the sphenopalatine and internal maxillary arteries.

Patients with refractory epistaxis required surgical re-intervention with the identification and coagulation of the sphenopalatine artery. An alternative treatment is the embolization of the internal maxillary artery [17, 18]. The sphenopalatine artery is the terminal branch of the maxillary artery. This artery enters the nasal cavity through the sphenopalatine foramen, topographically located behind the end of the middle turbinate, on the lateral wall of the nasal cavity, which also corresponds to the hidden inferior lateral corner of the sphenoid sinus.

Table 2 Complications resulting from transsphenoidal pituitary surgery

Complications resulting from transsphenoidal pituitary surgery. comparative results						
Nr.	Type of complication	Number of surgical intervention				Series (Ciric)
		< 200	200-500	>500	Average	146
		%	%	%	%	%
1	Septal perforation	7.6	4.6	3.3	6.7	0
2	Epistaxis	4.3	1.7	0.4	3.4	1.36
3	Sinusitis	9.6	6.0	3.6	8.5	2.05
4	Carotid artery injury	1.4	0.6	0.4	1.1	0.68
5	Central nervous system injury	1.6	0.9	0.6	1.3	0.68
6	Hemorrhage / swelling of the residual tumor	2,8	4,0	0,8	2,9	0,68
7	Visual dysfunction	2.4	0.8	0.5	1.8	0
8	Ophthalmoplegia	1.9	0.8	0.4	1.4	0.68
9	CSF leak	4.2	2.8	1.5	3.9	2.05
10	Meningitis	1.9	0.8	0.5	1.5	0.68
11	Anterior pituitary insufficiency	20.6	14.9	7.2	19.4	13.6
12	Diabetes insipidus	19.0	-	7.6	17.8	3.42
13	Death	1.2	0.6	0.2	0.9	0.68

Inside the nasal cavity, the sphenopalatine artery splits into two branches: the nasopalatine artery (medial) which passes above the choana and leads to the nasal septum, and the posterior nasal artery (lateral) which reaches the lateral wall of the nasal cavity (Figure 10). The risk of damaging the artery is potentially higher in the endoscopic endonasal procedure, because the approach to the sphenoid sinus is more lateral than in microscopic transseptal surgery. The sphenopalatine artery can be damaged during anterior sphenoidotomy, especially when the enlargement of the anterior wall of the sphenoid sinus is made in the inferior lateral or downward direction. The best way to avoid injury of the sphenopalatine artery or its nasopalatine branch is to

laterally displace the mucosa and to remove the bony structures only. When an intraoperative bleeding occurs, bipolar coagulation of the bleeding vessel is recommended.

3.2. Sphenoid sinus complications

The postoperative sphenoid sinusitis can be diagnosed clinically or on sellar MRI. Medical treatment reduces the inflammation of the sinus. Its incidence is 2% in the endoscopic approach and 8.5% in the conventional procedure [8, 10]. These results are due to a large opening of the sphenoid sinus, postoperative preserved pneumatization of the sphenoid sinus, not using the transsphenoidal retractor and respecting the osteomeatal landmarks.

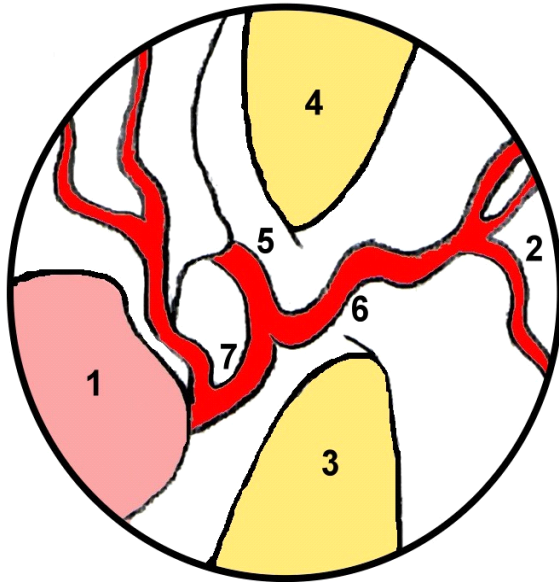


Figure 10 Schematic drawing illustrating the course of the branches of the right sphenopalatine artery. 1 – middle turbinate; 2 – nasal septum; 3 – choana; 4 – sphenoid sinus; 5 – sphenopalatine artery; 6 – nasopalatine artery; 7 – posterior nasal artery

3.3. Sella turcica complications

Postoperative, CSF leak can occur when the arachnoid is injured. An external lumbar drainage or endoscopic reconstruction of the sella can be used. This complication appears in 2% of patients in endoscopic approach, and 3.9% in microsurgical approach [8, 10].

3.4. Suprasellar complications

In large tumors, in which partial removal was performed, CT scan revealed swelling of the residual lesion with compression of the proximal anatomical structures and neurological deficits. An intrasellar / suprasellar hematoma can appear and meningitis can occur as well.

3.5. Parasellar complications

In case of accidental lesion of the intracavernous carotid artery, major bleeding occurs and can be life-threatening. Small lesions are intraoperative controlled

with tamponade. Once the bleeding has been controlled, a carotid cavernous fistula or a false aneurysm usually develops later on [17]. Because massive bleeding can occur, a neuroradiological follow-up is recommended (non-invasive imaging techniques: angio-CT and MRI). Angiography can be employed as a second line of study. If a pseudo-aneurysm is present the endovascular techniques are preferred because they are more easily performed, are associated with lower mortality and morbidity and permit a complete exclusion of the lesion from the arterial circulation, with preservation of the patent artery [17]. Lesions of the intracavernous nerves can also occur.

3.6. Endocrine complications

An anterior or posterior pituitary insufficiency (diabetes insipidus) can be diagnosed. Diabetes insipidus may be transitory or permanent.

Conclusions

Neurosurgical treatment of sellar and parasellar lesions has undergone considerable changes in recent years. It has become possible to perform regular noninvasive follow-ups by MRI, there are developments in drug therapy, the advent of gamma-knife allows for significant reduction of operative aggressiveness and minimal invasive surgery was extended [19]. Nevertheless, despite all technical progress, results is still strongly dependent on how the surgery itself is performed and is determined by the operative approach. In transsphenoidal surgery, the endoscopic endonasal transsphenoidal approach can be considered a very good choice for the removal of different sellar and parasellar lesions.

*Correspondence to: Ligia Tataranu, MD, PhD, “Bagdasar-Arseni” Clinical Emergency Hospital, Sos. Berceni 10-12, 041514 Bucharest, Romania
E-mail: medic@neurochirurg.ro
Phone: +40744-375 000

References

1. de Divitiis E, Cappabianca P, Cavallo LM, Endoscopic transsphenoidal approach: adaptability of the procedure to different sellar lesions. *Neurosurgery*, 2002. 51(3): p. 699-707.
2. Jho HD, Alfieri A, Endoscopic transsphenoidal pituitary surgery: various surgical techniques and recommended steps for procedural transition. *British Journal of Neurosurgery*, 2000. 14(5): p. 432-440.
3. Moreland DB, Diaz-Ordaz E, Czajka GA, Endoscopic endonasal hemisphenoidotomy for resection of pituitary lesions confined to the sella: report of 3 cases and technical note. *Minimally Invasive Neurosurgery*, 2000. 43: p. 57-61.
4. Rhoton AL, Harris FS, Renn WH, Microsurgical anatomy of the sella region and cavernous sinus. *Clinical Neurosurgery*, 1977. 24: p. 54-85.
5. Jho HD, Endoscopic endonasal approach to the optic nerve: a technical note. *Minimally Invasive Neurosurgery*, 2001. 44: p. 190-193.
6. Jho HD, Carrau RL, McLaughlin ML, Somaya SC, Endoscopic transsphenoidal resection of a large chordoma in the posterior fossa. *Acta Neurochirurgica (Wien)*, 1997. 139: p. 343-348.
7. Cappabianca P, Cavallo LM, Colao A, Del Basso De Caro M, Esposito F, Cirillo S, Lombardi G, de Divitiis E, Endoscopic endonasal transsphenoidal approach: outcome analysis of 100 consecutive procedures. *Minimally Invasive Neurosurgery*, 2002. 45(4): p. 193-200.
8. Cappabianca P, C.L., Colao AM, de Divitiis E, Surgical complications associated with the endoscopic endonasal transsphenoidal approach for pituitary adenomas. *Journal of Neurosurgery*, 2002. 97: p. 293-298.
9. Cappabianca P, C.L., De Divitiis E, Endoscopic endonasal transsphenoidal surgery. *Neurosurgery*, 2004. 55(4): p. 933-941.
10. Ciric I, Ragin A, Baumgartner C, Pierce D, Complications of transsphenoidal surgery. Results of a national survey, review of the literature and personal experience. *Neurosurgery*, 1997. 40: p. 225-237.
11. Badie B, Nguyen P, Preston K, Endoscopic-guided direct endonasal approach for pituitary surgery. *Surgical Neurology*, 2000. 53: p. 168-173.
12. Cho DY, Liau WR, Comparison of endonasal endoscopic surgery and sublabial microsurgery for prolactinomas. *Surgical Neurology*, 2002. 58: p. 371-376.
13. Jho HD, Endoscopic transsphenoidal tumor surgery. *Operative Techniques in Neurosurgery*, 2002. 5(4): p. 218-225.
14. Black PMcL, Zervas NT, Candia GL, Incidence and management of complications of transsphenoidal operation for pituitary adenomas. *Neurosurgery*, 1987. 20: p. 920-924.
15. Laws ER Jr, Kern EB, Complications of transsphenoidal surgery. *Clin Neurosurg*, 1976. 23: p. 401-416.
16. Semple PL, Laws ER, Complications in a contemporary series of patients who underwent transsphenoidal surgery for Cushing's disease. *Journal of Neurosurgery*, 1999. 91: p. 175-179.
17. Cavallo LM, B.F., Cappabianca P, Maiuri F, Valente V, Tortora F, Volpe A, Messina A, Elefante A, De Divitiis E, Hemorrhagic vascular complications of endoscopic transsphenoidal surgery. *Minimally Invasive Neurosurgery*, 2004. 47: p. 145-150.
18. Cockroft KM, Carew JF, Trost D, Fraser RA, Delayed epistaxis resulting from external carotid artery injury requiring embolization: a rare complication of transsphenoidal surgery: case report. *Neurosurgery*, 2000. 47: p. 236-239.
19. Marquardt G, Y.H., Hermann E, Seifert V, Direct transnasal approach for pituitary surgery. *Neurosurgical Review*, 2004. 27: p. 83-88.