

## Neuronavigation in the Percutaneous Treatment of Trigeminal Neuralgia. Technical note

M. Ivanov<sup>1</sup>, Andrew Brodbelt<sup>2</sup>, N. Ianovici<sup>3</sup>, A.V. Ciurea<sup>4</sup>,  
I. Poata<sup>5</sup>, F.M. Gramada<sup>2</sup>

<sup>1</sup>Neurosurgery, Plymouth Hospitals NHS Trust, Derriford Hospital, Plymouth, UK

<sup>2</sup>Neurosurgery, Walton Centre for Neurology and Neurosurgery, Liverpool, UK

<sup>3</sup>Neurosurgery, Clinical Emergency “N. Oblu” Hospital, Iasi, Romania

<sup>4</sup>Neurosurgery, Clinical Emergency Hospital “Bagdasar - Arseni”, Bucharest, Romania,

<sup>5</sup>Neurosurgery, University of Medicine and Pharmacy “Gr.T.Popa”, Iasi, Romania

### Abstract

*Objective:* To describe neuronavigation-guided percutaneous radiofrequency thermocoagulation in the treatment of trigeminal neuralgia.

*Methods:* Neuronavigation guided percutaneous radiofrequency thermocoagulation of the Gasser ganglion was used in nine patients with trigeminal neuralgia who developed resistance to drugs used in the treatment of TN or have had adverse effects due to drug toxicity. The age of the patients was between 62 and 78 years.

*Results:* All patients had immediate pain relief after thermocoagulation guided by neuronavigation. Neuronavigation allowed visualization of instrument position in relation to target and the related anatomical structures. The technique helped preoperative planning of the optimal trajectory for needle insertion. There were no complications of the procedure.

*Conclusion:* Image guided percutaneous thermocoagulation in the treatment of trigeminal neuralgia is a safe and promising procedure. The technique has reduced the risk of postoperative complications caused by “hunting” of the foramen ovale.

**Keywords:** Neuronavigation, Image guided surgery, Trigeminal neuralgia,

Minimally invasive surgery, Frameless stereotaxy.

### Introduction

Idiopathic trigeminal neuralgia has an incidence of 3-5 cases in 100 000. It is characterized by spontaneous facial pain that is either predominantly episodic (as in TN1) or constant (as in TN2) in nature. Pain distribution is unilateral and follows the sensory distribution of the trigeminal nerve, typically radiating to the maxillary (V2) or mandibular (V3) area. Since the description by Hartel in 1912 of transovale trigeminal rhizotomy a number of treatment options have been described. In patients unsuitable for microvascular decompression, selective interruption of the nociceptive fibres in most cases can provide pain relief<sup>18</sup>. Glycerol<sup>11,14</sup>, phenol<sup>19</sup> or alcohol infiltration, radiofrequency thermocoagulation<sup>6</sup>, balloon compression<sup>2, 4, 9, 17</sup>, stereotactic radiosurgery<sup>7, 8, 15, 16</sup>, peripheral nerve<sup>10</sup> block or rhizotomy<sup>3, 13</sup> – have all been used.

Currently radiofrequency thermocoagulation, balloon compression and stereotactic radiosurgery are the most common ablative methods used. Recent published reports suggest that between

these radiofrequency thermocoagulation is more efficient in treating the pain syndrome, but is associated with a higher risk of complication<sup>5</sup>.

Most methods use a percutaneous approach to the foramen ovale, Using X-ray guidance. Accuracy depends on individual anatomy, the surgeon's experience and the quality of imaging. A number of complications caused by "hunting" of the foramen ovale have been described. Reports of CT guided targeting of the foramen ovale has shown reduced complications. We present our experience on the first 9 cases of trigeminal neuralgia treated in our hospital using the navigation guidance with a DRF (dynamic reference frame) fixed to the patient's forehead.

## Methods

### *Subjects*

Nine patients diagnosed with idiopathic (Burchiel TN1 and TN2) trigeminal neuralgia were treated in the Iasi Neurosurgical centre using percutaneous thermocoagulation guided by neuronavigation.

An MRI scan was performed in all the cases to exclude an intracerebral lesion and a CT scan was used for preoperative planning, 3D rendering and integration of imaging into neuronavigation system.

For navigation a RADIONICS (2003) frameless neuronavigation system was used. Radiofrequency thermocoagulation was performed using a Radionics RFG-3CF generator (Tew Kit, Radionics, Burlington, MA). Stimulation at 50 Hz, 1 ms, and 0–0.3 volts was applied. The lesion was made at 60°C–70°C for 60–90 s.

### **Technique description**

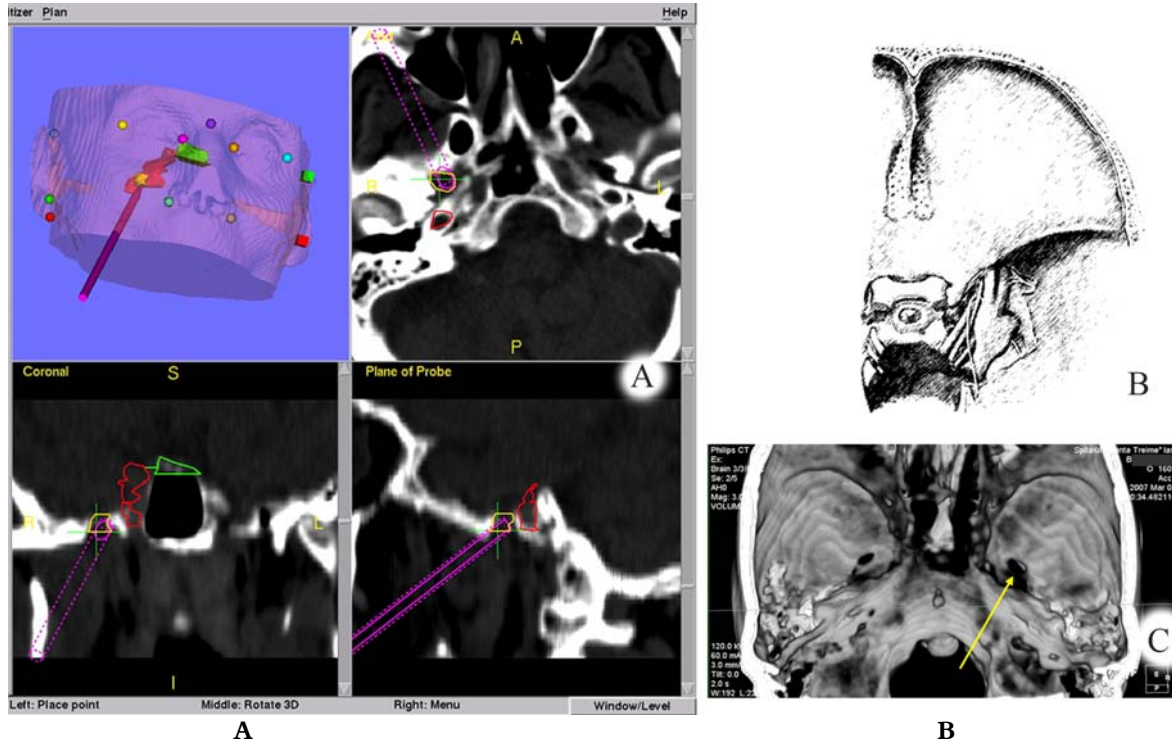
Image acquisition and preoperative planning. A helical CT scan with maximum

2 mm thickness was performed in all patients. Images were transferred to the navigation station and a 3D reconstruction of the skull base contouring the foramen ovale and adjacent critical structures (carotid artery, cavernous sinus etc. – Figure 1) was obtained. The target (upper postero-medial margin of the foramen ovale) and entry point (approximately 2–3 cm lateral to the ipsilateral labial commissura) was then planed. The obtained trajectory of the needle is verified in "probe's eye" or in the "probe view" window of the neuronavigation system, avoiding bony elements and important soft tissue structures, allowing adjustment as required.

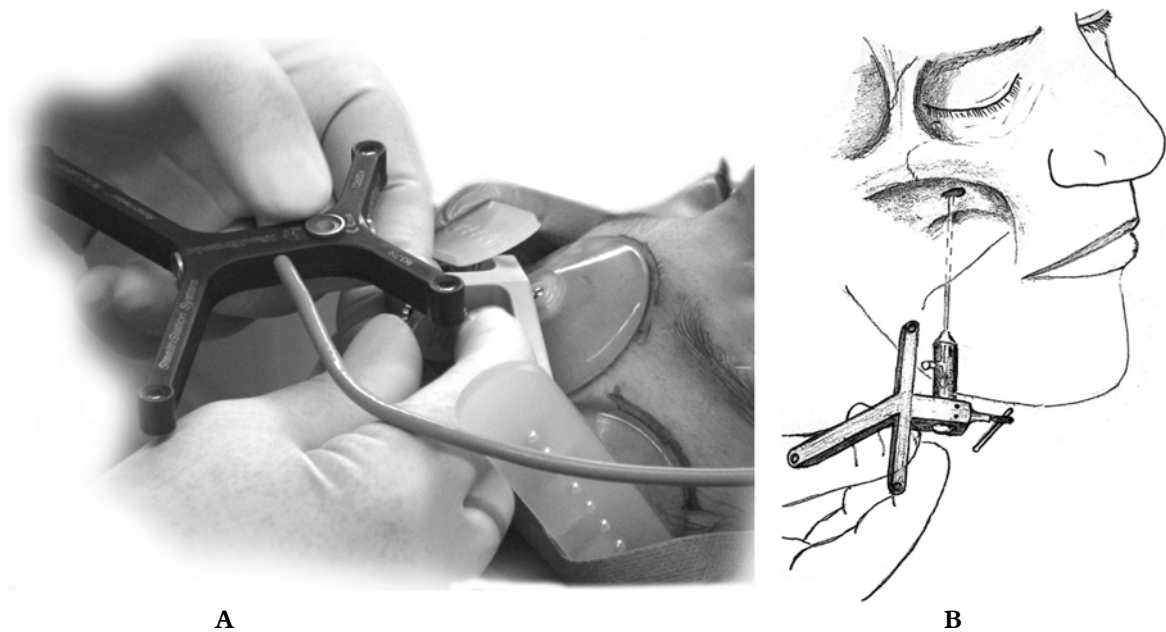
### **Intraoperative patient's registration**

All the patients received premedication with Atropine (0,5 mg intramuscular) and light sedation with Midazolam. Heart rate, blood pressure and blood oxygen saturation were monitored.

A Dynamic Reference Frame (DRF) was applied to the forehead of the patient. It was attached with an elastic velcro band (Radionics) and remained in a fixed position relative to the head during the entire procedure. As an alternative (eg. with Medtronic Stealth equipment) the reference point can be attached using a suction cup (Figure 2) or adhesive material as in EM guided procedures. The patient was registered using either surface matching, fiducials or anatomical landmarks. To achieve a better accuracy either a higher number of fiducials and anatomical landmarks (>15) or more extensive surface matching of the face contours was performed. No details of registration error were recorded, but from the literature we assumed this to be in a range of 1–3 mm.



**Figure 1** A Neuronavigation screenshot shows the needle position in relation to the foramen ovale and related anatomical structures; B Drawing and 3D CT rendering (C) of the skull base and foramen ovale



**Figure 2** A Dynamic reference frame fixed on the patient's forehead before registration; B The Universal Instrument Recognition (UIR) tool attached to the needle makes the tip of the instrument "visible" by the navigation system

The cannula used with a stylet was attached to the Universal Instrument Registration tool (UIR) and registered.

After aseptic field preparation and draping the previously established entry point is marked. A small perforation of the skin with 11 blade is made. The needle attached to the UIR tool is guided by the neuronavigation up to the medial border of foramen ovale, avoiding the oral cavity (Figure 2). The patient usually has ipsilateral masseter contraction and winces at this point. CSF fluid may also be obtained in some cases. At this point stimulation of the trigeminal nerve can be performed for localization of the affected branch and eventually fine needle readjustment. A dose of Propofol 1% (1 mg/kg) is administered and three sequential lesions, produced by 60- to 80 second applications, are performed by increasing the temperature by 5°C each time starting with 60°C. At the end of the procedure the patient should feel hypoaesthesia in the corresponding dermatome of the trigeminal nerve.

## Results

In our series no procedure-related complications have been noticed in patients where neuronavigation-guided percutaneous radiofrequency thermocoagulation was performed. All patients had good immediately postoperative and at one year follow-up pain control.

Patient registration time was between 7 and 20 minutes (mean 12 minutes). Overall length of time for the procedure was between 22 and 49 minutes (mean 29). It was higher in earlier cases and lower in later cases as learning curve is rapid.

## Discussions

Ablative or compressive procedures targeting the gasserian ganglion continue to play an important role in the management of trigeminal neuralgia. Localization of the foramen ovale can be difficult due to imaging quality (improved by biplanar radiology systems), operator inexperience and anatomical variations. The optimal target within foramen ovale is its posterior part. Complication rates due to inaccurate targeting are described as being 5%-7%. Optic nerve lesion, intracranial haemorrhage, carotid artery injury, carotico-cavernous fistula, lesion of other cranial nerves (oculomotor, trochlear, abducens) with secondary diplopia and facial haematoma are all described<sup>1</sup>.

Advantages of using neuronavigation include precision in localization of the foramen ovale, visualization of adjacent vascular and soft tissue structures, no irradiation of theatre personnel and no need for the radiographer in theatre. Also it aids trainees and less experienced surgeons in intraoperative orientation and planning. The imaging is given simultaneously both in 3D and in classical sagittal, coronal and transversal planes<sup>12, 20</sup>.

Disadvantages include the need for helical CT scan for preoperative planning and intraoperative guidance; slight initial increase to the length of surgery (short learning curve). A flexible needle risks inaccuracy if distortion occurs during passage through the soft tissues, this can be avoided by using a rigid stylet or cannula to guide the needle to the target. Addition of a localizer may reduce the effective length of the needle, requiring either a longer needle/stylet or changes in the design of the localizer.

## Conclusions

Neuronavigation guided approaches to the foramen ovale for the treatment of trigeminal neuralgia improves target visualization and potentially reduce the risk of complications. It is simple and precise. The preliminary results are encouraging. The future studies of a larger series of patients with longer follow-up will provide more detail about the efficiency and complications of this technique.

## References

1. Headaches, cranial neuralgias, facial pain, classification and diagnostic criteria. International Headache Society]. *Rev Prat* 40:416-426, 429-450, 1990
2. Belber CJ, Rak RA: Balloon compression rhizolysis in the surgical management of trigeminal neuralgia. *Neurosurgery* 20:908-913, 1987
3. Cetas JS, Saedi T, Burchiel KJ: Destructive procedures for the treatment of nonmalignant pain: a structured literature review. *J Neurosurg* 109:389-404, 2008
4. Cheshire WP: Trigeminal neuralgia: for one nerve a multitude of treatments. *Expert Rev Neurother* 7:1565-1579, 2007
5. Kanpolat Y, Berk C, Savas A, et al: Percutaneous controlled radiofrequency rhizotomy in the management of patients with trigeminal neuralgia due to multiple sclerosis. *Acta Neurochir (Wien)* 142:685-689; discussion 689-690, 2000
6. Kanpolat Y, Savas A, Bekar A, et al: Percutaneous controlled radiofrequency trigeminal rhizotomy for the treatment of idiopathic trigeminal neuralgia: 25-year experience with 1,600 patients. *Neurosurgery* 48:524-532; discussion 532-524, 2001
7. Kondziolka D: Functional radiosurgery. *Neurosurgery* 44:12-20; discussion 20-12, 1999
8. Kondziolka D, Lunsford LD, Flickinger JC: The application of stereotactic radiosurgery to disorders of the brain. *Neurosurgery* 62 Suppl 2:707-719; discussion 719-720, 2008
9. Lee ST, Chen JF: Percutaneous trigeminal ganglion balloon compression for treatment of trigeminal neuralgia--part I: pressure recordings. *Surg Neurol* 59:63-66; discussion 66-67, 2003
10. Long DM: Surgical therapy of chronic pain. *Neurosurgery* 6:317-328, 1980
11. Lunsford LD: Glycerol rhizotomy for trigeminal neuralgia. *J Neurosurg* 66:151-152, 1987
12. Mandat T, Brozyna B, Krzymanski G, et al: An image-guided, noninvasive method of cannulation of the foramen ovale for awake, percutaneous radiofrequency rhizotomy. *J Neurosurg* 111:1223-1225, 2009
13. Morello G, Bianchi M, Migliavacca F: Combined extra-intradural temporal rhizotomy for the treatment of trigeminal neuralgia. Results in 409 patients. *J Neurosurg* 34:372-379, 1971
14. North RB, Kidd DH, Piantadosi S, et al: Percutaneous retrogasserian glycerol rhizotomy. Predictors of success and failure in treatment of trigeminal neuralgia. *J Neurosurg* 72:851-856, 1990
15. Richards GM, Bradley KA, Tome WA, et al: Linear accelerator radiosurgery for trigeminal neuralgia. *Neurosurgery* 57:1193-1200; discussion 1193-1200, 2005
16. Sheehan J, Pan HC, Stroila M, et al: Gamma knife surgery for trigeminal neuralgia: outcomes and prognostic factors. *J Neurosurg* 102:434-441, 2005
17. Sweet WH: Percutaneous methods for the treatment of trigeminal neuralgia and other faciocephalic pain; comparison with microvascular decompression. *Semin Neurol* 8:272-279, 1988
18. Tew JM, Jr., Keller JT: The treatment of trigeminal neuralgia by percutaneous radiofrequency technique. *Clin Neurosurg* 24:557-578, 1977
19. Wilkinson HA: Trigeminal nerve peripheral branch phenol/glycerol injections for tic douloureux. *J Neurosurg* 90:828-832, 1999
20. Yang Y, Shao Y, Wang H, et al: Neuronavigation-assisted percutaneous radiofrequency thermocoagulation therapy in trigeminal neuralgia. *Clin J Pain* 23:159-164, 2007