

Neuroform stent – assisted coil embolization New treatment strategy for complex intracranial aneurysms with midterm results

Ali Ismail Alhothi, Tiewei Qi, Prof. Zhengsong Huang, Songzhong Shi,
Feng Liang, Lixuan Yang, Shaolei Guo

Neurosurgery, First Affiliated Hospital, Sun Yat-sen University, Guang Zhou City,
P.R. China

Abstract

Objective: To present detailed results of our treatment experience in using Neuroform Stent-Assisted Coil embolization to treat complex cerebral aneurysms over 3-year period, emphasizing on the technical difficulties, procedure-related complications, and to evaluate midterm results.

Methods: Patients underwent Neuroform stent-assisted coil embolization were registered in a database. We assessed patients' history, aneurysm morphology, indications for stenting, and technical details of the procedures, complications and midterm follow-up data.

Results: This study included twenty-six patients with 39 aneurysms. A total of 32 of 39 aneurysms were treated by Neuroform stent-assisted embolization (SAC). Three aneurysms stented without coiling, 2 aneurysms coiled without stenting and 2 aneurysms surgically clipped. The indications for use included broad-necked aneurysms (n = 28), giant or large aneurysms (n = 6), and fusiform aneurysms (n = 5). Of the 32 aneurysms treated by Neuroform SAC, we achieved complete (100%) and near complete (> 95%) occlusion in 27 aneurysms, and

Partial (< 95%) occlusion in 5 aneurysms. Follow-up angiographic data available in 22 of 32 aneurysms treated by Neuroform SAC (68.7%) (average follow-up, 12 mo; range 4–24 mo) demonstrating recanalization in 3 aneurysms (13.6%), and stable occlusion in 19 aneurysms (86.4%). No delayed progressive embolization or in-stent stenosis observed.

Conclusion: Neuroform microstent system led to a significant evolution in the endovascular treatment of complex intracranial aneurysms. Our results and midterm follow-up showed Neuroform stent-assisted coil embolization is safe and effective technique in the treatment of complex cerebral aneurysms. Although, the clinically significant complications are uncommon and the evaluation at midterm follow-up is encouraging, further studies needed to assess the long-term stability and durability of the stent.

Keywords: aneurysm, coil, embolization, midterm follow-up, neuroform, stent

Introduction

The Neuroform stent is self-expandable, microcatheter delivered Nitinol stent (formed by alloying nickel and titanium (~

50% Ni), is a shape memory alloy with superelastic properties) specifically designed for application to intracranial vessels. Neuroform stent microdelivery system is divided into three parts: the self-expanding stent itself, a 3F delivery microcatheter, and a (2F stabilizing microcatheter) stabilizer. It has converted some previously 'untreatable' aneurysms into endovascular amenable lesions. Only few series of patients treated with this stent has been reported in the literature (6, 11, 21, 22, 23, 24, and 25). Our aim is to report in details our immediate and available midterm results in the use of Neuroform microstent for the embolization of complex intracranial aneurysms.

Methods - Subjects

All patients included in this study represents an all-inclusive series of patients underwent Neuroform SAC embolization in our department during a 36-month period (December 2004 – December 2007). Normally, patients were included when the neurointerventionalist advised that the aneurysm could not be treated effectively with traditional endovascular techniques and the risk-to-benefit ratio equal or superior to that of microsurgical clipping based on the aneurysm location and anatomic characteristics combined with the patient clinical status and ability to afford the treatment expenses

A total of 26 patients harboring 39 aneurysms were deemed suitable for treatment. There were 11 males and 15 females ranging in age from 25 to 69 years with a mean age of 48.4 years. The patients' demographics are listed in Table 1. Twenty-three patients presented with ruptured aneurysms (included two

aneurysms in two different patients were presented as recurrence developed after primary coil embolization alone) and three patients had unruptured aneurysms. Regarding those aneurysms' types, there were 28 broad neck aneurysms (dome-to-neck ratio < 2 or neck diameter > 4-mm), 6 large aneurysms (dome > 9.5-mm), and 5 fusiform aneurysms. With respect to the broad neck aneurysms, the average dome size 3.6-mm, the average neck size 2.6-mm, and the average dome-to-neck ratio 1.38.

Pre-procedural arrangements

Before SAC procedure started, routinely, each patient or his/her family provided informed consent for the patient to undergo the procedure.

All patients underwent diagnostic cerebral angiography before stent placement. Following diagnostic angiography, the neurointerventionalist determines whether the patient is a suitable candidate for the Stent-Assisted Coiling (SAC) or not.

If a patient had unruptured aneurysm or was not in the acute stage of aneurysmal SAH and was selected for stent use before the procedure, our anti-coagulation regimen consists of Aspirin (Enteric Coated) 100 mg and Clopidogrel 75 mg by mouth for 3 days were administered. If the patient was not selected for stent use before the procedure, it was usually administered a bolus dose of clopidogrel 225 mg with Aspirin 100mg through NGT. After the femoral vascular access was obtained, a bolus dose of 2000 to 3000 U heparin was administered to achieve an Activated Clotting Time (ACT) of twice to treble of the baseline.

Table 1 Summary of patients treated with Neuroform SAC

Pt. No	Age /sex (yrs)	Status	H&H grade	Aneurysm Location	Sizes D/N (mm)	Type of Procedure	Stent Size	Immed. DSA Results	F/U time (mth)	F/U DSA Results
1	38/F	R	II	(BN)PComA/L	5.0/3.0	Stent/Coil	4.5x20	C	9	Sta
				(BN)ICA-OPHTH/L	5.0/3.0	Stent/Coil	4.5x20	C	9	Sta
2	67/M	UR	0	(L)AComA	15/12	Stent/Coil	3.5x20	NC	NA	
3	54/F	R	IV	(BN)Basilar	2.0/2.0	Stent only	4.5x15			
				(F)Vertebral/L	2.8/2.0	Stent/Coil	4.5x20	NC	NA	
4	43/F	R	I	(BN)ICA-C2/R	3.5/3.5	Stent/Coil	4.0x20	C	6	Sta
5	50/F	R	III	(BN)ICA-C2/R	5.8/5.2	Stent/Coil	3.5x20	C	11	Sta
6	45/F	R	IV	(BN)ICA-C4/R	2.4/2.6	Stent/Coil	3.5x20	C	8	Sta
7	47/M	R	II	(L)Ophth/R	10/5.0	Stent/Coil	4.5x20	C	6	Sta
				(BN)Ophth/L	5.0/4.0	Stent/Coil	4.5x20	NC	6	Sta
8	56/F	R	III	(BN)PComA/R	2.5/3.0	Stent/Coil	3.0x20	C	NA	
9	52/F	R	II	(BN)ICA-PComA/L	5.5/2.8	Stent/Coil	3.5x15	C	12	Sta
10	47/F	R	I	(BN)AComA	4.4/2.3	Stent/Coil	3.5x20	C	7	Rec
11	37/M	R	II	(BN)ICA-C2/R	2.2/1.4	Stent/Coil	4.0x15	P	17	Sta
				(BN)MCA-M2/R	6.5/3.0	Clipped				
12	62/F	R	II	(BN)AComA/L	3.8/2.0	Coil only				
				(BN)ICA-C6/L	2.1/3.3	Stent/Coil	4.5x20	C	6	Sta
13	39/M	R	III	(BN)AComA/L	4.2/3.8	Stent/Coil	4.0x20	NC	NA	
14	58/F	R	IV	(BN)MCA-M2/R	7.7/3.0	Coil only				
				(BN)ICA-C3/R	2.0/1.3	Stent/Coil	4.0x20	C	NA	
15	32/M	R	II	(BN)Ophth/L	4.0/3.0	Stent/Coil	4.5x20	C	11	Sta
16	54/M	R	II	(BN)AComA	4.7/2.7	Stent/Coil	4.0x15	P	24	Sta
				(BN)PComA/L	5.2/3.1	Stent/Coil	4.0x15	C	24	Sta
				(BN)Ophth/L	3.1/3.1	Stent/Coil	4.0x15	P	24	Sta
17	69/M	RE	II	(L)PComA/R	10.3/4.1	Stent/Coil	4.5x20	C	NA	
18	25/F	R	II	(BN)ICA-Ophth/L	6.4/3.2	Stent/Coil	3.5x20	C	4	Sta
19	26/M	RE	IV	(L)AChoA/L	9.5/1.6	Stent/Coil	4.5x20	C	NA	
20	54/F	R	II	(BN)PComA/R	6.3/6.0	Stent/Coil	4.5x15	C	NA	
21	48/F	R	II	(L)PComA/R	12/3.0	Stent/Coil	4.5x20	NC	12	Rec
22	69/M	UR	0	(F)ICA-C3/L	9.7/8.0	Stent/Coil	4.5x20	P	NA	
				(F)ICA/R	9.0/5.0	Stent only	4.5x15			
				(F)Basilar	26/20	Stent only	4.5x20			
23	51/M	R	IV	(F)MCA-M2/R	7.0/10.1	Stent/Coil	3.0x20	P	14	Rec
				(BN)ICA-C2/R	3.7/3.7	Stent/Coil	4.0x20	NC	14	Sta
				(BN)PComA/R	3.0/2.1	Clipped				
24	41/F	RE	0	(L)ICA-OPHT/L	11/4.2	Stent/Coil	4.0x20	C	24	Sta
25	39/M	R	II	(BN)MCA-M2/R	7.2/5.4	Stent/Coil	4.5x15	C	NA	
26	56/F	R	II	(BN)ICA-A2/L	4.0/3.0	Stent/Coil	4.5x20	C	8	Sta
				(BN)ICA-A3/R	5.0/4.0	Stent/Coil	4.5x20	C	8	Sta

After the procedure, heparinization was not reversed. Subcutaneously 0.4 ml Low Molecular Weight Heparin (LMWH) twice a day, usually administered for three days postoperative. Patients were continued on Clopidogrel 75 mg for 6 weeks and aspirin 100mg for six months postoperatively.

Indications

The indications for stent placement were categorized as broad neck aneurysm, fusiform/dissecting aneurysm, large/giant aneurysm, residual aneurysms after primary coil embolization and aneurysms with protruded coils (i.e., for patients in whom coils prolapsed or may prolapse into the parent vessel).

Stent and size estimation

Stents are sized on the basis of the largest diameter of the parent vessel in which the stent is to be deployed in. However, special attention should be paid to slightly oversized rather than undersized (we usually oversized by 0.5 – 1.0mm) with an overlap of at least 5 mm on each side of the neck of the aneurysm.

Results

A total of 26 patients (11 males and 15 females ranging in age from 25 to 69 years with a mean age of 48.4 years) harboring 39 aneurysms were deemed suitable for Neuroform SAC treatment. Twenty-three patients presented with aneurysmal Sub-Arachnoid Hemorrhage (SAH): whereas, three patients were presented by symptoms not related to the aneurysmal rupture. In regard to the patients presented with Aneurysmal SAH, 2 patients were Hunt and Hess Grade I, 13 patients were grade II, 3 patients were grade III, and 5 patients were grade IV.

In this study group, we used a total of 35 Neuroform stents., Twenty-three Neuroform stents implanted to cover the

neck of 23 broad neck aneurysms, 6 Neuroform stents implanted to cover the neck of 6 large aneurysms and 3 Neuroform stents overlap 3 fusiform aneurysms: meanwhile, we used 3 stents to cover the neck of 1 broad neck aneurysm and to overlap 2 fusiform aneurysms without coiling embolization.

The occlusion rates evaluation were ranked in complete occlusion, near complete occlusion and partial occlusion as 100%, > 95%, and <95% respectively. Of those 32 aneurysms treated by Neuroform SAC, complete (100%) occlusion achieved in 21 aneurysms (65.6%), and near complete occlusion (>95%) achieved in 6 aneurysms (18.7%), and partial occlusion (<95%) achieved in 5 aneurysms (15.6%). Table 2

Complications

Two clinically evident thromboembolic complications occurred (patient 12 and 23) after stent placement. Patient 12 experienced right hemi paresis upon waking after the deployment of stent within the left ICA to support the coil embolization of a broad neck aneurysm. However, both of the patients made good functional recovery. Those patients were treated in the context of acute SAH without pretreatment with antiplatelet medications. No aneurysmal rupture was encountered during the procedure, and no mortality related to the procedure.

Stent displacement encountered in one patient (patient 22). In this case, the initial plan was to deploy the second stent within the first one to achieve a satisfactory overlap over the aneurysm. Unfortunately, the first stent was displaced after the deployment. In this instance, the distal portion of the stent was displaced into the aneurysm sac located in the upper trunk of the basilar artery. The delivery system could not be navigated easily beyond the landing zone from the parent vertebral artery due to the severe

turtuosity between the aneurysm and the distal part of the parent artery which resulted in the displacement of the distal portion of the stent into the aneurysm sac.

Follow-up angiography

Follow-up angiographic data are available in only 22 of 32 aneurysms (68.7%) treated by Neuroform SAC embolization. The high number of follow-up dropouts (31%) was due to the uncomplying with doctor’s recommended follow-up angiography by some patients. The average follow-up time is 12 months (range, 4–24 months). In the available follow-up angiographies, no cases found to develop in-stent stenosis in this study group. No change was observed in 19 aneurysms: however, the size of the residual aneurysm increased in 3 patients (patient 10, 21, and 23) Table 2. With respect to the

aneurysms treated with stent alone, follow-up angiographies were are not available in all aneurysms.

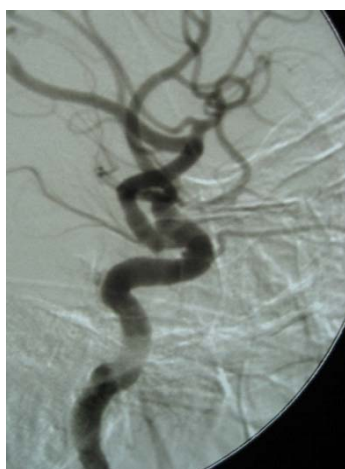Illustrative cases

Patient 24

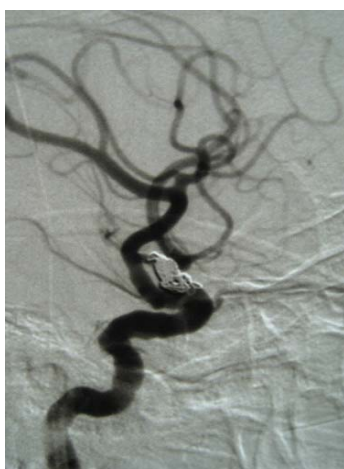A 41-year-old woman presented with headache. Cerebral arteriogram demonstrated a large aneurysm in the left ICA-Ophth junction (Figure 1 A). Initially, the aneurysm was coiled only with complete occlusion achieved (Figure 1 B). A two-year follow-up arteriogram revealed recurrence. This recurred aneurysm had a poor fundus-to-neck ratio, so she was deemed a good candidate for stent-assisted coiling (Figure 1 C & D). A Neuroform (4x20) stent was successfully deployed in the optimal segment across the aneurysm neck. Subsequent GDC coil sat safely in the aneurysm sac (Figure 1 E & F).

Table 2 Summary of patients treated with Neuroform Sac

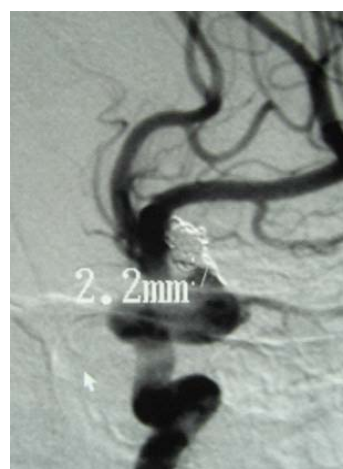
2.1. 39 ANEURYSMS TREATMENT			
STENT/COIL	STENT	COIL	CLIP
32	3	2	2
2.2. OCCLUSION ACHIEVED IN 32 ANEURYSMS TREATED BY NEUROFORM SAC			
PARTIAL(<95%)	NEAR COMPLETE(>95%)	COMPLETE (100%)	
5	6	21	
2.3. FOLLOW-UD DATA OF 22 ANEURYSMS TREATED BY NEUROFORM SAC			
PROGRESSIVE	RECANALIZATION	STABLE	IN-STENT STENOSIS
0	3	19	0



A



B



C

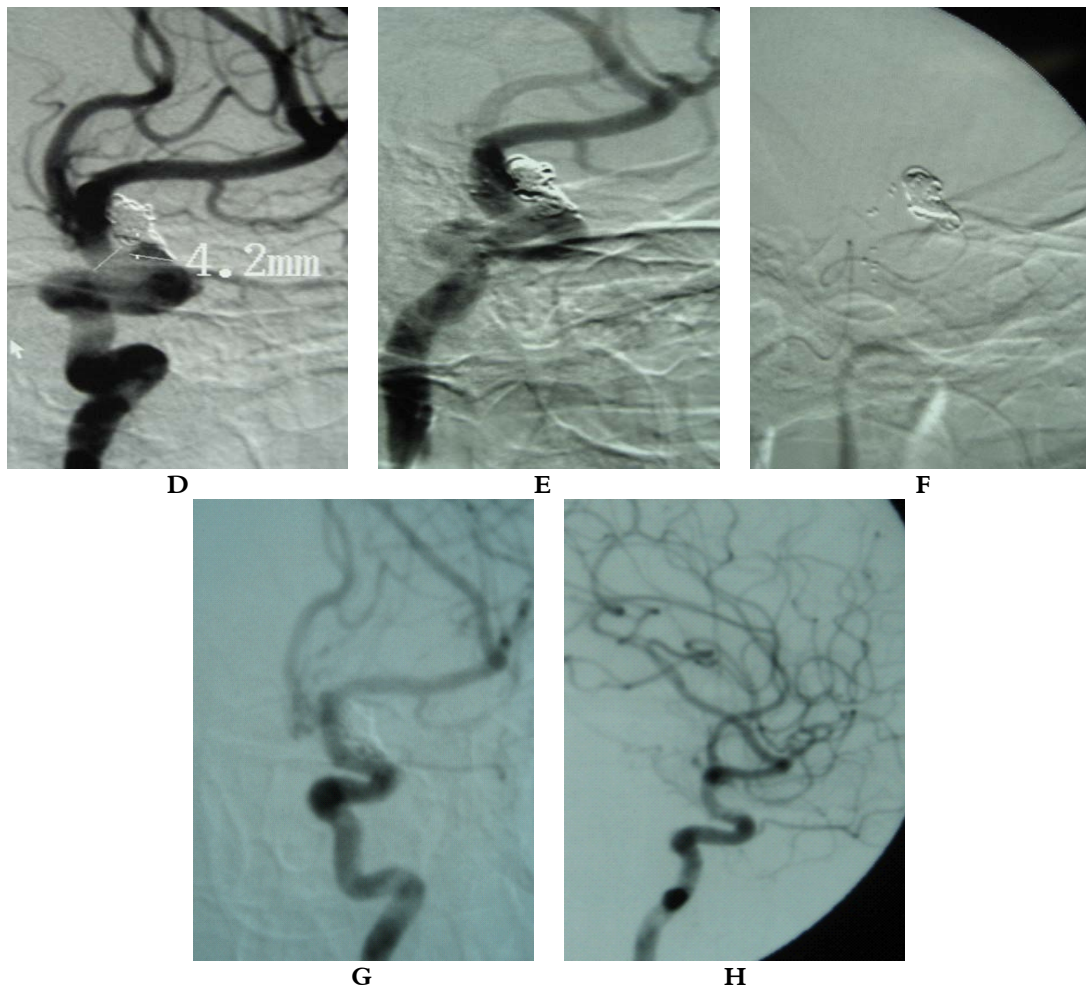


Figure 1 Arteriogram of a 41-year-old woman presented with headache. A, left ICA arteriogram demonstrating large aneurysm involving the left ICA-Ophth. artery take-off. B, control arteriogram showing complete occlusion after coil embolization. C&D, tow-year follow-up arteriogram revealed residual filling. E, post-stenting control arteriogram showing successful stent deployment and coiling with complete occlusion. F, unsubtracted film showed the stent and the coils are still in the optimal position. G, Control arteriogram after NF (4x20) stenting demonstrating complete (100%) occlusion of the aneurysm. H, two-year follow-up arteriogram demonstrating stable embolization of the recurrent aneurysm.

Immediate arteriogram showed complete occlusion (Figure 1 G) Two-year follow-up arteriogram revealed stable occlusion (Figure 1 H).

Patient 10

A 47-year-old woman presented with SAH Hunt & Hiss grade I. Diagnostic cerebral angiography revealed a broad neck aneurysm in the right ICA at the PComA take-off (Figure 2 A & B). This aneurysm

demonstrated a poor dome-to-neck ratio that made her a good candidate for SAC embolization. A Neuroform (3.5x20) stent was successfully deployed in the optimal segment across the aneurysm neck. Subsequent Cordis Helical Fill coil sat safely in the aneurysm sac (Figure 2 C & D). Post-procedural situation was uneventful. Seven-month follow-up arteriogram revealed residual filling of recurrence.

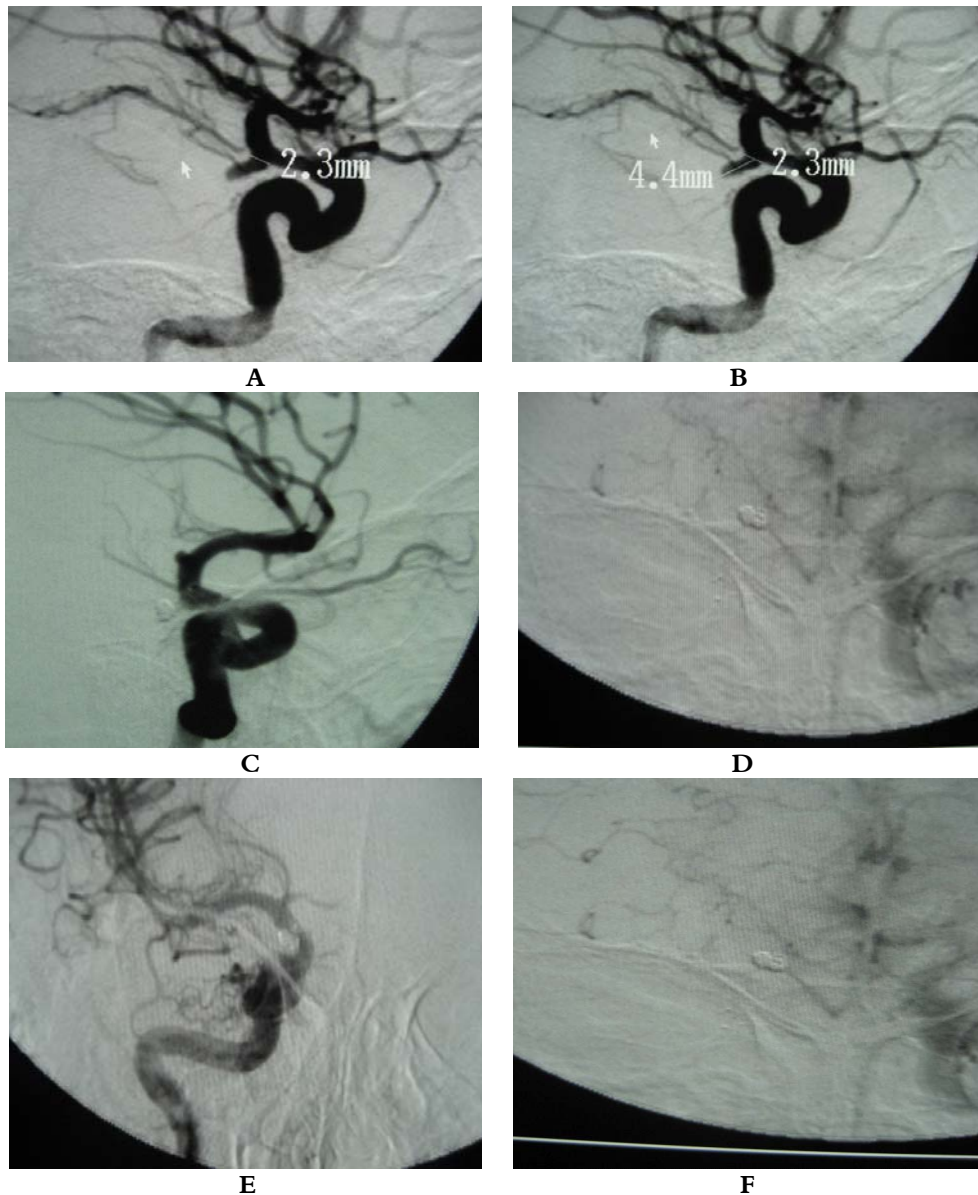


Figure 2 Imaging study of a 47-year-old woman presented with SAH Hunt & Hiss grade I. A, B, Cerebral arteriogram demonstrated a wide-neck aneurysm in the right ICA at the Posterior communicating artery take-off. C, post NF (3.5X20) stent-assisted coil embolization subtracted arteriogram showed complete occlusion(100%). D, Unsubtracted anteroposterior image showed the stent and coil in the optimal position. E, Follow up anteroposterior cerebral arteriogram revealed residual filling of recurrence. F, Anteroposterior unsubtracted film showed the stent and the coils are still in the optimal position.

Discussion

The goal of endovascular aneurysm treatment is to eliminate the aneurysm from the blood circulation and to prevent

the flow of blood into the aneurysm by filling the aneurysm sac with embolization material. (1) The introduction of three-dimensional coils, which retain a complex shape after detachment, provided some

additional flexibility with respect to the ability to treat patients with complex aneurysms (2). However, it is not feasible to perform a coiling procedure for some aneurysms (5% to 14.5 % of cases), (3, and 4) because unusual tortuosity of the vessels renders access difficultly or because the contours of the aneurysm do not permit the coils to sit safely inside. Therefore, larger aneurysms and aneurysms with wider necks typically had lower rates of successful occlusion. (5, 6, 7)

To overcome the problem of complex morphology aneurysms coiling, Moret et al. (8) pioneered the balloon remodeling technique that enables temporary remodeling of the aneurysm neck during coil delivery. We used this technique in seven patients of our study series (e.g. Patient 9 Figure 1).

After the first report of endovascular stent-supported coil embolization for the treatment of experimental carotid sidewall aneurysms in animals in 1994 (9, 10), Higashida reported the first use of stent in the human intracranial circulation to prevent backward protrusion of electrodetachable coils in 1997.

(11) Since then, series of patients treated with self-expandable stents devoted to intracranial aneurysms such as the Neuroform stent (9-11, 12, 13) the Cordis Enterprise stent (14) (Cordis Endovascular, Miami Lakes, FL) or the Balt Leo stent (15) (Balt, Montmorency, France) have been reported.

As reported in other series (9, 12, 13, and 16) we observed in our practice that the navigation of the stent delivery system to and beyond the landing zone was not problematic; the actual deployment of the stent is frequently difficult because of binding of the microwire, the stabilizer, and

the stent delivery catheter. Lylyk et al. (16) reported difficulties in placing the Neuroform stent in 31% of patients, mostly at the beginning of their experience. A second generation of devices resolved this limitation. Fiorella et al. (12) confirmed that using the second-generation (Neuroform 2) delivery system alleviated the technical problems with stent delivery and deployment encountered in their initial results (17). However, the technical advances in the newer generation of this stent (Neuroform 3), which is mounted in a more suitable delivery system, significantly facilitated this stent deployment.

Several case reports an initial practice with aneurysm stenting have been published, including the use of stents in fusiform and dissecting aneurysms (18, 19, and 20). These reports showed satisfying immediate anatomical exclusion of the aneurysm and safety since the procedure-related morbidity and mortality rates were low. Our series corroborates that the Neuroform stent was effective in providing a level of parent vessel protection adequate to allow satisfying packing in the complex aneurysms that were not amenable to conventional endovascular treatment.

Liang et al reported their clinical experience and 5 year follow-up results using Neuroform stent-assisted coiling of intracranial aneurysms for 107 patients, they achieved complete occlusion in 57.2%, neck remnant in 27.3% and incomplete occlusion in 15.5%. (23) Biondi et al angiographic results showed 14 (35%) aneurysm occlusions, 18 (45%) neck remnants, and eight (20%) residual aneurysms in 40 aneurysms treated with stent-assisted coiling (24). Eduardo Wajnberg et al reported their experience

with the Neuroform stent for the treatment of 24 wide-necked intracranial aneurysms, their immediate angiography demonstrated complete occlusion in 70.8%, neck remnant in 16.6% and incomplete occlusion 12.5%. (25)

In our study group, Immediate Angiographic Occlusion Rates of those 32 aneurysms treated with Neuroform SAC demonstrated complete (100%) occlusion in 21 aneurysms (65.6%), near complete occlusion (>95%) in 6 aneurysms (18.7%), and partial occlusion (<95%) in 5 aneurysms (15.6%). However, in our practice small aneurysms were among the most difficult aneurysms to achieve complete occlusion faced in our study group. The small wide-neck aneurysm did not provide enough space to hold coils and microcatheter tip during coil delivery which pushes the microcatheter out of the sac before coil detachment.

In other series, morbidity ranged from 5.8 to 20% and mortality from 2.1 to 8.9% (9, 11, 17, and 16). In our series, we observed a relatively low rate of complications (7.6% morbidity and 0% mortality), which appeared unrelated to the stenting procedures.

Obviously, the comparison of angiographic outcomes across reported series is difficult. A standard definition of what constitutes complete occlusion and residual aneurysm filling is lacking and quantification and analysis of the results is subjective (26). In addition, few papers report angiographic follow-up in stenting procedures for aneurysms. However, we believe that the high success rate of the combined stenting/coiling treatment in our study group is appreciated to the small number of analyzed patients with their relatively short follow-up time that may

produce a positive bias in this study. Further more, the high number of follow-up dropouts (31%) due to uncomplying with doctor's recommended follow-up angiography by some patients could also dramatically change the mortality/morbidity rates that had been presented.

Our follow-up angiography demonstrated that in no case progressive occlusion or in-stent stenosis found in aneurysms treated with Neuroform SAC. Whereas Murayama et al (6), reported rates of 30 and 22% in large and small, wide-necked aneurysms, respectively. Murayama et al relatively high rate of progressive thrombosis may have contributed to the bioactive coils (Matrix Coil). Fiorella et al. (12) reported delayed and severe in-stent stenosis in three of 64 (4.7%) patients. In our series, asymptomatic stenosis of the parent artery at the proximal end of the stent was not observed. However, our available follow-up data revealed three cases with growth residual that is highly attributed to coil compaction process.

The thrombogenicity of the Neuroform stents represents an important limitation with respect to the treatment of aneurysm, particularly those treated in the context of acute SAH (27). Dual anti-platelet regimens have been established to be superior to aspirin therapy alone (28). Clopidogrel is generally used because of its more potent platelet-anti-platelet effect, faster onset of action, and lower incidence of significant adverse effects (29).

In our practice, If a patient had unruptured aneurysm or was not in the acute stage of aneurysmal SAH and was selected for stent use before the procedure, Aspirin 100 mg and Clopidogrel 75 mg by mouth for 3 days were administered. If the patient was not selected for stent use before

the procedure or in the acute stage of SAH, it was usually administer a bolus dose of clopidogrel 225 mg with Aspirin 100mg through the NGT. After the femoral vascular access was obtained, a bolus dose of 2000 to 3000 U heparin was administrated to achieve an Activated Clotting Time (ACT) of twice to treble of the baseline.

Low Molecular Weight Heparins (LMWH) have been shown in recent years to be more effective and safer than heparin in the prevention of thromboembolic events after coronary angioplasty and stent placement. (30, 31) In our practice, upon completion of the intervention, heparin was discontinued and anticoagulation was preserved for 3 days with low molecular weight heparins (LMWH). Patients were continued on Clopidogrel 75 mg for 6 weeks and aspirin 100mg for six months postoperatively.

Conclusion

Neuroform microstent system led to a significant evolution in the endovascular treatment of complex intracranial aneurysms. Our results and midterm follow-up showed that Neuroform stent-assisted coil embolization is a safe and effective technique in the treatment of the complex cerebral aneurysms. Although, the clinically significant complications are uncommon and the evaluation at midterm follow-up are encouraging, further studies are needed to assess the long-term stability and the durability of the stent.

References

1. Richling B, MD History of endovascular surgery: Personal Accounts of the Evolution. *Neurosurgery* 59:s3-30-s3-38, 2006
2. Malek AM, Higashida RT, Phatouros CC, Dowd CF, and Halbach VV: Treatment of an intracranial aneurysm using a new three-dimensional-shape Guglielmi detachable coil: Technical case report. *Neurosurgery* 44:1142–1145, 1999.
3. Henkes H, Fischer S, Weber W, et al. Endovascular coil occlusion of 1811 intracranial aneurysms: early angiographic and clinical results. *Neurosurgery* 2004; 54: 268-80.
4. Brilstra EH, Rinkel GJ, van der Graaf Y, van Rooij WJ, Algra A. Treatment of intracranial aneurysms by embolization with coils: a systematic review. *Stroke* 1999;30:470-6.
5. Shanno GB, Armonda RA, Benitez RP, Rosenwasser RH. Assessment of acutely unsuccessful attempts at detachable coiling in intracranial aneurysms. *Neurosurgery* 2001; 48:1066-72.
6. Murayama Y, Nien YL, Duckwiler G, et al. Guglielmi detachable coil embolization of cerebral aneurysms: 11 years' experience. *J Neurosurg* 2003; 98:959-66.
7. Thornton J, Debrun GM, Aletich VA, Bashir Q, Charbel FT, Ausman J. Follow-up angiography of intracranial aneurysms treated with endovascular placement of Guglielmi detachable coils. *Neurosurgery* 2002; 50:239-49.
8. Moret J, Pierot L, Boulin A, et al.: Remodeling of the arterial wall of the parent vessel in the endovascular treatment of intracranial aneurysms. *Neuroradiology* 1994;36:Suppl 1:S83.
9. Akpek S, Arat A, Morsi H, Klucznick RP, Strother CM, Mawad ME: Self-expandable stent-assisted coiling of wide-necked intracranial aneurysms: A single-center experience. *AJNR Am J Neuroradiol* 26:1223-1231, 2005.
10. Alfke K, Straube T, Dorner L, Mehdorn HM, Jansen O: Treatment of intracranial broad-neck aneurysms with a new self-expanding stent and coil embolization. *AJNR Am J Neuroradiol* 25:584-591, 2004
11. Benitez RP, Silva MT, Klem J, Veznedaroglu E, Rosenwasser RH: Endovascular occlusion of wide-necked aneurysms with a new intracranial microstent (Neuroform) and detachable coils. *Neurosurgery* 54:1359-1368, 2004.
12. Fiorella D, Albuquerque FC, Deshmukh VR, McDougall CG: Usefulness of the Neuroform stent for the treatment of cerebral aneurysms: Results at initial (3-6-mo) follow-up. *Neurosurgery* 56:1191-1202, 2005.
13. Howington JU, Hanel RA, Harrigan MR, Levy EI, Guterman LR, Hopkins LN: The Neuroform stent, the first microcatheter-delivered stent for use in the intracranial circulation. *Neurosurgery* 54:2-5, 2004.
14. Higashida RT, Halbach VV, Dowd CF, Juravsky L, Meagher S: Initial clinical experience with a new self-expanding nitinol stent for the treatment of intracranial cerebral aneurysms: The Cordis Enterprise stent. *AJNR Am J Neuroradiol* 26:1751-1756, 2005.
15. Pumar JM, Blanco M, Vazquez F, Castineira JA, Guimaraens L, Garcia-Allut A: Preliminary experience with Leo self-expanding stent for the treatment of

- intracranial aneurysms. *AJNR Am J Neuroradiol* 26:2573-2577, 2005.
16. Lylyk P, Ferrario A, Pasbon B, Miranda C, Doroszuk G: Buenos Aires experience with the Neuroform self-expanding stent for the treatment of intracranial aneurysms. *J Neurosurg* 102:235-241, 2005.
17. Fiorella D, Albuquerque FC, Han P, McDougall CG: Preliminary experience using the Neuroform stent for the treatment of cerebral aneurysms. *Neurosurgery* 54:6-17, 2004.
18. Benndorf G, Campi A, Schneider GH, Wellnhofer E, Unterberg A: Overlapping stents for treatment of a dissecting carotid artery aneurysm. *J Endovasc Ther* 8:566-570, 2001.
19. Higashida RT, Smith W, Gress D, Urwin R, Dowd CF, Balousek PA, Halbach VV: Intravascular stent and endovascular coil placement for a ruptured fusiform aneurysm of the basilar artery. Case report and review of the literature. *J Neurosurg* 87:944-949, 1997.
20. Wakhloo AK, Lanzino G, Lieber BB, Hopkins LN: Stents for intracranial aneurysms: The beginning of a new endovascular era? *Neurosurgery* 43:377-379, 1998.
21. Sekhar LN, Stimac D, Bakir A, Rak R: Reconstruction options for complex middle cerebral artery aneurysms. *Neurosurgery* 2005;56(1Suppl):66-74 [discussion 66-74].
22. Wanke I, Doerfler A, Schoch B, Stolke D, Forsting M: Treatment of wide necked intracranial aneurysms with a self-expanding stent system: Initial clinical experience. *AJNR Am J Neuroradiol* 2003;24:1192-9.
23. Liang G, Gao X, Li Z, Wei X, Xue H: Neuroform stent-assisted coiling of intracranial aneurysms: a 5 year single-center experience and follow-up. *Neurol Res* 2009 Aug 5. [Epub ahead of print]
24. Biondi A, Janardhan V, Katz JM, Salvaggio K, Riina HA, Gobin YP: Neuroform stent-assisted coil embolization of wide-neck intracranial aneurysms: strategies in stent deployment and midterm follow-up. *Neurosurgery* 2007;61(3):460-8 [discussion 8-9].
25. Eduardo Wajnberg, Jorge Marcondes de Souza, Edson Marchiori, Emerson L. Gasparetto. Single-center experience with the Neuroform stent for endovascular treatment of wide-necked intracranial aneurysms. *Surgical Neurology, Volume 72, Issue 6, December 2009, Pages 612-619*
26. Katz JM, Tsiouris AJ, Biondi A, Salvaggio KA, Ougorets I, Stieg PE, Riina HA, Gobin YP: Advances in endovascular aneurysm treatment: Are we making a difference? *Neuroradiology* 47:695-701, 2005.
27. Yahia AM, Latorre J, Gordon V, et al. Thromboembolic events associated with Neuroform stent in endovascular treatment of intracranial aneurysms. *J Neuroimaging*. Epub ahead of print 26 June 2009
28. Leon MB, Baim DS, Popma JJ, Gordon PC, Cutlip DE, Ho KK, Giambartolomei A, Diver DJ, Lasorda DM, Williams DO, Pocock SJ, Kuntz RE; Stent Anticoagulation Restenosis Study Investigators: A clinical trial comparing three antithrombotic-drug regimens after coronary-artery stenting. *N Engl J Med* 339:1665-1671, 1998.
29. Caprie Steering Committee: A randomised, blinded, trial of clopidogrel versus aspirin in patients at risk of ischaemic events (CAPRIE). *Lancet* 348:1329-1339, 1996.
30. Daoulah A, Segev A, Leblanc K, et al. Post procedural low molecular weight heparin in patients at high risk of sub acute stent thrombosis. *Cardiovasc Radiat Med* 2003 Oct-Dec; 4:182-85
31. Yan AT, Goodman SG. Low-molecular-weight heparins in ischemic heart disease. *Curr Opin Cardiol* 2004; 19:309-16.