

## POSTERIOR FOSSA ARTERIOVENOUS MALFORMATIONS - CASE REPORT

ANGELA NEACSU MD, PROF RADU MIRCEA GORGAN MD PHD,  
NARCISA BUCUR MD PHD, AURA SANDU MD, MIHAI VIOREL PRUNA MD

First Neurosurgical Clinic, Fourth Neurosurgical Department  
Clinic Emergency Hospital "Bagdasar-Arseni", Bucharest

The posterior fossa arteriovenous malformation (AVM) is uncommon and different from other intracranial AVM in its natural history, diagnosis, treatment, prognosis, and other features. The authors present the case a 19 y.o. woman admitted for comatose state, GCS=6 points, left hemiparesis, flexion of right limbs on noxious stimuli, mydriasis with bilaterally preservation of oculomotor reflex and acute respiratory failure. Cerebral CT scan showed an intraparenchymal hematoma, located into the posterior cranial fossa, within the vermis, measuring 2.8/3.2 cm, with important surrounding edema, intraventricular bleeding within the third and fourth ventricle, massive infratentorial subarachnoid hemorrhage and acute hydrocephalus. Cerebral four vessels angiography showed an infratentorial AVM (arteriovenous malformation), located within the right cerebellar hemisphere, with a nidus, measuring around 3 cm maximal diameter, in the craniocaudal direction. The AVM had arterial feeders coming from the right posterior cerebral artery and superior cerebellar artery and venous drainage into the Galen vein, Herophil torcula, and right lateral sinus. We conclude the diagnosis of right ruptured cerebellar hemisphere AVM, grade Martin-Spetzler III, Hunt and Hess 5 and the choice treatment was open surgery. Authors insist on neurosurgical strategy for treatment which in our case conducted to excellent results.

**Keywords:** arteriovenous malformation, infratentorial location, posterior fossa

### INTRODUCTION

Arteriovenous malformations of the infratentorial space pose a unique technical challenge for neurovascular surgeons. Until recently, the surgical risk for resection of arteriovenous malformations in this location was considered unacceptable. With increasing experience and the refinements in surgical and anesthetic techniques, however, procedures once considered to court disaster can now be achieved with acceptable morbidity rates (4, 13).

### CASE REPORT

C.M.P., 19 y.o. woman, was admitted into the Fourth Neurosurgical Department, Intensive Care Department from the Emergency Clinical Hospital Bagdasar-Arseni, Bucharest. At admission the patient was comatose, GCS (Glasgow Coma Scale) 6 points. The patient presented with the sudden onset of

headache in conjunction with gait difficulty and left-sided dysmetria 48 hours prior admission, followed by progressive loss of consciousness.

She was evaluated after admission with CT scan, DSA, and basic evaluation for general health problems (blood tests, EKG, chest x-ray, cardiologic evaluation, ophthalmologic examination).

The patient presented acute respiratory failure, which required orotracheal intubation and mechanical ventilation. Physical examination found systolic blood pressure of 120 mmHg and heart rate of 90 beats/minute.

Neurological exam on admission revealed comatose state, GCS=6 points, left hemiparesis, flexion of right limbs on noxious stimuli, abnormally increased deep tendon reflexes on left limbs, Babinsky's sign at the left foot and absent cutaneous plantar response at

the right foot. She also had mydriasis with bilaterally preservation of oculomotor reflex.

The patient had no relevant history.

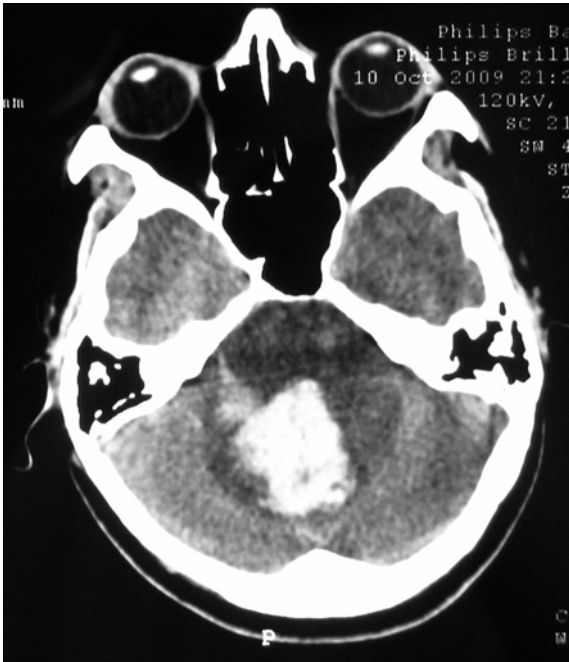

FIG. 1.1

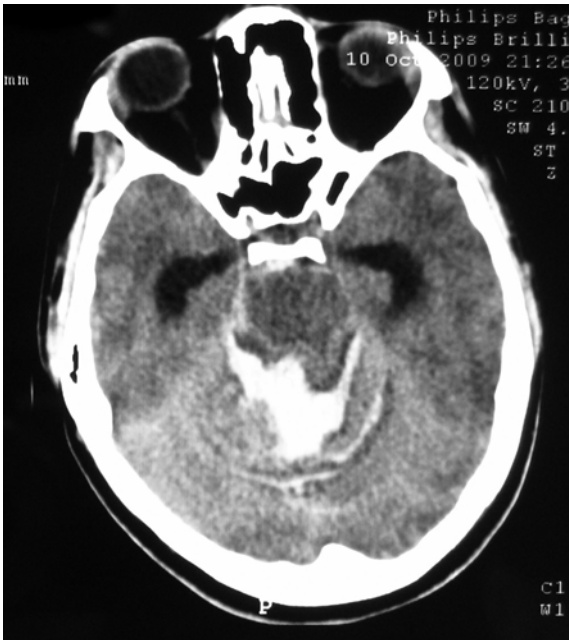

FIG. 1.2

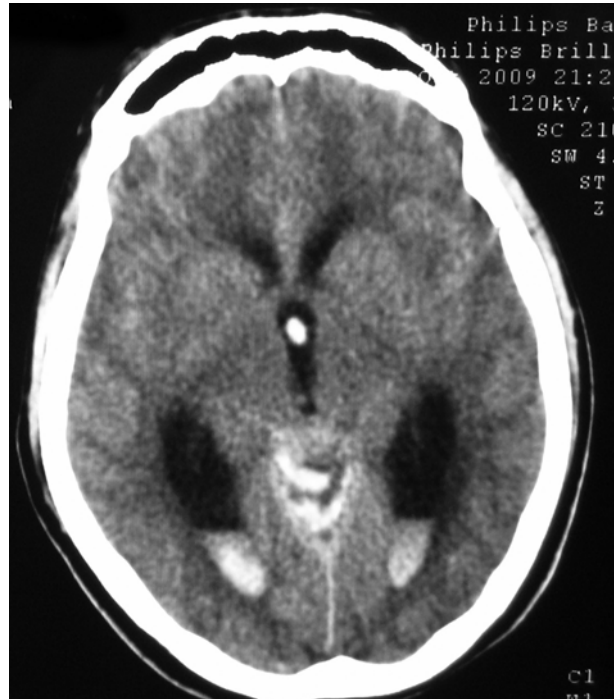

FIG. 1.3

FIG. 1.1, 1.2, 1.3 Cerebral CT scan showed an intraparenchymal hematoma, located into the posterior cranial fossa, within the vermis, measuring 2.8/3.2 cm, with important surrounding edema, intraventricular bleeding within the third and fourth ventricle, massive infratentorial subarachnoid hemorrhage and acute hydrocephalus.

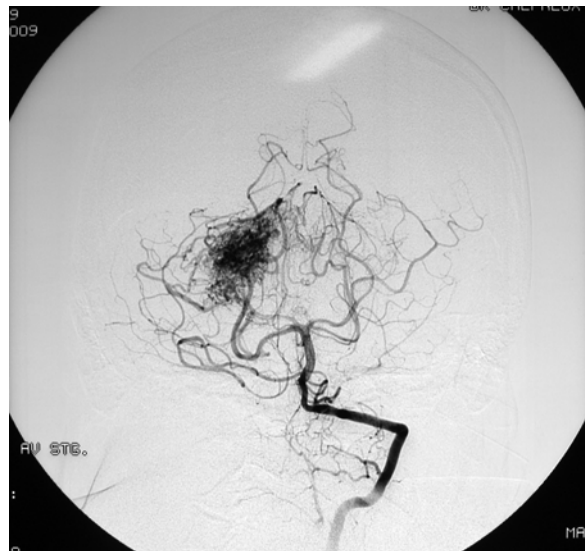

FIG. 2.1

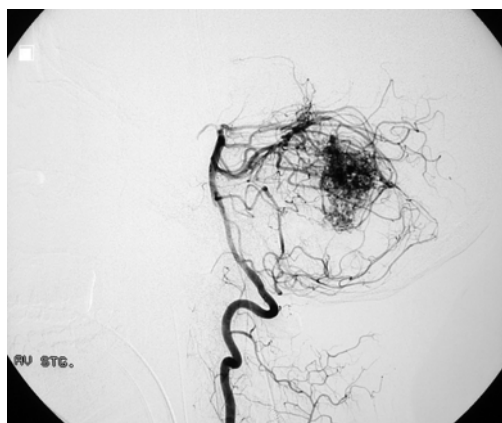

FIG. 2.2

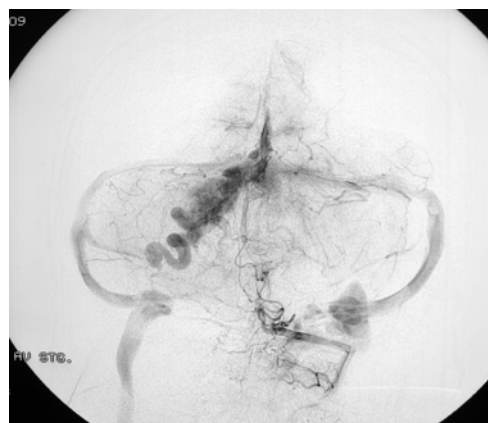

FIG. 2.5

Fig. 2.1, 2.2, 2.3, 2.4, 2.5 DSA - left vertebral angiogram

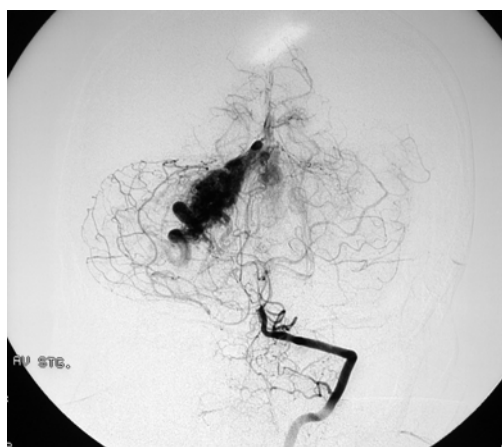

FIG. 2.3

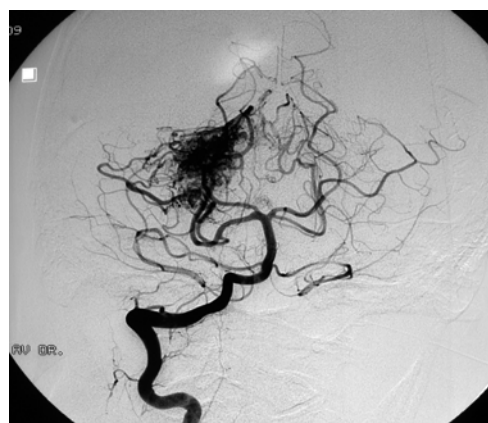


FIG. 3.1

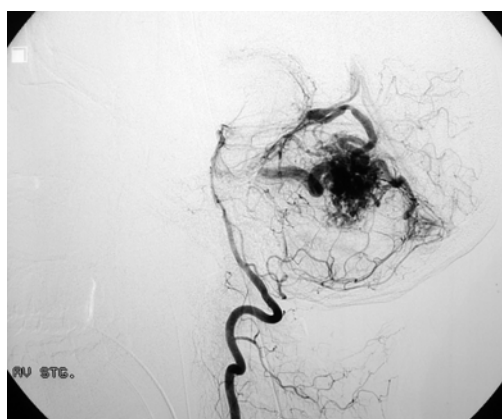


FIG. 2.4

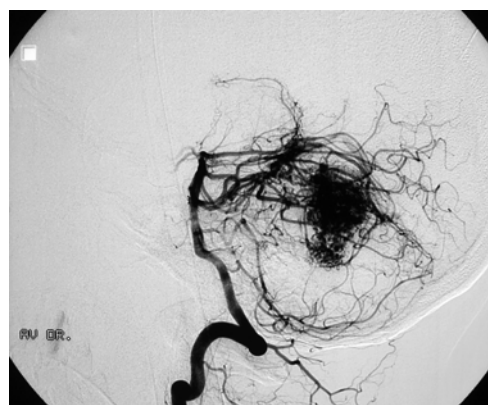


FIG. 3.2



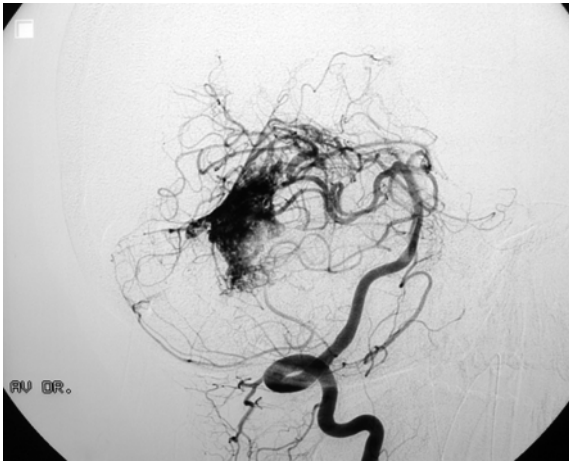


FIG. 3.3

FIG. 3.1, 3.2, 3.3 DSA – right vertebral angiogram

Cerebral four vessels angiography showed an infratentorial AVM (arteriovenous malformation), located within the right cerebellar hemisphere, with a nidus, measuring around 3 cm maximal diameter, in the craniocaudal direction. The AVM had arterial feeders coming from the right posterior cerebral artery and superior cerebellar artery and venous drainage into the Galen vein, Herophil torculla, and right lateral sinus. The AVM is injected from both vertebral arteries, the right vertebral artery being more prominent.

We conclude the diagnosis of right cerebellar hemisphere AVM, grade Martin-Spetzler III, Hunt and Hess 5.

Endovascular embolisation was concluded to be not possible because of very small diameter of feeding vessels, and poor neurological condition of the patient, related specially to the hematoma surrounding the AVM, with severe mass effect.

Family decided for surgery and patient was operated. We performed a bilateral posterior fossa craniectomy, extended on the right side 0.5 cm superior to the transverse sinus. After dura mater incision and occipital sinus ligation, opening the magna cistern was performed. Then, we performed an equatorial corticotomy, within the right cerebellar hemisphere and at 1.5 cm depth, cloths and the AVM was found. After careful dissection of the nidus, we controlled feeding arteries arising from right posterior cerebral artery and

superior cerebellar artery, followed by closure of the drainage veins into the Herophil torculla and right lateral sinus. We put a vascular clip on a deep drainage vein into the Galen vein. Careful hemostasis and wound closure were the final steps of the operation.

Mean operating time was 6 hours. During surgery the patient received 8 blood units, 2 fresh frozen plasma units.

Postoperative outcome was favorable, after 12 hours the patient was extubated, she regained consciousness, and was able to execute correctly simple motor commands. During next days the neurological outcome was favorable.

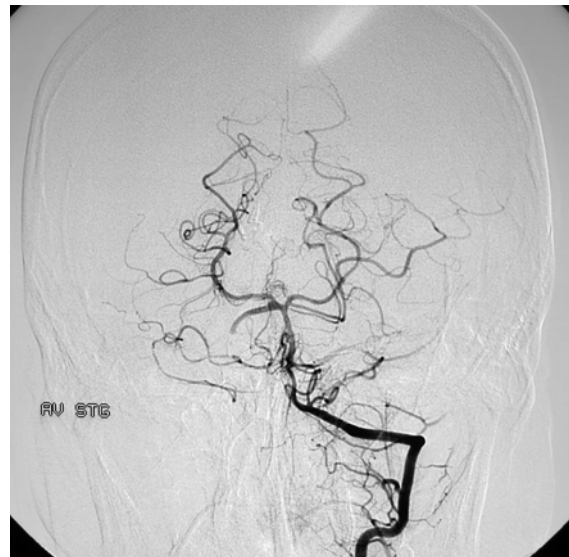


FIG. 4.1

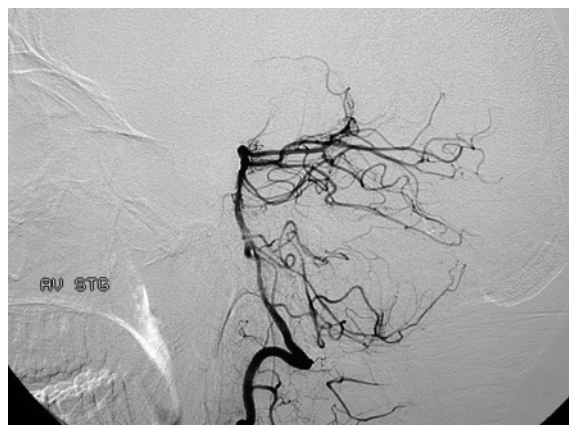

FIG. 4.2

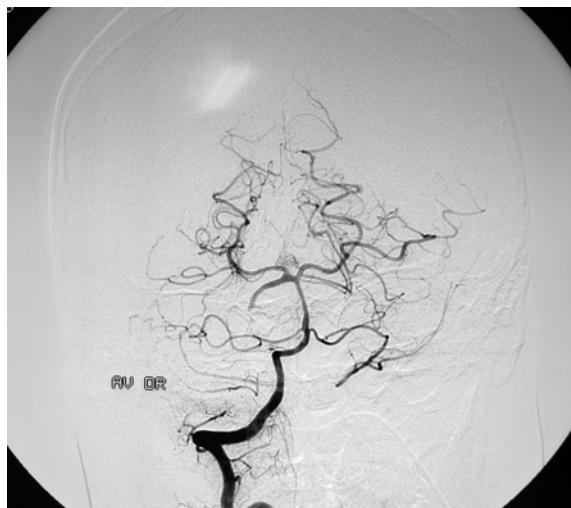

FIG. 4.3

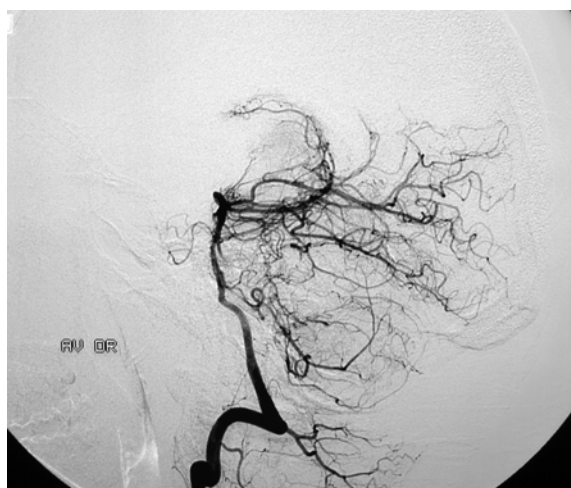

FIG. 4.4

FIG. 4.1, 4.2, 4.3, 4.4 Postoperative angiographic studies obtained in the same patient. Anteroposterior and lateral projections reveal complete resection of the cerebellar AVM and excellent flow through the vertebralbasilar circulation

## DISCUSSION

Arteriovenous malformations (AVMs) of the posterior fossa are complex neurovascular lesions that are less common than their supratentorial counterparts, accounting for < 15% of all AVMs (1, 2, 5, 6). The majority of patients with these lesions present with intracranial hemorrhage (3, 7, 14). Accumulating data have demonstrated an independent association of

infratentorial AVM location and hemorrhagic presentation (9, 12, 15). This is alarming in light of the considerably greater morbidity and mortality associated with posterior fossa AVM rupture (8). Fortunately, with accumulating surgical experience and the cultivation of multimodality AVM therapy, therapeutic success continues to improve (11).

Management is complicated by eloquence of adjacent neurological structures, multimodality treatment is often necessary, and obliteration is not always possible.

Because most posterior fossa AVMs present with intraparenchymal hemorrhage, the initial surgical focus is directed at hematoma removal and treatment of any acute mass effect or hydrocephalus if it is present. When feasible, however, definitive resection of the AVM should be deferred for 4 to 6 weeks. Delayed extirpation in this manner often ensures sufficient time for brain swelling to diminish and the hematoma to liquefy, features which greatly facilitate ultimate AVM excision. Late treatment is also of benefit in that associated cerebral aneurysms, which might initially be obscured by intraparenchymal hemorrhage on the first angiogram, could later be well visualized after a brief period of quiescence. On rare occasions, a patient who needs early hematoma evacuation may require complete AVM resection during the same operation because of intraoperative hemorrhage. In such a situation, every effort is made to preserve all viable cerebellar tissue as well as alleviate any undue mass effect on the brainstem.

Intraoperative technical considerations for cerebellar hemispheric AVMs.

The basic tenets of AVM resection are the same for lesions both above and below the tentorium. The principles of optimal patients positioning, adequate bony exposure, extensive dural opening, meticulous attention to sharp microdissection, and compulsive hemostasis are critically important during surgical resection of posterior fossa AVMs (4, 10).

Both the PICA and AICA are dissected in the subarachnoid space and followed to their entry point into the malformation, at which point they are clipped and divided. As with vermian AVMs, the SCA feeding vessels to hemispheric malformations are often

obscured early in the treatment by the dilated venous drainage running over the superior aspect of the cerebellum into the galenic system. Dissection proceeds circumferentially, favoring the medial aspect of the AVM. The AVM is usually hinged on its venous drainage along the lateral aspect of the hemisphere; hence, medial-to-lateral dissection continues into deeper levels to undercut the AVM toward its anterior border. Late bleeding during the resection is invariably due to deep AICA feeding vessels at the peripendymal level that are rather easily controlled using bipolar electrocautery with entry into the fourth ventricle. When all arterial inflow to the malformation is eliminated, the AVM can be delivered from the resection bed, tethered only by a final venous outflow pedicle, which can then be transected (4, 10).

**CONCLUSION**

In this particular case the strategy of complete treatment of a ruptured posterior fossa AVM in one surgical step was very difficult, but successful. Neurological and general evolution after neurosurgical procedure was without incidents with a very good outcome.

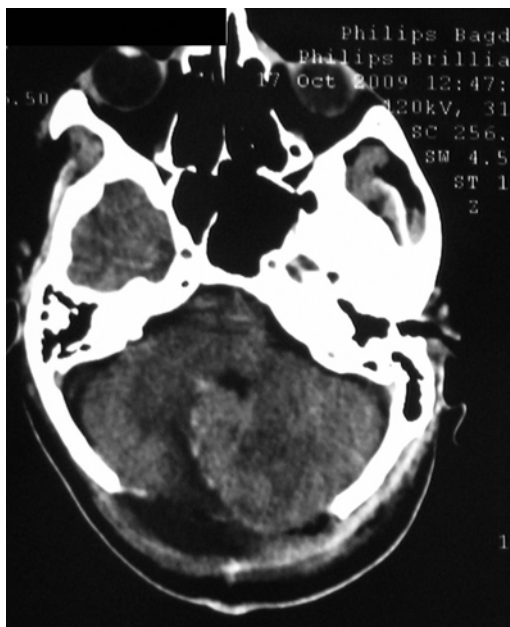


FIG. 5.1

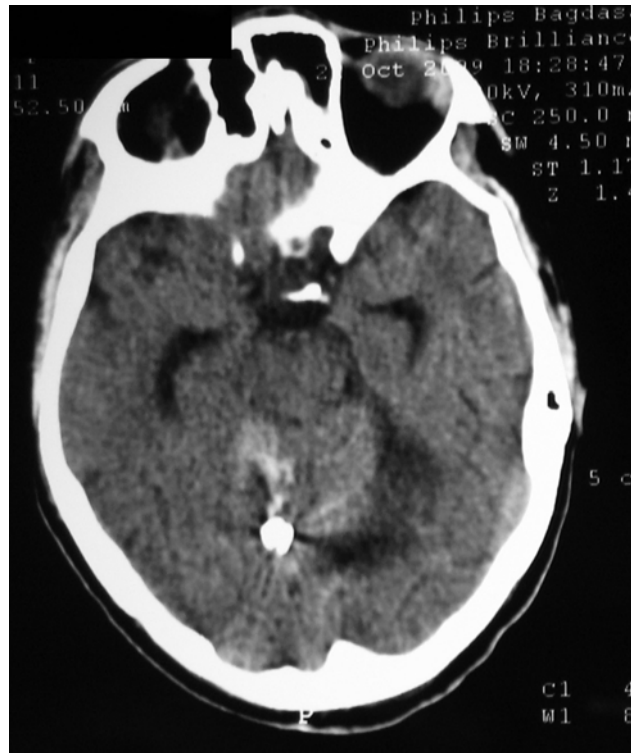

FIG. 5.2

FIG. 5.1, 5.2 Postoperator CT scan showed posterior fossa craniectomy, right paravermian vascular clip.

The patient was discharged in 10 days after surgery

**REFERENCES**

1. Al-Shahi R, Warlow C: A systematic review of the frequency and prognosis of arteriovenous malformations of the brain in adults. *Brain* 124:1900–1926, 2001
2. Batjer H, Samson D: Arteriovenous malformations of the posterior fossa: clinical presentation, diagnostic evaluation and surgical treatment. *Neurosurg Rev* 9:287–296, 1986
3. da Costa LB, Thines L, Dehdashti AR, Wallace MC, Willinsky RA, Schwartz M, et al: Management and clinical outcome of posterior fossa arteriovenous malformations: report on a single-center 15-year experience. *J Neurol Neurosurg Psychiatry* 80:376–379, 2009
4. David CA, Vishteh AG, Spetzler RF: *Surgical Approaches: Infratentorial and Brain Stem Lesions, Vascular Malformations of the Central Nervous System*, edited by J.J. Jafar, I.A. Awad and R.H. Rosenwasser, Lippincott Williams&Wilkins, Philadelphia, 1999, 327-338.
5. Drake CG, Friedman AH, Peerless SJ: Posterior fossa arteriovenous malformations. *J Neurosurg* 64:1–10, 1986
6. Fleetwood IG, Steinberg GK: Arteriovenous malformations. *Lancet* 359:863–873, 2002

## ANGELA NEACSU

- 7.Hernesniemi JA, Dashti R, Juvela S, Vaart K, Niemela M, Laakso A: Natural history of brain arteriovenous malformations: a long-term follow-up study of risk of hemorrhage in 238 patients. *Neurosurgery* 63:823–831, 2008
- 8.Kelly ME, Guzman R, Sinclair J, Bell-Stephens TE, Bower R, Hamilton S, et al: Multimodality treatment of posterior fossa arteriovenous malformations. *J Neurosurg* 108:1152–1161, 2008
- 9.Khaw AV, Mohr JP, Sciacca RR, Schumacher HC, Hartmann A, Pile-Spellman J, et al: Association of infratentorial brain arteriovenous malformations with hemorrhage at initial presentation. *Stroke* 35:660–663, 2004
- 10.Marciano FF, Vishteh AG, Karahalios DG, Spetzler RF: Arteriovenous Malformations-Infratentorial, *Operative Neurosurgery*, edited by Andrew H. Kaye and Peter McL. Black, Harcourt Publishers Limited 2000, 1093-1106
- 11.Omar M. Arnaout, B.A., Bradley A. Gross, M.D., Christopher S. Eddleman, M.D., Ph.D., Bernard R. Bendok, M.D., Christopher C. Getch, M.D., H. Hunt Batjer, M.D.: Posterior fossa arteriovenous malformations, *Neurosurg Focus* 26 (5):E12, 2009
- 12.Ondra SL, Troupp H, George ED, Schwab K: The natural history of symptomatic arteriovenous malformations of the brain: a 24-year follow-up assessment. *J Neurosurg* 73:387–391, 1990
- 13.Samson DS, Batjer HH: Posterior fossa arteriovenous malformations. In: Carter LP, Spetzler RF, Hamilton MG, eds. *Neurovascular surgery*, New York: McGraw-Hill, 1995:1005-1015
- 14.Symon L, Tacconi L, Mendoza N, Nakaji P: Arteriovenous malformations of the posterior fossa: a report on 28 cases and review of the literature. *Br J Neurosurg* 9:721–732, 1995
- 15.Wilkins RH: Natural history of intracranial vascular malformations: a review. *Neurosurgery* 16:421–430, 1985