

Evaluation of Post-Operative Complications of Subcondylar Fractures Treated with Conservative Method

Luay Hatem Jalil

Department of oral and maxillofacial surgery at Al-Shaheed Ghazi-Alhareeri Hospital

Luay.hjalil@gmail.com

ARTICLE INFO

Submission date: 10/4/2019

Acceptance date: 19/5/2019

Publication date: 1/6/2019

Abstract

The aim: The aim of this prospective study is to evaluate the scope of conservative method effectiveness in the treatment of sub-condylar fracture of the mandible through the assessment the possible complications.

Materials and method: 20 patients with unilateral sub-condylar fracture were treated with conservative method by arch bar and stainless steel wires, and then evaluate the possible post-operative complications, the follow up examinations, including clinical, radiographic measurements, and subjective parameter like pain by visual analogue scale (VAS) for period of (4) months, including (6) visits .

Results: Post-operatively, regarding deviation, radiographically, in (70%) of the patients, the deviation is not significant (<3%) [i.e. the deviation not clear clinically, although it indeed radiographically exist], in (15%) of the patients is significant (>3%) [clinically mild deviation], and the others (15%) of the patients are symmetrical (0%). The visual analogue scale (VAS) of pain shows significant mean difference related to sex ($p=0.031$), the pain is higher in female, however, it decreases in both sexes with the time. There is a significant indirect strong correlation ($p=0.001$) between pain and mouth opening limitation. Lastly, the limitation of mouth opening is not significant to sex ,age, deviation, or the cause of fracture.

Conclusion: The adjustment of occlusion during IMF for patient with subcondylar fracture treated with closed reduction, play an important role in minimizing the possible post-operative facial asymmetry. Most patients with subcondylar fracture, especially those with mild or moderate displacement (less than 45 degrees) can be successfully treated with closed reduction with minimal post-operative complications.

Keywords: post-operative, conservative method, stainless steel wires, clinical, radiographic measurements

Introduction

Fractures of the mandibular condyle are common and account for 25-35% of all mandibular fractures and they are the most controversial fractures regarding diagnosis and management [1]. The mandibular condyle is a region that plays a key role in the opening and closing of the mouth, and because it causes functional and aesthetic problems such as facial asymmetry, it is very important to perform accurate reduction[2].

Condylar fractures are classified according to the anatomic location (intracapsular and extracapsular) and degree of dislocation of the articular head[2]. The most common external causative factor is car accident, violence, industrial hazard, fall, sports, and gunshot wound are also included in the external causative factors. Fracture of the condyle can be treated either by closed or open method, open reduction with internal fixation is technically difficult, leaves a visible external scar, and has the risk of facial nerve injury, avascular necrosis, resorption, and arthrosis.[2][3]

Ellis et al. reported that the open reduction having a better prognosis than closed reduction under appropriate indications and conditions, and the development of radiological diagnosis and surgery techniques is seen as playing a role in viewing such results.[4], while Archer made an extreme claim, saying that there is no indication for open reduction because it causes the problems of trismus or ankylosis and sterile or suppurative resorption .[4]

In general, if a patient has an acceptable range of motion, relatively good occlusion, and minimal pain, it is ideal to perform observation or closed reduction and maxillo-mandibular fixation.[5]

According to Zide, in cases with displacement and ramus height instability, either of these two actually become indications of open reduction.[5]

Haug and Assael reported that no statistically significant difference in occlusion status and complication such as mandibular movement restriction was found between open and closed reductions for mandibular condyle fracture.[6] Ellis et al. reported that complications such as intra-operative bleeding and postoperative infection, facial nerve paralysis, functional disorder of the auriculo-temporal nerve, and condyle growth disorder significantly increased when open reduction was conducted to treat condylar head and neck fractures, and that closed reduction was more advantageous than open reduction.[6]. In the study of the Santler et al. reported there is no significant difference in mobility, joint problems, occlusion, muscle pain, or nerve disorders were observed when the surgically and non-surgically treated patients were compared. The only significant difference was in subjective discomfort. Surgically treated patients showed significantly more weather sensitivity and pain on maximum mouth opening. Because of these disadvantages, open surgery is only indicated in patients with severely dislocated condylar process fractures.[7]

According to these controversies, this thesis try to evaluate the conservative and closed method and minimize post-operative complications.

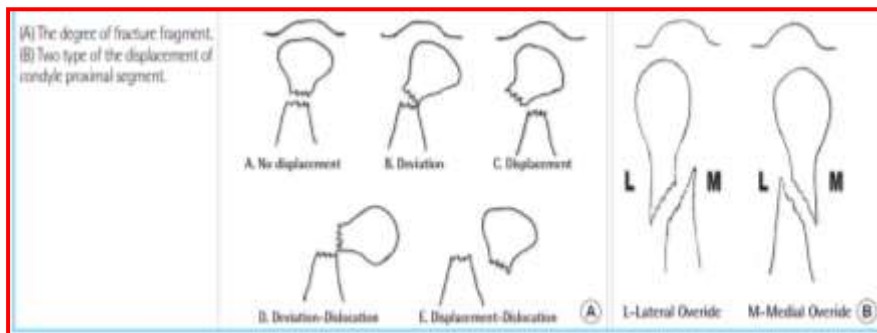
Classification of condylar fractures

MacLennan created a classification system based on deviation, displacement and dislocation of fragments in relation to the glenoid fossa [2][12]. (Fig. 1)

Condylar fracture also can be classified as follows according to Lindahl classification, it is classified into condyle head fracture, condyle neck fracture, and subcondyle fracture according to fracture position.[8] (Fig. 2).

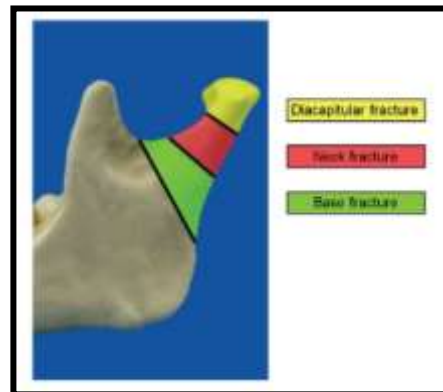
Condylar head fracture is also called intracapsular fracture as the joint capsule exists until the condyle neck[13]. It is an extracapsular fracture as it is not included in the joint capsule, and exists at the inferior attached area of the lateral pterygoid. The most commonly observed type is the displacement of the condyle head to the anteromedial side, which is shown in a fracture that occurs inferiorly to the lateral pterygoid muscle .[5][11]

The majority of mandibular condyle fractures involve the condylar neck, with few reports of intracapsular fractures. Sagittal or vertical fractures of the mandibular condyle are rare.[6]



(Fig. 1): Classification of condylar fractures according to MacLennan

(Fig. 2)
Classification of condylar
fractures according to Lindahl



Patients collection and definitions

A prospective study targeting 20 patients (3 females, 17 males), average age (28) years , age range (19 to 44) years , whose records were completely preserved and whose symptoms had improved was conducted at the Department of Oral and Maxillofacial Surgery, at Al-Shaheed Ghazi-Alhareeri Hospital . All patients were diagnosed with condylar fracture based on clinical findings supported by radiograph and follow up period ranged from (4 to 6) months after removal of IMF.

In this study, selection of patients based on the following criteria :

-Inclusion criteria:

Patient with unilateral sub-condylar fracture at 18 years of age or more, and the fracture can be treated with closed reduction or conservative treatment.

-Exclusion criteria:

We will exclude the cases which need absolute open reduction such as:

- 1-lateral extracapsular displacement.
- 2-Dislocation of condylar head into middle cranial fossa or external auditory meatus.
- 3-Open joint wound with foreign body or gross contamination.

In addition, medically compromised patients and pregnant women have been excluded.

Evaluation of patients with condylar fracture

At the initial visit , for every patient, demographic data, chief complaint, thorough history were collected, clinical examination for the condyle, mouth opening, dentition and occlusion, deviation , severity of pain and any other signs also cause of trauma and medical history were performed .

Conventional radiography orthopantomography (OPG), P.A view was taken to determine site of fracture (extra- or intra-capsular),and severity of displacement.

All patients are treated with closed method under local anesthesia, some of them by using Erick type arch bar and stainless steel wire , while the other by using eyelets. According to the severity of fracture, the period of IMF ranged from (4 to 6) weeks. After removal of IMF, the post-operative follow up period extend to more than (6) months later to evaluate the following parameters:

1-Occlusion:

Occlusion can be assessed and adjusted pre-operatively directly from the mouth before fixation, and then post-operatively, occlusion evaluation depend on history, enamel attrition, patient satisfaction, TMJ pain free, and functional occlusion.

2-Deviation:

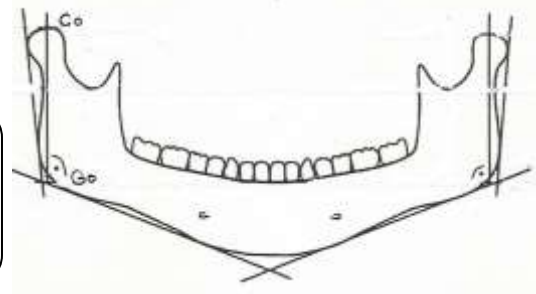
Severity of condylar fracture displacement may cause clinical mandibular deviation during mouth opening due to ramus height shortening, there is no perfect clinical method to determine the deviation just depend on experience, however, significant shortening lead to obvious disfigurement.

Radiographically, (20) patients with previous condylar fracture with post-operative (OPG) have been used to measure the ramus height of the fractured and non fractured side from the highest point of condyle (condylion Co) to the angle of the mandible (gonion Go) (Fig. 3). Gonion (Go) point is determined by bisecting the angle formed by tangents to the lower and posterior borders of the mandible, however, this method depend on experiency of operator when determine the points and depend on the quality of OPG.

The values were then put into the formula described by Habetes et al in 1988, $(R-L)/(R+L) \times 100$,and the asymmetry was expressed in percentage.

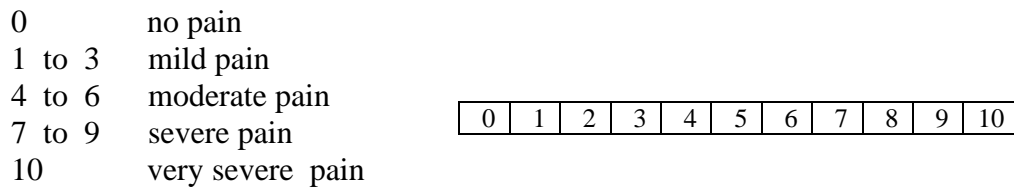
R=height in mm. of right ramus
L=height in mm. of left ramus

Fig. (3)
diagram of (OPG) for mandible show the condylion (Co) and gonion (Go). The line represent the vertical height of the ramus from (Go) to (Co)



3-pain:

Post-operatively, the pain is located in the TMJ and/or muscles, usually the masseter and temporalis muscles on the affected side. The pain will be evaluated by the patient (him/her self) by using the visual analogue scale (VAS) calibrating from 0 to 10 . (Fig. 4)



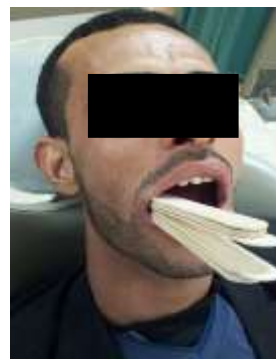(Fig. 4)
Visual analogue scale (VAS)

4-Mouth opening limitation:

The post-operative mouth opening limitation can be treated by physiotherapy (the normal inter-incisal opening usually exceed 40 mm). Functional therapy which consists of passive mandibular movement and mouth opening exercise, (usually by wood tongue depressor) to gain a normal range of inter-incisal opening. Analgesic may be necessary in the beginning . (Fig. 5 , 6).

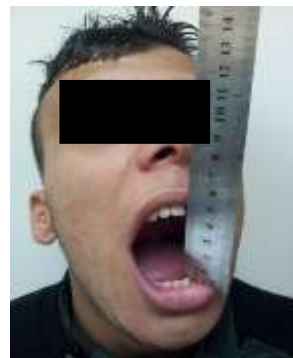(Fig. 5)

**Patient with post-operative physiotherapy
by using wood tongue depressor**



(Fig. 6)

**Measurement of inter-incisal opening
which is usually exceed (40) mm**

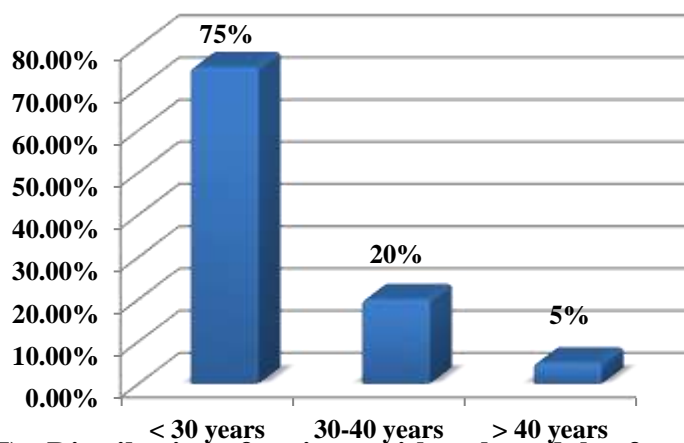


Results

1- Distribution of patients by age, sex and etiology of condylar fracture

This study has been carried out on twenty patients with condylar fracture. The overall mean age of the patients was (28.00± 6.02) years old. Majority (75.0%) of the patients aged younger than 30 years (Figure 7). there was no significant mean difference between the mean age of male patients (27.76± 5.98) and female patients (29.33± 7.37) t=0.407, df= 18, p= 0.689.

<i>Range of age</i>	<i>Frequency</i>	<i>Percent %</i>
<i>Less than 30 y.</i>	<i>15</i>	<i>75%</i>
<i>30-40 y.</i>	<i>4</i>	<i>20%</i>
<i>More than 40 y.</i>	<i>1</i>	<i>5%</i>
<i>Total</i>	<i>20</i>	<i>100.0%</i>



(Fig.7) : Distribution of patients with subcondylar fracture by age

Figure (8) shows the distribution of patients with condylar fracture by sex, majority (85%) of the patients were male.

(Fig. 8) sex distribution

<i>Sex</i>	<i>Frequency</i>	<i>Percent %</i>
<i>Male</i>	<i>17</i>	<i>85%</i>
<i>Female</i>	<i>3</i>	<i>15%</i>
<i>Total</i>	<i>20</i>	<i>100.0%</i>

Figure (9) shows the distribution of patients with condylar fracture by etiology of the fracture, only (45%) of the condylar fracture has been caused by RTA.

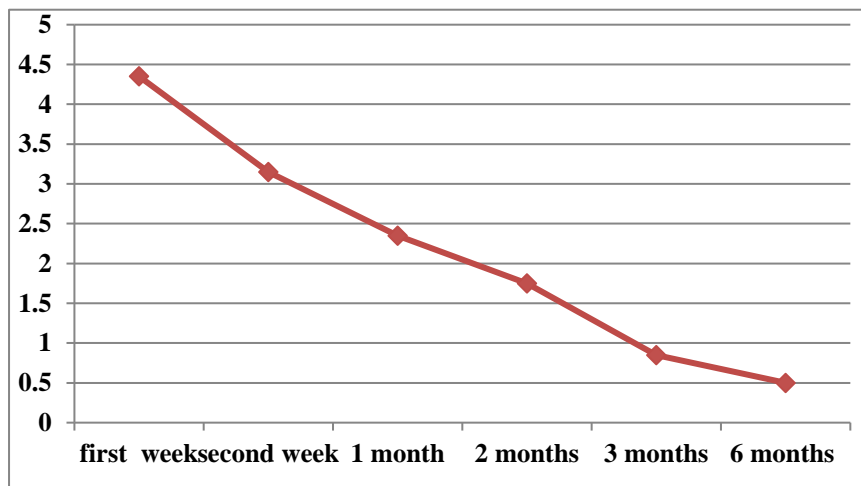
(Fig. 9) Etiology distribution

<i>Etiology</i>	<i>Frequency</i>	<i>Percent %</i>
<i>RTA</i>	<i>9</i>	<i>45%</i>
<i>FFH</i>	<i>4</i>	<i>20%</i>
<i>Fighting</i>	<i>6</i>	<i>30%</i>
<i>Sporting</i>	<i>1</i>	<i>5%</i>

2- Distribution of patients with condylar fracture by pain

Pain levels determined by visual analogue scale (VAS), the pain decrease in severity with time and in most patients disappear completely after several weeks or few months (Figure 10).

<i>Time</i>	<i>Average of pain by (VAS)</i>
<i>Fist week</i>	<i>4.35</i>
<i>Second week</i>	<i>3.15</i>
<i>One month</i>	<i>2.35</i>
<i>Two months</i>	<i>1.75</i>
<i>Three months</i>	<i>0.85</i>
<i>Six months</i>	<i>0.5</i>

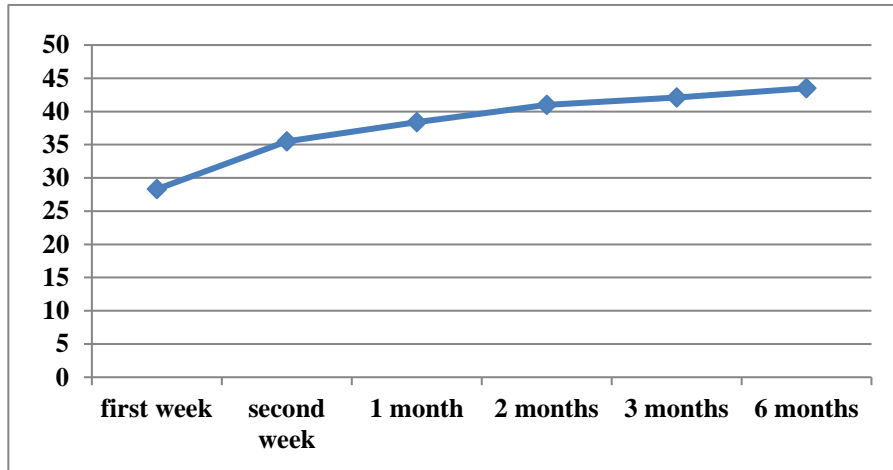


(Fig. 10) :Distribution of patients with condylar fracture by pain

3- Distribution of patients with condylar fracture by mouth opening limitation

Figure (11) shows the distribution of patients by mouth opening limitation, mouth opening increase gradually with time and exceed (40) mm beyond the first month in most patients.

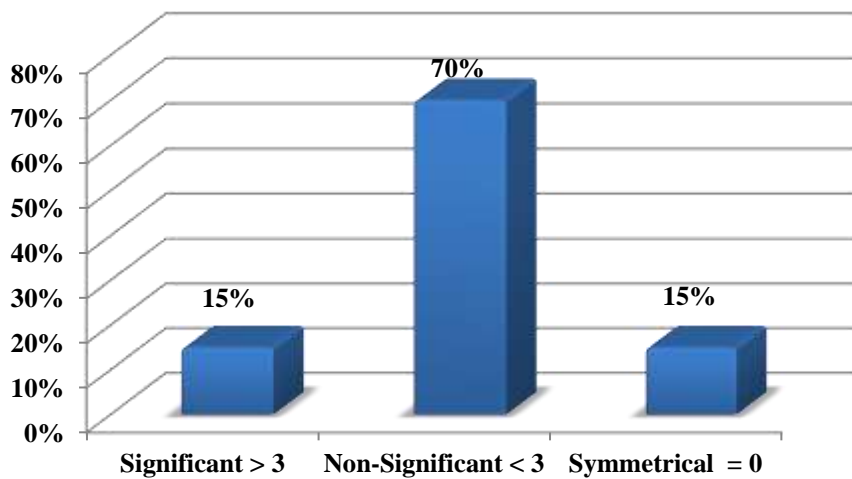
<i>Time</i>	<i>Average of mouth opening measured in (mm)</i>
<i>First week</i>	<i>28.3 mm</i>
<i>Second weeks</i>	<i>35.5 mm</i>
<i>One month</i>	<i>38.4 mm</i>
<i>Two months</i>	<i>41 mm</i>
<i>Three months</i>	<i>42.1 mm</i>
<i>Six months</i>	<i>43.5 mm</i>



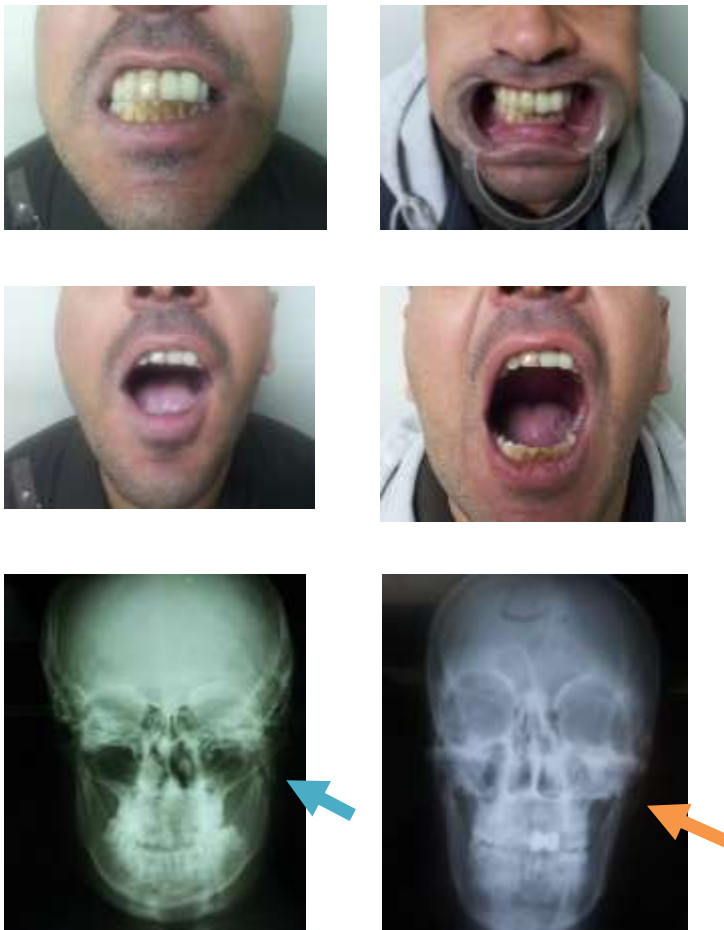(Fig. 11):Distribution of patients with condylar fracture by mouth opening limitation

4- Distribution of patients with condylar fracture by deviation

The majority (70%) of patients have no significant deviation,(15%) were significant and (15.0%) the right and left ramus heights are symmetrical (0%) . see Fig. (12) .



(Fig. 12): Distribution of patients with condylar fracture by deviation



27 years old male with condylar fracture without displacement (left side) treated with closed reduction ,the result was good occlusion , satisfactory mouth opening but slight deviation and (P.A) view show healing site of fracture.

Discussion

1-Age and sex distribution:

Young males predominance was clear shown in sex and age distribution ,the overall mean age of the patients was (28) years, majority of the patients (75%) aged younger than 30 years (fig.7),this may be due to hyperactivity of this group of age ,male to female ratio approximately 6/1 (fig.8), these findings are comparable with the results of (Richard A. Loukota) [20],(John D. Langdon 2012) [19] . However our male to female ratio is higher due to that in our country men go and spend a lot of time in the outside house.

2-Etiology distribution

The sample comprised 20 patients, the traffic accidents were the most common cause: 9 (45%),followed by alleged assault: 6 (30%) and fall from height (FFH) (fig.9). These results were agreement with epidemiological research of (P. Marker et al) [21][5].Blast injury is not present within this study although it's not excluded, because all cases of blast injuries were associated with multiple facial bones fractures and soft tissue laceration and treated in theatre as open reduction.

3-Pain:

Commonly, the pain associated with subcondylar fractures is not severe and is located in the TMJ and/or muscles of mastication, usually the masseter and temporalis muscles on the affected side, the pain is generally present only during function of the jaw, especially during opening movements but occasionally when occluding the teeth.

Visual analogue scale (VAS) shows the pain severity is moderate one week after removal of fixation (average is 4.35) and decrease gradually to be mild and then disappear in most patients during several weeks or few months later (0.5 average of pain after 6 months). fig.(10). This result was corresponding to prospective study by Haug and Assael (2001) which suggest that the pain is chronic for several months.[18].

The pain is not related (not significant) to the age fracture etiology or deviation during mouth opening, but it's significant ($p=0.031$) to the sex, It's more in female than male, this may be female afraid more than male.

4-Limitation of mouth opening

The normal inter-incisal opening ranged from (38-47mm), preoperatively, subcondylar fracture usually associated with varying degree of limited mandibular movement due to muscle spasm, edema, and haemarthrosis, or due to the pain from site of fracture, however, postoperatively, and after removal of fixation also there is varying degree of hypomobility due to pain and myofibrosis which is common after extended periods of inter-maxillary fixation (IMF), and this can be seen in the result of (20) patients with subcondylar fracture treated by conservative method, the average inter-incisal opening is (28.3 mm) first week of removal of fixation and increase gradually with time by functional movement and physiotherapy to exceed (40 mm) beyond first month, (Fig. 11), however, some patients have maximum mouth opening earlier. Mouth opening limitation is not significant to the sex, age, fracture etiology or deviation (p value > 0.05) (table 4.7), but there is significant reverse strong correlation between mouth opening and pain (Fig. 11) where the (p value=0.001).

The best way to manage the pain is to promote wide movement of the mandible.

5-Deviation during maximum mouth opening:

One of the complications of subcondylar fracture is a shortening in ramus height of fractured side which may lead to facial asymmetry, the severity of deviation depend on degree of fractured segment displacement and skillful of operator. [8] [14] . There is no clinical scientific method used to measure the degree of asymmetry and only the obvious disfigurement can be detected, however, the adjustment of occlusion during fixation, and select the patients with mild or slightly moderate degree of displacement will minimize the post-operative deviation.[18]

Post-operative panoramic radiograph (OPG) to assess the shortening in ramus height · Fig.(3), by using the formula $(R-L)/(R+L) \times 100$ introduced by (Habets et al 1987, 1988, 1999 and Ferrario V.F. 1997)[17][18], the asymmetry was calculated and expressed in percentage and +% values means that the right side is higher, -% values means that the left side is higher.

20 patients with subcondylar fracture treated by conservative method, the result was 70% of them (14) have no significant deviation (<3%), Fig.(12),15% of the patients (3) were significant (>3%),and 15% of them (3) were symmetrical (0%).

The non-significant values (<3%) is not classified as a true asymmetry, although the deviation may exist because, it's very mild and clinically not obvious . These results are agree with the results of the study has been done by Uwe Eckelt et al 2006. [18]

Treating mandibular subcondylar fractures need for providing the optimal environment for bony healing to occur, adequate blood supply, immobilization,and proper alignment of fracture segments. As a result, most fracture require reduction and fixation to allow for primary or secondary bone healing.[8][10]

6-Occlusion:

Malocclusion is assessed clinically by an examiner and described by the patient . (2) out of (20), (10%) patients (subjective) reported occlusal disturbance,but the clinical examination by operator (objective) reveal mild occlusal disturbance in (1) patient (5%),this agreement the study of (Horswell 1995) [9] that suggest approximately (15%) of adult patients treated with closed reduction have varying degree of occlusal disturbance,however,Eckelt et al 2006 [18] suggest that(23%) of patients treated with closed reduction suffering post-operative occlusal disturbance.

The adjustment of occlusion in patient with subcondylar fracture is so important because,it's consider as a key to minimize other possible complications later,for example,the application of force from the muscles,through incorrect occlusal contacts,results in load, and that load produces damage to (TMJ) and surrounding tissue,that means the malocclusion may increasing pain which has reverse correlation with mouth opening (i.e. enhance pain lead to enhance mouth opening limitation). [16]. One important factor of closed method is return the patient to pre-trauma occlusion which is called physiological occlusion (it may be normal occlusion or malocclusion). Physiological occlusion differ from pathological occlusion in which the components function efficiently and without pain, and remain in a good state of health , it can be either normal or malocclusion, in this state, the tempo-mandibular joint and associated structures should function freely and without pain. [15]

Finally, the successful of conservative method in treatment of subcondylar fractures highly dependent on degree of displacement, adjustment of occlusion, and post-operative rehabilitation.

CONFLICT OF INTERESTS.

There are non-conflicts of interest .

References

1. Virendra Singh, Amrish Bhagol, Rahul Dhingra. A comparative clinical evaluation of the outcome of patients treated for bilateral fracture of mandibular condyles. *Journal of Cranio-Maxillo-Facial Surgery* 2012, 40:464-466 .
2. Brooks SL et al: Imaging of the temporomandibular joint. Position paper of the American Academy of Oral and Maxillofacial Radiology, *Oral Surg Oral Med Oral Pathol Oral Radiol Endod* 83:609, 1997
3. Su-Seong Park, Keun-Cheol Lee, Seok-Kwun Kim. Overview of Mandibular Condyle Fracture. *Arch Plastic Surg* 2012,39:281-283 .
4. Kang-Young Choi, Jung Dug Yang, Ho-Yun Chung, Byung-Chae Cho. Current Concepts in the Mandibular Condyle Fracture Management Part II Open Reduction Versus Closed Reduction. *Arch Plastic Surg* 2012,39:301-308 .
5. Kang-Young Choi, Jung Dug Yang, Ho-Yun Chung, Byung-Chae Cho. Current Concepts in the Mandibular Condyle Fracture Management Part I, Open Reduction Versus Closed Reduction. *Arch Plastic Surg* 2012,39:291-300 .
6. Renato VALIATI, Danilo IBRAHIM, Marcelo Emir Requia ABRIEU, Claitom HEITZ, Rogerio Belle de OLIVEIRA , Rogerio Miranda PAGNONCELLI, Daniela Nascimento SILVA. The treatment of condylar fractures: to open or not to open? A critical review of this controversy. *Int J of medical sciences* 2008,5:313-318.
7. Bos, R.R., Ward Booth , R.P., de Bont LG.(1999). Mandibular condylar fractures: a consensus. *Br J Oral Maxillofac Surg. Apr*;37(2):87-89.
8. Peter Ward Booth, FDS , FRCS. *Maxillofacial Trauma and Esthetic Facial Reconstruction* 2012. Text book.
9. Walker RV. Condylar fractures: nonsurgical management. *J Oral Maxillofac Surg. Nov* 1994;52(11):1185-8.
10. John C. Koshy, M.D., Evan M. Feldman, M.D., Chuma J. Chike-Obi, M.D., and Jamal M. Bullocks, M.D. *Pearls of Mandibular Trauma Management* . *Semin Plast Surg* 2010;24:357-374.
11. Michael Miloro DMD, MD, FACS. G.E. Ghali DDS, MD, FACS. Peter E. Lasen, DDS. *Peterson's Principles of Oral and Maxillofacial Surgery*. Third edition 2012. Text book
12. Loucota, R.A., Eckelt U., DeBont L., Rasse M. Subclassification of fractures of the condylar process of the mandible. *Br. J Oral Maxillofac Surg.* 2005 ;43(1):72-73.
13. Matthias Hlawitschka, DDS, MD,* and Uwe Eckelt, DDS, MD Assessment of Patients Treated for Intracapsular Fractures of the Mandibular Condyle by Closed Techniques. 2002 American Association of Oral and Maxillofacial Surgeons . *J Oral Maxillofac Surg.* 60:784-791, 2002.
14. Helen E. Giannakopoulos, D.D.S., M.D., Peter D. Quinn, D.M.D., M.D., Eric Granquist, D.M.D., M.D., and Joli C. Chou, D.M.D., M.D. Post-Traumatic Temporomandibular Joint Disorder. *Craniofacial Trauma Reconstruction* 2(2):91-101, 2009.
15. Hassan Ra*, Rahimah AKb. Occlusion, malocclusion and method of measurements - an overview . *Archives of Orofacial Sciences* (2007) 2, 3-9.
16. S. Davies, and R. M. J. Gray, What is occlusion? *British Dental Journal*, Volume 191, No. 5, September 8 2001.

17. R. Borrato, U. Gambardella, P.Micheletti, L. Pagliani, L. Preda, T.L Hansson. Condylar Asymmetry, a Reality. Bull Group. Int. Rech. Sci. Stomatol. Odotol. 44,52-56,2002.
18. Uwe Eckelt, Matthias Schneider, Francois Erasmus, Klaus Louis Gerlach, Eberhard Kuhlisch, Richard Loukota, Michael Rasse, Johannes Schubert, Hendrik Terheyden ,Open versus closed treatment of fractures of the mandibular condylar process—a prospective randomized multi-centre study ,Journal of Cranio-Maxillofacial Surgery , 2006 European Association for Cranio-Maxillofacial Surgery.
19. John D. Langdon ,Mohanf.patel, Robert A. Ord, Peter A. Brennan : Operative oral and Maxillofacial Surgery ,management of condylar fractures ,including endoscopic reduction ,2nd ed.2011 hodder Arnold .
20. Richard A.loukota ,Khalid Abdel –Galil :Condylar fractures :In Peter ward Booth ,Barry I.Epply ,Rain Schmelzein :maxillofacial trauma&esthetic facial reconstruction 2nd ed Elsevier sunders :2012 :270-287.
21. P. Marker, A. Neilsen, H. Lehmann Bastian. Fractures of the Mandibular Condyle. Part I . Pattern of distribution of types and causes of fractures in 348 patients. British journal of oral and maxillofacial surgery. October 2000, page 417-421.
22. Burdi, A. R.: Morphogenesis. In Sarnat, B C, Laskin, D. M.: The tempromandibular joint: a biological basis for clinical practice. 4th ed. Saunders, Philadelphia 1992 (pp. 36-47).
23. Hayward JR , Scott RF :Fractures of mandibular condyle. J Oral Maxillofac Surg. 51:57-61, 1993.

تقييم المضاعفات الناتجة عن علاج الكسور تحت النتوء القمي لمفصل الفك الأسفل

بالطريقة التحفظية

الهدف: إن الهدف من هذه الدراسة هو تقييم مدى فعالية أسلوب المغلقة في علاج كسور اللقمة من خلال تقييم المضاعفات المحتملة. تم علاج 20 مريضاً مع كسر اللقمة من جانب واحد بالطريقة المغلقة بواسطة الاسلاك المعدنية من الفولاذ المقاوم للصدأ، ومن ثم تقييم المضاعفات المحتملة بعد اتمام مدة الربط ورفع الاسلاك ومتابعة الفحوصات السريرية بما في ذلك، الوظيفية منها مثل مدى القدرة على فتح الفم، وفحص الرقائق الشعاعية، وقياس شدة الألم بواسطة مقياس خاص يدعى analoque (VAS) لفترة (6) أشهر، تتضمن (6) زيارات (أسبوع واحد، أسبوعين، شهر واحد، شهرين، ثلاثة أشهر، وستة أشهر) بعد إزالة التثبيت.

النتائج: إن السبب الأكثر شيوعاً ل كسر اللقمة هو حوادث الطريق (RTA). بالنسبة لقياس الانحراف في الفك الأسفل بعد اتمام العلاج وحسب الأشعة السينية، فإن (70%) من المرضى يكون الانحراف ليس كبير (> 3%) [أي الانحراف ليس واضحاً سريريا على الرغم من انه موجود في الواقع حسب الأشعة السينية] ، في (15%) من المرضى تكون نسبة الانحراف (< 3%) [الانحراف موجود شعاعياً و سريريا ايضا لكنه قليل] ، وعدم وجود انحراف في الباقي (15%) من المرضى اي متناظر (0%) .

مقياس analoque (VAS) لقياس شدة الألم يبين ان هناك فروقات ذات دلالة احصائية متعلقة بالجنس، فالألم هو أعلى في الإناث ومع ذلك، فإنه ينخفض في كلا الجنسين مع الوقت . هناك ارتباط كبير وقوي بصوره عكسيه بين الألم ومدى فتحة الفم فكلما قل الألم زاد اتساع فتحة الفم وبالعكس. وأخيراً، فإن مدى اتساع فتحة الفم ليست متعلقة بالجنس، والعمر، والانحراف، أو سبب الكسر.

الاستنتاج: النتائج منطقيه، سريريا الاطباق بعد العملية مقنع ومقبول من قبل المريض والانحراف في الفك الأسفل لاوجود له سريريا على الرغم من أنها موجودة بالفعل شعاعياً.

الكلمات الدالة: بعد العملية الجراحية، الطريقة التحفظية، أسلاك الفولاذ المقاوم للصدأ، القياسات الشعاعية السريرية.