

A Comparative Study between Laser Hemorrhoidoplasty Procedure and Conventional Hemorrhoidectomy

Ahmed Fadhil Mohammed

Al-Hilla General Teaching Hospital and Al-Imam Alsadiq Hospital

Drahmed.aljamal@yahoo.com

Dheyaa Ali Hussien Al-Sultani

Al-Hilla General Teaching Hospital and Al-Imam Alsadiq Hospital

dhiyaali@gmail.com

Husham Majeed Flaifel Janabi

Al-Hilla General Teaching Hospital

Hisham Aljanabi@gmail.com

ARTICLE INFO

Submission date: 18/1/2018

Acceptance date: 18 /11/201

Publication date: 20/2/2019

Abstract

Hemorrhoids are very common anorectal diseases that affected any age groups and both genders.

There are different and several options for treatment of patients with hemorrhoids .ranging from conservative approach with dietary modifications ,rubber band ligation, sclerotherapy injection, diathermy coagulation, or minimal invasive procedures like; open surgical procedure and recently various types of laser was introduced such as carbon dioxide (CO₂) laser, and the neodymium :yttrium – aluminum – garnet (Nd: YAG) laser procedures.

In our study, we choose (1000 patients) all of them were free of medical diseases, those lie into two main groups , 500 patients (males and females) with different age groups were treated with conventional open surgical (Milligan – Morgan) hemorrhoidectomy operation ,and 500 patients (males and females) with different age groups were treated with minimally invasive diode laser hemorrhoidoplasty technique .

Laser hemorrhoidoplasty technique is used to treat the patients with 2nd and 3rd degree hemorrhoids, as an outpatients procedure without causing any additional harm or injuries to the surrounding normal (healthy) tissues, and significantly less post-operative complications with very short operative time and very rapid return to the normal daily activities.

Key words: Laser hemorrhoidoplasty, Piles, Laser therapy, Hemorrhoidal bleeding, Post hemorrhoidoplasty complication.

1. Introduction

Hemorrhoids are a very common anorectal condition defined as the symptomatic enlargement and distal displacement of the normal anal cushions. They affect millions of people around the world, and represent a major medical and socioeconomic problem.^{[1],[2]}

Hemorrhoidal diseases are the most common diseases of the rectum and anal canal, and the estimated worldwide prevalence ranges approximately from 3% to 28%, of which more than 4% are symptomatic. Approximately, 33% of these patients needs physicians for advice. ^{[3],[4]} Age distribution with a peak incidence between Forty five and sixty five years with subsequent decline after sixty five years. Males are more frequently affected than females. The anorectal vascular cushions along with the internal anal sphincter are essential in the maintenance of continence by providing soft tissue support and keeping the anal canal closed tightly. ^{[5],[6]}

There are multiple theories of development of hemorrhoids which are listed below:

The most common of them are:

- **Infection**
- **Diet and stool consistency**
- **Anal hypertonia**
- **Ageing**
- **Portal hypertension and varicose veins**
- **Vascular causes**
- **Shearing forces**

Clinical features

Bleeding, is the principal and earliest symptom. The nature of the bleeding is characteristically separate from the motion and is seen either on the paper for wiping or as a fresh splash in the pan. Very rarely, the bleeding may be sufficient to cause anemia. Pain is not commonly associated with the bleeding and its presence should make the clinician alert to the possibility of another diagnosis; however, pain may result from congestion of pile masses below a hypertonic sphincter. Piles associated with bleeding alone are called first-degree hemorrhoids. ^{[7],[8] [9],[10] [11],[12],}

Patients may complain of true 'piles', lumps that appear at the anal orifice during defecation and which return spontaneously afterwards (second-degree hemorrhoids), piles that have to be replaced manually (third-degree hemorrhoids), or piles that lie permanently outside (fourth-degree hemorrhoids). By this stage, there is often a significant cutaneous component to the pile masses, which arise through repeated congestion and edema. In addition to the main symptoms of pain and prolapse, patients may complain of anal irritation, which may occur as a result of mucus secretion from the caudally displaced rectal mucosa, minor leakage through a now imperfect anal seal or difficulties in cleaning after defecation because of the irregularity of the anal verge. ^{[13],[14][15] [16,17,18] .[19]}

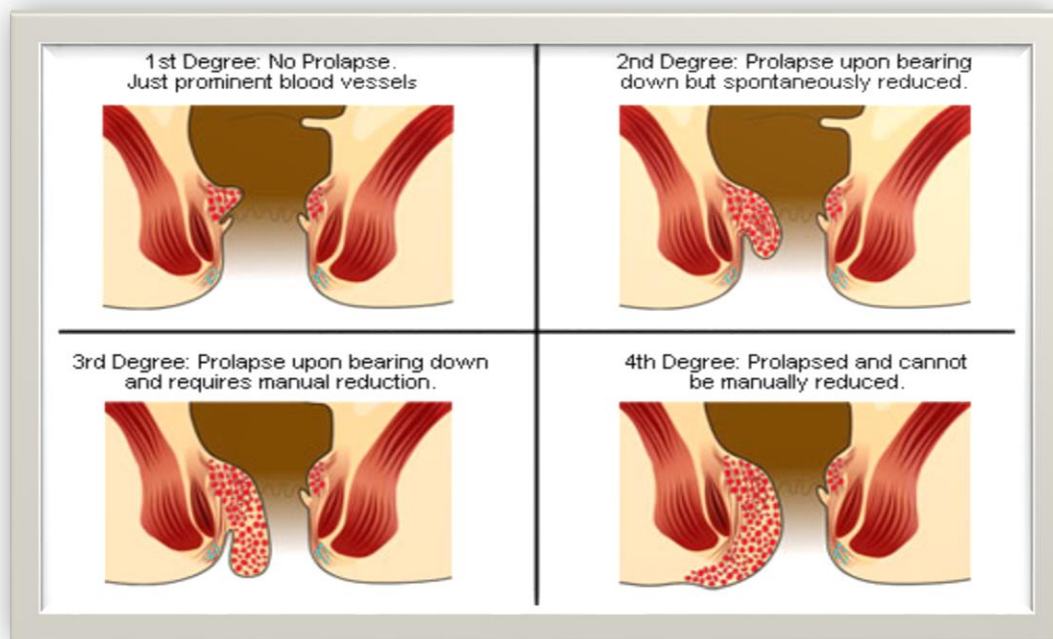


Figure 1. The Degrees of Hemorrhoids

2. Patients and Methods

Recently laser hemorrhoidoplasty has been available as a minimal invasive treatment for hemorrhoid problems.

In the our study, which is comparative and prospective study, 1000 patients were involved ,of which 500 patients (350 males and 150 females) were treated with laser hemorrhoidoplasty and 500 patients (368 males and 132 females) were treated with open surgical (conventional) traditional hemorrhoidectomy (Milligan –Morgan).

*This study was performed in Babylon (AL-Hilla) city in Iraq, from October 2014 to February 2018.

Laser Hemorrhoidoplasty :

* After detailed history and physical examination and use of anoscope, the laser procedure in our study was performed according to the following steps:

- 1- Lithotomy position of the patient to identify each hemorrhoid.
- 2- Local anesthesia 20 ml of 1% infiltration of Xylocaine without adrenaline.
- 3- c-shaped anoscope was inserted in the anal canal to explore each hemorrhoid, as showing in figure 2 .

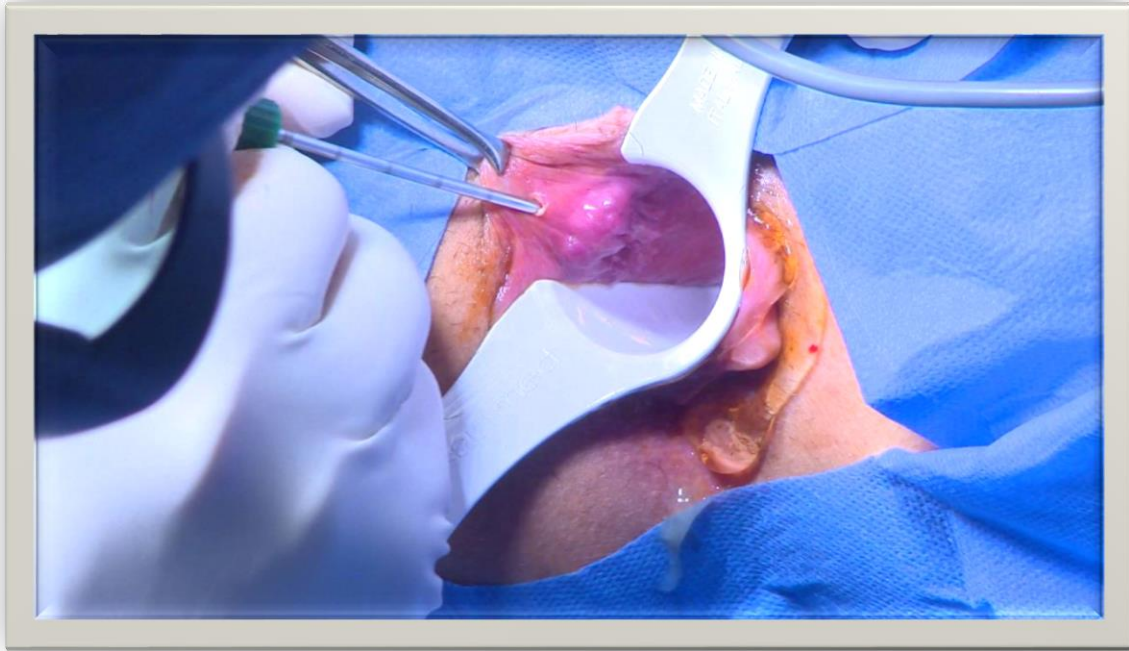


Figure 2- C- Shaped Anoscope.

4- As shown in figure 3. Below :

A- Firstly, we made a small incision to the skin in about (1 cm) distance from the anal edge.

B-Then laser probe is quickly delivered, followed by 5- 6 pulses (laser shots) according to the size of the hemorrhoid (pulsed manner used to minimize the damage to the adjacent normal tissues , and the depth can be regulated accordingly .

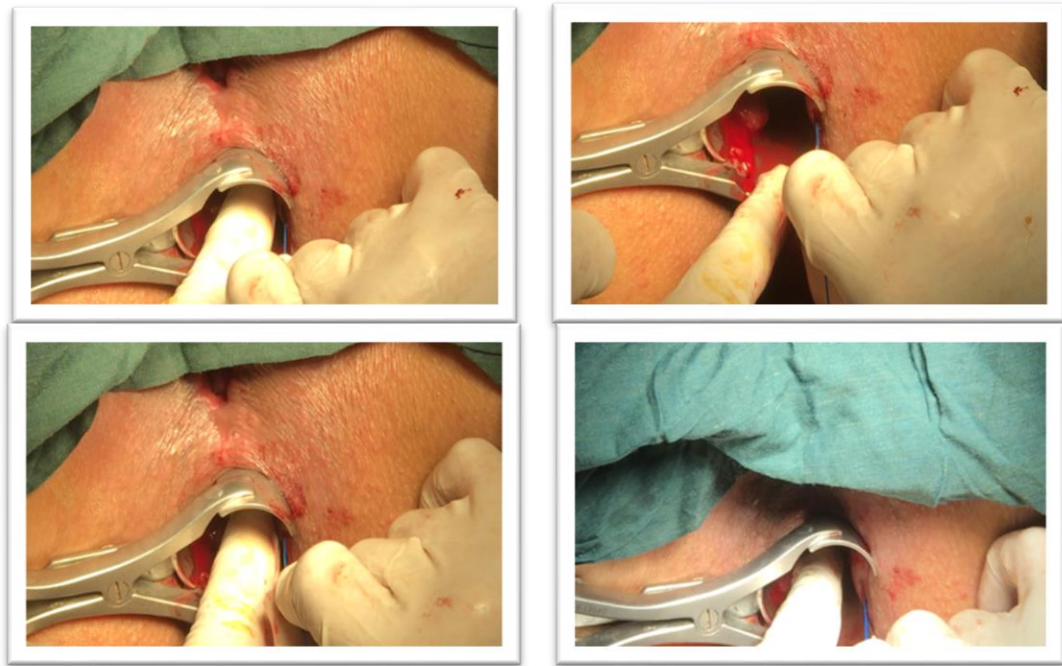


Figure 3. Incision The Skin And Insertion Of Laser Probe .

*....device setting which is diode laser 980nm and the cable 400Mm (0.4 mm)

**....device setting (300m.Sec) ON and(200m.Sec) OFF.

Power used is usually (5 watt)

5. Duration total dose according to the patient state and size of the hemorrhoids.
6. Hemostasis if needed, done by laser and pressure only (no sutures or hemostatic agents were applied).
7. Patient sometime receive injectable analgesia 30 min prior to the operation in the form of voltarin (diclofenac) or rolac (ketorolac) .
8. External dressing used at the end of the operation.
9. Patient allowed to have rest for one hour before discharge, so its performed as out-patients technique and don't need bowel preparations. 10. Then, patients were followed at the time of the operation, and after 3 days and 5 days and then at 7-14 days later.

Postoperative pain was involved according to the numeric pain score (10 points score from 0 to 10, in which 0 represents no pain and 10 represents very severe pain (the worst pain).

And also according to the post-operative bleeding, infection, fistulae in an anal stenosis ,and recurrence .

Conventional Hemorrhoidectomy:

Our study was done in AL-Hilla General Teaching Hospital .

*After detailed history and physical examination.

1. We do it according to the classical hemorrhoidectomy and done under general anesthesia.
2. Lithotomy position of the patient, as showing in figure 5 and 6 .
3. Four fingers dilatation of the anal canal to explore of the hemorrhoid.
4. A tissue forceps was applied to hold the external part of the hemorrhoid, and artery forceps to the pedicle.
5. A V-shaped incision was made by using a fine scissor to cut underneath the external skin component of the hemorrhoid, and the hemorrhoid is dissected off the underlying internal sphincter.
6. The mucosal and submucosal pedicle at the proximal end of the hemorrhoid is transfixed and ligated .
7. Hemorrhoid was finally removed .
8. Good hemostasis was done by using either sutures and / or diathermy.
9. Packing and external dressing was used at the end of the operation.
10. Then, patients were followed at the time of the operation, after 3 days , 5 days and then at 7- 14 days later.

Postoperative pain was involved according to the numeric pain score (10 points score from 0 to 10, in which 0 represents no pain and 10 represents very severe pain (the worst pain).

And also according to the post-operative bleeding, infection, fistulae in ano , anal stenosis ,and recurrence..

3. Results

In the our study, which is comparative and prospective study, one thousands (1000) patients were involved ,of which 500 patients (350 males and 150 females) were treated with laser hemorrhoidoplasty and 500 patients (368 males and 132 females) were treated with open surgical (conventional) traditional hemorrhoidectomy (Milligan – Morgan) hemorrhoidectomy.

This study was performed in Babylon (AL-Hilla) city, in Iraq from October 2014 to February 2018.

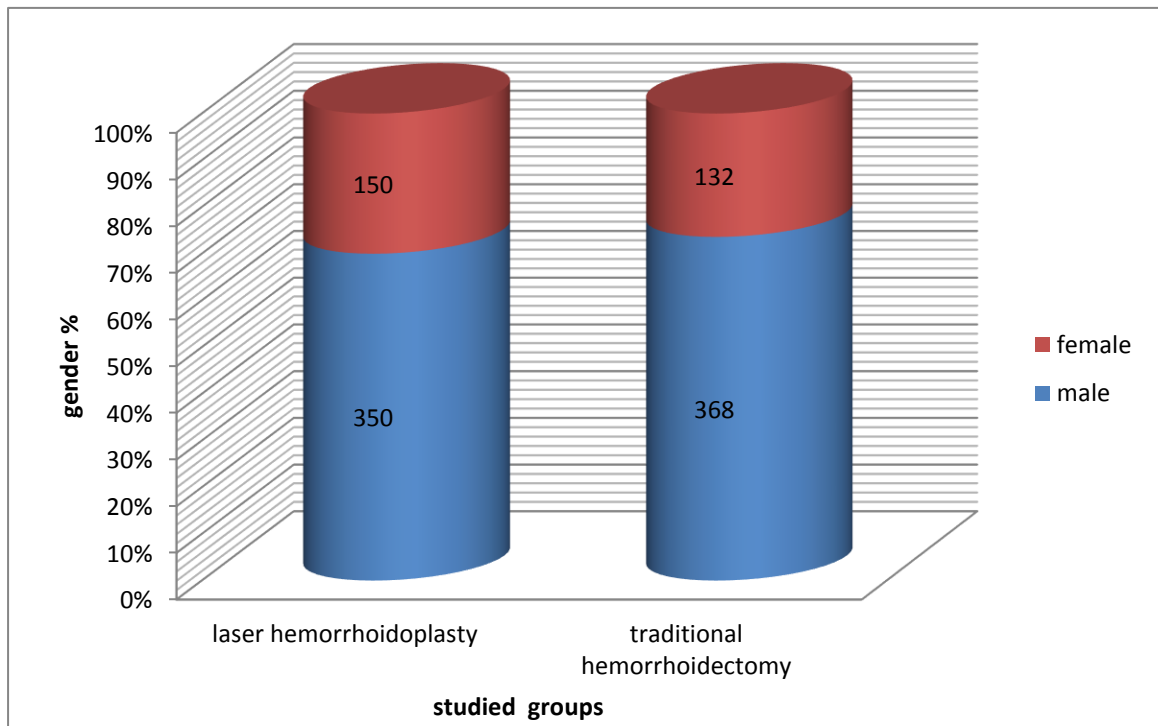


Figure (4): Gender in studied groups.

All patients were followed after procedures for 3 years to detect complications and recurrence.

In our study, all figures and tables and all statistical data were analysis by SPSS (17) which mean:

(Statistical Package for the Social Sciences, version 17).

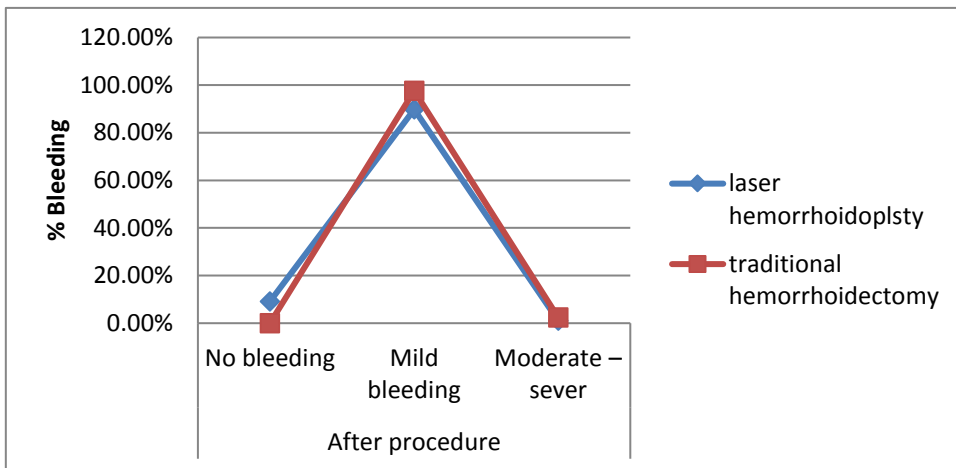
Our discrete data ware collected and analyzed by (Chi-Square) test also written as X^2 test and (Yates' chi-square) on needed because there is significant differences between the two samples in one or more categories.

Our results were collected according to the complications and recurrence, which are as the following:

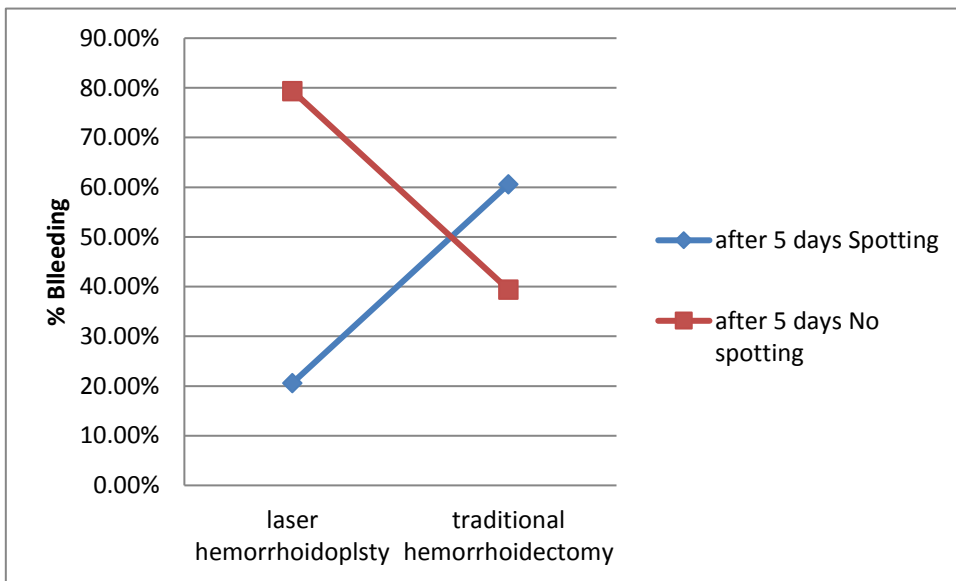
Bleeding

Post- laser hemorrhoidoplasty, 89.8% of patients developed mild bleeding in form of spotting after defecation. Only 20.6% keep spotting till 5th day. 1 % had moderate to severe bleeding, 2 cases(out of 500) of them ware in need for surgical intervention to stop bleeding. The rest stopped on conservative treatment, post- traditional hemorrhoidectomy, 97.6% of patients developed mild bleeding, only 2.4 % of cases had moderate to severe bleeding after the operation, while 60.6% of cases keep spotting till 5th post-operative days, according to our study.

Bleeding Post- laser hemorrhoidoplasty significantly lower than post-traditional hemorrhoidectomy ($P < 0.01$).



Figures (5. a): Bleeding Post- laser hemorrhoidoplasty and post-traditional hemorrhoidectomy



Figures (5. b): Bleeding after 5 days Post- laser hemorrhoidoplasty and post-traditional hemorrhoidectomy

Pain

Post-laser hemorrhoidoplasty, 98.6% of patients developed mild pain after the procedure, controlled by injectable analgesia which replaced by oral analgesia in second day. 85.2% had mild pain which kept on oral analgesia after 5th post-operative days. All patients stopped analgesia at day 8 post-traditional hemorrhoidectomy, 39.2 % of patients developed moderate – severe pain immediately after the operation, while at 5th post-operative days 54.6% developed mild pain and 55.4% complained from moderate to severe pain, according to our study.

Pain Post- laser hemorrhoidoplasty is significantly lower than post- traditional hemorrhoidectomy ($P < 0.01$).

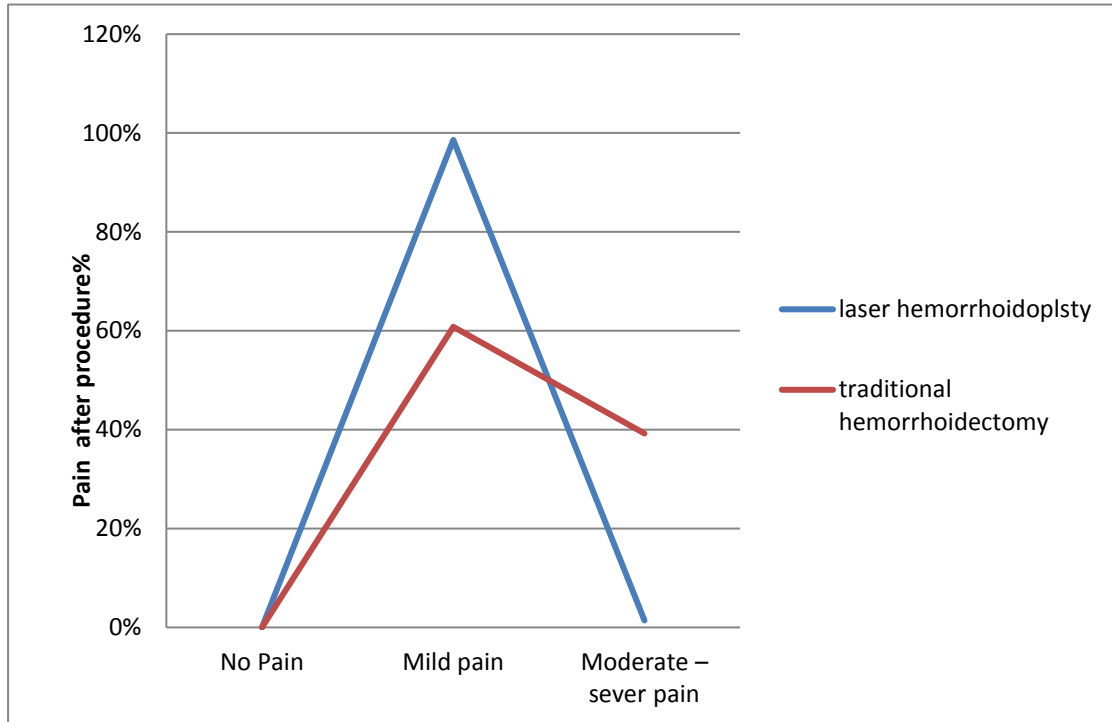


Figure (6. a): Pain Post laser hemorrhoidoplasty and traditional hemorrhoidectomy immediatly after the procedures.

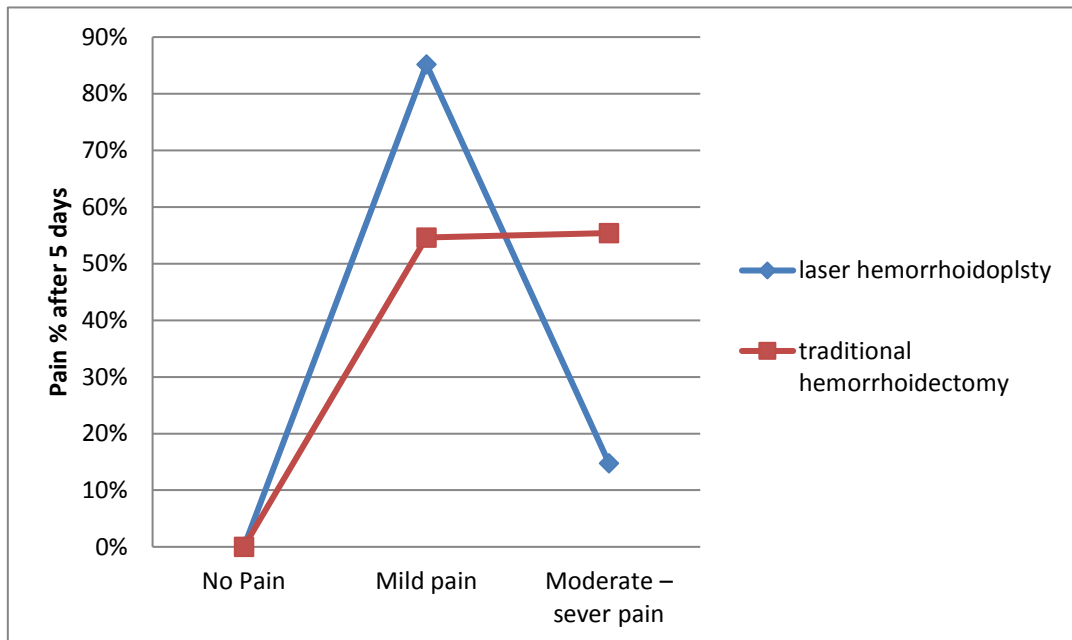


Figure (6. b): Pain Post- laser hemorrhoidoplasty and post-traditional hemorrhoidectomy after 5 days

Infection

Post- laser hemorrhoidoplasty, Mild infection take a part in 25.2% of cases in form of mild pus discharge and local inflammation. Moderate infection happened in 1.6% cases only in form of diffuse swelling, none was in need for surgical intervention .Only 1% of cases developed sever infection and abscess formation that was drained under local anesthesia, post- traditional hemorrhoidectomy, 37.4% of cases developed mild infection. While 14.6% of cases developed moderate infection in the form of diffuse swelling, while 3% developed sever infection and abscess formation was drained under local anesthesia, according to our study.

Infection Post- laser hemorrhoidoplasty significantly lower than post-traditional hemorrhoidectomy (P<0.01) .

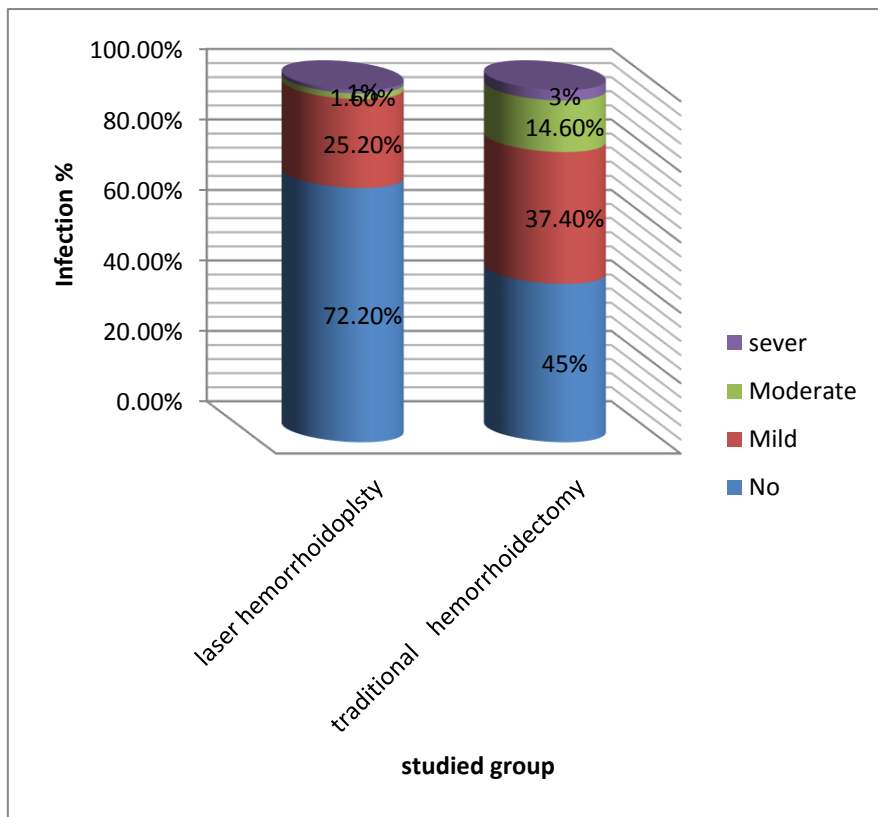


Figure (7): Infection Post- laser hemorrhoidoplasty and post-traditional hemorrhoidectomy.

Fistula in ano

Post- laser hemorrhoidoplasty, only 2 cases developed low type fistula in ano. 1st case managed conservatively. 2nd case was in need for fistulotomy under local anesthesia using laser, while in Post-traditional hemorrhoidectomy, 3% of patients developed Fistula in ano, according to our study.

Fistula in ano Post- laser hemorrhoidoplasty significantly lower than post-traditional hemorrhoidectomy (P<0.01) .

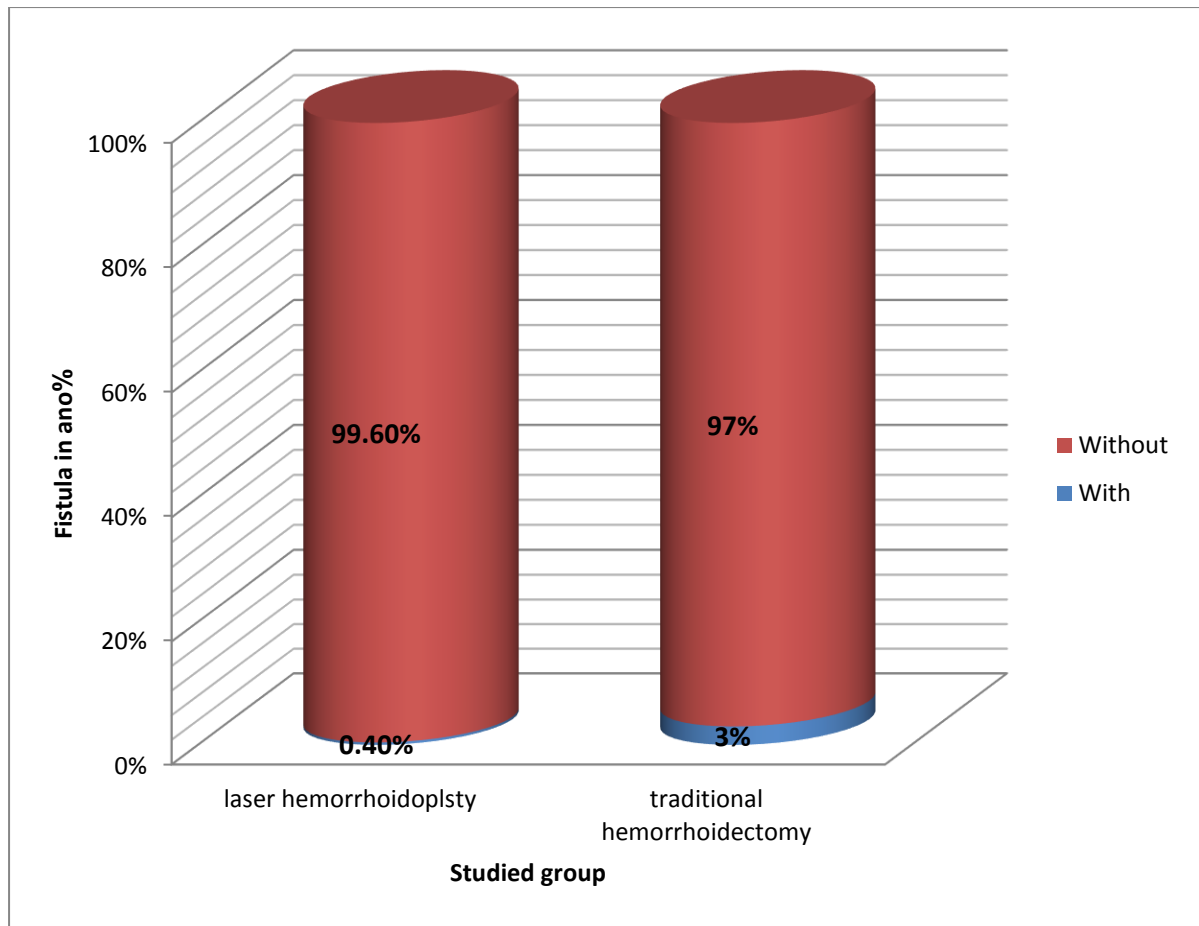


Figure (8): Fistula in ano Post- laser hemorrhoidoplasty and post-traditional hemorrhoidectomy

Anal Stenosis

Post- laser hemorrhoidoplasty, no patients developed anal stenosis while post-traditional hemorrhoidectomy, 6% of patients developed anal Stenosis, according to our study .

- **Anal Stenosis** Post- laser hemorrhoidoplasty significantly lower than post-traditional hemorrhoidectomy ($P < 0.01$) .

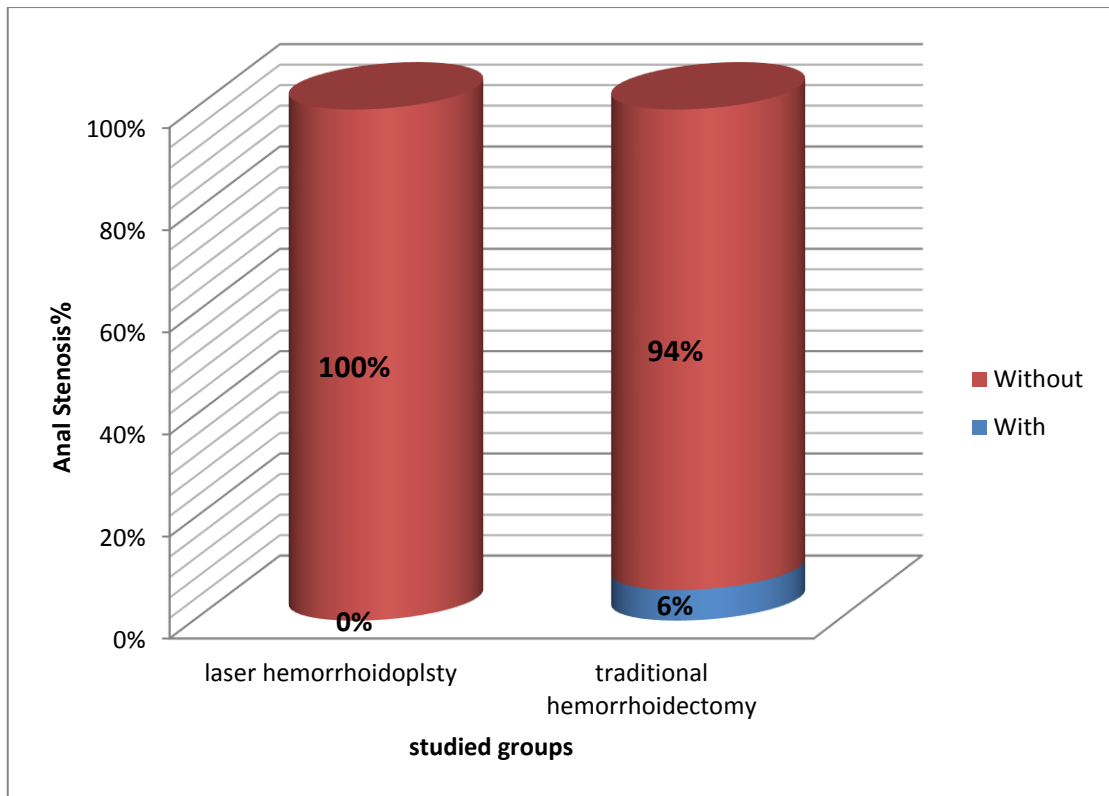


Figure (9): Anal Stenosis Post- laser hemorrhoidoplasty and post-traditional hemorrhoidectomy.

Fecal incontinence

No patients developed fecal incontinence after laser procedure, while 1.6% of cases developed fecal incontinence after traditional hemorrhoidectomy, according to our study.

Fecal incontinence post-laser hemorrhoidoplasty is significantly lower than post-traditional hemorrhoidectomy ($P < 0.01$).

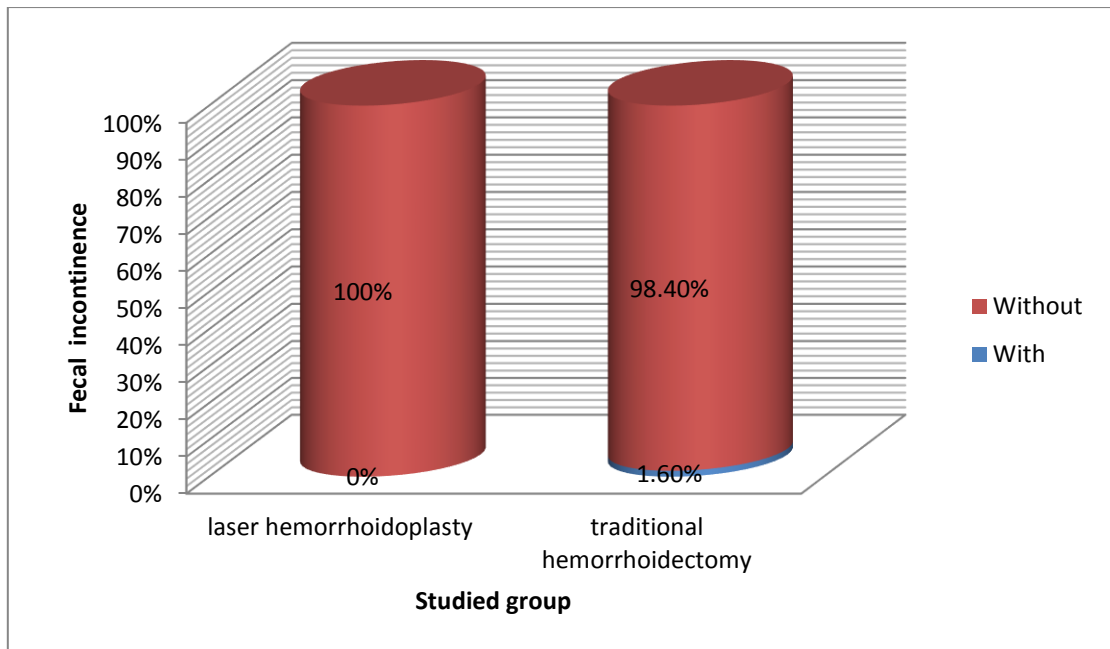


Figure (10): Fecal incontinence Post- laser hemorrhoidoplasty and post-traditional hemorrhoidectomy

Urinary retention

No patients developed urinary retention after laser procedure, while 1.4% of cases developed urinary retention after traditional hemorrhoidectomy, according to our study.

* Urinary retention post- laser hemorrhoidoplasty is significantly lower than post-traditional hemorrhoidectomy ($P < 0.01$).

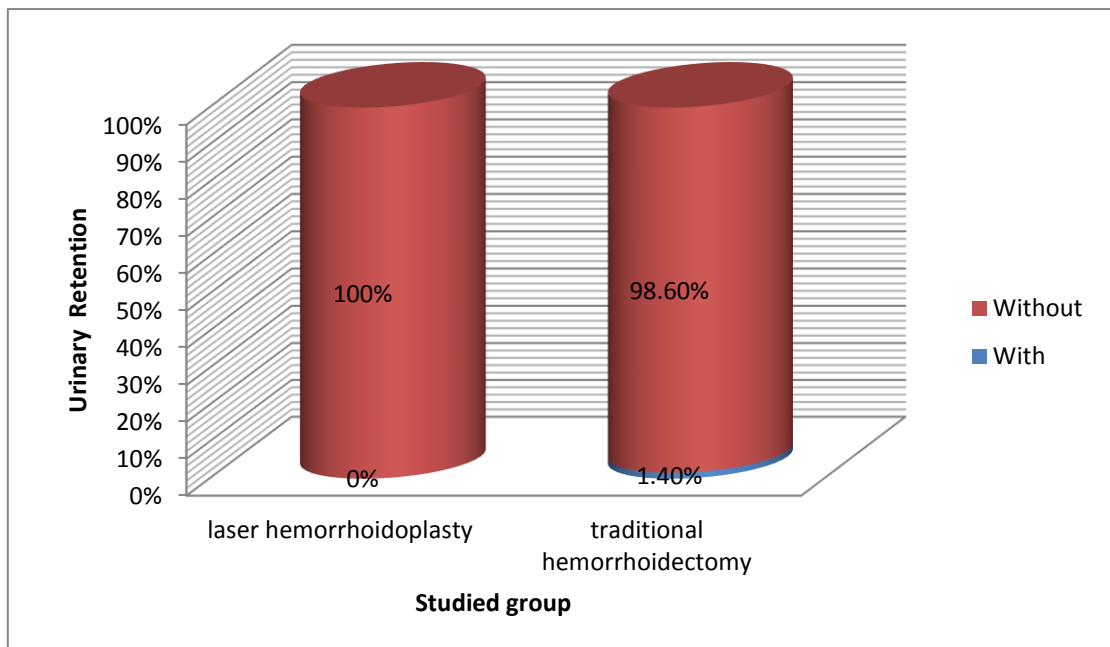


Figure (11): Urinary retention Post- laser hemorrhoidoplasty and post-traditional hemorrhoidectomy.

Recurrence

At 3 years of follow up:

- Post- laser hemorrhoidoplasty, none of the patients arrived with clinical evidence of recurrence.
- Post- traditional hemorrhoidectomy, 9% of patients had recurrence, according to our study.

*Recurrence Post- laser hemorrhoidoplasty significantly lower than post- traditional hemorrhoidectomy ($P < 0.01$).

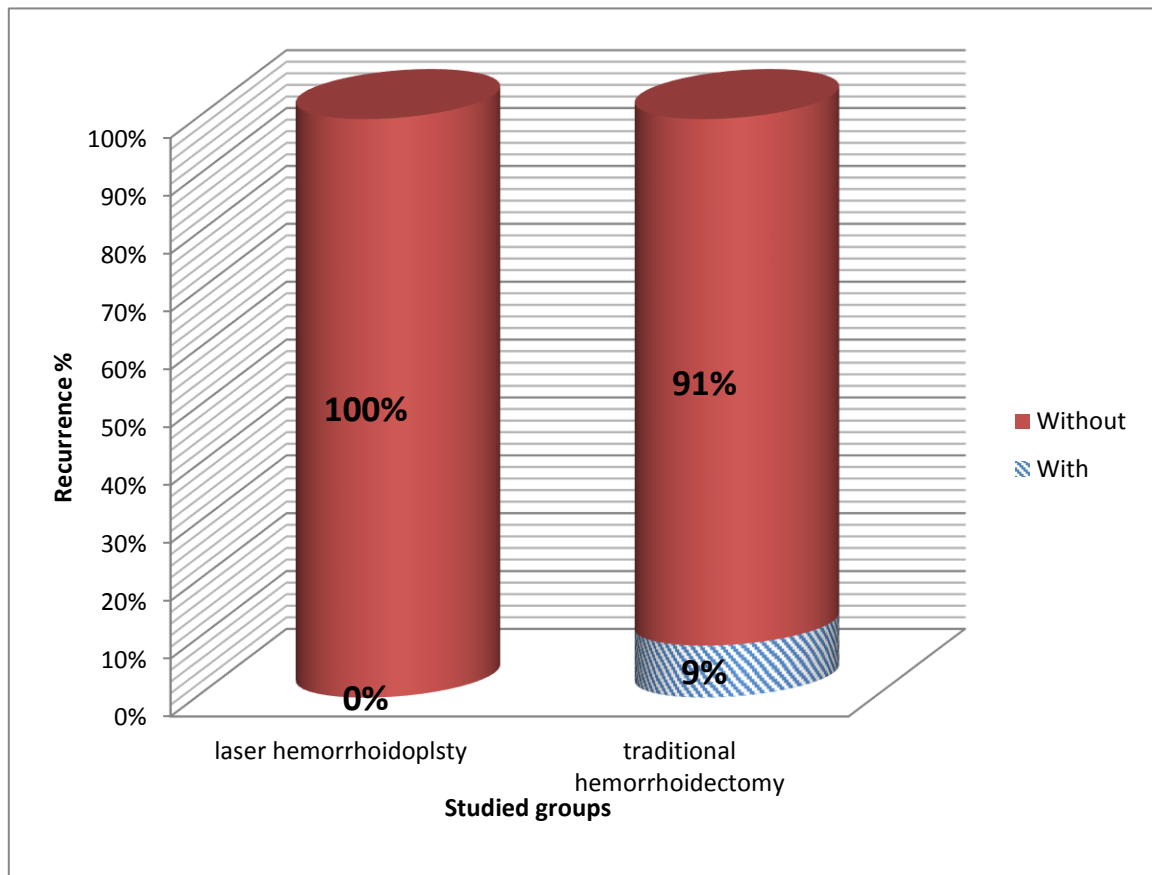


Figure (12): Recurrence Post- laser hemorrhoidoplasty and post-traditional hemorrhoidectomy

(Table – 1) The results in our study according to the complications between laser hemorrhoidoplasty and traditional hemorrhoidectomy

No	Complications	Laser Hemorrhoidoplasty	Traditional Hemorrhoidectomy	P- value
1	Bleeding after procedure	No bleeding (9.2 %)	(0%)	< 0.01**
		Mild bleeding (89.8%)	(97.6%)	
		Moderate – sever (1%)	(2.4%)	
2	After 5 days	Spotting (20.6 %)	(60.6%)	< 0.01**
		No spotting (79.4 %)	(39.4%)	
3	Pain after the procedure	No Pain (0%)	(0%)	< 0.01**
		Mild pain (98.6%)	(60.8%)	
		Moderate – sever pain (1.4%)	(39.2%)	
4	Pain after 5 days	No Pain (0%)	(0%)	< 0.01**
		Mild pain (85.2%)	(54.6%)	
		Moderate – sever pain (14.8%)	(55.4%)	
5	Infection after the procedure	No Infection (72.2%)	(45%)	< 0.01**
		Mild Infection (25.2%)	(37.4%)	
		Moderate Infection (1.6%)	(14.6%)	
		Sever Infection (1%)	(3%)	
6	Fistula in ano	With (0.4%)	(3%)	< 0.01**
		Without (99.6%)	(97%)	
7	Anal stenosis	With (0%)	(6%)	< 0.01**
		Without (100%)	(94%)	
8	Fecal incontinence	With (0%)	(1.6%)	< 0.01**
		Without (100%)	(98.4%)	
9	Urinary retention	With (0%)	(1.4%)	< 0.01**
		Without (100%)	(98.6%)	
10	Recurrence	With (0%)	(9%)	< 0.01**
		Without (100%)	(91%)	

** P value < 0.01 was highly significant

4- Discussion

The hemorrhoids are the most popular rectal and anal canal diseases among population, that occur with peak incidence ranged between 40years -60years, and usually male patients are affected more common than female patients.

The modalities of the managements depend on the general conditions of the patients and the severity of the symptoms especially pain and /or bleeding which ranged from the conservative managements and different modalities of the surgical interventions to the laser hemorrhoidoplasty .which is a new technique for outpatients treatment of the hemorrhoids in which, the feeding vessels of the pile stopped by mean of laser photothermal coagulation effect.

- In our study that done in Babylon (AL-Hilla) city, by collected samples consisted of (1000 patients) which divided into two equal groups, half of them managed with open surgical technique (Milligan – Morgan)hemorrhoidectomy in AL-Hilla general teaching

hospital which mainly done under general anesthesia, and another half managed with laser hemorrhoidoplasty technique, which is mainly done under local anesthesia.

- Our results were collected throughout 3 years ago including following the patients up according to the pain, bleeding, infections, fistulae, stenosis, and recurrences, immediately after the procedure and after 3 days and 5 days, till 7 – 14 days.

We found that laser hemorrhoidoplasty had several advantages in comparing with open surgical hemorrhoidectomy (Milligan – Morgan) procedure.

*** In this study:**

*Postoperative pain, immediately and 3-5 days until 2 weeks, is significantly less, according to the patients' perceptions (subjective) depending on the numeric pain grading, from (0 - 10) where (0 point) represent: no pain, while 10 point represent most severe (worst) pain.

* Postoperative bleeding is significantly less.

*Infection is also less significantly.

* Anal stenosis and fistulae are nearly nil.

We found that;

During 3 years of follow up none of the patients arrived with clinical evidence of recurrence.

In contrast, the conventional (open surgical) hemorrhoidectomy operation were associated with significantly rate of postoperative pain and bleeding.

Stenosis and fistulae also occur in some cases with increasing in the recurrence rate can be noticed.

So, we concluded (that laser hemorrhoidoplasty is safe technique, associated with less postoperative pain and bleeding, and can be done as outpatients procedure under local anesthesia, with significantly less duration of time if we compare it with open surgical operation).

All of these points can be considered convincing factors for patients with hemorrhoids.

5- Conclusion

Laser hemorrhoidoplasty technique is a new modality of minimally invasive technique for treatment of patients with hemorrhoids, which is characterized by using a Diode-laser device to stop the feeding vessels of the hemorrhoids in the manner of pulses (shots) by laser photothermal coagulation of the hemorrhoidal tissue proper then after until the hemorrhoids shrunk.

In brief, laser hemorrhoidoplasty in a comparative study with conventional hemorrhoidectomy is associated with less post-operative time, less post-operative complications, with significantly less recurrent rate, in which there is no need for

sutures(stiches) or scissors(cut) ,and never harm the adjacent normal tissues, so that ,the fast recovery of the patients and quick return to the normal activity within a shortest period of time ,no dietary restrictions ,and its ability to be done to all age groups. All of these are preferable factors compared to the conventional one.

Acknowledgement

This study was done under the supervision and care of the consultant general surgeon (DR. DHEYAA ALI HUSSIEN AL-SULTANI) (C.A.B.S.).

Consultant surgeon ,who is not only encouraged but also helped me how to be responsible post graduate doctor , I also appreciate all the efforts of my seniors , colleagues , all the medical staff of AL- Hilla General Teaching Hospital ,for their great assistance .

CONFLICT OF INTERESTS.

There are non-conflicts of interest.

6- References

1. Johanson JF, Sonnenberg A. The prevalence of hemorrhoids and chronic constipation: an epidemiological study. *Gastroenterology*. 1990; 98(2):380.
2. Rogozina VA. Hemorrhoids. *Eksperimental' Naia I Klinicheskaia Gastroenterologia*. 2002; 4:93–96.
3. Johanson JF, Sonnenberg A. The prevalence of hemorrhoids and chronic constipation: an epidemiological study. *Gastroenterology*. 1990; 98(2):380 – 386.
4. Parks AG. De Hemorrhoids. A study in surgical history. *Guy's Hospital Report*. 1985; 104:135–150.
5. Keighley MRB. Vol. 1. WB Saunders publishers; 1993. *Surgery of Anus, Rectum and Colon*. 1; pp. 295–298.
6. Haas PA, Fox TA, Jr, Haas GP. The Pathogenesis of hemorrhoids. *Diseases of the colon and rectum*. 1994;27(7):442–450.
7. Bailey & Love's Short Practice of Surgery. Norman S. Williams, Christopher J.K. Bulstrode. 26th Edition.
8. *Schwartz's Principles of Surgery*. F. Charles Brunicaudi, Tenth Edition.
9. Thomson WH: The nature of haemorrhoids. *Br J Surg* 62:542, 2009.
10. Holley CJ: History of hemorrhoidal surgery. *South Med J* 39:536,1986.
11. Morgado PJ, Suárez JA, Gómez LG, Morgado PJ. Histoclinical basis for a new classification of hemorrhoidal disease. *Dis Colon Rectum*. 1998;31:474–480.

12. Milligan ET, Morgan CN, Lond LE: Surgical anatomy of anal canal, and the operative treatment of hemorrhoids. Lancet 2:1119, 1937. [41].
13. Thomson WHF. The nature of Hemorrhoids. British Journal of Surgery. 1995; 62(7):542–552.
14. MacRae HM, McLeod RS. Comparison of Hemorrhoidal Treatment Modalities. A meta-analysis. Dis Colon Rectum. 1995; 38(7):687–694.
15. Bleday R, Pena JP, Rothenberger DA, Goldberg SM, Buls JG. Symptomatic Hemorrhoids: Current Incidence and Complications of Operative Therapy. Diseases of the colon and rectum. 1992; 35(5):477–481.
16. Sardinha TC, Corman ML. Hemorrhoids. The Surgical clinics of North America. 2002; 82(6):1153–1167.
17. Goligher J, Duthie H, Nixon H. London: Baillière Tindall; 1994. Surgery of the Anus Rectum and Colon. 5.
18. Salfi R. A new technique for ambulatory hemorrhoidal treatment Doppler-guided laser photocoagulation of hemorrhoidal arteries. Coloproctology. 2009; 31:99–103.
19. Chia YW, Darzi A, Speakman CT, Hill AD, Jameson JS, Henry MM. Department of Surgery, Central Middlesex Hospital, London, UK Int. J Colorectal Dis. 1995;1011:22–24.

الخلاصة

البواسير: هي من الأمراض الشرجية الشائعة جدا التي تصيب أي فئة عمرية ومن كلا الجنسين. هناك خيارات مختلفة وعديدة لعلاج المرضى الذين يعانون من البواسير. انطلاقا من العلاج التحفظي مع التعديلات الغذائية ، الربط باستخدام الشريط المطاطي ، حقن المعالجة بالتصلب ، التخثر الحراري ، أو عملية الجراحة المفتوحة ومؤخرا تم إدخال أنواع مختلفة من الليزر مثل ليزر ثاني أكسيد الكربون (CO2) ، والليوديميوم: الايتريوم والألومنيوم - العقيق (Nd: YAG).

في دراستنا ، اخترنا (1000 مريض) جميعهم كانوا خالين من الأمراض الطبية ، وتكمن في مجموعتين رئيسيتين ، تم علاج 500 مريض (ذكور وإناث) مع فئات عمرية مختلفة باستخدام الجراحة التقليدية المفتوحة (ميليجان - مورغان) وتم علاج 500 مريض (ذكور وإناث) مع فئات عمرية مختلفة ايضا باستخدام تقنية ازالة البواسير بالليزر

تستخدم تقنية ازالة البواسير بالليزر لعلاج المرضى الذين يعانون من البواسير من الدرجة الثانية والثالثة، كإجراء للمرضى في العيادات الخارجية دون التسبب في أي ضرر أو إصابات إضافية في الأنسجة الطبيعية (السليمة) المحيطة بها، ومضاعفات ما بعد العمليات الجراحية أقل بكثير مع وقت قصير جدا في الجراحة والعودة السريعة جدا إلى الأنشطة اليومية العادية.

الكلمات الدالة: ازالة البواسير باستخدام الليزر، بواسير، العلاج باستخدام الليزر، نزف البواسير، مضاعفات ما بعد عملية ازالة البواسير.