

Incidence of Orchiectomy in Patients with Testicular Torsion Treated in The Urology Department in Hilla Teaching Hospital

Wadhah A. Al-marzooq^a, Salam Abd Elameer Yahya^b, Ameer Kadim Alhumairi^c

^aDep. Of surgery/ College of medicine, University of Babylon

^bDep. Of surgery/ College of medicine, University of Babylon

^cDep. Of community medicine/ College of medicine, - University of Babylon

^adrwadhahuro@yahoo.com ^bSalamurosurgery3@gmail.com ^cameer.alhumairi@gmail.com

Keywords: Testicular torsion. Orchiectomy. Orchiopexy

1. Abstract

Acute torsion of the testicle(s) is one of the common emergencies in the field of urology; it results in either decrease or complete disruption of testicular blood flow, it affect about 4.5/100000 less than 25 years male. The golden period of testicular saving intervention is the first 6 – 8 hours from the onset of symptoms.

The aim of this study is to obtain a statistic about patients with testicular torsion treated at our center, concentrating on patients ended with orchiectomy.

A total number of 25 patients presented to our center during the study period (2 years).

After taking full history and scrotal examination, all patients sent to Doppler scrotal ultrasonography to confirm the diagnosis and assess vascularity, and then all patients underwent scrotal exploration through a scrotal incision. Orchiopexy or orchiectomy was done depending on viability of the testis. Contralateral orchiopexy was done in all patients. Forty percent of our patients ended with orchiectomy, the incidence of orchiectomy was higher in patients lived in rural areas (70 %), there also was strong relationship between cold weather and the incidence of orchiectomy.

The most important factor in detecting testis salvageability was the duration of symptoms before presentation.

2. Introduction

Acute torsion of the testicle(s) is one of the common emergencies in the field of urology; it results in either decrease or complete disruption of testicular blood flow, it affect about 4.5/100000 less than 25 years male. [1]

The golden period of testicular saving intervention is the first 6 – 8 hours from the onset of symptoms. [2]

It has been estimated that about 1/3 of cases ended with orchiectomy because of non-viability of the testis at the time of intervention. [3]

Regarding the etiology, it has been postulated that some anatomical abnormalities may increase the risk of testicular torsion, these include; long intra vaginal part of the spermatic cord (bell clapper deformity) and cryptorchidism. [4]

Although many cases of torsion occur spontaneously during sleep without any precipitating event, however, external trauma and exercise, especially riding bicycle are the main triggering that may precipitate the condition. [5]

For diagnosis of acute testicular torsion, detailed history and careful physical examination, concentrating on scrotal examination is essential and usually enough to decide the need for surgical intervention, although radiological imaging study using Color Doppler Sonography may be needed to confirm the diagnosis in equivocal cases [6]

Generally, the urologist must depend on detailed history and a careful physical examination to reach the diagnosis and surgical intervention should be done in any suspected cases. [7] [8]

Treatment of testicular torsion usually require surgical intervention, manual detorsion, sometime, is a possible option, in order to salvage the testis, surgical intervention should be done as quickly as possible and the first 6 hours after the symptom is considered the golden period. Delayed intervention will decrease the chance of testis preservation. [8]

Whether surgical treatment ended by testicular loss or preservation of the ipsilateral testis, most urologist does contralateral orchiopexy. [Kutikov A, et al. 2008].

Testicular compartment syndrome can occur after reperfusion of the affected testis, the longer the period of ischemia, the higher the risk of this syndrome. [9]

As orchiectomy is associated with psychological trauma to such young patients, some authors describe placement of testicular prosthesis at the same session of orchiectomy. [10]

Torsion can also occur in neonatal period, where the testis and tunica vaginalis twist as one unit (extra vaginal torsion). [11]

While there is some controversy regarding time of intervention of unilateral neonatal torsion, [12] [13], there is no doubt that bilateral neonatal torsion requires immediate surgical exploration aiming for preservation of endocrine function of the testis. [14]

3. Patients and methods

From January 2015 to January 2017, twenty-five male patients who are seeking medical advice for painful scrotal conditions in the emergency department in Hilla teaching hospital are included in this study. Age of those patients ranging from (9-32) years.

Thorough medical history taken from each patient, concentrating on the time of the beginning of pain, any event precipitating or preceding the pain, any associated symptoms such as urinary symptoms, fever nausea or vomiting.

Careful clinical examination done for each patient concentrating on scrotal examination to reach the exact diagnosis and differentiate it from mimicking conditions like epididymorchitis and complicated inguinal hernia.

Investigation is including Urinalysis, hematocrit and blood sugar done for each patient.

Also, Doppler scrotal ultrasonography done for each patient to confirm the diagnosis and

exclude other pathologies.

Urgent surgical exploration done for each patient through transverse scrotal skin incision with either detorsion of the affected testicle and orchiopexy of both testes or orchiectomy of the gangrenous testicle and orchiopexy of the other testicle.

Follow up for each patient for a period of 30 days by medical history, physical examination and Doppler scrotal ultrasonography to assess the condition of the testes.

4. Results

The total number of patients in our study was 25, Mean age of the patients was (17.76 ± 5.17) years, the mean duration of symptoms before presentation was (28.8 ± 20.17) hours (table number 1).

Table 1 Distribution of patients according to study variables

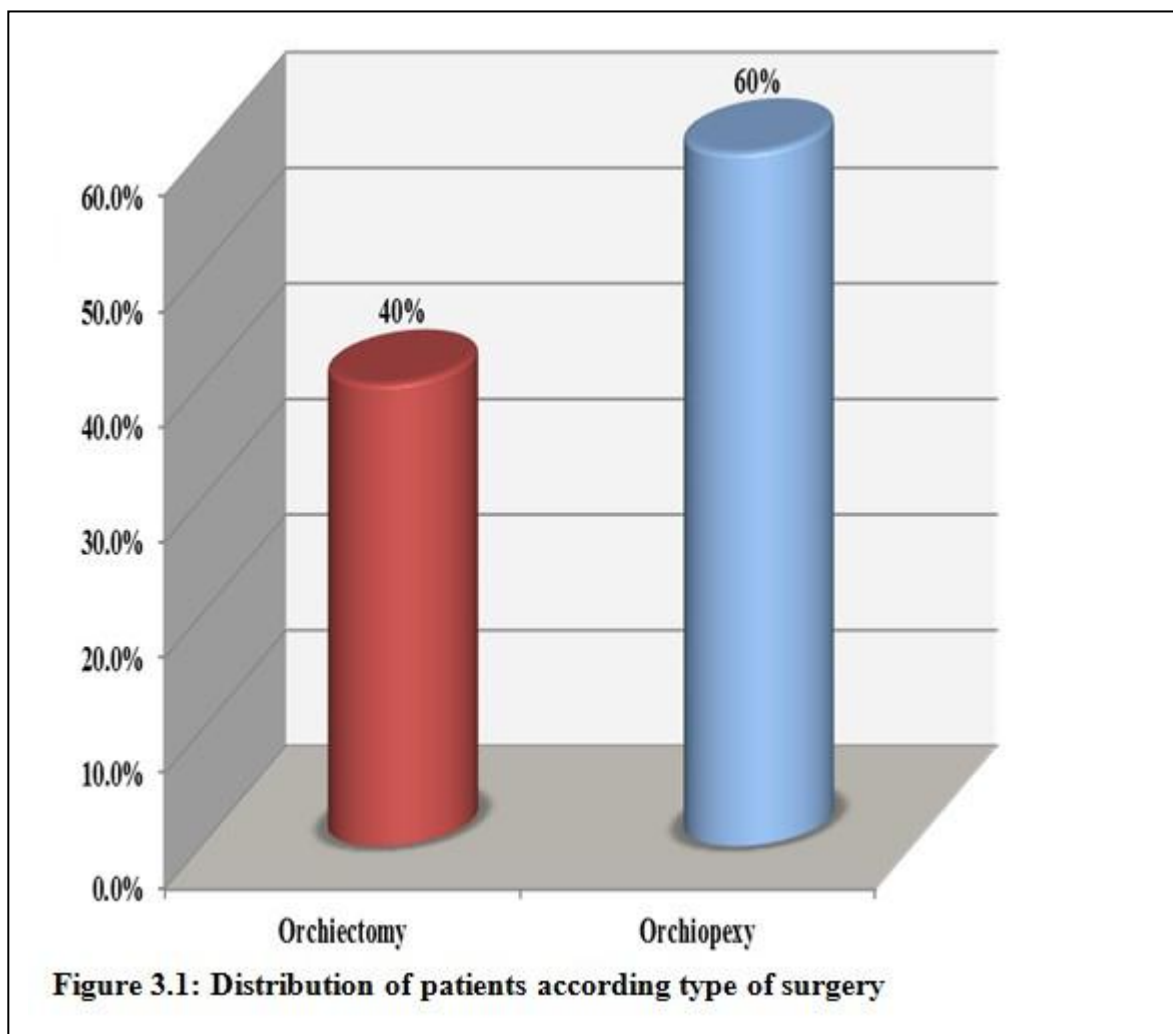
Study variables	mean + SD	
Age (years)	(9-32)	(17.76 ± 5.17)
Duration (hours)	(4-72)	(28.8 ± 20.17)

Eighty percent of patients presented with left side testicular torsion, while the right side affected in only 20 % of patients, 15 (60 %) of patients lived in urban area, were as 10 (40%) from rural areas. (Table number 2)

Table No. 2

Study variables	No. of patients	%
Residence		
Urban	15	60%
Rural	10	40%
Total	25	100%
Side affected		
Left	20	80%
Right	5	20%
Total	25	100%

Figure 1 shows the distribution of patients according to type of surgery. (60%) of study patients treated by orchiopexy (testicular fixation), and 40 % (10 patients) treated by orchiectomy.



Although statistically insignificant, the age of patients ended with orchiectomy was slightly higher than those ended with orchiopexy.

The mean duration of symptom in orchiectomy patients was (38.6±21.62) hours, which is significantly longer than orchiopexy patients are. Table number 3

Table 3: The mean differences of age and duration of torsion according to type of operation

Study Variable	Study group	N	Mean ± SD	t-test	P value
Age (years)	Orchiopexy	15	17.13 ± 5.44	- 0.735	0.47
	Orchiectomy	10	18.7 ± 4.85		
Duration (hours)	Orchiopexy	15	22.26 ± 16.81	- 2.123	0.045
	Orchiectomy	10	38.6 ± 21.62		

*P value ≤ 0.05 was significant.

Table 4 shows the association between type of operation and study variables including (residence and side of torsion). Most of patients treated by orchietomy were living in rural areas. There was a significant association between type of operation and residence.

Table 4 Association between type of operation and study variables

Study variables	Type of operation		P-value
	Orchiopexy	Orchiectomy	
Residence			0.034
Rural	3 (20.0)	7 (70.0)	
Urban	12 (80.0)	3 (30.0)	
Total	15 (100.0)	10 (100.0)	
Side of torsion			1.000
Left	12 (80.0)	8 (80.0)	
Right	3 (20.0)	2 (20.0)	
Total	15 (100.0)	10 (100.0)	

*p value ≤ 0.05 was significant. Fisher-exact test.

Table number 5 shows a significant association between time of presentation and the type of surgery, most of the cases ended by orchietomy presented at wintertime.

The testicular Doppler study was positive in 20 patients (80 %), there was no significant association between type of surgery and the results of doppler study.

Table 5 Association between type of operation and study variables

Study variables		Type of operation		P-value
		Orchiopexy	Orchiectomy	
Time of presentation				0.04
Oct. – Feb.	14	6	8	
March. – Sep.	11	9	2	
Total	25	15	10	
Doppler study				1.000
Positive	20	12	8	
Negative	5	3	2	
Total	25	15	10	

*p value ≤ 0.05 was significant. Fisher-exact test. □

5. Discussion

In order to salvage the testis in patients with testicular torsion, both the patient and the health care giver must be alert to the symptoms and the gravity of the subject, so the health care giver must interfere as soon as possible. [15]

Unfortunately, some time the patient may voluntarily or involuntarily fail to attain a medical interference in a suitable time. [16]

The present study found that the rate of testicular loss was 40 %, the most important factor that determined testicular salvageability was duration of symptom prior to surgery. This means that 40 % of our patients get delayed surgery.

In the present study the risk of testicular loss was significantly associated with patient residence (higher in patients lived in rural areas).

The higher incidence of orchiectomy in patients who live in rural areas can be related to many factors, first is delay transfer to hospital, second some social and traditional factors that makes patients denied such pathology, and the lower educational level about the risk of such disease.

In the present study, the mean age of orchiectomy patients was slightly higher; however, the difference was statistically insignificant.

In a large retrospective study done by Barada et al found that, the risk of orchiectomy increases as the patient's age increases. [17]

Many previous studies found that there is an association between the season and the risk of torsion with an increase in risk during cold climate. [18]

In the present study we reported that most of cases were during the months (October to February), the period of winter in IRAQ.

Cold weather can increase the risk of testicular loss by many mechanisms, it causes more stimulation to cremasteric muscle, and in addition to that, patients transfer from rural areas to hospital is more difficult during winter.

Our result is consistent with many previous studies, which found that testicular loss was related to many factors such as age, race, and hospital transfer. [17] [1]

Conclusions

Our study showed that high (40) % of testicular torsion patients lose their testis (ended with orchiectomy)

Most of patients ended with orchiectomy were from rural area, and most of them presented during winter.

Scrotal Doppler ultrasonography is essential to confirm the diagnosis; however, in suspected cases surgical exploration is better than delayed exploration waiting the result of Scrotal Doppler ultrasonography

Duration of symptom is the most important factor in detecting testicular salvageability in patients with torsion.

Data Analysis

Statistical analysis was carried out using SPSS version 20. Categorical variables were presented as frequencies and percentages. Continuous variables were presented as (Means \pm SD). Student t-test was used to compare means between two groups. Fisher's-exact test was used to find the association between categorical variables. A *p*-value of ≤ 0.05 was considered as significant.

References

- [1] J. M. Mansbach, P. Forbes, and C. Peters, "Testicular torsion and risk factors for orchiectomy," *Arch Pediatr Adolesc Med*, vol. 159, no. 12, pp. 1167–1171, 2005.
- [2] F. X. Schneck and M. F. Bellinger, "Abnormalities of the testes and scrotum and their surgical management," W. P. R. A. and V. E. Eds. Philadelphia: Pa WB Saunders Co, 2002, p. 2379.
- [3] J. Cubillos and et al, "Familial testicular torsion," *J Urol*, vol. 185, no. 6 Suppl, pp. 2469–2472, 2011.
- [4] R. E. Caesar, "Incidence of the bell-clapper deformity in an autopsy series," *Urology*, vol. 44, no. 1, pp. 114–116, 1994.
- [5] P. M. Cuckow and J. D. Frank, "Torsion of the testis," *BJU Int*, vol. 86, no. 3, pp. 349–353, 2000.
- [6] L. A. Baker and et al, "An analysis of clinical outcomes using color doppler testicular ultrasound for testicular torsion. pediatrics," *Pediatrics*, vol. 105, no. 3 Pt 1, pp. 604–607, 2000.
- [7] B. Burgu and et al, "Feasibility of transscrotal near-infrared spectroscopy (nirs) in the evaluation of acute scrotum: a pilot human study; moderated poster at aua annual meeting," 2011.
- [8] A. Kutikov and et al, "Testicular compartment syndrome: a new approach to conceptualizing and managing testicular torsion. urology," *Urology*, vol. 72, no. 4, pp. 786–789, 2008.
- [9] Y. Moritoki and et al, "Intratesticular pressure after testicular torsion as a predictor of subsequent spermatogenesis: a rat model," *BJU Int*, 2011.
- [10] A. Bagrodia, D. Preuss, and N. Bush, "American urological association national convention," in *Combined Orchiectomy and Prosthetic Exchange: Surgical Technique*, Washington, D.C, 2011.
- [11] L. A. Guerra and et al, "Management of neonatal testicular torsion: Which way to turn?" *Can Urol Assoc J*, vol. 4, no. 4, pp. 367–379, 2008.
- [12] E. B. Yerkes and et al, "Management of perinatal torsion: today, tomorrow or," *J Urol*, vol. 174, no. 4 Pt 2, pp. 1579–1582, 2005.
- [13] M. Baglaj and R. Carachi, "Neonatal bilateral testicular torsion: a plea for emergency exploration," *J Urol*, vol. 177, no. 6, pp. 2296–2299, 2007.
- [14] P. R. Callewaert and P. V. Kerrebroeck, "New insights into perinatal testicular torsion," 2009.
- [15] M. S. Rampaul and H. SW, "Testicular torsion: most delay occurs outside hospital," *Ann R Coll Surg Engl*, pp. 80169–172, 1998.
- [16] P. Nasrallah, G. Nair, and J. Congeni, "Clmcmahon d testicular health awareness in pubertal males," *J Urol*, vol. 164, pp. 1115–1117, 2000.
- [17] J. H. Barada, J. L. Weingarten, and W. J. Cromie, "Testicular salvage and age-related delay in the presentation of testicular torsion," *J Urol*, pp. 142746–748, 1989.
- [18] A. K. Srinivasan, J. Freyle, J. S. Gitlin, and et al, "Climatic conditions and the risk of testicular torsion in adolescent," *J Urol*, vol. 178, no. 2585, 2007.

دراسة نسبة استئصال الخصية في المرضى الذين يعانون من التواء الخصية والتي تم علاجها في قسم المسالك البولية في مستشفى الحلة التعليمي

الخلاصة

التواء الخصية الحاد، حيث تدور الخصية فجأة في كيس الصفن مما يؤدي الى التواء الأوعية الدموية المجهزة للخصية مؤدية الى تقليل ثم منع تدفق الدم الى الخصية هو السبب الأكثر شيوعا من اسباب ظهور الألم المفاجئ في جانب واحد من كيس الصفن. تقدر البحوث أن حوالي ٤,٥ لكل ١٠٠٠٠٠٠ من الذكور و الذين تقل اعمارهم عن ٢٥ سنة يعانون من التواء الخصية في كل السنة.

والهدف من هذه الدراسة هو الحصول على إحصاءات حول المرضى الذين يعانون من التواء الخصية و الذين تم علاجهم في مركزنا، مع التركيز على المرضى الذين انتهى بهم العلاج مع استئصال الخصية.

اشتملت الدراسة على ٢٥ مريض ممن راجعوا شعبة جراحة المسالك البولية في المستشفى.

بعد أخذ التاريخ المرضي الكامل و اجراء فحص كيس الصفن، أرسل جميع المرضى إلى فحص كيس الصفن بالموجات فوق الصوتية الملونة للتأكد من التشخيص ولتقييم الأوعية الدموية، وبعد ذلك خضع جميع المرضى لاستكشاف كيس الصفن من خلال شق الصفن. تم اجراء عملية تثبيت او استئصال الخصية اعتمادا على حيوية الخصية. تم إجراء عملية تثبيت الخصية المقابلة في جميع المرضى.

تم اجراء استئصال الخصية في ٤٠% من المرضى، كان معدل استئصال الخصية أعلى في المرضى الذين يعيشون في المناطق الريفية (٧٠%) وكان هناك أيضا علاقة قوية بين الطقس البارد و معدل حدوث استئصال الخصية.

وكان العامل الأكثر أهمية في الكشف عن امكانية انقاذ الخصية هو المدة الزمنية بين ظهور الأعراض و اجراء العملية

الكلمات المفتاحية: التواء الخصية، استئصال الخصية، تثبيت الخصية.