

Journal of University of Babylon, Pure and Applied Sciences, Vol.(26), No.(5): 2018

Evaluation of Protective Activity of Curcumin in Reducing Methotrexate Induced Liver Cells Injury: An Experimental Study on Iraqi White Domestic Rabbits

Hussain Abady Aljebori¹, Ali H Abady^{2*}, Isra'a Mahdi Al-Sudani³

¹College of Medicine, Department of Pathology, University of Al-mustansiriyah, Iraq

²Al-Yarmouk College of Pharmacy, E-mail: abbadyhussain@gmail.com

, E-mail:

dr.israamahdi@yahoo.com

Abstract

Background: Hepatotoxicity is a common problem in medical practice, most of the commonly used drugs are potentially hepatotoxic. Although Methotrexate is a hepatotoxic drug, it is widely used in the treatment of many cancerous and non-cancerous conditions because of its cytotoxic and immunosuppressant activity. Curcumin contains a variety of natural substances with antioxidant properties, it is widely used in folk medicine. Antioxidant activity of Curcumin can reduce liver cell injury induced by Methotrexate administration.

Objective: The research aims to study the methotrexate hepatotoxicity on rabbits, and the hepatoprotective activity of Curcumin.

Materials and Methods: Thirty white domestic rabbits were bought from animal market and grouped randomly into three groups; control group received intraperitoneal normal saline, methotrexate group received 6.5 mg/Kgm body weight intraperitoneal methotrexate, and curcumin group received oral Curcumin in addition to intraperitoneal methotrexate.

Results: The study showed abnormal liver function tests, INR, liver tissues oxidative markers, and liver cell injury on histopathology in Methotrexate group, and normal findings in Curcumin groups.

Conclusion: It is concluded that the Methotrexate is a hepatotoxic drug. The results also show that the concomitant administration of Curcumin reduced hepatotoxicity.

Recommendation: It is recommended to use of Curcumin in clinical practice as a food supplement to patient receiving methotrexate to reduce hepatotoxicity.

Keywords: *Methotrexate, Hepatotoxicity, Curcumin.*

تقييم النشاط الوقائي لمادة الكركم في الحد من إصابة خلايا الكبد نتيجة تناول دواء الميثوتريكسيت: دراسة تجريبية على الأرانب العراقية

البيضاء

حسين عبادي الجبوري، علي حسين عبادي، اسراء مهدي السوداني

الخلاصة

المقدمة: إصابات خلايا الكبد والخلل في وظائفها تشكل مشاكل الشائعة في الممارسات الطبية. معظم العقاقير شائعة الاستخدام من الممكن ان تؤدي الى التهاب الكبد او خلل في وظائفه، مثلا المضادات الحيوية، مسكنات الالم مثل الباراسيتامول وغيره، الأدوية المضادة للسرطان، تناول الكحول، والمواد الكيميائية السامة الأخرى المستخدمة في الصناعة. على الرغم من أن الميثوتريكسيت هو عامل فعال مضاد للسرطان، فهو كذلك يستخدم على نطاق واسع في علاج العديد من الحالات غير السرطانية كالأزمات الجلدية والروماتيزم لمانعة مضاد للمناعة. الكركم يحتوي على مجموعة متنوعة من المواد الطبيعية مع خصائص مضادة للأكسدة قوية وفعالة في مكافحة الإجهاد التأكسدي الناجم عن تناول الميثوتريكسيت.

الهدف من الدراسة: أولا لمعرفة تأثير دواء الميثوتريكسيت على أنسجة الكبد، وثانيا دراسة النشاط الوقائي لمادة الكركم في الحد من تأثير هذا الدواء على أنسجة الكبد.

المواد والطرق: تمت الدراسة على الارانب البيضاء العراقية وقد تم فصل الحيوانات عشوائيا إلى ثلاث مجموعات. مجموعة السيطرة، مجموعة ميثوتريكسيت، ومجموعة الكركم.

النتائج: أثبتت نتائج مستويات البيليروبين وإنزيمات الكبد في مصل الدم والفحوصات النسيجية على أنسجة الكبد عن التهاب الكبد الحاد نتيجة تأثير علاج الميثوتريكسيت، وتشير النتائج عن توليد الأوكسجين التفاعلي (روس)، ونقص في آليات الدفاع المضاد للأكسدة.

الاستنتاج: أثبتت الدراسة ان لمادة الكركم تأثير مضاد للأكسدة وباستطاعته التقليل من التأثيرات الجانبية لدواء الميثوتريكسيت على أنسجة الكبد.

التوصية: توصي الدراسة باستخدام مادة الكركم في الممارسة السريرية وخاصة للمرض الذين يستخدمون العلاجات الكيميائية كونه مكملا غذائيا وكونه مادة طبيعية ومضاد قوي للأكسدة.

الكلمات مفتاحية: الميثوتريكسيت، الكركم، سمية الخلايا الكبديه.

1-Introduction

Methotrexate (MTX) is a widely used immunosuppressant and anticancer Drug [1]. It is used in clinical practice against variety of neoplastic and non-neoplastic diseases especially autoimmune diseases like systemic lupus erythematosus, psoriasis, inflammatory bowel diseases, and rheumatoid arthritis [2] [3] [4] [5] [6].

Methotrexate is a folic acid antagonist because of its folic acid reeducates inhibitory capability, its chemical structure is (4-amino-N10-methyl folic acid), and its anti-cancer activity is due to inhibition of DNA synthesis resulting in blocking of cell proliferation [7]. Cytotoxic activity of MTX is extended to affect cells of vital organs especially the bone marrow, gastrointestinal mucosal cells, liver, kidneys, and hair follicle cells in addition to tumor cells [8]. Methotrexate affects in particularly, most actively growing cells [9] [10]. It can't distinguish between actively growing cancer and normal body cells, so treatment with MTX results in alopecia and pancytopenia because of elimination of fast growing normal body cells such as hair and blood forming cells in hair root and bone marrow [11] [12]. Hepatotoxicity induced by MTX is thought to be the result of oxidative stress formed by generation of reactive oxygen species (ROS) in parenchymal liver cells and depletion of parenchymal liver cells from its natural antioxidant defense mechanisms [11] [13]. Superoxide dismutase (SOD) in mitochondria converts superoxide ($O_2^{\cdot-}$) to H_2O_2 , and Glutathione peroxidase (GPx) in mitochondria converts hydroxyl ion (OH^{\cdot}) into H_2O_2 [13]. Therefore, measurement of SOD and GSH in liver tissue homogenate by ELISA is an indirect estimate of the level of ROS and oxidative stress in liver cell parenchyma [13]. Curcumin is derived from the perennial herb "Curcuma longa" [14]. Curcumin is a yellow-colored spice well known for its anti-cancer and anti-oxidant properties, and it is widely used in folk and traditional medicine for centuries in the treatment of variety of diseases such as liver disorders, hepatitis, cancer, inflammatory disorders, rheumatoid arthritis, skin diseases, and Alzheimer's disease [15] [16]. Curcumin can reduce ROS formed during oxidative stress by lessen regulation of nitric oxide synthetase (NOS) activity in macrophages [16], which synthesizes nitric oxide (NO) during 'oxidative burst' necessary in defense against pathogens. The present study was designed to study of methotrexate-induced hepatotoxicity on Iraqi white domestic rabbits, and the hepato-protective activity of Curcumin.

2-MATERIALS AND METHODS

3-Animals

Thirty healthy male white domestic Iraqi rabbits of age 5 to 6 months, and weighing between 1.5 and 2 Kg were obtained from Baghdad animal market. Rabbits were randomly divided into three experimental groups of 10 rabbits each and rabbits were labeled. The experimental groups were; the control group, Methotrexate group, and Curcumin group. Every three animals were housed in one cage, and standard conditions of temperature, humidity, and 12 hrs. light/dark cycles were maintained in all the cages, and during the whole experiment. The experimental protocol was approved by Ethical Committee at Almustansiriyah College of Medicine. Animals were fed with normal diet and left for 72 hrs. to be acclimatized to the facility before starting the study. The study was conducted between December 2016 and February 2017 at the Department of Pathology, Al-mustansiriyah College of Medicine. The experiment duration was seven days.

4-Experimental Design

5-Control group

Members of this group received during the whole period of experiment 3ml, of normal saline intraperitoneally every day and fed normal diet. This group serves as a negative control for other two groups.

6-Methotrexate group

Members of this group during the whole period of experiment received 6.5mg/Kgm body weight methotrexate (from medac Pharma company) intraperitoneally as a single daily dose to induce hepatotoxicity and fed with normal diet.

7-Curcumin group

Members of this group during the whole period of experiment received 6.0 gm/Kgm body weight curcumin daily orally dissolved in distilled water in three divided doses using animal feeding tube, in addition to the daily dose of 6.5 mg/Kgm body weight of methotrexate intraperitoneally, and they also received a normal diet.

8-Methodology

9- Labelling and weighing of rabbits

Before starting the experiment, the animals were labelled and the weight of each was taken and recorded to adjust doses of drugs accordingly.

10-Administration of drugs

Drugs were given from day-1 to day-7 of experiment per weight and experimental design.

11-Anesthetizing the rabbits

Rabbits were anesthetized by placing a piece of cotton over the nostrils and mouth soaked with ether from BDH company and keep it in place until the animal was completely anesthetized and left it in place until the end of animal dissection.



Figure 1: A Rabbit During Anesthesia.

12-Aspiration of blood

After fully anesthetizing the animals, blood was withdrawn directly from the heart by inserting needle through the skin inferior and to left side of the xiphisternum and continue pushing until it reached the heart. As much as possible blood was withdrawn. About 1.8 milliliter of fresh blood were added to 0.2 milliliter of sodium citrate for International Normalized Ratio (INR) study, and all remaining blood were left to clot in labelled plain tubes. Obtained sera were deeply freeze for later biochemical studies of serum bilirubin, and serum liver enzymes (AST, ALT, ALP, and LDH), using special kits from Biosystem company and spectrophotometer.

13-Dissection of rabbits

While animal still fully anesthetized, dissection started by pinning the legs to both sides and making midline incision using scalpel from xiphisternum to the pelvis. Opening abdominal wall was completed by scissor dissection. Then liver was removed and divided into two parts, one part left in 10% isotonic buffered formal-saline for histopathologic examination, and second part of liver was taken fresh for homogenization in tissue homogenizer and kept in deep freeze for further studies.

14-Grading of liver cell injury

Severity of liver injury was graded per serological examination into five grades depending on Council for International Organizations of Medical Sciences (CIOMS) toxicity scale [17]: **Mild, 1+**: Total serum bilirubin <2.5 mg/dl, and elevated serum levels of AST, ALT, or alkaline phosphatase, but without coagulopathy (INR <1.5). **Moderate, 2+**: Total serum bilirubin >2.5 mg/dl, and elevated levels of serum AST, ALT, or alkaline phosphatase or both or coagulopathy (INR >1.5) without hyperbilirubinemia. **Moderate to Severe, 3+**: Total serum bilirubin >2.5 mg/dl, and hospitalization and elevated serum levels of AST, ALT, or alkaline phosphatase. **Severe, 4+**: Total serum bilirubin >2.5 mg/dl, and elevated serum levels of AST, ALT, or alkaline phosphatase, and at least one of the following: Prolonged jaundice, and symptoms beyond 3 months, or signs of hepatic decompensation (INR >1.5, ascites, encephalopathy), or other organ failure induced by the drug. **Fatal, 5+**: causing death or need liver transplantation.

15-Markers of oxidative stress in liver cells

Include estimation of Malodialdehyde (MDA), reduced glutathione (GSH), and superoxide dismutase (SOD) in liver tissues homogenate by ELIZA technique using special kits from Biocusa company and fully automated Biotech ELIZA system.

16-Histopathological findings and Scores of liver cells injury

Liver cell injury was ranked per extent of histopathological alterations found by examination of ten high power fields into four scores according [20]: **Score (0)**: No or very mild +/- histopathological changes seen in < 5% of fields. **Score mild (+)**: when histopathological changes seen in >5% but < 20% of fields. **Score moderate (++)**: histopathological changes seen in 20 to 60% of fields. **Score severe (+++)**: histopathological changes seen in >60% of fields.

17-Statistical analysis

The IBM SPSS version 24 statistical software and Microsoft Excel 2010 were used for statistical analysis. Numerical data results were formulated as mean and standard error. Comparison between two groups were carried out by *t-test* on data that were normally distributed. Non-parametric Mann-Whitney U test was carried out on data that were not normally distributed. The data were considered statistically significant when the (*p*-value) is below 0.05.

18-Results

19-Results of blood studies

The levels of serum bilirubin, liver enzymes (AST, ALT, ALP, and LDH), INR were elevated in methotrexate group as compared to these in the control group. While, these parameters were normal or very close to the normal ones in Curcumin group. Grading of liver cell injury depending on grading system using serological findings introduced by Council for International Organizations of Medical Sciences (CIOMS) toxicity scale can be summarized as follows: Methotrexate group one rabbit was mild grade +, three were moderate grade ++, and six were rabbits moderate to severe grade +++. Grading of liver cell injury in Curcumin group was one rabbit mild grade +, and nine was normal grade 0. All results were statistically significant, and the *p-values* were < 0.05, table-1 and figures 2&3.

Table 1: Serum Total Bilirubin, and INR in Study Groups.

Groups	Serum mg/dl bilirubin	Serum AST(IU/L)	Serum ALT(IU/L)	Serum ALP(IU/L)	Serum LDH(IU/L)	INR	P-Values
Control	0.64±2.8	31.3±6.1	34.15±4.4	30.3±2.62	86.5±5.8	1.0±0.01	<0.001
Methotrexate	14.85±4.9	350.4±36.7	312.4±15.6	206.3±17.2	430.4±15.1	2.1±0.62	<0.001
Curcumin	0.82±2.1	36.2±4.2	38.52±3.4	28.15±1.95	90.32±4.6	1.0±0.04	<0.003

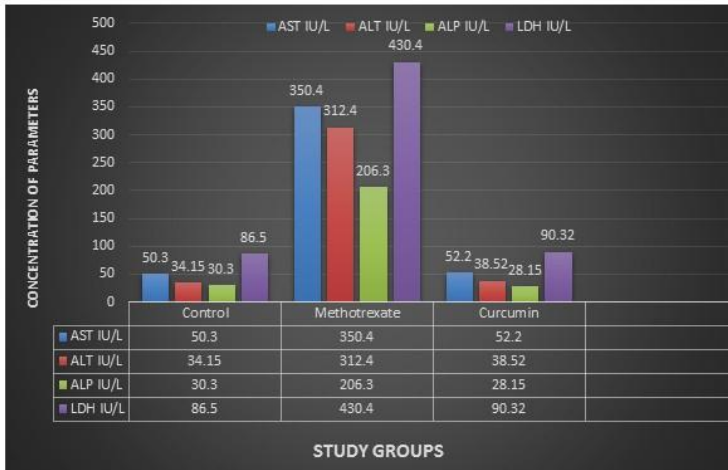


Figure 2: Mean of Total Serum Bilirubin and Liver Enzymes in Study Groups.

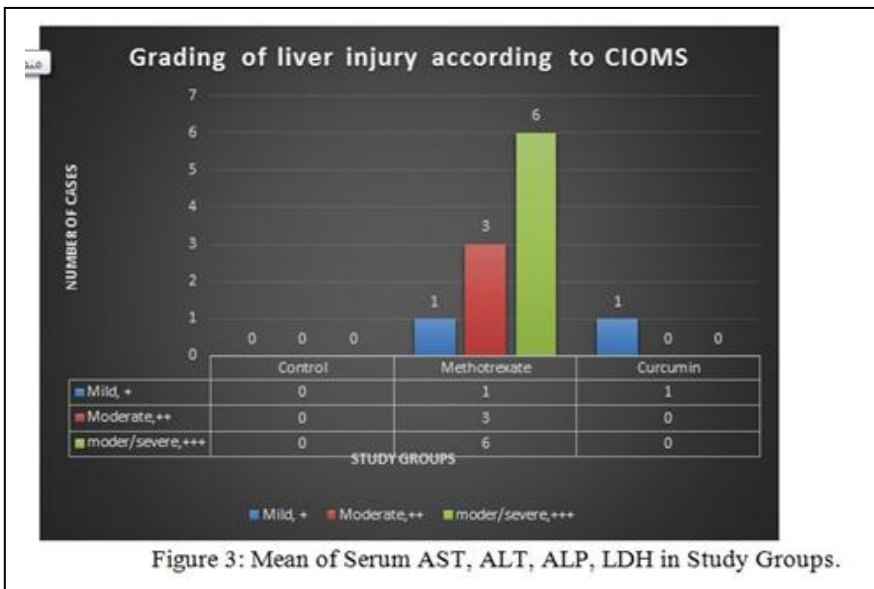


Figure 3: Mean of Serum AST, ALT, ALP, LDH in Study Groups.

20-Results of oxidative markers in liver tissue homogenate

Using ELIZA system from Biotech and kits from Biocusa company, the mean of MDA level liver tissue homogenate in methotrexate group was markedly elevated compare to control. There was also reduction in the levels of GSH and SOD which are intracellular antioxidant systems. While, in Curcumin group, the results of these markers were normal or very close to normal. All the results were statistically significant with p -values<0.05, table 2, and figure 4.

Table 2: Markers of Oxidative Stress in Liver Tissue Homogenate of Study Groups.

Groups	MDA ($\mu\text{mol/gm}$ liver tissues)	GSH (nmol/gm liver tissues)	SOD (Units/gm liver tissues)	<i>P-Values</i>
Control	27.5 \pm 1.9	12.3 \pm 2	15.9 \pm 1.8	<0.001
Methotrexate	62.7 \pm 2.4	4.8 \pm 1	5.8 \pm 0.7	<0.01
Curcumin	31.2 \pm 1.5	10.4 \pm 0.9	13.6 \pm 1.1	<0.04

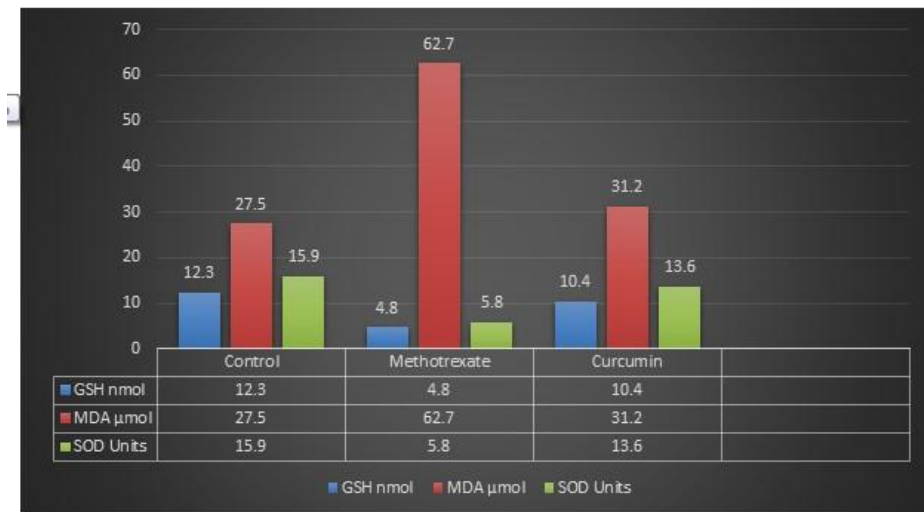


Figure 4: Mean of Oxidative Markers in Liver Tissue Homogenate of Study Groups.

21-Histopathologic Results and Scores of Liver Cells Injury

Histopathological examination of the liver sections from methotrexate group showed acute hepatic injury of diffuse type. Scores of liver cells injury in methotrexate group according David E Kleiner [20] were: Score+ in one rabbit, Score++ in three rabbits, and

Score+++ in six rabbits. While sections from liver of rabbit in Curcumin group showed one rabbit with score+/0 (very mild), and Score 0 in other nine rabbits, figures 4-7. These findings agree with scores obtained by serological tests by CIOMS method shown in figure-5. All results were statistically significant with p -values<0.05.

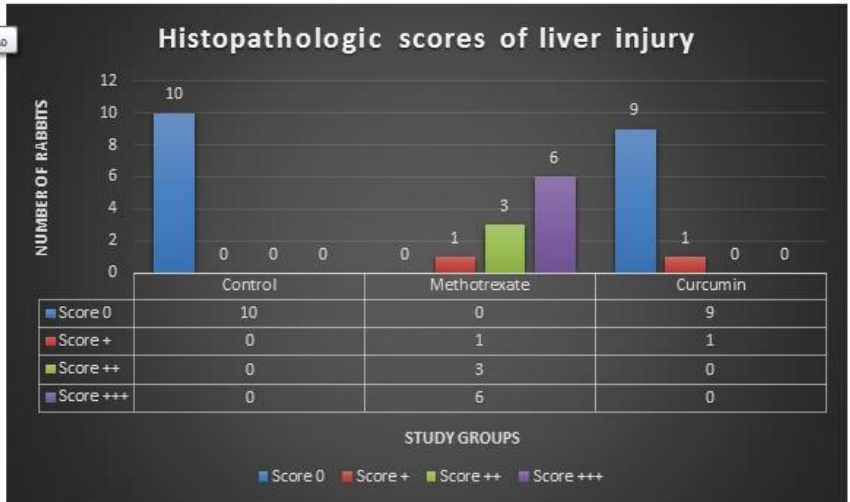


Figure 5: Scores of Liver Injuries in Study Groups According to David E Kleiner.

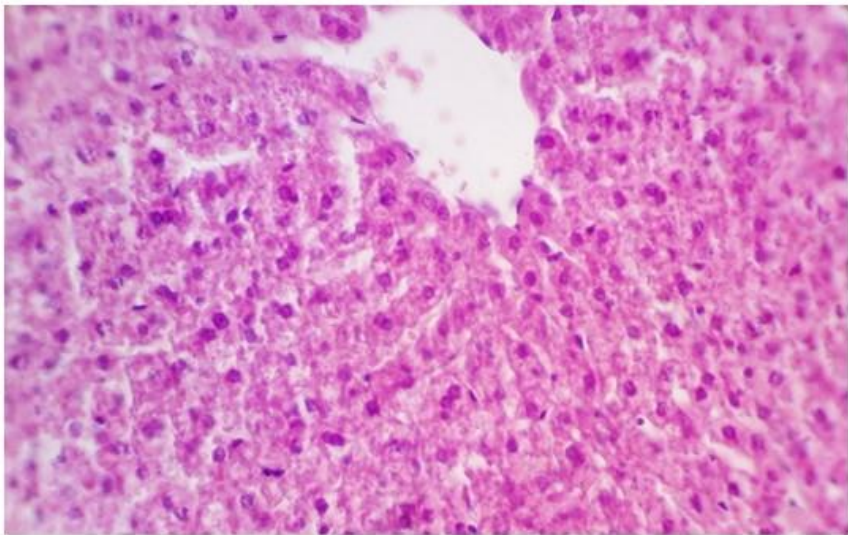


Figure 6: Section from Control Group (Normal Liver Histology).

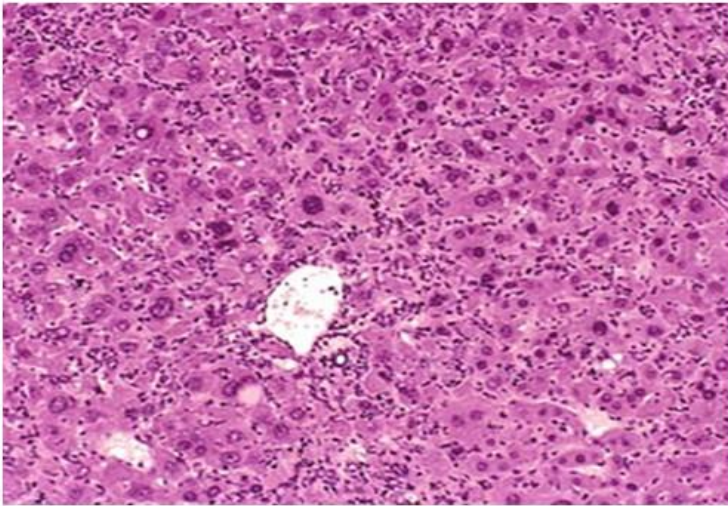


Figure 7: Section of Liver from Methotrexate Group, Showing Acute Hepatitis.

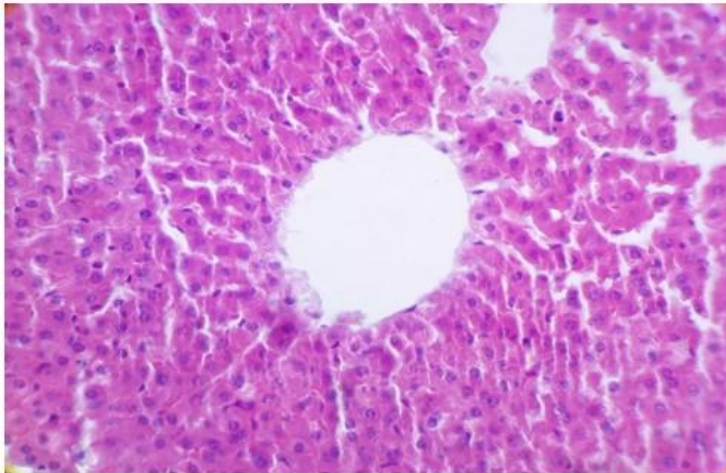


Figure 8: Section of Liver from Curcumin Group Showing Almost Normal Histology.

22-Discussion

Chemotherapeutic agents are widely used in treatment of various human cancers [1]. Chemotherapeutic drugs are not working selectively on tumor cells, they interfere with physiological homeostasis of cells in most of vital body organs in particularly the liver, kidneys, hair forming cells, bone marrow producing cells and heart [2] [4]. Although, Methotrexate is one of the most efficient anticancer drug it has been reported to cause toxicity in livers, hearts, kidneys, and cause hair loss [2] [4]. The present study showed that methotrexate is a hepatotoxic drug. Hepatotoxicity of methotrexate was shown by finding in Methotrexate group of abnormal levels of serum bilirubin, liver enzymes (AST, ALT, ALP, and LDH), INR, and confirmed by histopathological examination of liver sections. Findings from present study also showed that, total serum bilirubin, INR and serum liver enzymes are good markers for liver cells injury, because their levels correlate well with the scores of liver cells injury on histopathological examination. The more the liver cell damage seen on histopathology, the more the alterations in these serum parameters. The scores of liver cells injury depending on serum parameters, and per scoring system introduced by CIOMS [17], were scores were 0 in control group, in Methotrexate group one rabbit scored mild 1+, three moderate ++, and six moderate to severe +++. While in Curcumin group, one rabbit scored mild score +, and nine scored 0. These findings agree with other studies by [1] [18] [3]. Although the mechanism of methotrexate induced liver toxicity is not entirely elucidated but in the present study, occurrence of oxidative stress is highly suspected because of increased levels of MDA and decrease level of GSH and SOD in liver tissue homogenate. The MDA level is a marker for lipid peroxidation, while GSH and SOD are intracellular antioxidant systems [19]. Results of present study showed MDA significantly accumulated in liver cells of methotrexate group compared to controls indicating membranes damage and lipid peroxidation because of oxidative stress and generation and accumulation of ROS induced by methotrexate administration. This finding agreed with previously reported studies by [7] [8] [9]. The finding of reduced levels of SOD and GSH in liver tissue homogenates in the present were due to their utilization which again support oxidative stress and generation of ROS in the pathogenesis of methotrexate induced hepatotoxicity. This finding also agree with the same findings in studies by [7] [8] [9] [15] [17] [19]. The histopathological scoring of liver cell injury depending on scoring method introduced [19] by David E Kleiner (2017) was in control group the score was 0, in Methotrexate group one rabbit scored mild score +, three moderate score ++, and six severe score +++ liver cell injury. Histopathological scoring in Curcumin group was one rabbit mild score +/-, and nine normal score 0. The histopathologic scoring result in the present study also correlates good with results of serological scoring system introduced by CIOMS toxicity scale. These finding agreed with findings obtained in other studies by [19] [20] [21]. Evaluation of whole results of serological parameters, liver tissue homogenate, scoring systems and liver tissue histopathology in the present study revealed liver cell injury and hepatotoxicity in Methotrexate group, and normal or near normal in Curcumin group. These findings support Methotrexate induced hepatotoxicity and Curcumin hepatoprotective ability in reducing Methotrexate induced hepatic injury by its antioxidant activity. These findings agreed with other studies by [14] [15] [16] [22].

23-Conclusion

In spite of being a potent chemotherapeutic agent, methotrexate has a lot of side effects including bone marrow suppression, hepatotoxicity, nephrotoxicity and hair loss. The mechanism of methotrexate toxicity is through oxidative stress and reactive oxygen species production. The deleterious effects of methotrexate can be reduced by concomitant administration of natural antioxidant especially Curcumin. Recommendation was to encourage the cancer patients to take natural antioxidants herbs and food supplement especially Curcumin before, during and after the courses of chemotherapy.

References

- [1] A. R. Moghadam, S. Tutunchi, A. Namvaran-Abbas-Abad, and M. Yazdi, "Fateme bonyadi, daryoush mohajeri et al. pre-administration of turmeric prevents methotrexate-induced liver toxicity and oxidative stress," *Complementary and Alternative*, vol. 15, p. 246, 2015. [Online]. Available: 10.1186/s12906-015-0773-6
- [2] I. D. U. M. Steinman AJ, Gladman DD, "Prolonged serologically active clinically quiescent systemic lupus erythematosus: frequency and outcome," *J Rheumatol*, vol. 37, pp. 1822–27, 2010.
- [3] R. Sakthiswary and E. Suresh, "Methotrexate in systemic lupus erythematosus: a systematic review of its efficacy," *Lupus*, vol. 23, pp. 225–35, 2014.
- [4] Sakthiswary R, Suresh E, "Methotrexate in systemic lupus erythematosus: a systematic review of its efficacy," *Lupus*, vol. 23, no. 23, pp. 225–35, 2014.
- [5] M. X.-B. Q. Y.-H. L. S.-F. Zhu H, Deng F-Y, "Pharmacogenetics and pharmacogenomics for rheumatoid arthritis responsiveness to methotrexate treatment: Pharmacogenomics," *Pharmacogenomics*, vol. 15, pp. 551–66, 2014.
- [6] J. West, S. Ogston, C. Palmer, C. Fleming, V. K. R. Dawe, S. Waterston, and J. Foerster, "Methotrexate in psoriasis under real-world conditions: long-term efficacy and tolerability," *British Journal of Dermatology*. June, vol. 174, no. 6, pp. 1407–10, 2016.
- [7] P. T. Wong and S. K. Choi, "Mechanisms and implications of dual-acting methotrexate in folate-targeted nanotherapeutic delivery," *Int J Mol Sci*, vol. 16, pp. 1772–90, 2015. [Online]. Available: 10.3390/ijms16011772
- [8] K. F. A. M. Gilani ST, Khan DA, "Adverse effects of low dose methotrexate in rheumatoid arthritis patients," *J Coll Physicians Surg Pak*, vol. 22, no. 2, pp. 101–4, 2012. [Online]. Available: 02.2012/JCPSP.101104
- [9] M. A. Schwartz, "High-dose methotrexate for metastatic breast cancer to the central nervous system: A single-institution review of 46 patients." *Journal of Clinical Oncology*, vol. 32, no. 5, pp. 1079–89, 2014. [Online]. Available: 10.1200/jco.2014.32.15_suppl

- [10] A. E. Kela, P. Stegmaierc, T. Valeevb, J. Koschmannc, V. Poroikove, and O. V. Kel-Margoulisc, “et al. multi-omics “upstream analysis” of regulatory genomic regions helps identifying targets against methotrexate resistance of colon cancer,” *Journal Data in Brief.*, vol. 10, pp. 499–04, 2017.
- [11] A. A. S. Ralf Paus, Iain S Haslam and V. A. Botchkarev, “Pathobiology of chemotherapy-induced hair loss,” *The Lancet Oncology*, vol. 14, no. 2, pp. 50–9, 2013.
- [12] I. Pountos and P. V. Giannoudis, “Effect of methotrexate on bone and wound healing,” *Journal Expert Opinion on Drug Safety*, pp. 1–11, 2017.
- [13] C. E. Z. D. G. T. Sami Akbulut, Hulya Elbe and E. O. et al., “Cytoprotective effects of amifostine, ascorbic acid and n-acetylcysteine against methotrexate-induced hepatotoxicity in rats,” *World J Gastroenterol*, vol. 20, no. 29, pp. 10 158–10 165, 2014.
- [14] A. H. M. S. H. Seyed Fazel Nabavi, Maria Daglia and S. M. Nabavi, “Curcumin and liver disease: from chemistry to medicine,” *Comprehensive Reviews in Food Science and Food Safety*, vol. 13, 2014.
- [15] R. S. Y. P. H. L.-Y. C. Bao W, Li K and N. A. e. a. Zhang X, “Curcumin alleviates the ethanol-induced hepatocytes oxidativ damage involving heme oxygenase-1 induction,” *J Ethnopharmacol*, vol. 128, pp. 549–53, 2010.
- [16] S. C. Gupta, S. Patchva, and B. B. Aggarwal, “Therapeutic roles of curcumin: Lessons learned from clinical trials,” *The AAPS Journal*, vol. 15, p. 1, 2013.
- [17] J. C. W. M. Huihui Donga, Douglas Slainc and W. Lianga, “Eighteen cases of liver injury following ingestion of polygonum multiflorum.” *Complementary Therapies in Medicine*, vol. 22, no. 1, pp. 70–74, 2014.
- [18] W. T. D. A. B. J. S. C. Maybury CM, Jabbar-Lopez ZK, “Methotrexate and liver fibrosis in people with psoriasis: a systematic review of observational studies.” *Br J Dermatol*, vol. 171, no. 1, pp. 17–29, 2014.
- [19] D. E. Kleiner, “The histopathological evaluation of drug-induced liver injury.” *Histopathology*, vol. 70, no. 1, pp. 81–93, 2015.
- [20] J. M. Crowford, “Evidence-based interpretation of liver biopsies,” *Lab Invest*, vol. 86, pp. 326–34, 2006.
- [21] M. M. Skelly, P. D. Lames, and S. D. Ryder, “Finding on liver biopsy to investigate abnormal liver function test in the absence of diagnostic serology,” *J Hepatol*, vol. 35, pp. 195–209, 2001.
- [22] S. M. S. B. A. V. Ruptanu Banerjee, Mrinmoy Dey and U. S. et al, “Preventive role of curcumin against hepatotoxic effects of methotrexate and cyclophosphamide,” *Journal of Chemical and Pharmaceutical Sciences.*, no. Special Issue (4), pp. 38–41, 2016, issue (4) Pages: 38 – 41.