

The Role of Corrugate Drain In Decreasing Postoperative Complication Of Penile Fracture Surgery

Salam Abd El-Ameer Almosawi

Ahmed Turki Obaid

Surgical department, College of Medicine, Babylon University

Urological department of Al Hilla teaching hospital

Ahmed.carm5@yahoo.com

Abstract

Objective: to study the role of corrugate drain (which is used by some urologists) followed surgical correction of fractured penis in decreasing post operative complications such as penile swelling, pain and curvature.

Patient and method: comparative cross sectional study was carried out at the urological department of Al-Hilla teaching hospital from March 2008 to April 2011.

Twenty male patients (age between 21-40 years) admitted to the urological department in Al-Hilla teaching hospital suffering from penile fracture from March 2008 to April 2011 were included in this study.

Immediate surgical repair done to all those patients ,corrugate drain put post operatively for 10 patients while the remaining 10 patients without drains.

All patients are followed for at least 3 months regarding postoperative penile swelling, deformity, pain and sexual function.

Result: regarding age distribution of patients suffering from fracture penis, from twenty patients included in this study 11 patients their age range from (20-30)years, 7 patients their age group range from (31-45)years and only 2 patients their age range from (46-60)years. Fifteen patients are married and only 5 patients are unmarried. No one develop postoperative penile swelling in patients with corrugate drain and only one patient develops swelling in patients without corrugate drain. Regarding postoperative pain, in patients surgically corrected with drain, 6 patients develop pain and only 2 patients surgically corrected without drain develops pain.

Conclusion: No beneficial effect of corrugate drain in decreasing postoperative penile swelling or curvature and on the other hand it increase post operative penile pain.

Key words: fracture penis, corrugate drain, curvature.

الخلاصة

الغرض من الدراسة: هو دراسة دور المصرف المتجدد والذي يقوم بأستخدامه البعض من جراحي الجراحة البولية بعد إجراء عملية تصحيح كسر القضيب للتقليل من التورم والالام والانحراف في القضيب.

طريقة العمل : دراسة مقارنة مقطعية أجريت في شعبة الجراحة البولية في مستشفى الحلة الجراحي، عشرون مريضاً أعمارهم تتراوح بين 21 إلى 40 سنة كانوا يعانون من كسر القضيب للفترة من اذار 2008 الى نيسان 2011.

ادخلوا الى شعبة الجراحة البولية في مستشفى الحلة التعليمي العام، تم إجراء تداخل جراحي فوري لكل المرضى، حيث تم وضع المصبب المتجدد الى عشرة من هؤلاء المرضى ولم يتم ذلك للعشرة الاخرين. جميع المرضى تم متابعتهم مابعد العملية ولفترة لا تقل عن ثلاثة أشهر وخصوصاً بمايتعلق بتورم وتشوه القضيب وايضا الالام والوظائف الجنسية.

النتائج: بما يتعلق بأعمار المرضى الذين يعانون من كسر القضيب والمشمولين في الدراسة، كان هناك 11 مريضاً أعمارهم تتراوح بين (20-30) سنة، 7 من المرضى كانت أعمارهم بين (31-45) سنة، 2 من المرضى كانت أعمارهم تتراوح بين (46-60) سنة. وبما يتعلق بالحالة الزوجية للمرضى، 15 مريضاً كانوا متزوجين فقط و 5 من المرضى كانوا غير متزوجين. لم يعاني أي مريض من المرضى الذين تم إجراء لهم عملية تصحيح كسر القضيب وتم وضع لهم المصبب المتجدد من اي تورم في القضيب ولكن مريض واحد فقط من المرضى الذي تم إجراء لهم عملية تصحيح الذكر ولم يتم وضع لهم المصبب المتجدد كان قد عانى من تورم القضيب. بما يتعلق بالالام ما بعد عملية تصحيح كسر القضيب، 6مرضى فقط كانوا قد من الالام من المجموعة الذي تم وضع لهم المصبب المتجدد بينما مريضان فقط من المرضى الذي لم يتم وضع لهم المصبب المتجدد كانوا قد عانوا من الالام مابعد عملية تصحيح كسر القضيب.

الاستنتاج: من النتائج المستوحاة لهذا البحث إن استخدام المصّب المتجدد مابعد عملية تصحيح كسر القضيب غير مفيد بالتقليل من التورم او تقليل الالم او إنحراف الذكر مابعد عملية تصحيح كسر القضيب .
الكلمات الافتتاحية: كسر القضيب، المصّب المتجدد، انحراف القضيب

Introduction:

A **penile fracture** is an injury caused by the rupture of the tunica albuginea, which envelops the corpus cavernosum penis. It is most often caused by a blunt trauma to an erect penis (Jagodic *et al* 2007).

It usually occur during vigorous sexual intercourse and presented with pain and swelling of the penis due to penile hematoma. Also popping or cracking sound, significant pain, immediate flaccidity, and skin hematoma of various sizes are commonly associated with the event (Jagodic *et al* 2007).



Picture (1) penile fracture deformity

Penile fractures typically occur when the engorged penile corpora are forced to buckle and literally “pop” under the pressure of a blunt sexual trauma (Andrew *et al.*, 2010.).

The fracture occurs when one or both corpora cavernosa are ruptured, usually during erection due to a direct trauma. There may be associated injury to the corpus spongiosum or urethra (3). In more than half of the cases, rupture occurs during sexual intercourse (Andrew, *et al* 2010), and the remaining are secondary to rolling over in bed (Nuzzo, Regina,2009), or kneading the penis to achieve detumescence (Jagodic *et al* 2007). There have been other mechanisms of rupture reported previously (Zargooshi, *et al* 2000)

Incidence and Pathophysiology

Anatomically, the flaccid penis lacks a fulcrum for snapping and contains relatively thick tunica albuginea, protecting it from internal rupture under strain.

In contrast, the tunica of the erect penis thins to approximately 0.25 mm on expansion, and the firmly engorged corpora under the strain of buckling can generate pressures in excess of 1500 mm Hg and exceed the limit of the thinned tunica (3).

The first case of a penile fracture was described in the literature in 1924 (Chung, *et al.*, 2006).

Although initially regarded as a relatively rare injury, fracture of the penis is an increasingly reported genitourinary trauma.

A review by one investigator identified more than 1600 cases in the world literature, with more than half of those cases originating from Muslim countries (El Etat *et al.*, 2008). The largest single series to date describes 172 cases over 9 years in a single province of Iran (El Etat, *et al.* 2008).

In the United States, the majority of cases are the result of traumatic coitus, usually from thrusting an erect penis against the symphysis pubis or perineum (El Etat, *et al.*, 2008).

In Japan, only 19% of cases are attributed to sexual intercourse, with the majority of cases reported as the result of masturbation and rolling over in bed onto an erect penis (Ishikara, *et al.* 2003).

A majority of the cases in Mediterranean countries are the result of patients kneading and snapping their penis during erection to achieve detumescence (El Etat *et al.* 2008). In Iran, only 8% of the cases were attributed to sexual intercourse; the remaining cases were due to self-manipulation and potentially fabricated events, such as a donkey bite to the erect penis, a man falling from a mountain onto his erect penis, and a brick falling onto an erect penis (El Etat *et al.*, 2008).

Other rare reports in the world literature include cases resulting from banging an erect penis against a toilet, masturbating into a cocktail shaker, and placing an erect penis into tight pants. (Ishikara, *et al.*, 2003)

Although immediate surgical repair has been recommended by most authors for fractured penis, delayed repair is possible and has been suggested in situations where accurate localization of the fracture site is clinically not evident (Naraynsingh *et al.*, 2003; Nasser and Mostafa, 2008).

The gross penile swelling decreases rapidly, and by 7-12 days, the clot at the fracture site is easily palpable and is often visible.

Earlier, we had described the 'rolling sign' for early identification of the fracture site, even when the penis is quite swollen (Naraynsingh and Raju, 1985). We report a late presentation of a case of fracture penis which probably clarifies the pathogenesis of the 'rolling sign' (Muentener, *et al.* 2004).

Clinical Presentation

Penile fractures are commonly diagnosed from their stereotypical clinical presentation (Mansi, *et al.* 1993).

Patients commonly report hearing a "pop" or cracking sound from the erect penis at the moment of injury (Muentener, *et al.* 2004).). Some patients have likened the sound to the snapping of a corn stalk or glass rod (Zargooshi, *et al.* 2000). Detumescence occurs rapidly, and acute swelling, pain, and penile deformity follow. The pain can vary from minimal to severe and is not proportional to the degree of injury (Mydlo, 2001).

Cases that lack the popping sound or in which there is gradual detumescence have a higher rate of false positive diagnosis¹⁴ and might benefit from additional preoperative workup.

The gross appearance of a fractured penis is often summarized as an “eggplant deformity,” which refers to the combination of localized penile swelling, discoloration, and deviation toward the opposite side of the fracture (Mydlo, 2001).

Manual examination of the penis can often detect the site of the corporal tear by palpation of the overlaying hematoma (Naraynsingh, *et al* 1985).

Treatment

Nonoperative Treatment of Penile Fractures

Ice packs, Foley catheterization, and anti-inflammatory medicines were initially regarded as the standard of care for penile fractures (Cendron, *et al* 1990), and the condition was associated with a relatively high morbidity rate. Attempts to minimize the long-term complications of penile fractures involved the use of compression bandages, erection-inhibiting estrogens, penis splints, antibiotics, and fibrinolysis agents; however, the long-term complication rates remained approximately 30% or higher despite all of the above (Nicoliasen, *et al.*, 1983). Commonly reported complications included painful erections, severe penile angulation, arterial-venous fistulas, infected hematomas, abscess formation, and impotence (Nicoliasen *et al.*, 1983).

As a result, instead of conservative therapy, current recommendations are for immediate surgical exploration and repair (Ishikawa, *et al.*, 2003).

Surgical Repair and Timing of Repair

Surgical repair of penile fractures was popularized in the 1980s after several studies demonstrated that long-term complications were reduced from 30% to 4% in surgically treated patients (Nicoliasen *et al.*, 1983). Thus, the current literature generally advocates immediate surgical repair upon presentation to the hospital (Fetter *et al* 1936). In the event of a delayed presentation (48 hours after injury), immediate repair is still advocated, although it is associated with increased risk of long-term sequelae (Ishikawa *et al* 2003). In 1 patient, delayed treatment was performed as late as 30 days after the injury (Ishikawa *et al.*, 2003). In another series of 3 patients, investigators reported successful outcomes after intentionally delaying the repair for 7 to 12 days, though this practice is not universally recommended (Naraynsingh *et al* 1985).

Surgical Technique

Proper surgical repair of penile fractures requires evacuation of the hematoma, identification of the tunica injury, local corpora debridement, closure of the tunica lacerations, and ligation of any disrupted vasculature (Eke, 2002). The type and location of the incision is operator dependent, although we use and recommend a distal circumferential degloving incision, as advocated by McAninch and others (Zargooshi, 2000). In addition to being the most cosmetic incision, distal degloving readily allows exposure to the entire tunica bilaterally, facilitating diagnosis and repair of coexisting urethral and contralateral injuries (Cendron *et al.*, 1990). Some surgeons argue that the degloving is associated with increased neurovascular injury and skin necrosis (Cendron *et al.*, 1990) and they advocate a less invasive lateral incision directly over the hematoma site (Cendron *et al.*, 1990). Still others prefer the

selective use of each incision based on the clinical presentation and severity of injury (Ishikawa *et al.*, 2003). Suprapubic, inguinal-scrotal, and perineal incisions have also been reported to have excellent functional and cosmetic results (Asgari *et al.*, 1996). Regardless of the incision site, proper dissection must be carried down until the hematoma within Buck's fascia is exposed and evacuated (Klein *et al.*, 1985). The underlying laceration in the tunica albuginea usually runs transverse in direction (Eke, 2002), and lies ventral and lateral in location (Eke, 2002). Most commonly, the proximal corpora is the source of the rupture, but the injury can occur anywhere (Fergany *et al.*, 1999). Extremely proximal corporal injuries have also been reported, sometimes necessitating a perineal approach for repair (Pruthi *et al.*, 2000). For an unknown reason, significantly more lesions occur to the right corpora (Eke, 2002) with the right side incidence as high as 75%.

Patients and Methods

Twenty male patients (age between 20-60 years) admitted to the urological department in Al-Hila teaching hospital suffering from penile fracture from March 2008 to April 2011 were included in this study.

The interval from injury to presentation was between 6 hours and the 3 days.

Detail history and good physical examination had been done to all those patients.

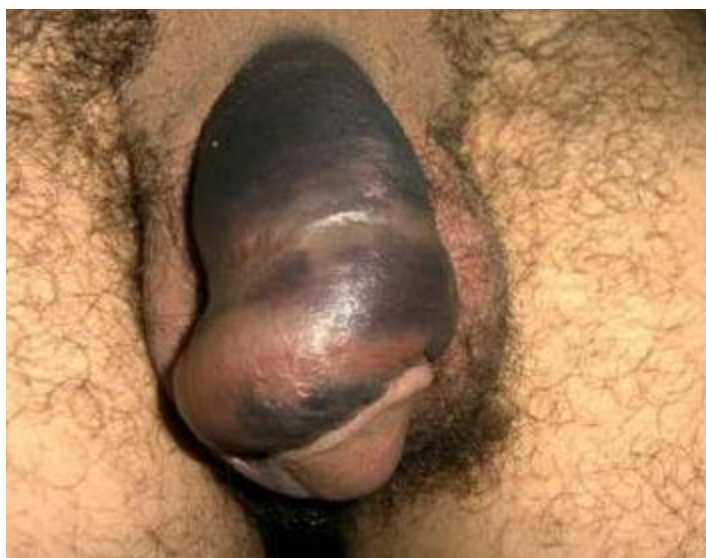Immediate surgical repair done to all those patients under general anesthesia and using sub coronal circumferential degloving skin incision to locate and repair the fracture site.

Patients with urethral injuries and those with multiple sites of fractured penis are excluded from the study.

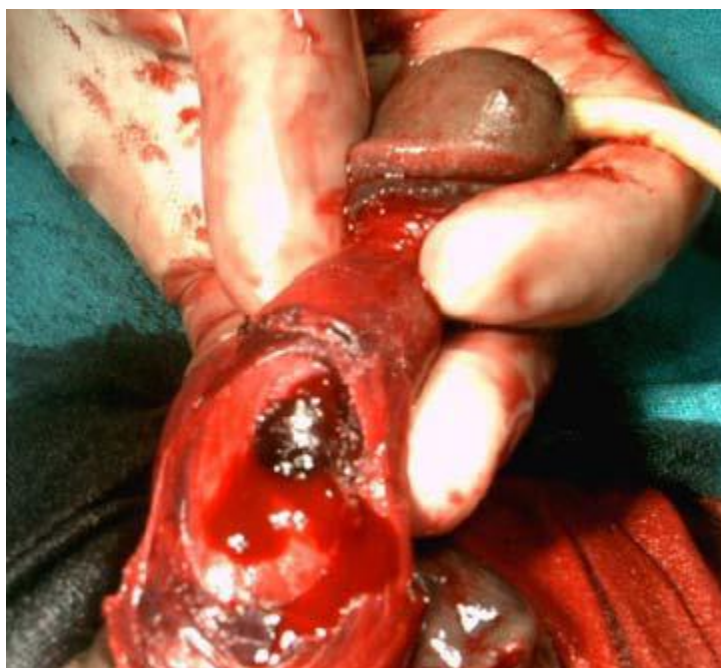Corrugate drain put for 10 patients while the remaining 10 patients surgically corrected without drain.

All patients are followed for at least 3 months regarding postoperative penile swelling, deformity, pain and sexual function.

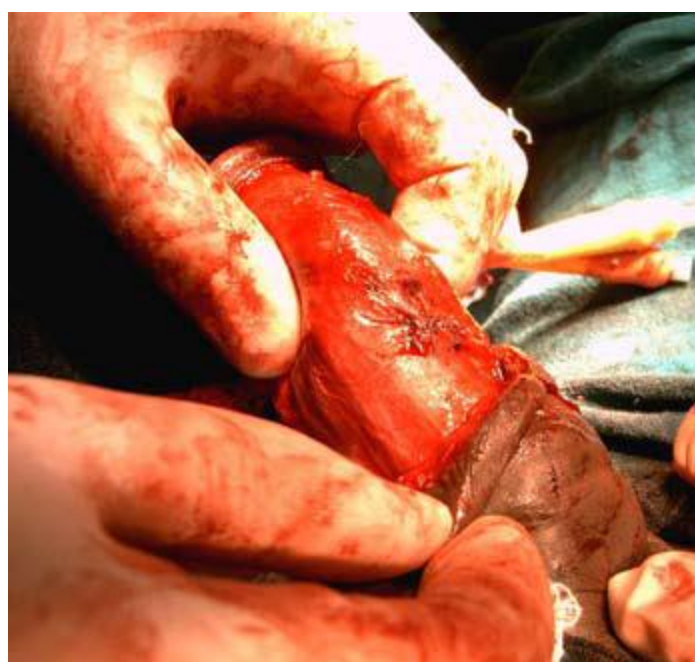Data had been statistically analyzed using Fisher exact test and regression analysis with p-value <0.05 consider significant, p-value <0.01 is highly significant while p-value <0.001 is extremely significant.



Picture (2): Eggplant deformity of fractured penis



Picture (3): Subcoronal circumferential degloving penile skin incision show the site of hematoma (fracture site).



Picture (4) water tight sutured tunica albuginea.

Results and Discussions

1- Fractured penis distribution among age group and marital state

In this study, most cases of fractured penis occur among young and early middle age group males. These results are comparable to those obtained by Imtiaz Wani *et al.*, in 2000 A.C.

Also in this study, fractured penis is more common among married male persons (15 married versus 5 single patients) but these results are not similar to those obtained by Imtiaz Wani *et al* in India in 2000 A.C. which reveal that fractured penis is more common among single persons.

These finding can be explained by the fact that young and early middle age group persons are more sexually active persons and more susceptible to fractured penis during vigorous sexual intercourse which is the most common mechanism of injury.

Regarding the differences in the incidence among married and single persons between this study and Imtiaz Wani study occur because the difference in the mechanism of injury in different populations.

These results are shown in table (1) and table (2) also in figure (1) and figure (2).

Table (1) distribution of fractured penis cases among age groups.

Age of patients	No. of fractured penis cases	Percentage
20-30 years	11	55%
31-45 years	7	35%
45-60 years	2	10%

Table (2) distributions of fractured penis cases according to the marital state

Marital state	No. of fractured penis cases	Percentage
Married	15	75%
Un married	5	25%

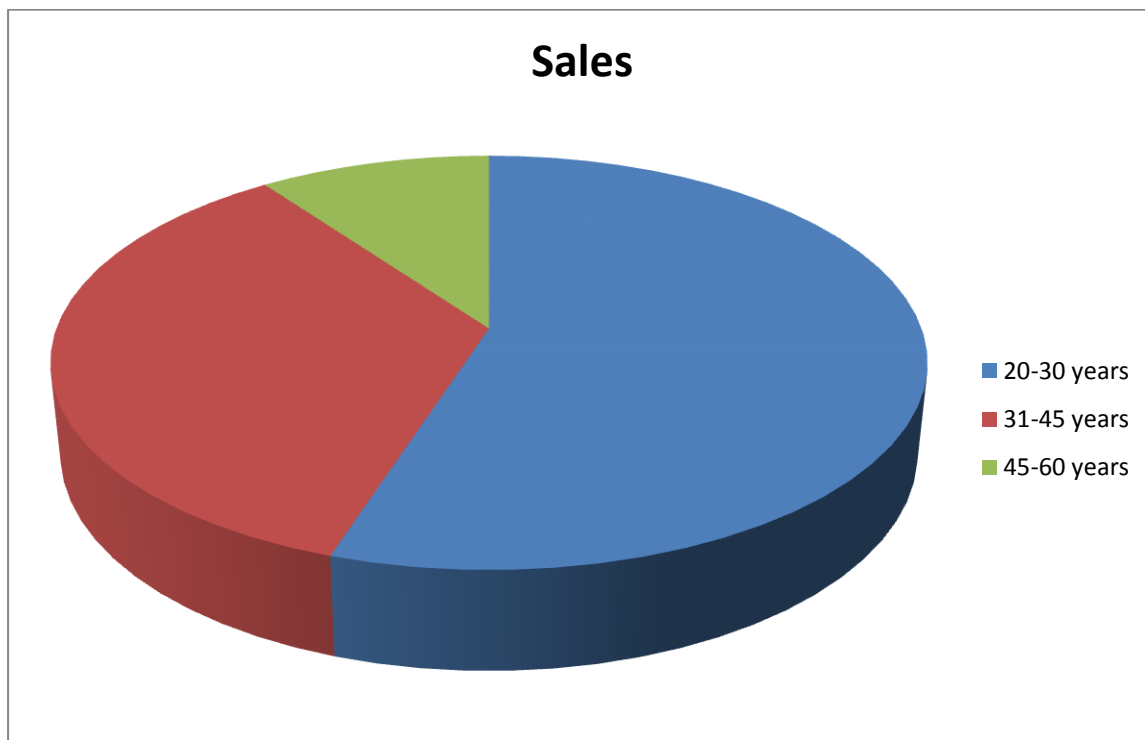


Figure (1) Distribution of fractured penis among age groups.

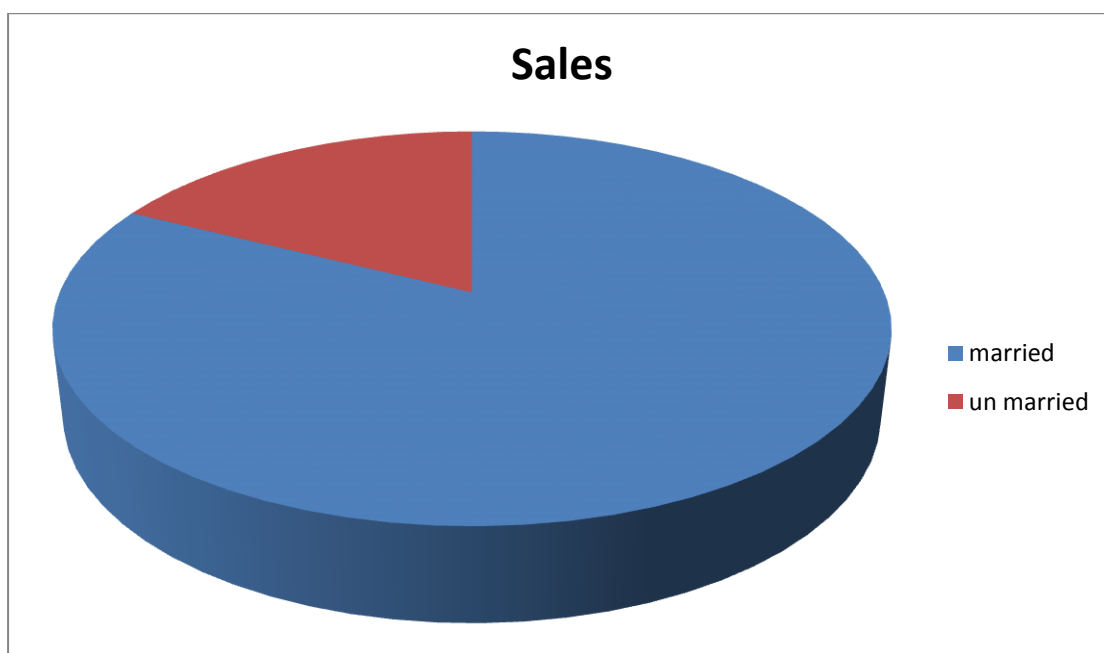


Figure (2) fractured penis cases according to the marital state.

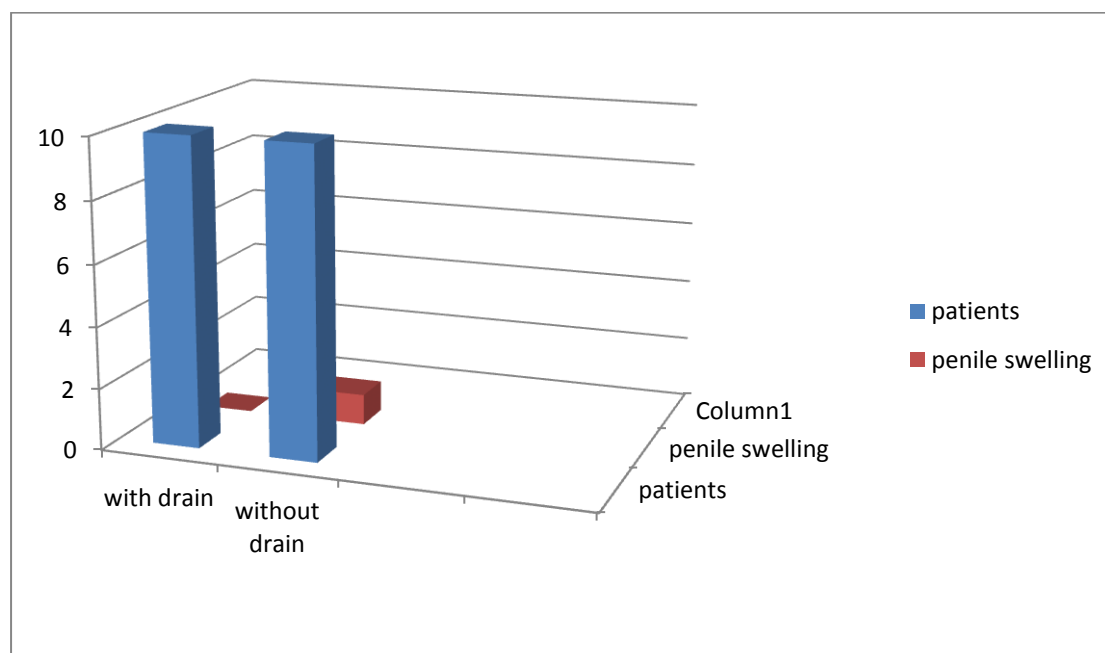
2-The effect of corrugate drain on postoperative penile swelling

Of the 10 patients with corrugate drain, no one complaining of postoperative penile swelling while only one patient of those with drain less correction of penile fracture complaining of postoperative penile swelling need evacuation of hematoma by opening one of the sub coronal sutures.

These results are insignificant statistically with $p\text{-value} > 0.05$. This can be explained by fact that the tunica albugina is tightly sutured (water tight sutures) and in tow layers this prevent leakage of blood from cavernous sinusoids, also the oozed blood from the penile skin and subcutaneous tissue not accumulate in the penis (even without drain) because the sub coronal skin sutures are interrupted and allowed blood to passed between sutures and not accumulate.

Table (3) the effect of corrugate drain on postoperative penile swelling.

Fractured penis patients	Total number of patients	Patients with post op. penile swelling
Surgically corrected with drain	10	0
Surgically corrected with out drain	10	1



Figure(3) The effect of corrugate drain on postoperative penile swelling.

3- The effect of corrugate drain on postoperative penile pain

The pain threshold differs from person to person but in general we depend on the effect of pain on the patient sleep to consider it as severe pain.

Of the 10 patients with fractured penis whose corrected surgically with use of postoperative drain,6 of them complain of severe pain pain in day 0 postoperatively while only 2 of patients without drains suffering from severe pain.

These results are statistically significant with $P\text{-value} < 0.05$.

This can be explained as the corrugate drain can cause trauma and irritation to the nerve supply of the penis causing more pain.

Table (4) the effect of corrugate drain on postoperative pain.

Fractured penis patients	Total number of patients	Patients with severe post op pain
Surgically corrected with drain	10	6
Surgically corrected with out drain	10	2

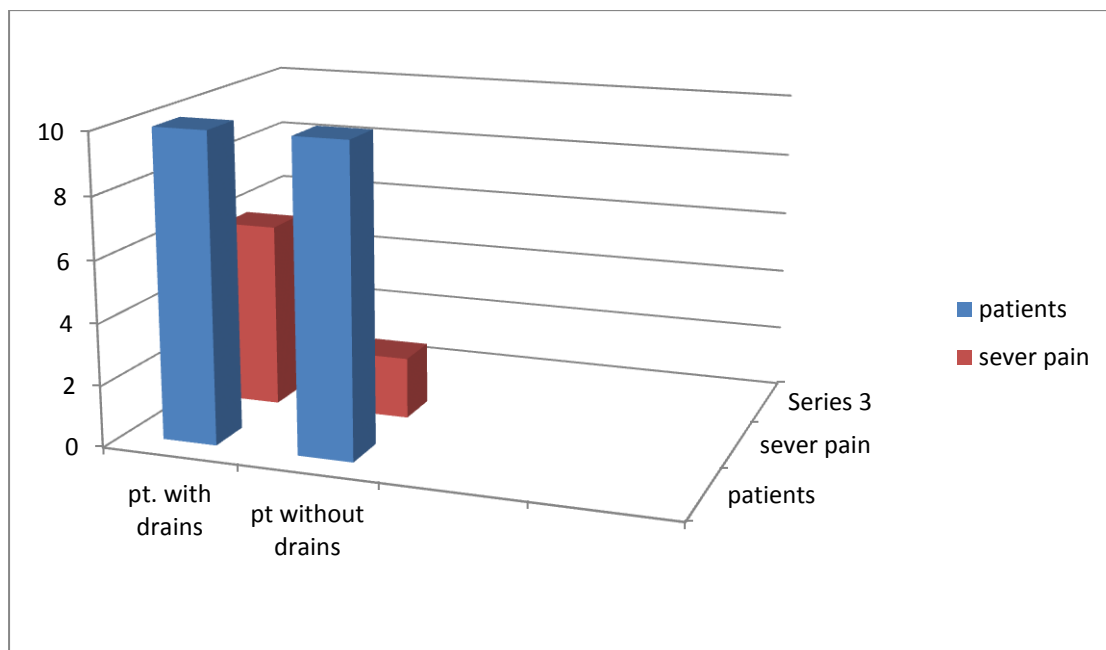


Figure (4) the effect of corrugate drain on postoperative pain.

4- The effect of corrugate drain on postoperative penile curvature:

Some degree of penile curvature occur postoperatively in most patients with penile fracture but sever penile curvature that cause severe pain and obstacle subsequent sexual intercourse occur only in 2 patients , one patient had history of postoperative corrugate drain and the other without drain so no beneficial effect of corrugate drain in decreasing post operative penile curvature.

Table (5) the effect of corrugate drain on postoperative penile curvature.

Fractured penis patients	Total number of patients	Patients with severe post op. penile curvature
Surgically corrected with drain	10	1
Surgically corrected with out drain	10	1

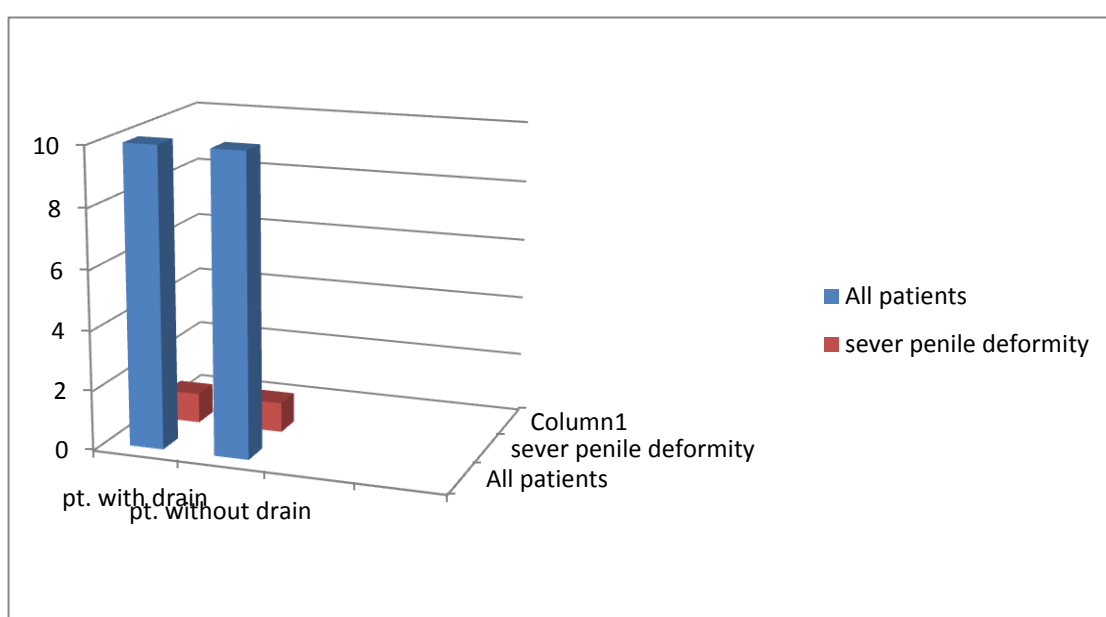


Figure (5) the effect of corrugate drain on postoperative penile curvature

Conclusion

Penile fracture is a remarkable but under-reported urologic injury. It is more common in young married male persons. Surgical treatment is the preferred option of treatment with less complication. No beneficial effect for postoperative corrugate drain in decreasing postoperative swelling or curvature on contrast it increase postoperative pain.

References

- Andrew B. Peitzman; Michael Rhodes; C. William Schwab; Donald M Yealy, Timothy C Fabian (1 September 2007). *The trauma manual: trauma and acute care surgery*. Lippincott Williams & Wilkins. pp. 305–. ISBN 978-0-7817-6275-5. <http://books.google.com/books?id=JnTMQOMcYZwC&pg=PA305>. Retrieved 18 April 2010.
- Asgari MA, Hosseini SY, Safarinejad MR. Penile fractures: evaluation, therapeutic approaches and long-term results. *J Urol*. 1996;155:148–149. [PubMed]
- Beysel M, Tekin A, Gurdal M. Evaluation and treatment of penile fractures: accuracy of clinical diagnosis and the value of corpus cavernosography. *Urology*. 2002;60:492–496. [PubMed]
- Can you break your penis?," "The Times of India <http://timesofindia.indiatimes.com/life-style/relationships/ask-the-expert/Can-you-break-your-penis/articleshow/5283625.cms>
- Cendron M, Whitmore KE, Carpiello V, et al. Traumatic rupture of the corpus cavernosum: evaluation and management. *J Urol*. 1990;144:987–991. [PubMed]
- Chung CH, Szeto YK, Lai KK. Fracture of the penis: a case series. *Hong Kong Med J* 2006; 12: 197-200
- Cumming J, Jenkins J. Fracture of the corpora cavernosa and urethral rupture during sexual intercourse. *Br J Urol*. 1991;67:327. [PubMed]
- Eke N. Fracture of the penis. *Br J Surg*. 2002;89:555–565. [PubMed]

- El Etat R, Sfaxi M, Benslama MR, Amine D, Ayed M, Movelli SB, Chebil M, Zmeril S.
- Fergany AF, Angermeier KW, Montague DK. Review of Cleveland Clinic experience with penile fracture. *Urology*. 1999;54:352–355. [PubMed]
- Fetter TR, Gartman E. Traumatic rupture of penis. Case report. *Am J Surg*. 1936;32:371.
- Fracture of the penis: management and long-term results of surgical treatment. Experience in 300 cases. *J Trauma* 2008; 64: 121-5
- Ghanem AN. Re: penile fractures in Kermanshah. *Br J Urol*. 2002;89:890.
- Godec CJ, Reiser R, Logush AZ. The erect penis-injury prone organ. *J Trauma*. 1988;28:124–126.[PubMed]
- Ishikara T, Fujisawa M, Tamanda H, Inoue T, Shimatani N. Fracture of the penis: nine cases with evaluation of reported cases in Japan. *Int J Urol* 2003; 10: 257-60.
- Ishikawa T, Fujisawa M, Tamada H, et al. Fracture of the penis: nine cases with evaluation of reported cases in Japan. *Int J Urol*. 2003;10:257–260. [PubMed]
- Jagodic K, Erklavec M, Bizjak I, Poteko S, Korosec Jagodic H. A case of penile fracture with complete urethral disruption during sexual intercourse: a case report. *J Med Case Reports*. 2007 May 2;1:14. <http://www.jmedicalcasereports.com/content/1/1/14>
- Jallu A, Wani NA, Rashid PA. Fracture of the penis. *J Urol*. 1980;123:285–286. [PubMed]
- Kamdar C, Mooppan UM, Kim H, Gulmi FA. Penile fracture: preoperative evaluation and surgical technique for optimal patient outcome. *BJU Int* 2008; 102: 1640-4
- Karadeniz T, Topsakal M, Ariman A. Penile fracture: differential diagnosis, management, and outcome. *Br J Urol*. 1996;77:279–281. [PubMed]
- Klein FA, Smith V, Miller N. Penile fracture: diagnosis and management. *J Trauma*. 1985;25:1090–1092. [PubMed]
- Malis J. Zur Kausistik der fractura penis. *Arch Klin Chir*. 1924;129:651. (Ger).
- Mansi MK, Emran M, el- Mahrouky A, el-Mateet MS. Experience with penile fractures in Egypt: Long- term results of immediate surgical repair. *J Trauma* 1993; 35: 67-70.
- Miller S, McAninch JW. Penile fracture and soft tissue injury. In: McAninch JW, editor. *Traumatic and Reconstructive Urology*. Philadelphia: W.B. Saunders; 1996. pp. 693–698.
- Muentener M, Suter S, Hauri D, Sulser T. Long-term experience with surgical and conservative treatment of penile fracture. *J Urol* 2004; 172: 576-9
- Mydlo JH. Surgeon experience with penile fracture *J Urol* 2001; 166: 526-9
- Mydlo JH. Surgeon experience with penile fracture. *J Urol*. 2001;166:526–529. [PubMed]
- Naraynsingh V, Raju GC. Fracture of the Penis. *Br J Surg* 1985; 72: 305-6
- Naraynsingh V, Raju GC. Fracture of the penis. *Br J Surg*. 1985;72:305–306. [PubMed]
- Naraynsingh V, Ramdass MJ, Thomas D, Maharaj D. Delayed repair of a Fractured Penis: A New Technique. *Int J Clin Pract* 2003; 57: 428-9
- Nasser TA, Mostafa T. Delayed Surgical Repair of Penile Fracture under Local Anesthesia. *J Sexual Med* 2008; 5: 2464-9
- Nicoliasen GS, Melamud A, McAninch JW. Rupture of the corpus cavernosum: surgical management. *J Urol*. 1983;130:917–919. [PubMed]

- Nuzzo, Regina. Preventing penile fractures and Peyronie's disease. Los Angeles Times, February 9, 2009. <http://www.latimes.com/features/health/la-hew-mating9-2009feb09,0,5573112,full.story>
- Porst H. Re: Penile fracture repair: assessment using color Doppler ultrasound. *Int J Impot Res.* 2000;12:128–129.
- Pruthi RS, Petrus CD, Nidess R, Venable DD. Penile fracture of the proximal corporeal body. *J Urol.* 2000;164:447–448. [PubMed]
- Schonberger B. Verletzungen der mannlichen Genitalorgane. *Z Urol Nephrol.* 1982;75:879. (Ger).[PubMed]
- Shah DK, Paul EM, Meyersfield SA. False fracture of the penis. *Urology.* 2003;61:1259. [PubMed]
- Tsang T, Demby AM. Penile fracture with urethral injury. *J Urol.* 1992;147:466–468. [PubMed]
- Zargooshi J. Penile fracture in Kermanshah, Iran: report of 172 cases. *J Urol.* 2000;164:364–366.[PubMed]
- Zargooshi J. Re: Surgeon experience with penile fracture. *J Urol.* 2001;166:528–529.
- Zargooshi, Javaad. Penile Fracture in Kermanshah, Iran: Report of 172 cases. *The Journal of Urology: Vol 164, Issue 2, August 2000, Pages 364-366.*