

Dose response effects of carbohydrate nature of lyophilized leaf powder of *Azadirachta indica* on testis of albino rats

Kalpana I. Pattan,¹ Mukhtar Ahmed G.Ghodesawar^{2*} and Ravindranath H.Aladakatti³

¹K.L.E. Society, R.L.S. Institute, Belgaum –590001, Karnataka, India.

²Anjuman Arts, Sciences & Commerce College, Bijapur –586101, Karnataka, India.

³Central Animal Facility, Indian Institute of Science, Bangalore-560012, Karnataka, India.

Abstract

The purpose investigation is designed to investigate the effect of carbohydrate nature of lyophilized *Azadirachta indica* leaf powder on the histology of testis, since experimental studies shown that the chemical nature of leaf powder was studied and observed that the leaf powder was carbohydrate-rich in nature. In the present study of histomorphometric and histopathological dose dependent assessments of carbohydrate nature of lyophilized *A.indica* leaf powder on the testis of male wistar rats given 25, 50 and 75 mg in suspension of 1 mL Propylene Glycol, respectively/kg body weight, once daily, orally, for 24 days showed varying degrees of desquamation of seminiferous epithelial cells, degeneration of seminiferous tubules and presence of large-sized multinucleated cells as well as the spermatogenesis was arrested either at the primary spermatocytes or the spermatogonial stages. Damaged seminiferous tubules contained the abundance of vacuoles with varying size Total count, cell and nuclear diameter of spermatogonia, spermatocytes, spermatids and Leydig cells were reduced in a dose dependent manner ($P \leq 0.05$). From the results obtained, it can be observed such effects on the testis are possibly due to curtailing of androgen supply within the testis or it may be a direct effect of this carbohydrate-rich nature of lyophilized *A. indica* leaf powder on the tissue probably due to direct or indirect gonadotrophic hormone deficiency.

Keywords: Lyophilized *A. indica* leaf powder, Testis, Germ cells, Leydig cells and Albino rats

INTRODUCTION

Currently, one of the social problems regarding world health is the stability of population growth. Even though research on male reproduction has been extensive in the last years, little effort has been made to develop male contraception. Demand for scientific interest in many aspects of complementary medicine particularly medicinal plants has increased considerably in recent years and elucidation of plants medicines will ultimately provide the scientific basis to establish the safety and efficacy of all forms of herbal medicines (Borchers et al., 1997). Due to the strict sequence and nature of the events that determine male gamete maturity, interference in any step would have serious consequences on the eventual sperm fertilizing capability. A method of interfering in the male reproductive process, without affecting libido, spermatogenesis or the genomic integrity of the sperm cell would be attractive. Various plants and their active principles have been extensively tested for spermatogenesis and accessory reproductive organs in different animals (Bhargava, 1988). The role of these indigenous plant products in the induction of male and female fertility in experimental animals has drawn the attention of researchers over the turn of the century (Farnsworth, et al., 1975).

Azadirachta indica A. Juss (Syn: *Melia Azadirachta* L,

Meliaceae family), commonly known as neem, is an important medicinal plant cultivated throughout India and Burma. This plant is extensively used as an astringent, antiperiodic, antiprotozoal, antileprosy and bronchitis; for healing ulcers in urinary passages; for chronic fever and many other disorders (Bhakuni et al., 1990). Oral administration of crude extracts of *A.indica* leaves persuades changes in the spermatogenic pattern and ultrastructural changes in the Sertoli cells and Leydig cells of rat testis (Aladakatti & Nazeer Ahamed, 2005a, 2005b; 2006). Further, *in vitro* and *in vivo* experimental studies were shown that the lyophilized *A.indica* leaf powder is carbohydrate in nature and act as spermicidal in rat and human spermatozoa (Kumbar et al., 2012a, Killare and Shrivastav, 2003); antiandrogenic nature by affecting the androgen dependent biochemical parameters of rat testis and epididymis (Aladakatti et al., 2010); and elicit depletion of antioxidant defense system by decreasing the activities of antioxidant enzymes and increasing the levels of lipid peroxidation and hydrogen peroxide generation in rat epididymal spermatozoa (Kumbar et al., 2012b). The present experiment was designed to study the effect of lyophilized *A.indica* leaf powder on rat testis and an attempt has also been made to delineate the histological changes within the seminiferous tubule or epithelium.

MATERIALS AND METHODS

Preparation of neem lyophilized leaf powder

An aqueous extract was prepared from *A.indica* (neem) leaves. Neem leaves were ground in a mixer and filtered with gauze. The filtrate was washed with chloroform in 1:1 proportion, centrifuged at 3000 rpm for 20 min. The pellet was discarded and the supernatant frozen at -20°C for lyophilization. The extracts were lyophilized separately.

Received: Sept 10, 2012; Revised: Nov 02, 2012; Accepted: Dec 23, 2012.

*Corresponding Author

G.Ghodesawar

Anjuman Arts, Sciences & Commerce College, Bijapur –586101, Karnataka, India.

Email: drmukhtarahmedgg@gmail.com

Chemical nature of lyophilized leaf powder

The chemical nature of ingredients of lyophilized leaf powder was studied for the presence of lipid, protein and carbohydrate. Preparation of Fehling's solution for the carbohydrate estimation was performed as described elsewhere (Hawk, 1965, Killare and Shrivastav, 2003). Briefly, to the warm Fehling's solution, lyophilized leaf powder was added and the mixture was heated after each addition. The production of yellow or brownish-red cuprous oxide indicates that reduction has taken place. The differences in color of the cuprous oxide precipitates under different conditions are apparently due to difference in the size of the particles, the more finely divided precipitates having a yellow color, while the coarser ones are red.

Animals and treatment

Colony bred healthy adult male albino rats (Wistar strain) weighing 200 g were utilized for experiments. All animals were proven fertility and obtained from the rat colony maintained in the department. They were housed at a temperature of $26 \pm 2^\circ\text{C}$ and exposed to 13 -14 h of daylight and maintained on a standard diet and water was given *ad libitum*. The animals were equally divided into 4 groups containing 10 rats each and treated as follows:

Group I: Oral administration of 1 mL propylene glycol/rat/ day and served as control;

Group II: Lyophilized *A. indica* leaf powder suspended in 1 mL Propylene Glycol (25 mg/kg body weight);

Group III: Lyophilized *A.indica* leaf powder suspended in 1 mL Propylene Glycol (50 mg/kg body weight); and

Group IV: Lyophilized *A. indica* leaf powder suspended in 1 mL Propylene Glycol (75 mg/kg body weight).

The lyophilized *A. indica* leaf powder was then mixed with propylene glycol as required and administered orally (gavage) to the experimental animals (WHO, 1983).The Propylene Glycol and the graded doses of lyophilized *A. indica* leaf powder were administered orally (gavage) on daily basis for 24 days. . Five animals from each group were used for fertility test. Twenty-four hours after the last dose, the control and treated animals were sacrificed by cervical dislocation. The testes were dissected out, blotted free of mucus and weighed to the nearest milligram.

Histology and Histometry

The testes were fixed in aqueous Bouin's fluid for 24 hours, washed thoroughly in 70 % alcohol, dehydrated in graded series of alcohol, cleared in benzene and embedded in paraffin wax. Section of 5 μm thickness were obtained and stained in haematoxylin (Delafield's) and eosin.

For histometrical studies, the calibrated ocular micrometer (Erma, Japan) was used. From each testis, 20 sections randomly were used in each group to record the following histometrical data:

- Number of seminiferous tubules per microscopic field.
- Diameter of seminiferous tubules.

- Number of spermatogonia, spermatocytes, spermatids, Sertoli and Leydig cells.
- Diameter of spermatogonia, spermatocytes, and spermatids.
- Nuclear diameter of spermatogonia, spermatocytes, spermatids and Leydig cells.

Fertility test

To assess the fertility rate with reference to the number of implantations, the female rats of proven fertility exhibiting regular estrous or early proestrus stage were separately housed with the control and treated males overnight. The appearance of sperm in the vaginal smear next morning confirmed the mating and is considered as day1 of the pregnancy. After 8 days, the females were laparotomized and the numbers of implantations and pups were recorded.

Statistical analysis

Data were analyzed using one way analysis of variance (ANOVA) using the Graph Pad Prism software method, followed by Dunnet test by comparing all treated groups against controls. Values represented are mean \pm SEM (n=3). $P \leq 0.05$ is considered to indicate a significant difference between experimental and controls.

RESULTS

Chemical nature

Using Fehling's test, the nature of the leaf powder was found to be carbohydrate in nature. Carbohydrates possessing a free or potentially free Aldehyde or ketone group have the property of readily reducing the ions of certain metals such as copper, bismuth, mercury, iron and silver. The most widely used tests for sugar are based on this property. For example, when blue cupric hydroxide suspended in an alkaline medium is heated, it is converted into insoluble black cupric oxide. However, in the presence of reducing agents such as certain sugars, the cupric hydroxide is reduced to insoluble yellow or red cuprous oxide. Based on the above property, the chemical nature of leaf powder was studied using Fehling's test. The production of yellow or brownish-red cuprous oxide indicated that reduction has taken place. The difference in color of cuprous oxide precipitate under different conditions was apparently due to differences in the size of the particles, the more finely divided precipitates having yellow color while the coarser ones were red. This test was found to be positive, indicating that the leaf powder is carbohydrate in nature.

Body and testis weights

The body weight of rats treated with graded doses of lyophilized *A. indica* leaf powder exhibited a slight difference, but not significant, when compared to controls (Graph.1A). However, the weight of testes in all lyophilized *A. indica* leaf powder treated animals was decreased in a dose dependent manner. A significantly decreased in the weights of testis of both 50 and 75 mg/kg body weight of lyophilized *A. indica* leaf powder treated animals ($P \leq 0.05$) when compared to controls (Graph.1B).

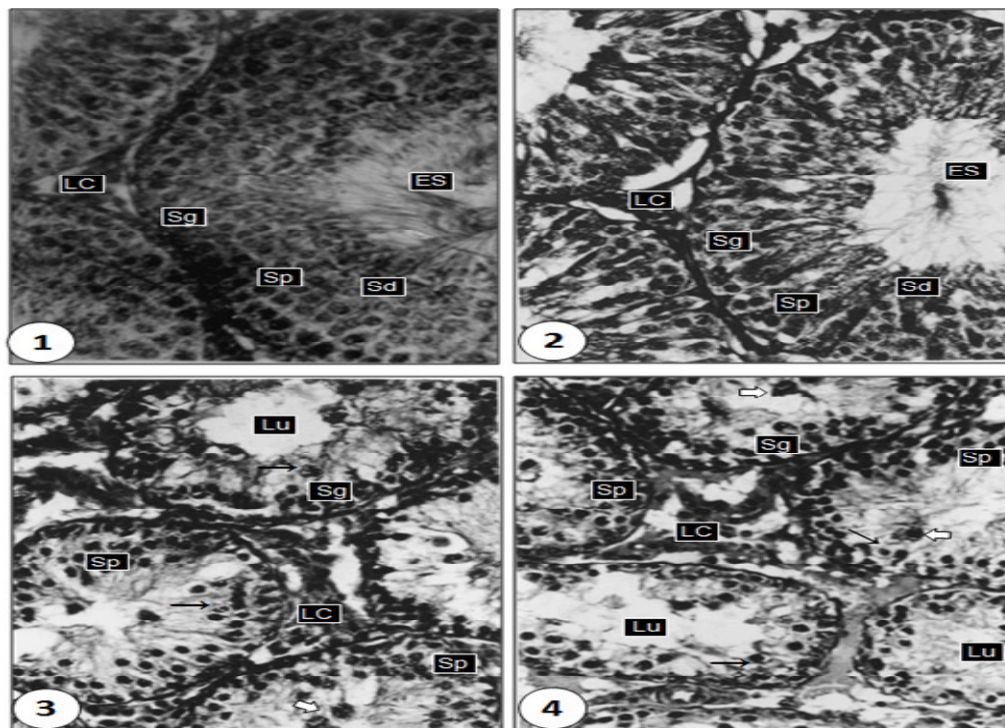
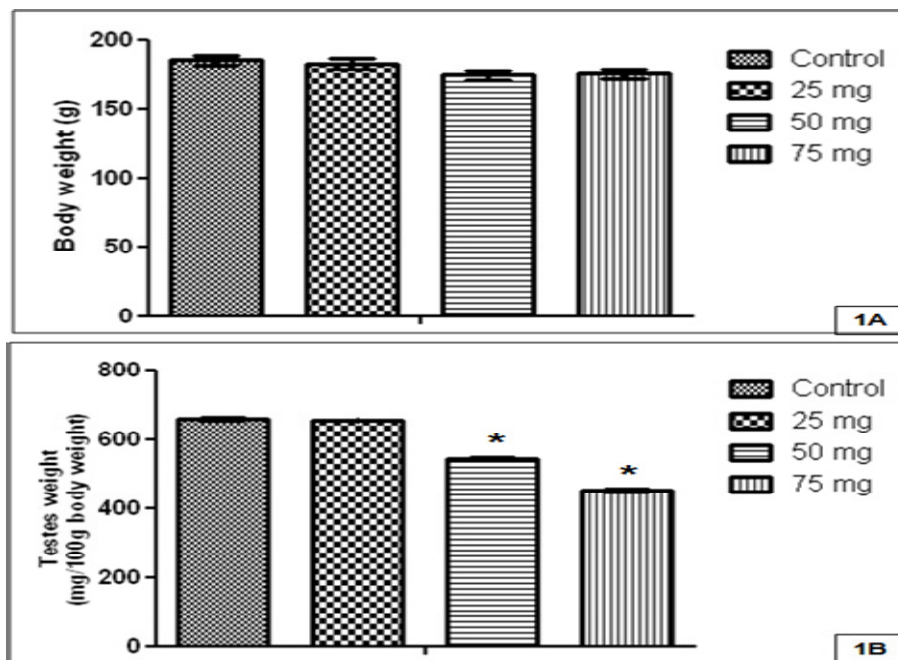
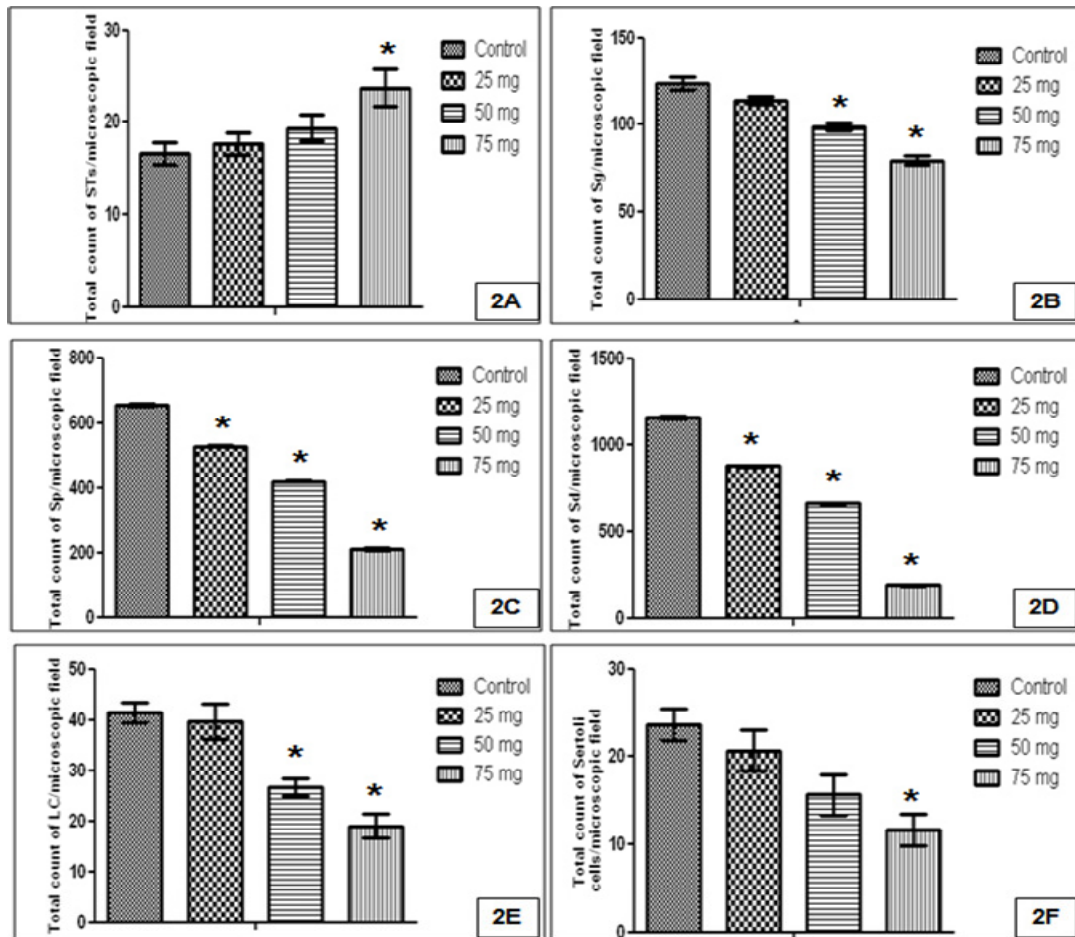


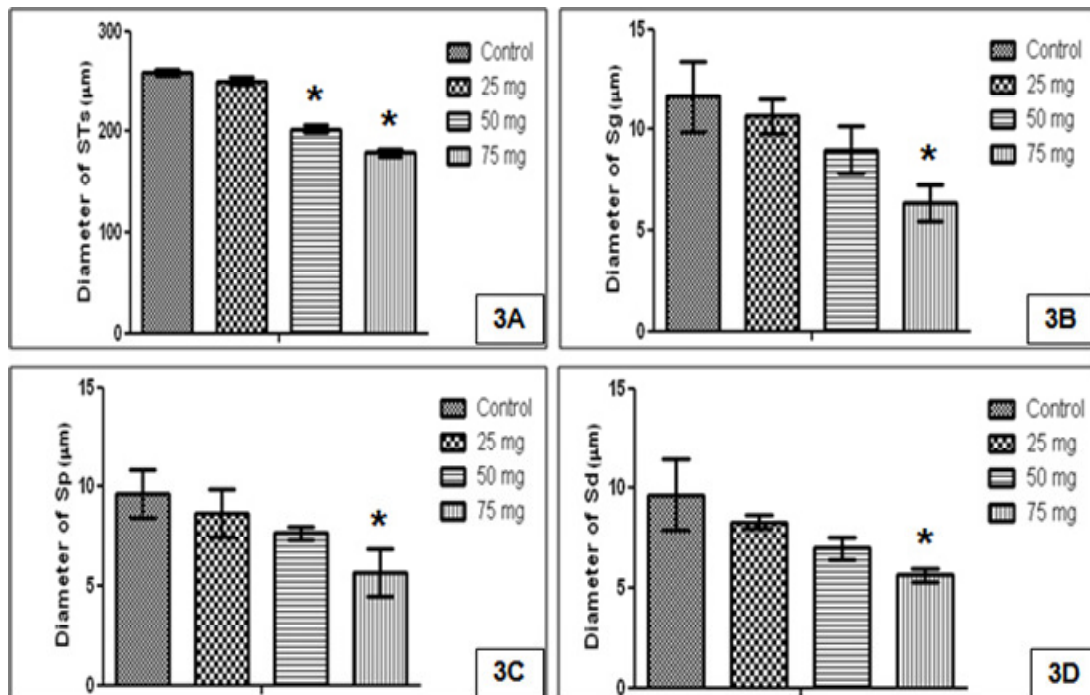
Fig 1. Section of the seminiferous tubules (STs) of control rat exhibiting normal spermatogenesis with normal features consisting of spermatogonia (Sg), spermatocytes (Sp), spermatids (Sd), elongated spermatids(ES) and interstitial elements(LC) X 400. Fig.2. STs of 25mg/kg body weight lyophilized *A.indica* leaf powder treated rat illustrate the normal appearance of spermatogenesis. STs contain many round Sds, the majority of which are correctly aligned and few ES are seen. Some of the LCs shows still atrophic with normal rounded nuclei X 400. Fig.3. STs of 50mg/kg body weight lyophilized *A.indica* leaf powder treated rat show the disruption of seminiferous epithelia and the evident of spermatogenesis stopped at the primary spermatocytes stage (arrows). Interstitial spaces increased and atrophy of LCs, which are sparsely distributed. The germ cells show overall decrease in cytoplasmic ground substance followed by vacuolation at the basal lamina and towards the lumen (LU) X 400. Fig.4. STs of 75mg/kg body weight lyophilized *A.indica* leaf powder treated rat exhibiting intraepithelial vacuoles of varying size, exfoliation and the germ cells are depleted. Degenerating Sps exhibited characteristics of vacuolization with disrupted nuclei (arrows). The vacuoles are positioned or started one cell layer away from the basal lamina towards the lumen of the tubules. The LCs shows characteristics of degeneration X 400. Note: In figures 3 and 4, there is evident of germ cells exhibiting the signs of degeneration and aggregate to form giant cells (hallow arrows).



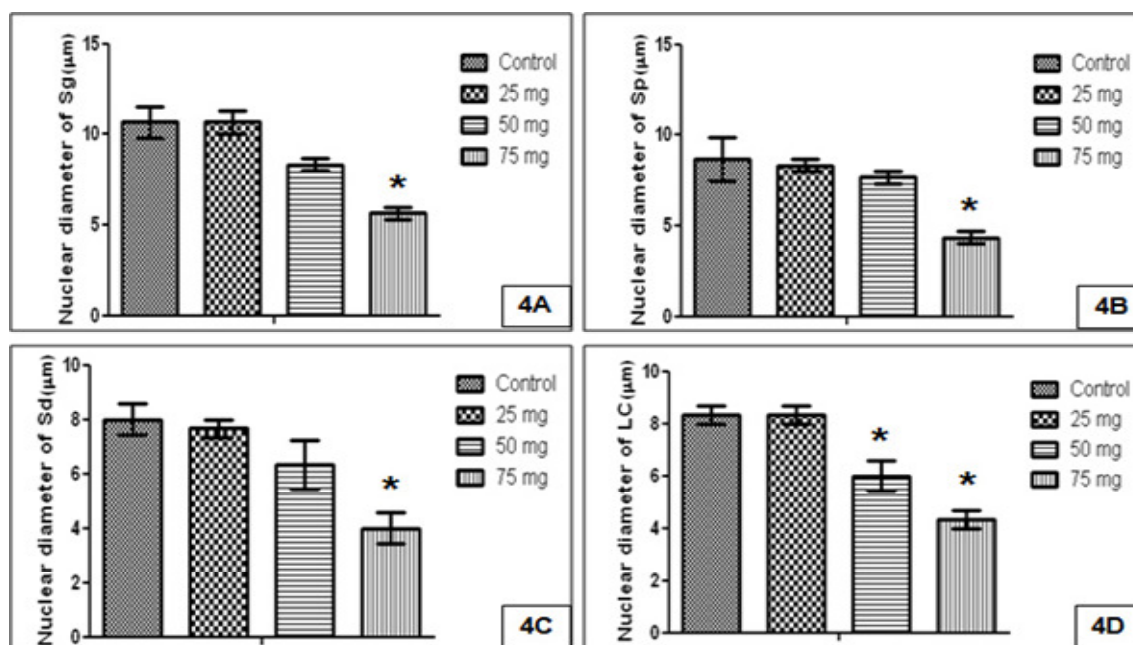
Graphs.1A&B. Dose dependent administration of lyophilized *A.indica* leaf powder in 1 mL propylene glycol/rat/day on body weight (1A) and testis weight (1B) respectively for period of 24 days. Values are mean ± SEM (n=10) and * indicates significant ($P \leq 0.05$) compared to control.



Graphs.2A-F. Dose dependent administration of lyophilized *A.indica* leaf powder in 1 mL propylene glycol/rat/day on total count of seminiferous tubules (2A), spermatogonia (2B), spermatocytes (2C), spermatids (2D), Leydig cells (2E) and Sertoli cells (2F) respectively for period of 24 days. Values are mean ± SEM (n = 10) and * indicates significant (P ≤ 0.05) compared to control.



Graphs.3A-D. Dose dependent administration of lyophilized *A.indica* leaf powder in 1 mL propylene glycol/rat/day on diameter of seminiferous tubules (3A), spermatogonia (3B), spermatocytes (3C) and spermatids (3D) respectively for period of 24 days. Values are mean ± SEM (n = 10) and * indicates significant (P ≤ 0.05) compared to control.



Graphs.4A-D. Dose dependent administration of lyophilized *A.indica* leaf powder in 1 mL propylene glycol/rat/day on nuclear diameter of spermatogonia (4A), spermatocytes (4B), spermatids (4C) and Leydig cells (4D) respectively for period of 24 days. Values are mean \pm SEM (n = 10) and * indicates significant ($P \leq 0.05$) compared to control.

Table 1. Dose dependent administration of lyophilized *A.indica* leaf powder in 1 mL propylene glycol/rat/day on the implantations, number of pups and their body weight of female rats mated with treated male rats (Values are expressed in SEM of 5 animals)

Group & Treatment	Number of implantations	Number of Pups	Body weight (gm)	
			1 day	1 Week
I (1 mL Propylene Glycol/rat)	8.20 \pm 0.80	8.00 \pm 0.78	5.73 \pm 0.08	9.66 \pm 0.04
II 25 mg in 1 mL Propylene Glycol / kg body weight	7.20 \pm 0.86	6.80 \pm 0.66	5.72 \pm 0.03	9.67 \pm 0.04

Histological changes

The testis of control rats exhibited different stages in seminiferous elements comprising of germ cells, Sertoli cells and interstitial cells which are normal in their appearance. Towards the lumen, the primary spermatocytes, secondary spermatocytes, early spermatids and elongated spermatids were associated with Sertoli cells. Towards the lumen, arrangement of mature spermatozoa could be observed (Fig. 1). Morphometric data is presented in Graphs.2-4.

In 25 mg/kg body weight of lyophilized *A. indica* leaf powder treated animals, a partial effect was observed in the process of spermatogenesis. The shrinkage of the seminiferous tubule was conspicuous and the tunica propria and the overall vascularity were normal. In some tubules the spermatogenic process was with all the cellular stages and the lumen was filled with sperms, but in others the spermatogenic process was advanced only upto primary spermatocytes stage and the Leydig cells were still atrophic (Fig.2). Histological examination of the testes revealed insignificant effect on spermatogenesis or tubules and appears qualitatively normal. The number of seminiferous tubules per microscopic field (Graph.2A) and the diameter of the seminiferous tubules (Graph.3A) did not show variation. The total count of the spermatogonia, Leydig cells and Sertoli cells did not much show variation from the control rats (Graphs.2B, 2E and 2F). However, the total count of spermatocytes

(527.3 \pm 2.60) and spermatids (879.3 \pm 3.75) was significantly ($P \leq 0.05$) decreased (Graphs.2C and 2D). Rest of the parameters like, diameter and nuclear diameter of spermatogonia, spermatocytes, spermatids and Leydig cells were similar to the control animals [Graphs.3 (A-D) and 4 (A-D)].

However, the animals fed with higher doses of lyophilized *A. indica* leaf powder 50 and 75 mg/kg body weight showed atrophic tubules and it is evident that spermatogenesis was very much suppressed, arrested in majority of the tubules. The tunica propria was disintegrated. Basement membrane was thin and disrupted. In about 80 percent of the tubules, spermatogenesis was arrested either at the primary spermatocytes or the spermatogonial stages. In some tubules, complete cytolysis of the entire spermatogenic elements was seen and in some, the spermatogenesis advanced only upto the formation of primary spermatocytes and arrested thereafter. The Sertoli cells showed vacuolization and cell debris due to cytolysis. The spermatogenesis did not advance beyond pachytene spermatocytes and few of these cells exhibited signs of degeneration and aggregate to form giant cells. The intercellular spacing became wider, Leydig cells were reduced in number or the interstitium contains mostly fibroblasts, only occasional Leydig cells were discernible. There was preponderance of fibroblasts like elements over the Leydig cells with shrunken nuclei (Fig.3 and 4). There was significant ($P \leq 0.05$) increase in the seminiferous tubules

per microscopic field (Graph.2A) and decrease in the diameter of seminiferous tubules (Graph.3A). The total count of spermatogonia, spermatocytes, spermatids, Leydig cells and Sertoli cells was significantly ($P \leq 0.05$) decreased (Graphs.2B-F). Also, there was significant decrease in the diameter and their nuclear diameter of germ cells and Leydig cells [Graphs.3 (A-D) and 4 (A-D)].

Fertility test

Results of fertility performance test (Table.1) showed that female rats mated with control male rats illustrated that the numbers of implantations were 8.20 ± 0.80 on day 8 of pregnancy. Number of pups obtained 8.00 ± 60.78 and the body weight of one day old pup was 5.73 ± 0.08 gm and those of one week old were 9.66 ± 0.04 gm. Graded doses of lyophilized *A.indica* leaf powder were used to achieve the fertility inhibition. With a dose of 25 mg lyophilized *A.indica* leaf powder in 1 ml Propylene Glycol / kg body weight treated animals, there is no difference in numbers of implantations and number of pups (7.20 ± 0.86 and 6.80 ± 0.66 respectively) when compared to controls. However, the remaining groups of 50 and 75 mg lyophilized *A.indica* leaf powder treated animals, no implantations were observed and indicating 100 % fertility inhibition.

DISCUSSION

Androgen is essential for most of the stages of spermatogenesis, meiosis in particular. Sperm production cannot proceed optimally to completion, without a continuous androgen supply. Interference of testosterone production leads to atrophy of the organ and impairment of spermatogenesis (Mann and Lutwak-Mann, 1981). It has been reported that reducing testicular weight and maturational arrest of the primary spermatocytes manifest androgen deficiency (Samuel et al., 1967). It has been reported that reducing testicular weight and maturational arrest of the primary spermatocytes manifest androgen deficiency (Saito et al., 2000). The morphometric analysis confirms the adverse effect on the spermatocytes, spermatids and Leydig cells. The degeneration of Leydig cells reflects the depletion of androgen levels and absence of germinal cells i.e., spermatocytes, spermatids and support the observations/ hypothesis/view, since these stages are completely androgen dependent (Beardsley and O'Donnell, 2003). Most of the plants product affecting aspects of male reproduction brings about the effects through either of two mechanisms namely, estrogenic effect or antiandrogenic effect (Kasinathan et al., 1972) and these studies indicated that the absence of the Leydig cells may have also resulted in decreased synthesis and release of other androgens especially testosterone, due to suppressed levels of gonadotropins.

In the present study the antispermatogenic activity of lyophilized leaf powder *A.indica* is reflected in the arrest of spermatogenesis. The adverse effect of leaf powder on the rat testis including tubular atrophy, along with the abnormal histological appearance of the seminiferous epithelium and the Leydig cells are may be due to curtailing of androgen supply within the testis or it may be a direct effect of this plant extract on the tissue. A significant reduction in weight of the testes due to treatment of *A. indica* leaves suggests the dwindling of androgen status or provides an indirect evidence for the antiandrogenic action of the plant. In addition, the regression and degenerative changes in the seminiferous tubules, significantly decreased number of Leydig cells and their nuclear diameter in the present study reflect the depletion of androgen level.

It is supported by decreased number of germinal cells i.e., spermatocytes and spermatids since these changes are completely androgen dependent (Dym et al., 1979; Brooks, 1981). Similar observations related to the unique nature of changes in the seminiferous tubule treated with different parts of plant extracts have been assayed so far, in the perspective of male antifertility. To quote a few, *Carica papaya* (Udoh et al., 2005), *Dendrophthoe falcata* (Gupta and Kachhawa, 2007), *Mucuna Urens* (Etta et al., 2009), *Adiantum lunulatum* (Bhatia et al., 2010), *Ocimum sanctum* (Aladakatti et al., 2010) and *Moringa oleifera* (Paul and Didia, 2012) have been studied in this category.

The occurrence of multinucleate giant cells towards the lumen due to the action of lyophilized *A.indica* leaf powder may suggest that during mitosis of the spermatogonia and meiosis of the spermatocytes, subsequent to division of the nucleus the cells fail to undergo cytokinesis. The multinucleate giant cells produced are consistent with the multinucleated giant cell formation generated by andrographolide (Akbarsha and Murugaian, 2000); triptolide (Sinha Hikim et al., 2000); leaf extract of *Calotropis procera* (Akinloye et al., 2002); and benzene extract of *Ocimum sanctum* leaves (Aladakatti et al., 2010). These studies suggested that the treatment induced Symplasts at stages I and II resulting in several nuclei and action at stages V–VII resulting in fewer nuclei. In the present study, we do not know that the nuclei in the multinucleate masses due to the action of lyophilized *A.indica* leaf powder at stages I and II or V–VII. The stage-specific nature of this lyophilized *A.indica* leaf powder in inducing symplast formation deserves further investigation.

In the present study, along with some degenerating spermatocytes and round spermatids, the development of vacuoles occurred in the tubules at or above the position of the Sertoli cell cytoplasm or towards the lumen. To support for this observation has been provided by studies described the similar vacuoles in Triptolide, (Sinha Hikim et al., 2000) ; crude extract *A.indica* leaves (Aladakatti and Nazeer Ahamed, 2006) ; benzene extract of *Ocimum sanctum* leaves (Aladakatti et al., 2010); and ethanol extract of *Adiantum lunulatum* decoction (Bhatia et al., 2010) treated rats. It is not known if vacuole formation occurs as a direct consequence of germ cell necrosis or is a non specific response of the Sertoli cells to androgen deprivation (Kerr et al., 1993). The concurrent appearance of numerous smaller vacuoles represents a morphological indicator of Sertoli cell damage (Sharpe et al., 1990; Ghosh et al., 1991). Further studies are required to identify the exact sites and reasons for vacuole formation in spermatogenesis. Fertility study exhibits a decrease in the number female rats impregnated by males receiving the leaf powder treatment was demonstrated by a decrease in the implantation sites and number of litters born by the female rats cohabited with the leaf powder treated male rats leading to reduced fertility probably due to the destructive activity of the leaf powder on the testicular tissue and accessory organs rendering the deprived androgen and thereby establishing the antifertility property of the plant studied.

REFERENCES

- [1] Akbarsha, M. A., Murugaian, P. 2000. Aspects of the Male Reproductive Toxicity/Male Antifertility Property of Andrographolide in Albino Rats: Effect on the Testis and the Cauda Epididymidal Spermatozoa. *Phytother. Res.* 14, 432–435.

- [2] Akinloye, A.K., Abatan, M.O., Alaka, O.O., Oke, B.O. 2002. Histomorphometric and histopathological studies on the effect of *Calotropis procera* (Giant milkweed) on the male reproductive organs of wistar rats. *Afr. J. Biomed. Res.* 5, 57–61.
- [3] Aladakatti, R.H., Ghodesawar, M.G., Mukhtar Ahmed., Sannadurgappa, D. 2010. Effect of lyophilized *Azadirachta indica* leaf powder on biochemical parameters of testis and epididymis in albino rats. *Int. J. Biol. Chem. Sci.* 6, 75–87.
- [4] Aladakatti, R.H., Nazeer Ahamed, R. 2005a. Changes in Sertoli cells induced by *Azadirachta indica* A.Juss leaves in albino rats. *J. Basic. Clin. Physiol. Pharmacol.* 16, 67–80.
- [5] Aladakatti, R.H., Nazeer Ahamed, R. 2005b. Ultrastructural changes in Leydig cell and cauda epididymal spermatozoa induced by *Azadirachta indica* leaves in albino rats. *Phytother. Res.* 19, 756–766.
- [6] Aladakatti, R.H., Nazeer Ahamed, R. 2006. *Azadirachta indica* A.Juss induced changes in spermatogenic pattern in albino rats. *J. Nat. Remed.* 6, 62–72
- [7] Beardsley, A., O'Donnell, L. 2003. Characterization of normal spermiation and spermiation failure induced by hormone suppression in adult rats. *Biol. Reprod.* 68, 1299–1307.
- [8] Bhakuni, D.S., Goel, A.K., Sudha, T., Mehrotra, B.N., Simal, R.C. 1990. Screening of Indian plants for biological activity. Part XIV. *Indian J Exp Biol.* 28, 619–637.
- [9] Bhargava, S.K. 1988. Antifertility agents from plants. *Fitoterapia.* 59, 163–167.
- [10] Bhatia, D.K., Sharma, A.K., Pathania, P.C., Khanduri, N.C. 2010. Antifertility effects of crude different of *Adiantum lunulatum* Burm. On Reproductive Organs of male albino rats. *Biological Forum- An Int. J.* 2, 88–93.
- [11] Borchers, A.T., Hackman, R.M., Keen, C.L., Stern, J.S., Gershwin, M.E. 1997. Complementary medicine 1-3: a review of immunomodulatory effects of Chinese herbal medicines. *Am. J. Clin. Nutr.* 66, 1303–1312.
- [12] Brooks, D.E. 1981. Secretion of proteins and glycoproteins by the rat epididymis: Regional differences, androgen-dependence, and effects of protease inhibitors, procaine, and huicarnycin. *Biol Reprod.* 25, 1099–1117.
- [13] Dym, M., Madhwa Raj, H.G., Lin, Y.C., Chemes, H.E., Kotite, N.J., Nayteh, S.N., French, F.S. 1979. Is FSH required for maintenance of spermatogenesis in adult rats. *J. Reprod. Fertil. Suppl.* 26, 175–181.
- [14] Farnsworth, N.R., Bingel, A.S., Cordell, G.A., Crane, F.A., Fong, H.H.S. 1975. Potential value of plants as source of new antifertility agents. *J Pharm Sci.* 64, 535–549.
- [15] Ghosh, S., Sinha Hikim, A.P., Russell, L.D. 1991. Further observations of stage specific effects seen after short-term hypophysectomy in the rat. *Tissue. Cell.* 23, 613–630.
- [16] Gupta, R.S., Kachhawa, J.B.S. 2007. Evaluation of contraceptive activity of methanol extract of *Dendrophthoe falcata* stem in male albino rats. *J. Ethnopharmacol.* 112, 215–218.
- [17] Etta, H.E., Bassey, U.P., Eneobong, E.E., Okon. O, B. 2009. Anti-spermatogenic effects of ethanol extract of *Mucuna Urens*. *J.Reprod. Contraception.* 20, 161–168.
- [18] Hawk, P.B. 1965. Hawk's physiological chemistry. New York: McGraw-Hill Book Company, p. 83–1322.
- [19] Kashinathan, S., Ramakrishna, S., Basu, S.L. 1972. Antifertility effect of *Ocimum sanctum*. *Indian J. Exp. Biol.* 10, 23–25.
- [20] Kerr, J.B., Millar, M., Maddocks, S., Sharpe, R.M. 1993. Stage-dependent changes in spermatogenesis and Sertoli cells in relation to the onset of spermatogenic failure following withdrawal of testosterone. *Anat. Rec.* 235, 547–559.
- [21] Khillare, B., Shrivastv, T.G. 2003. Spermicidal activity of *Azadirachta indica* (neem) leaf extract. *Contraception.* 68, 225–229
- [22] Kumbar, S.B., Jadaramkunti, U.C., Aladakatti, R.H. 2012a. In vitro spermicidal efficacy of nimbolide, an isoprenoid of neem leaf, in albino rats. *J. Phytother. Pharmacol.* 1, 1–13.
- [23] Kumbar, S.B., Jadaramkunti, U.C., Aladakatti, R.H. 2012b. In vitro effect of nimbolide, an isoprenoid of neem leaf, on antioxidant system of rat cauda epididymal spermatozoa: A dose dependent study. *J. Appl. Pharm. Sci.* 2, 84–93.
- [24] Mann, T., Lutwak - Mann, C. 1981. Male reproductive function and Semen. Springer, Berlin Heidelberg, New York. pp.139–144
- [25] Paul C.W., Didia. B.C. 2012. Methanolic Extract of *Moringa oleifera* Lam Roots is Not Testis-Friendly to Guinea Pigs. *Asian. J. Med. Sci.* 4, 47–54.
- [26] Saito, K., O'Donnell, L., McLachlan, R.I., Robertson, D.M. 2000. Spermiation failure is a major contributor to early spermatogenic suppression caused by hormone withdrawal in adult rats. *Endocrinol.* 141, 2779– 2785.
- [27] Samuels, L. T., Uchikawa, T., Huseby, R. A. 1967. Direct and Indirect Effects of Oestrogens on the Enzymes of the Testis. *Ciba Found. Colloq. Endocrinol.* 16, 211–228.
- [28] Sharpe, R.M., Maddocks, S., Kerr, J.B. 1990. Cell-cell interactions in the control of spermatogenesis using Leydig cell destruction and testosterone replacement. *Am. J. Anat.* 188, 3–20.
- [29] Sinha Hikim, A.P., Lue, Y.H., Wang, C., Reutrakul, V., Sangsuwan, R., Swerdloff, R.S. 2000. Post-testicular antifertility action of triptolide in the male rat: evidence for severe impairment of cauda epididymal sperm ultrastructure. *J Androl.* 21, 431–437.
- [30] Udoh, P., Essien, I., Udoh, F. 2005. Effects of *Carica papaya* (paw) seeds extract on the morphology of pituitary-gonadal axis of male Wistar rats. *Phytother. Res.* 19, 1065–1068.
- [31] WHO Protocol, LG-06 1983. Extraction and fractionation for biological and phytochemical studies. *A.P.J.F.I.P, A*, pp 1001–1083.