

Recent Research in Science and Technology 2011, 3(12): 53-57
 ISSN: 2076-5061
 Available Online: <http://recent-science.com/>



Van der woude syndrome- a case report

Shamimul Hasan and Nabeel Ishrat Khan*

Department of Oral Medicine and Radiology, Z. A. Dental College and Hospitals A. M. U., Aligarh-202002, India.

Abstract

Van der Woude syndrome (VWS) is a rare, autosomal dominant disorder, caused by deletions in the chromosome band 1q32-q41, and characterized by cleft lip or cleft palate, distinctive pits of the lower lips, or both. The most prominent and consistent features of Van der Woude syndrome are oro-facial defects. The oro-facial abnormalities include lower lip pits alone, hypodontia, or isolated cleft lip and cleft palate of varying severity. A case of Van der Woude syndrome, with the typical manifestations in a seven year old male patient is being presented, along with its review of literature.

Keywords: Van der Woude syndrome, Cleft lip and palate, Congenital lip pits, Hypodontia.

INTRODUCTION

Van der Woude syndrome is a rare developmental, congenital malformation with autosomal dominant inheritance, high penetrance, and variable expressivity [1]. The pathologic entity was first delineated by Demarquay [2] but was originally reported by Van der Woude [3]. The distinctive feature of VWS is the presence of lower lip pits and/or sinuses, which are present in approximately 85% of cases. In some rare cases, a single barely visible pit might be the only distinguishable feature of VWS. Other anomalies that are frequently associated with VWS include hypodontia, submucous cleft palate (CP) and bifid uvula [4]. Manifestations of the syndrome in other than the oral or facial areas are unusual. More extreme phenotypes in parents tend to produce more extreme expression in their children [5], however, the lesser expressions of VWS are common and should be actively looked for when counseling families about cleft lip or cleft lip and palate [6]. With these considerations in mind, all patients should be informed of the 50% inheritance of this disorder. The potential of embryoscopy to detect minor malformations such as cleft lip allows for early termination of pregnancy in patients with VWS [7]. Surgical repair includes reconstruction of the cleft lip and/or palate, sinus excision, and plasty of the lower lip [8-10]. Lip pits may be surgically excised if repeated infections become problematic or for cosmetic reasons [11].

CASE REPORT

A 7 Year old boy was referred to the Department of Oral Medicine and Radiology with the complaint of unaesthetic appearance of the lower lips. His parents told that when the child was born they noticed deformity of the upper lip and depressions in the lower lip. Past surgical history revealed that the patient had undergone surgical correction of the upper cleft lip at the age of 18 months. The family history did not reveal consanguineous marriage of his parents and was negative for lip pits, clefts, and other congenital anomalies. The patient had two siblings, one brother and one sister, and both were apparently healthy. According to his mother, the patient was born after an uneventful, full term pregnancy with no radiation exposure. The patient had a nasal twang. General physical examination of the patient was non-contributory. Extraoral examination revealed surgical scar mark of the operated upper cleft lip, and bilateral paramedian pits, symmetrically seen on either side of the midline on the lower lip (Fig. 1). Lip pits were completely asymptomatic and there was no discharge or secretions. While intraoral soft tissue examination revealed bilateral cleft palate extending from pre-maxilla to soft palate (Fig. 2).

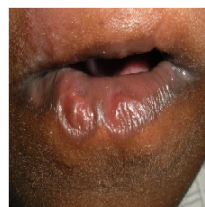
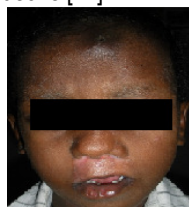

Fig1. Extraoral examination showed surgical scar mark of the operated upper cleft lip, and bilateral paramedian pits on the lower lip.

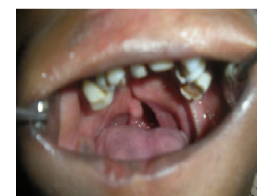
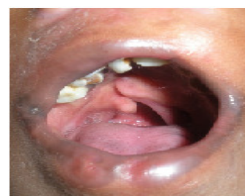
Fig 2. Intraoral soft tissue examination showed bilateral cleft palate extending from pre-maxilla to soft palate.

Received: Oct 15, 2011; Revised: Nov 02, 2011; Accepted: Nov 22, 2011.

*Corresponding Author

Ishrat Khan
 Department of Oral Medicine and Radiology, Z. A. Dental College and Hospitals
 A. M. U., Aligarh-202002, India.

Tel: 09953290676
 Email: nabcool@gmail.com

Dental examination revealed mixed dentition, malaligned teeth and missing deciduous right maxillary central incisor and deciduous left maxillary central and lateral incisor teeth. Orthopantomogram (OPG) revealed bilateral maxillary cleft and missing maxillary permanent right and left central incisors teeth and mandibular permanent second premolar teeth. (Fig. 3). As the defects were present at the time of the birth it is a congenital defect. The defect was associated with congenital lip pits, cleft palate, operated cleft lip, and hypodontia, a provisional diagnosis of Van Der Woude syndrome **was** made. The patient was referred to the department of oral and maxillofacial surgery for correction of lower lip defects and cleft palate.

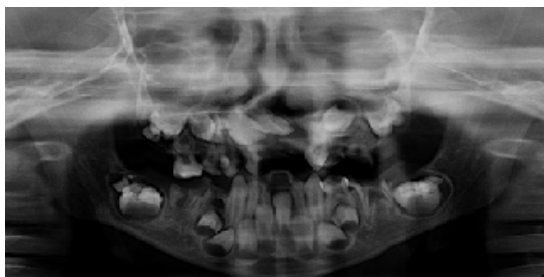

Fig 3. OPG revealed bilateral maxillary cleft and missing maxillary permanent right and left central incisors teeth and mandibular permanent second premolar teeth.

DISCUSSION

Congenital lower lip sinuses have been reported in about 0.001% of the population, and 65% to 75% of the cases are associated with cleft lip and palate [5,12]. Congenital pits of the lower lip in association with clefting of the lip or palate or both occur in many syndromes [13]. Van der Woude was the first to combine lower lip pits with cleft lip and / or cleft palate, introducing a new clinical entity, while she also described its mode of heredity [14]. The prevalence of VWS is estimated between 1:40,000 and 1:100,000, which probably results from the registration of children treated in different centers rather than epidemiological studies [1]. Numerous authors [15-17] have carried out extensive reviews and analyses of published cases. The most complete survey is that of Burdick et al [5].

In 1987 Bocian et al. reported a patient with lip pits and a deletion in 1q32-q41, and subsequently Murray et al. found linkage between VWS and markers from the same region [18,19]. Microdeletions in 1q32-q41 have also been reported in families with VWS [20,21]. However, chromosome 1p34 was mapped as the second locus for the Van der Woude Syndrome [22]. Recently, mutations have been found in the interferon regulating factor 6 gene in patients with VWS and popliteal pterygium syndrome [23]. However, the lack of 100% concordance in monozygotic twins suggests that genetic events alone are not responsible for the clefting phenotype. The process of monozygotic twinning is in a sense a teratogenic event, and monozygotic twins have an increased incidence of (often discordant) structured malformations [24].

Clinical features

Oral manifestations

1. Lip Pits: Usually bilateral, often symmetrically placed

depressions are observed on the vermilion portion of the lower lip, one on each side of the midline. The dimples are usually circular but they may be transverse slits or sulci [25]. Most of the lip pits are located in the lip vermilion and on the muco-cutaneous line at a distance of about 5-25 mm from each other [26]. On occasion, they may be located at the apex of nipple-like elevation [27]. Rarely, the elevations may fuse in the midline, producing a snout like structure. The depressions represent blind sinuses that descend through the orbicularis oris muscle to a depth of 1mm to 2.5 cm and communicate with the underlying minor salivary glands through their excretory ducts. Although usually bilateral and symmetrically placed, an asymmetric single pit [28-30], a central single pit [29,31], or bilateral asymmetric pits [31] may occur. The appearance of the pits may be remarkably subtle [6]. Microforms exist such as transverse mucosal ridges of the lower lip and bilateral somewhat conical elevations of the lower lip mucosa [25]. The latter are associated with cleft palate but not with cleft lip [32]. Such microforms of VWS can be detected only by careful examination of the patient and by the coexistence of a cleft and family history. [25] The presence of a sinus is directly related to the severity of the cleft lip, palate, or both [33]. Lower lip pits are usually asymptomatic [34]. The only symptom might be the continuous or intermittent drainage of water or salivary secretions [35]. The mucous accumulation occurs more rapidly before and during mealtimes, or in relation to crying, when infants are concerned [26]. Fistulae represent failure of closure of evanescent sulci that appear at 10-14th month of embryonic period [36]. The most logical explanations are the two proposed by Wang and Mc Comber [29]. The anomaly is attributable to a defective gene which would explain the familial appearance and the frequent association with cleft lip, cleft palate (or both) or the anomaly is the result of retardation or inhibition of a certain phase in the normal development of embryonic lower lip, hence the constancy of location [37].

2. Cleft Lip/Palate: Orofacial clefts including cleft lip and cleft palate (CL/P) are a major structural birth defect with the worldwide incidence roughly 1 in 500-1000 births [38,39]. More than 400 syndromes include cleft lip (CL) with or without cleft palate (CP) in their etiology. Van der Woude syndrome (VWS) is one of the most common accounting for about 2% of all cases of CL/P worldwide [25]. Immediately after birth, individuals with CL/P have facial deformation, feeding problems, and frequent middle ear infection, the treatments of which require interventions from multiple disciplines. At the age of speech acquisition, speech therapy is often needed to correct problems resulting from muscular defects of the cleft. As the individual continues to grow, defects in tooth development and malocclusion require dental and sometimes surgical treatment. Clinically, when CL/P appears with other (usually two or more) malformations in recognisable patterns, it is classified as syndromic CL/P (SCL/P). If it appears as an isolated defect or if syndromes cannot be identified, the term non-syndromic CL/P (NSCL/P) is used [40]. The distinction between NSCL/P and SCL/P, however, is sometimes not clear-cut. In families with SCL/P, some affected members may present with only CL/P, because of variable expression of the syndrome. On the other hand, more than 20% of patients with NSCL/P were found to have associated congenital malformations in one study [41].

3. Hypodontia: Hypodontia is considered as a cardinal associated feature and has been observed in 10-81% of all VWS patients [25], with the number of teeth missing in the upper jaw almost double that in corresponding control groups. The teeth

missing in sequence of frequency are the upper second premolars, the lower second premolars, and the upper lateral incisors.

4. Submucous Cleft Palate: It is common and may be easily missed on physical examination. Hypernasal voice and cleft or bifid uvula are clues to this diagnosis. It is possible as well that a bifid uvula is an isolated finding in certain individuals with the Van der Woude syndrome [42]. Infrequent anomalies include congenital adhesion of the jaw (syngnathia), narrow arched palate and ankyloglossia (tongue tie) [42].

Extra-oral manifestations

The reported incidences of extraoral manifestations are rare but include limb anomalies, popliteal webs, and brain abnormalities. Accessory nipples, congenital heart defects, and Hirschsprung disease have also been reported. It is uncertain whether these extraoral manifestations unassociated additional anomalies or infrequently expressed aspects of Van der Woude syndrome [42].

The patient in our case exhibited a peculiar combination of all traits associated with Van der Woude syndrome, i.e bilateral lower lip pits, cleft palate, operated cleft of the upper lip and multiple missing teeth.

Diagnosis

Because of variable expressivity, affected family members may exhibit clefts without pits. This may greatly complicate genetic counseling as the chances for transmitting cleft lip or palate vary depending on whether the anomaly is associated with lip pits (50%) or is an isolated phenomenon (2%–5%) [7]. Genetic counseling is critical for the diagnosis of VWS [43]. All affected parents should be cautioned that they carry a risk of 50% for each child with a cleft lip or palate or both [34]. Prenatal diagnosis has been made using embryoscopy [7].

Differential diagnosis

1. Popliteal Pterygium Syndrome: Popliteal pterygium syndrome is a rare, autosomal dominant anomaly with a variety of manifestations, including lower lip sinuses, popliteal webbing, cleft lip, cleft palate, syndactyly, and genital and nail anomalies [44].

2. Orofaciodigital Syndrome- Type 1: Orofaciodigital syndrome is another disorder including lower lip sinuses, clefts of the jaw and tongue in the areas of the lateral incisors and canines, malformations of the face and skull, and mental retardation [44].

3. Aganglionic megacolon combined with CP and lip pits (Hirschsprung disease) [34].

4. Ankyloblepharon filiform adnatum [27].

Treatment

Several methods have been described for treatment of VWS. The clefts are treated like an isolated cleft lip or palate [45], the sinuses of the lower lip should be excised to correct the deformity and to prevent possible infections. Electrocoagulation techniques and marsupialization of the sinuses into the oral cavity have been discontinued because of high complication rates and poor results [13]. The simple excision of the sinuses and adjacent glands that empty into the sinuses is the most commonly accepted procedure [10-13]. Several authors emphasized that simple excision had

inferior results, such as lower lip muscle loosening and whistling deformity [10]. Another surgical approach that has attempted to achieve radical excision of the dysplastic tissue and repair of lip muscles to restore good lip functionality and bilabial symmetry is the split-lip advancement technique. In this technique, two opposite labial artery-based flaps, including the whole thickness of the vermilion and the mucosal surface of the lip, are used to repair the median defect that results from excision of the sinuses [46].

CONCLUSION

The identification of previously identified and novel mutations in IRF6 is useful information for genetic counseling of families affected by VWS. The known mutations highlight the importance of these amino acid residues for IRF6 function and identify two other residues as potential mutational hotspots, whereas the novel mutations add to the current repertoire of mutations in IRF6 [47].

REFERENCES

- [1] Rizos, M. and M. N. Spyropoulos. 2004. Van der Woude syndrome: a review. cardinal signs, epidemiology, associated features, differential diagnosis, expressivity, genetic counseling and treatment. *Eur. J. Orthod.* 26:17–24.
- [2] Demarquay, J. N. 1845. Quelques considerations sur le bec-deliévre. *Gaz Me'd Paris.* 13:52-53.
- [3] Van der Woude, A. 1954. Fistula labii inferioris congenita and its association with cleft lip and palate. *Am J Hum Genet*;6: 244–256
- [4] Ghassibe M., N. Revencu, B. M. Bayet, Y. Gillerot, R. Vanwijck, C. Verellen-Dumoulin and M. Vikkula. 2004. Six families with Van der Woude and/or popliteal pterygium syndrome: all with a mutation in the IRF6 gene. *J Med. Genet.* 41:e15.
- [5] Burdick, A. B., D. Bixler and C. L. Puckett. 1985. Genetic analysis in families with Van der Woude syndrome. *J. Craniofac Genet Dev Biol Suppl.* 5:181–208.
- [6] Menko, F. H., P. H. Koedijk, J. A. Baart and M. L. Kwee. 1988. Van der Woude syndrome recognition of lesser expressions: case report. *Cleft Palate J.* 25:318–321.
- [7] Dommergues, M., M. Lemerrer, G. Couly, A. L. Delezoide and Y. Dumez. 1995. Prenatal diagnosis of cleft lip at 11 menstrual weeks using embryoscopy in the Van der Woude syndrome. *Prenat Diagn.* 15:378–381.
- [8] Gawrych, E. and K. Jamroszczyk. 2004. Familial occurrence of Van der Woude syndrome – a case report. *Pediatr Pol.* 79:327–329.
- [9] Kruk-Jeromin, J. and M. Żurawska-Klepacz. 2000. Lower lip sinus with cleft lip and/or palate. Van der Woude syndrome. *Czas Stomatol.* 53:289–294.
- [10] Capon-Degardin, N., V. Martinot-Duquennoy and P. Auvray G, Pellerin. 2003. Lower lip repair in Van der Woude syndrome. *Eur. J. Ped. Surg.* 13:92–96.
- [11] Eisen and D. P. Lynch. 1998. Developmental disorders. In:

- Eisen D and Lynch DP (Eds.), The mouth: diagnosis and treatment, *St Louis: Mosby*, pp. 52-53.
- [12] Sumitomo, S., S. Ogawa, K. Hirai and Y. Takai, 2002. Congenital sinus of the upper lip with idiopathic precocious puberty. *Oral Diseases*. 8:308-309.
- [13] Guner, U., N. Çelik, C. Özek, et al. 2002. Van der Woude Syndrome. *Scand. J. Plast. Reconst. Surg. Hand. Surg.* 36:103-105.
- [14] Schutte, B. C., A. Sander, M. Malik and J. C. Murray. 1996. Refinement of the Van Der Woude gene location and construction of a 3.5 Mb YAC contig and STP map spanning the critical region in 1q32-q41. *Genomics*. 36:507-14.
- [15] Cervenka, J., R. J. Gorlin and V. E. Anderson. 1967. The syndrome of pits of the lower lip and cleft lip and/or palate: Genetic considerations. *Am. J. Hum. Genet.* 19:416-432.
- [16] Velez, A., F-J. Alamillos, A. Dean and J-J Ruiz-Masera. 1995. Congenital lower lip pit (Van der Woude) syndrome. *J. Am. Acad. Dermatol.* 32:520-521.
- [17] Watanabe, Y., M. Otake and K. Tomida. 1951. Congenital fistulas of the lower lip. *Oral Surg.* 4:709-722.
- [18] Murray, J. C., D. K. Nishimura, K. H. Buetow, H. H. Ardinger, M. A. Spence and R. S. Sparkes. 1990. Linkage of an autosomal dominant clefting syndrome (Van derWoude) to loci on chromosome 1q. *Am. J. Hum. Genet.* 46:486-491.
- [19] Bocian, M. and A. P. Walker. 1987. Lip pits and deletion 1q32-41. *Am. J. Med. Genet.* 26: 437-443.
- [20] Sander, A., R. Schmelzle and J. Murray. 1994. Evidence for microdeletion in 1q32-41 involving the gene responsible for Van der Woude syndrome. *Hum Mol Genet.* 3:575-578.
- [21] Schutte, B. C., A. M. Basart, Y. Watanabe et al. 1999. Microdeletions at chromosome bands 1q32-q41 as a cause of Van der Woude syndrome. *Am. J. Med. Genet.* 84:145-150.
- [22] Koilline, H., F. K. Wong, J. Rautio, V. Ollikainen, A. Karsten, O. Larson, J. Huggare, P. Lahermo, C. Larsson and J. Kere. 2001. Mapping of the second locus for the Van der Woude syndrome to chromosome 1p34: *European Journal of Human Genetics*. 9:747-752.
- [23] Kondo, S., B. C. Schutte, R. J. Richardson et al. 2002. Mutations in IRF6 cause Van der Woude and popliteal pterygium syndromes. *Nat Genet.* 32:285-289.
- [24] Cunningham, F. G., N. F. Ganta, K. J. Leveno. 2001. Multifetal pregnancy. In: F. G. Cunningham et al., (Eds), *Williams Obstetrics*, New York: *McGraw-Hill*, pp.765-810.
- [25] Rintala, A. E. and R. Ranta. 1980. Lower lip sinuses. Epidemiology, microforms and transverse sulci. *Br. J. Plast. Surg.* 34:25-30.
- [26] Crisba, A. 1966. Bilateral connote fistula of the lower lip. *Oral surgery, Oral Med, Oral Pathology.* 22: 226-230.
- [27] Srivastava, S. and R. L. Bang. 1989. Congenital sinuses of the lower lip: Reappraisal of van der Woude syndrome on the basis of nine patients. *Ann. Plast. Surg.* 22:316-320.
- [28] Taylor, W. B. and D. K. Lane. 1966. Congenital fistulas of the lower lip: Associations with cleft lip-palate and anomalies of the extremities. *Arch. Dermatol.* 94:421-424.
- [29] Wang, M. K. H. and W. B. Macomber. 1956. Congenital lip sinuses. *Plast. Reconst. Surg.* 18:319-328.
- [30] Warbrick, J. G, J. R. McIntyre and A.G. Ferguson. 1952. Remarks on etiology of congenital bilateral fistulae of the lower lip. *Br. J. Plast. Surg.* 4:254-262.
- [31] Rintala, A. E. and R. Ranta. 1970. Congenital sinuses of the lower lip in connection with cleft lip and palate. *Cleft Palate J.* 7:336-346.
- [32] Ranta, R. and A. E. Rintala. 1983. Correlations between microforms of the Van der Woude syndrome and cleft palate. *Cleft Palate J.* 20:158-162.
- [33] Onofre, M. A., H. B. Brosco and R. Taga. 1997. Relationship between lower lip fistulae and cleft lip and/or palate in Van der Woude syndrome. *Cleft Palate Craniofac. J.* 34:261-265.
- [34] Shprintzen, R. J., R. B. Goldberg and E. J. Sidoti. 1998. The penetrance and variable expression of the Van der Woude syndrome: implications for genetic counseling. *Cleft Palate J.* 17:52-57.
- [35] Nagore, E, J. M. Sanchez-Motilla, M. I. Febrer, et al. 1988. Congenital lower lip pits (Van der Woude syndrome): presentation of 10 cases. *Pediat. Dermatol.* 15:443-445.
- [36] Waldron, C. A. 1990. Face, lips, tongue, teeth, Oral, soft tissue, jaws, salivary glands. In: J. M. Kissane (Ed.), *Anderson's pathology, St Louis: Mosby*, pp.1095-6.
- [37] Brauen, R. O. 1971. General aspects of the bilateral cleft lip repair. In: W. C. Grabb, S. W. Rosenstein and K. R. Bzoch (Eds.). *Cleft lip and palate*, Boston: *Little/Brown*, pp.278-79.
- [38] Tolarova, M. M. and J. Cervenka. 1998. Classification and birth prevalence of orofacial clefts. *Am. J. Med. Genet.* 75:126-137.
- [39] Vanderas, A. P. 1987. Incidence of cleft lip, cleft palate, and cleft lip and palate among races: a review. *Cleft Palate J.* 24:216-225.
- [40] Online Mendelian Inheritance in Man. National Library of Medicine website: <http://www.ncbi.nlm.nih.gov/omim/>. Accessed 2 Feb 2004.
- [41] Stoll, C., Y. Alembik, B. Dott and M. P. Roth. 2000. Associated malformations in cases with oral clefts. *Cleft Palate Craniofac. J.* 37:41-7.
- [42] Shafer, W. G., M. K. Hine and B. M. Levy. 2007 *A Textbook of Oral Pathology*; 5th edition; WB Saunders Company, Philadelphia.
- [43] Calista, D. 2002. Congenital lower lip pits. *Pediatr. Dermatol.* 19:363-364.
- [44] Wong, F. K. and B. Gustafsson. 2000. Popliteal pterygium syndrome in a Swedish family-clinical findings and genetic analysis with the Van der Woude Syndrome locus at 1q32-q41. *Acta Odontol. Scand.* 58:85-88.

- [45] Fink, S. C. and R. A. Hardesty. 1998. Craniofacial syndromes. In: M. L. Bentz (ed.), *Pediatric Plastic Surgery*, Stamford, CT: *Appleton & Lange*, pp.1–45
- [46] Mutaf, M., O. Sensoz and E. T. Ustuner. 1993. The split-lip advancement technique (SLAT) for the treatment of congenital sinuses of the lower lip. *Plast. Reconst. Surg.* 92:615–620.
- [47] Malik S, Kakar N, Hasnain S, Ahmad J, Wilcox ER, Naz S. 2010. Epidemiology of Van der Woude syndrome from mutation in affected patients from Pakistan. *Clin Genet.* 78: 247-256.