

Recent Research in Science and Technology 2011, 3(10): 30-39  
ISSN: 2076-5061  
[www.recent-science.com](http://www.recent-science.com)



ANATOMY

## THE ANATOMY OF RIGHT CONUS ARTERY AND ITS CLINICAL SIGNIFICANCE

Udaya Sankari T<sup>1\*</sup>, Vijaya Kumar J<sup>2</sup>, Saraswathi P<sup>3</sup>

<sup>1</sup>Department Of Anatomy, Vinayaka Missions Medical College & Hospital, Keezakasakudimedu, Karaikal, Puducherry U.T-609 609 Tamilnadu, India

<sup>2</sup> Professor, Department of Anatomy, Saveetha Medical College & Hospital, Saveetha University, Saveetha nagar, Thandalam, Chennai- 602 105, Tamilnadu, India

<sup>3</sup>Professor and Head, Department of anatomy, Saveetha Medical College & Hospital, Saveetha University, Saveetha nagar, Thandalam, Chennai- 602 105, Tamilnadu, India

### Abstract

**Background of the study:** An intimate knowledge of the anatomy of coronary arteries, the 'Crown' of the heart, does a self-evident pre-requisite for a complete understand of the coronary artery disease or for more intelligent planning of surgery. The right conus artery (R.Con.A) is the first ventricular branch of the right coronary artery (RCA). The aim of this study is to analyse the number and level of ostia in the anterior aortic sinus with regard to the sinu-tubular junction, pattern of origin of right conus artery, angulations of right conus artery, and the branching pattern of right conus artery. The above findings would be of great significance in the interpretation of coronary arteriography, angiography, surgical revascularization of myocardium and embryological interpretations. **Methods:** A total number of thirty cadaveric hearts and twenty angiograms were utilized for this study. This is carried out by dissection method and by coronary angiographic images study. The study is carried out to analyse the number and level of ostia in the anterior aortic sinus with regard to the sinu-tubular junction, pattern of origin of right conus artery, angulations of right conus artery, and the branching pattern of right conus artery. **Results:** The results shows that the percentage calculation of multiple ostium is less than double and single ostia. Individual having triple or multiple opening go in for cardiac problems. The percentage level of ostia, above the sinu-tubular junction was less than that of the below and at the level of sinutubular junction. For the pattern of origin more population had the right conus artery arising from the right coronary artery. In this study the angulation between direct origin of right conus artery from aorta and the angulation between right coronary artery (RCA) and right conus artery was significant. The angulation study suggests that the right conus artery with aortic origin was obtuse and with right coronary artery it was acute. Regarding branches more population had long branches which were boon for them. The results of angiographic images regarding pattern of origin was almost nearer with the previous study and dissection method. The positive results found in the present study provide an extensive knowledge of the right conus artery pattern which is essential for the diagnostic and therapeutic interventional procedures. **Conclusion:** The existence of right conus artery bridges for collateral circulation between the right and left coronary system which is really significant in ischaemic changes of heart.

**Keywords:** Right conus artery (R.Con.A), right coronary artery (RCA), Ostium, pattern of origin, Angulation, Coronary angiogram

### Introduction

An intimate knowledge of the anatomy of coronary arteries, the 'Crown' of the heart, is a self evident pre-requisite for a complete understanding of the coronary artery disease or for more intelligent planning of surgery. Harvey realized it earlier than any other anatomist, that "Structure is a real guide to function; no physiological theory can be true, unless it gives a complete and final explanation of all points of structure."

The right conus artery (R.Con.A) is the first ventricular branch of the right coronary artery (RCA)<sup>[12]</sup>. Most frequently it arises from the proximal part of the right coronary artery. Schlesinger described it as the third coronary artery, as it arise as an independent vessel from the anterior aortic sinus. This extra

coronary artery may be a boon for the person having it<sup>[11]</sup>. This artery when present may help in the establishment of partial identity of an individual, if ante-mortem record and angiography are available<sup>[11]</sup>.

The right conus artery usually forms an anastomosis with the corresponding branch of left coronary artery (LCA). This anastomosis lies on the distal part of the bulbous cordis (truncus arteriosus) and is known as the Vieussen's arterial ring<sup>[22]</sup>. Several authors have postulated that it functions as an important collateral pathway between the right and left coronary arteries.

An embryological investigation has offered a few hypotheses about the development of coronary arteries, but none of those have been directly related to third coronary artery. Several studies have suggested that

\* Corresponding Author, Email: [udipraba@gmail.com](mailto:udipraba@gmail.com)

the coronary arteries did not arise from the aorta, but grew into the aorta from the proximal peri-truncal ring of coronary arterial vasculature<sup>[4,5]</sup>. In developing countries, this study helps the cardiologist during routine diagnostic work and in the management of cardiac diseases.

A cadaveric study in an unsuspected population provides the basis for understanding the variations in the coronary arteries, as coronary artery disease is one of the major causes of death.

The aim of the present study is to analyse the number and level of ostia in the anterior aortic sinus with regard to the sinu-tubular junction, pattern of origin of right conus artery, angulations of right conus artery, and the branching pattern of right conus artery. The above findings would be of great significance in the

interpretation of coronary arteriography, angiography, surgical revascularization of myocardium and embryological interpretations.

## Materials and Methods

### I. Embalming procedure of the cadaver

The cadavers were embalmed by the arterial embalming method, by injecting the embalming fluid (methanol-55%, glycerin -20%, water-15%, formalin-10% and thymol few crystals) into the femoral artery with the help of embalming machine. A total number of thirty hearts were obtained from these embalmed cadavers of adult individuals and the same were fixed in 10% formalin. The study was carried out in Department of Anatomy[Table-I].

Table - I

Department of anatomy	Number of heart studied
Saveetha Medical College and Hospital, Thandalam, Kanchipuram-602105.	15
Saveetha Dental College and Hospital, velappan chavadi, Chennai-600 077.	4
From various Medical Colleges, Chennai.	11
Total number of hearts	30

## II. Dissection method

### A. Gross Dissection

Gross dissection was done on the hearts with the help of dissection forceps (pointed, tooth, blunt), scalpel and scissors.

#### (i) To study the pattern of origin

The right coronary artery was traced through epicardium and subepicardial adipose tissue. Then the subepicardial adipose tissues were removed. The branches of right coronary artery were traced with particular attention to the origin of the right conus artery and the right conus artery branches were traced macroscopically.

#### (ii) To study the ostium

The ascending aorta was transversely sectioned approximately 1cm above the commissure of the aortic leaflets. The aorta was then longitudinally opened at the level of the right posterior aortic sinus (noncoronary sinus) which enabled to analyse the level and number of ostia, with respect to sinu-tubular junction.

After the dissection, the ostia were displayed clearly, and then photographed by the following methods. The common opening and separate ostium were displayed clearly by inserting GP sticks. This method is not applicable in multiple ostia, hence it was photographed without GP sticks.

### B. Micro dissection

To trace the branches of R.Con.A, blood vessels were washed with saline. Then micro dissection was

done with the help of the hand lens to trace the terminal branches. The traced branches were painted with red coloured enamel paint using a brush. The specimens were dried and then photographed.

### C. Method for measuring the angle

Angulation of right conus artery was measured with respect to aorta and right coronary Artery using manual goniometer consisting of two arm; a fixed and a movable arm with a protractor.

#### i) Angulation with respect to Aorta

Central axis of goniometer was placed at the junction of Aorta and origin of right conus artery. Fixed arm of goniometer was placed along with the axis of ascending aorta and the movable arm was placed along with the axis of right conus artery and the angulation was measured.

#### ii) Angulation With Respect to Right Coronary Artery

Central axis of goniometer was placed at the junction of right coronary and right conus artery. Fixed arm of goniometer was placed along the axis of right coronary artery and the movable arm was placed along the right conus artery and the angulation was measured.

## III. CT Coronary Angiographic study

The CT coronary angiograms of patients, who had undergone this procedure for various reasons, were utilized in this study.

**A. Exclusion criteria**

Myocardial infarction patients  
Children were excluded.

**B. Procedure:**

**Pre-procedure precautions**

- The patients were enquired, to rule out the presence of any drug allergy, to avoid the occurrence of any untoward anaphylactic reaction, during the procedure.
- Two days prior to the procedure the patients were advised to avoid the intake of fatty food.
- During the procedure:
- Just before the procedure the patient was advised to drink only water.
- Blood urea and creatinine levels were evaluated prior to the procedure.
- An hour prior to the procedure the patient was given  $\beta$ -blockers to reduce the heart rate.
- Half an hour prior to procedure ECG and pulse rate were monitored.
- Administered  $\beta$ -blockers maintained a heart rate of 55-60 beats/min during the procedure.
- The patient was cannulated through a 15 gauge venflon into one of the peripheral veins, preferably the cephalic vein.
- The patient was now shifted to the CT scanner.
- The patient was adequately counselled to reduce his /her anxiety, in order to maintain the optimum heart rate of 55-60 beats /min.
- The contrast dye (iohexol) in concentration of 70:20, i.e., contrast: normal is infused through the

canula, using a pressure injector at the rate of 4ml/sec.

- The patient was then made to lie down on the CT table and scanning was done.
- During the CT scan procedure, the scanner rotates around the patient and a number of X-ray images were taken.
- These X-ray images taken from various angles during the CT scanning procedure were sent to a computer, which analyses the pictures and gives a 3- dimensional volume rate image.
- Such CT coronary angiographic images obtained from patients ageing above 45 years have been randomly selected for this study. Out of these, CT angiograms of 20 patients were studied, to see the pattern of origin of right conus artery.

**Statistical analysis**

All the values obtained were expressed in percentage .and the p value obtained for angulation of right conus artery with respect to aorta and right coronary artery was 0.0003, which was extremely statistically significant.

**Results**

**I.Number of ostia in anterior aortic sinus**

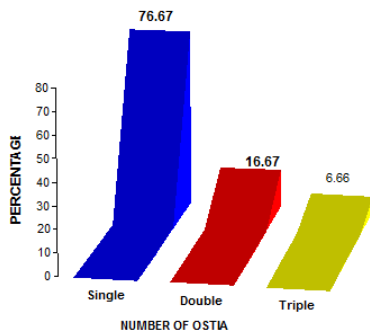
Table II and Fig 1 shows Single ostium was seen in twenty three cadaveric hearts (76.67%), double ostia were seen in five hearts (16.67 %) and triple ostium were seen in two hearts (6.66%).

Number of ostia in anterior aortic sinus [Table – II]

Number of ostia	Percentage (%)
Single(23/30)	76.67
Double(5/30)	16.67
Triple(2/30)	06.66

**Number of ostia in anterior aortic sinus**

Figure1-Percentage of number of ostia



**II. Result of Level of ostia with respect to sinu-tubular junction(Table III ,fig 2)**

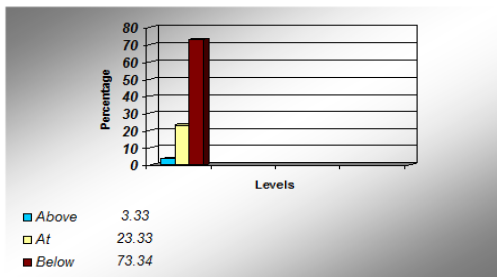
The levels of the ostia were observed at, above and below the sinu-tubular junction. The ostia were present below the sinu-tubular junction in twenty two hearts (73.34%), at sinu-tubular junction in seven hearts (23.33%) and above the sinu-tubular junction in one heart(3.33%).

Level of ostia with respect to sinu-tubular junction [ TableIII]

Level of ostia	Percentage (%)
Above sinu-tubular junction (1/30)	3.33
At sinu-tubular junction (7/30)	23.33
Below sinu-tubular junction (22/30)	73.34

Level of ostia with respect to sinu-tubular junction

Figure 2 Percentage of level of ostium



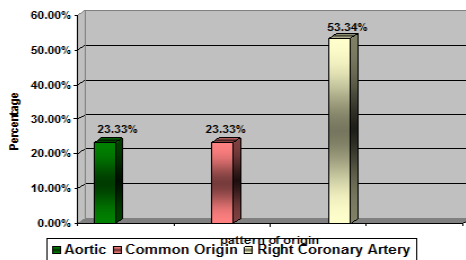
III Pattern of origin OF R. CON. A.

Out of 30 hearts, the origin of right conus artery from the right coronary artery was seen in 16 hearts , common origin [right conus artery and right coronary artery was seen in 7 hearts and aortic origin of right conus artery were seen in 7 hearts (23.33%) [Table IV and fig3].

Pattern of origin OF R. CON. A. : TableIV

pattern of origin	Percentage (%)
Aortic (7/30)	23.33
Common origin(7/30)	23.33
Right coronary artery(16/30)	53.34

Figure3 Percentage of pattern of r. Con. A.



conus artery and remaining sixteen hearts had the right conus artery from the right coronary artery .

IVa. The Angulation with respect to aorta: (TableV and Fig4)

Out of fourteen hearts, eleven hearts showed the angulation of origin of the right conus artery, ranging between 90° - 100°(78.57%), in two hearts the range 100°-110° (14.29%) and in one heart the range was 120°-130°(7.14%) [Fig.8, Out of fourteen hearts, eleven hearts showed the angulation of origin of the right conus artery, ranging between 90° - 100°(78.57%), in two hearts the range 100°-110° (14.29%) and in one heart the range was 120°-130°(7.14%) .

IV. Result of Angulation

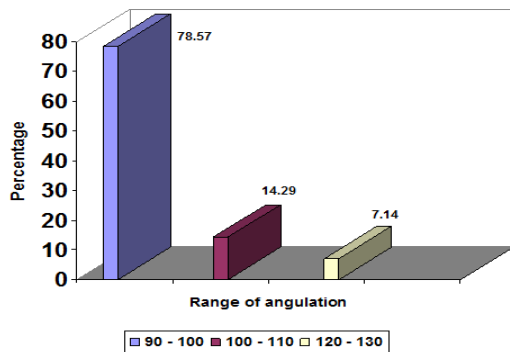
Result of angulation of right conus artery in relation to aorta and right coronary artery. Out of thirty hearts fourteen hearts had aortic origin of the right

The Angulation with respect to aorta :Table V

Range	No. of heart specimen	(%) with respect to aorta
90° -100°	11	78.57
100° -120°	2	14.29
110° -120°	-	0
120° -130°	1	7.14

The Angulation with respect to aorta

Figure 4 Percentage of angulation with respect to aorta



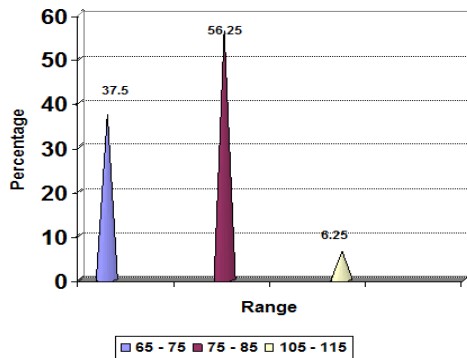
IV b. Angulations with respect to right coronary artery: (Table VI and Fig5)

Out of sixteen hearts, in nine hearts showed the right conus artery arose from the right coronary artery in an angle ranging between 75°-85° (56.25%), in six hearts the range was 65°-75°(37.5%) and in 1 heart it was 105°-110°(6.25%).

Angulations with respect to right coronary artery Table VI

Range	No of Heart specimens	% with respect to right coronary artery
65° -75°	6	37.50
75° -85°	9	56.25
85° -95°	-	-
95° -105°	-	-
105° -110°	1	6.25

Figure 5 Percentage of angulation with respect to right coronary



Statistical analysis and result for angulation of right conus artery with respect to aorta and right coronary artery[tableVII]

Table VII

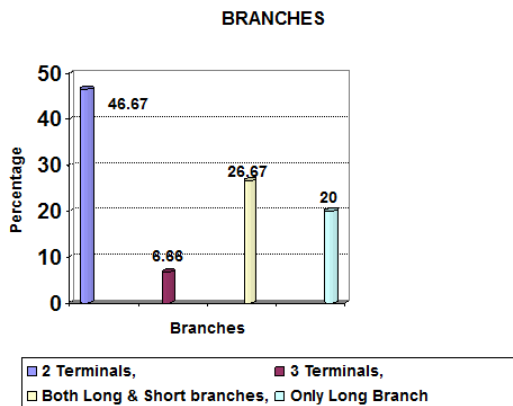
Statistical variants	With respect to aorta	With respect to right coronary artery
Mean	95.86°	76.69°
Standard deviation (SD)	11.38	10.05
Standard error of mean (SEM)	±3.04	±2.51
Number	14	16

The angulation measurements were studied by statistical method to show the significance. The p value obtained for angulation of right conus artery with respect to aorta and right coronary artery was 0.0003, which was extremely statistically significant.

**V. Study of branches of right conus artery: (fig6).**

Out of thirty adult cadaveric hearts studied, in fourteen hearts the right conus artery divided into two small terminal branches (46.67%), in two hearts (6.66%), it divided into three small terminal branches, eight hearts (26.67%) had both short and long branches and six hearts (20%) had only one long branch (figVI). By micro dissection with hand lens, the branches of the long and the short branches were studied in detail.

Fig 6 Percentage of branches of r. Con.a.



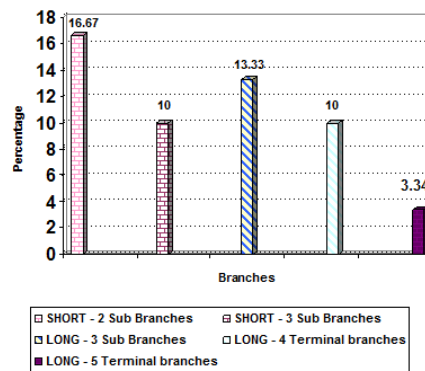
**Short branches: (fig7).**

Two short sub branches were found in five out of eight hearts (16.67%) and three short sub branches were seen in three hearts (10%).

**Long branches: (fig7).**

Three long sub branches were found in four out of eight hearts (13.33%), four long sub branches were seen in three hearts (10%) and five long sub branches were seen in one heart (3.34%).

Figure 7 Percentage of sub branches r. con. A



**Result of angiographic study of 20 randomly selected CT angiogram: Table VIII, figure 8**

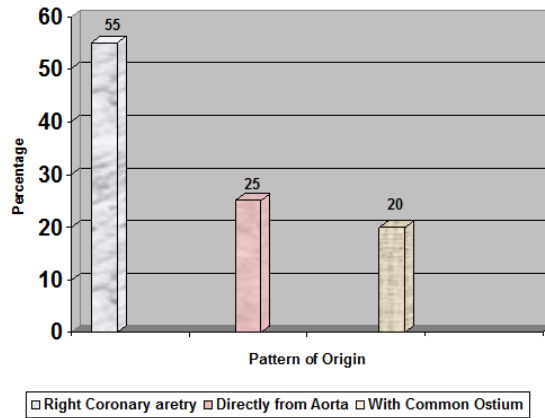
In this method only the pattern of origin were studied. Other findings of ostia, angulation and sub branches could not be made out. Result of angiographic study of 20 randomly selected CT angiograms

**Angiographic study of 20 randomly selected CT angiogram**

Table VIII

Pattern of origin of right conus artery	Percentage (%)
From right coronary artery(11/20)	55
Directly from aorta (5/20)	25
With common ostium (4/20)	20

Figure 8 Percentage of pattern of origin of right conus artery in ct angiogram



## Discussion

In the present study the ostium, pattern of origin, angulations and branches of right conus artery were studied in 30 adult cadaveric hearts.

### Number of ostia

Similar study of ostia has been carried out previously by Kurjia et al (1986), Murlimanju (2006), Galit Aviram et al (2007), Olabu et al (2008), and Joseph Knig et al (2009).

The presence of multiple ostia in anterior aortic sinus, suggestive of emergence of the following arteries directly from the aorta: Right conus artery, right coronary artery, SA nodal artery, vasovosorum of pulmonary trunk and anomalous origin of left coronary artery. Individuals with multiple ostia in anterior aortic sinus should be advised for regular follow-up and to carefully look for any related symptoms of angina, myocardial infarction and left ventricular dysfunction [8].

In this study number of ostia was studied in detail. Single ostium was present in 76.67%, double ostium in 16.67% and triple ostium in 6.66%. The knowledge of double opening in 16.67% individuals may be useful in performing coronary arteriography. Individuals having triple opening may go in for cardiac problems. Out of three branches coming from ascending aorta, the right coronary artery is thin and slender, other two branches (vasa vasorum of pulmonary trunk and right conus artery) are short. Hence all the three branches coming from ostia were small. The above finding suggests that the irrigation for the right side of the cardiac musculature may be poor. This knowledge of number of opening present in anterior aortic sinus may be utilized, while performing coronary arteriography and angiography.

Boger and his coworkers (1989) in their study regarding development of coronary arteries suggested that the coronary artery do not grow out of aorta, but

they grow into aorta from the peritruncal ring of coronary vasculature. This view throws a new light on normal and abnormal development of proximal coronary arteries and orifices [4].

David et al. (2002) suggested that the development of the coronary arteries were from outside to inside i.e, the multiple vessels arising from the peritruncal ring of capillaries[5]. This process involves apoptotic changes by the molecular mechanism involving, vasculo endothelial growth factor (VEGF) and fibroblast growth factor (FGF-I). These factors stimulate the vasculogenesis and angiogenesis.

In this study the multiple openings found in anterior aortic sinus would have been due to the folding of the heart resulting in bulbous cordis being absorbed into both the ventricles. The folding of the heart results in opening of existing peritruncal capillaries at the cono truncal circle either directly into the newly formed aorta (results in multiple ostia) or secondarily attached to the existing blood vessels surrounding the atrioventricular circle resulting in the right conus artery arising from right coronary artery by Ivan stankovic et al.(2004). The knowledge of ontogeny of the right conus artery requires further detailed study in foetus [12].

### Level of ostium

Since the right conus artery did not arise from the right coronary artery always, the study of level of ostium gains importance for angiographic dye injection. If the right conus artery arises directly from the aorta it is named as third coronary artery (Schlesinger1949). The level of ostium was studied in this work in relation to sinu-tubular junction.

Similar study has been previously reported by Johannes Piegger et al (2001), Murlimanju et al (2006), Markou et al (2007), Louis I Bezold (2010), Subhash et al (2010).

Murlimanju et al (2006) reported that the right coronary ostium was below the sinu-tubular junction in 16% and was above the sinu-tubular junction in 2% of the cases. Subhash et al (2010) reported the location of right coronary ostium, below the sinu-tubular junction in 89% [26].

In this study, the level of ostia, above the sinu-tubular junction was 3.33%, at the level 23.33% and below the level was 73.34%. The difference found in all the 3 levels with reference to Murlimanju et al. (2006), could have been due to geographical differences as described by Gouda Hareesh et al (2009) [23,11]

### Pattern of origin

Origin of right conus artery was studied in three patterns:

- i. directly from aorta

ii. aortic origin with common opening of right coronary artery

iii. outside the aorta from right coronary artery .

Similar study has been done by Schlesinger (1949), Edwards (1981), Kurjia et al.(1986), Miyazaki et al. (1988), Kalpana (2003), Ivan Stankovic et al. (2004), Susan standing (2006), Olabu et al. (2008), Gouda Hareesh et al. (2009), Pinar Kosar et al. (2009).

In this study aortic origin of right conus artery was found in 23.33% and this result go in hand with Kalpana (2003) 24%, Pinar Kosar et al.(2009) 22% and difference with Susan standing (2006) 34% could be due to geographic variation [16,25,27].

The common origin of right conus artery with right coronary artery was observed in this study in 23.33%. This may be useful while performing coronary arteriography and angiography. Gajbe et al. (2010) suggested that a preliminary aortic root injection of dye method was followed to locate the exact number of orifice of the coronary ostia, in order to prevent the fatal outcome [8].

In this study, 53% of the population had the right conus artery arising from the right coronary artery and in the rest 47% of the individual's right conus artery either arose directly from the aorta or in common with right coronary artery. So the present study suggests that 47% of population needs care while performing coronary angiography to prevent fatal out come.

#### Study of angulations

Similar study of angulations has been done by Ivan Stankovic et al (2004). He reported that the angle between the third coronary artery (TCA) and Aorta is  $73.4^{\circ} \pm 35.2^{\circ}$  (insignificant) and angle between right coronary artery and right conus artery is  $82.3^{\circ} \pm 39.8^{\circ}$  (insignificant) [12].

In this study the angulation between direct origin of right conus artery from aorta was  $95.86^{\circ} \pm 3.04^{\circ}$  (significant  $p=0.0003$ ) and the angulation between right coronary artery (RCA) and right conus artery was  $79.69^{\circ} \pm 2.51^{\circ}$  (significant  $p=0.0003$ ).

Mostly in cases where the right conus artery arises from the right coronary artery the angle ranges between  $75^{\circ}$ - $85^{\circ}$ (56.25%),  $65^{\circ}$ - $75^{\circ}$ (37.50%),  $105^{\circ}$ - $110^{\circ}$ (6.25%). The knowledge of angulation would be useful for the surgeons while performing right ventriculotomy to avoid damage to right conus artery. The present study also suggests that, very rarely the branch may ranges from  $105^{\circ}$ - $110^{\circ}$  (6.25%). Most of the aortic origin of right conus artery ranges between  $90^{\circ}$ - $100^{\circ}$  (78.57%).

The angulation study suggests that the right conus artery with aortic origin was obtuse and with right coronary artery it was acute.

From Table-VI, it is obvious that in 53% of the population, the right conus artery had acute angulation. More the acute, more the ischaemic changes.

According to this study in 47% of the population, right conus artery arose from the aorta, and the angle was obtuse. So they were advantageous over the 53% of the population who were having right conus artery arising from the right coronary artery.

#### Branches of right conus artery

Branches of right conus artery has been studied by Takumi Sumimoto et al.<sup>2</sup> (1992), Antonello Musiani et al. (1995), Tuvia Ben-Gal et al. (1997), Masakazu Yamagishi et al. (2005), Markou et al. (2007), Wynn et al. (2008).

Branches of the right conus artery form an important collateral circulation between the right and left coronary artery as suggested by Miyazaki et al.<sup>21</sup>(1988).

In this study out of 30 hearts two small terminal branches were seen in 46.67%, three small terminal branches in 6.66%, both short and long conus branch in 26.67% and only one long branch in 20% of individuals.

The two small terminal branches were seen in 46.67% and three small terminal branches were seen in 6.66%. Altogether small terminal branch of right conus artery was seen in 53.33% of individuals.

For the 53.33% of population who had the short branch from the right conus artery, it was not a boon [Gouda Hareesh et al (2009)] because for these individuals the collateral circulation with left anterior descending branch was negligible [11].

Both short and long branches were seen in 26.67% of the individuals and only one long branch was seen in 20% of the individuals. Altogether 46.67% of individuals had long branch from right conus artery.

During obstruction and atresia of LAD these long branches of right conus artery, serve as collateral branches and irrigate the myocardium below and above the obstruction. A similar study has been done by Antonello Musiani et al. (1995), Wynn et al (2008). For individuals having a long branch from right conus artery, it was really a boon [3,31].

It was interesting to note that the presence of the only long branches from the right conus artery running parallel to left anterior descending branch (LAD) was about 20%. This branch supplies the inter ventricular septum up to the apex of the heart and these branches may compensate for the blood supply of the relatively reduced coronary blood flow during hypertrophied myocardium [28]. So the study of the branches of right conus artery concludes that from the 30 cadaveric hearts 53.33% of the population had short branches and 46.67% had long branches. In 46.67 % of the population, the right conus artery was a boon for them.

#### Angiographic study

Similar angiographic studies were carried out by Takumi Sumimoto et al.(1992), Tuvia Ben-Gal et al.



(1997), Masakazu Yamagishi et al. (2005), Joseph Knig et al. (2009), Pinar Kosar et al. (2009).

In this study the pattern of origin of right conus artery was studied with the help of 20 coronary angiograms. It was difficult to carry out the study of branches, as it required digital subtraction angiogram. Findings of ostium, angulation and sub branches could not be made out.

Similar study of pattern of origin of right conus artery was carried out by Pinar Kosar et al (2009). His observation of origin of right conus artery from the aorta was about 22% [25].

In this study origin of right conus artery from the aorta shows 20%, this was nearer to Pinar Kosar et al. (2009).

The other two pattern of origin i.e., the right conus artery arising from right coronary artery were seen in 55% and common ostia were seen in 25% of individuals. These findings correlate with the dissection method result which was 53.33% and 23.33% of individuals respectively.

## Conclusion

In this work, 30 human cadaveric hearts were used to study the ostium, pattern of origin, angulations and branches of right conus artery and 20 Coronary angiograms were also used to study the pattern of origin.

The presence of single, double and triple ostia at different levels (at, below, above) with respect to sinu-tubular junction were studied and its presence has been interpreted embryologically.

The patterns of origin (aortic, common and right coronary artery) in the cadaveric study and in the angiographic study were nearly similar.

Angulation of the right conus artery with the aortic origin was obtuse and with the right coronary artery it was acute. This reveals that if right conus artery directly arises from the aorta (third coronary artery) it is really a boon with an obtuse angle.

The branching pattern could not be studied with angiographic images. If the branches are short the myocardium of the right ventricle would suffer from irrigation, but if the branches are longer they run parallel to left anterior descending artery and establish double collateral circulation for interventricular septum and myocardium of the left ventricle. This prevents the right coronary artery "steal" phenomenon.

The existence of right conus artery bridges for collateral circulation between the right and left coronary system which is really significant in ischemic changes of heart.

"Blessed are the people, those who are born with right conus artery (R.Con.A) with long branches"

## Bibliography

1. Abdelmoneim Abdellah, Ahmed SA Elsayed, Mohamed Hassan Angiographic coronary artery anatomy. Khartoum Medical journal 2009; 02(1):162-164.
2. Anderson, Mcgoon D, Lu J. Surgical significance of coronary artery anatomy in truncus arteriosus communis. The American journal of cardiology 2009;41(1):76-81 .
3. Antonello Musiani, Ezio Micalizzi, Carlo Gasperis DE. Surgical Revascularization for left main coronary artery atresia. Ann Thorac Surg 1995; 60: 229-23.
4. Boger, Gittenberger Groot, Poelmann RE, Peault BM, Huysman HA. A development of the origin of the coronary arteries, a matter of ingrowth or outgrowth. Journal anatomy and embryology 1989;150(5):437-4415.
5. David Bernanke H, Matthew Velkey J. Development of the coronary blood supply. Changing concepts and current ideas Clin. Anat2001; 5:369-372.
6. Duran, Fernandez T, Fernandez Gallego, Aroute JM and Sans Coma V et al. Number of Coronary Ostia in Syrian Hamsters (*Mesocricetus auratus*) with Normal and Anomalous Coronary Arteries. Anatomia Histologia Embryologia 2007 oct;10:439-788.
7. Edwards WD, Edwards JE. Aortic origin of conus coronary artery. Evidence of postnatal coronary development. British Heart Journal 1981; 45: 555-558.
8. Gajbe UL, Gosavi S, Meshram S ,Gajbhiye The anomalous origin of multiple coronary ostia and their clinical significance. Int.j.morp 2010 Feb; 4 (1): 2129-2133.
9. Galit Aviram, Haim Shmilovich, Ariel Finkelstein, Galia Rosen, Shmuel Banai, Moshe Graif et al. Coronary ostium—straight tube or funnel shape, a computerized tomographic coronary angiography study. Acute cardiac care 2006 Dec; 8(4):224-228.
10. Geraldo de Oliveira Silva-Junior, Sandro Wilson da Silva, Carlos Alberto Mandarim Lacerd. Origin and development of the Coronary Arteries. Int. J. Morphol 2009; 27 (3):891-898.
11. Gouda Hareesh, Meshri shashidhar Third coronary artery – Boon or Bane? Journal of Indian Academy of Forensic Medicine 2009, 31(1): 971-973.
12. Ivan Stankovic, Milica Jesic Morphometric analysis of the conal coronary artery. MJM 2004; 8: 2-6.
13. Jamshid Shirani, Jamshid Shirani MD, Alessandra Brofferio. Isolated coronary artery anomalies. 2009 Dec.
14. Johannes Piegger Peter Kovacs, Edda Ambach Extremely high origin of the right coronary artery

- from the ascending aorta. *Clinic anatom.* 2001sep; 14(5):369 - 372.
15. Joseph Knig Vartan Kurtcuoglu, Karl Muffly, William Marshall Jr, Paul Stolzmann, Lotus D, Burkhardt Seifert et al. Normal in vivo distribution and variation coronary ostial locations. 2009mar; 31(8):597-604.
  16. Kalpana M. A study on principal branches of coronary arteries in Humans. *J Anat. Soc. India* 2003; 52(2): 137-140.
  17. Kurjia HZ, Chaudhry MS; Coronary artery variation in a native Iraqi population. *Cathet Cardiovasc Diagn* 1986; 12(6):386-90.
  18. Louis Bezold , Coronary Artery Anomalies. 2010
  19. Markou, Gavrielatos G, Alexanian I, Anastasopoulou A, Salahas, Antonellis Anomalous origin of right coronary artery. Is there a link between coronary artery variation and myocardial ischemia? *The Int. Journal of Cardiology.* 2007; 5(1).
  20. Masakazu Yamagishi , Kazuo Haze, Jun Tamai, Kenichi Fukami , Shintaro Beppu, Tsuyoshi Akiyama, Kunio Miyatake Visualization of isolated conus artery as a major collateral pathway in patients with total left anterior descending artery occlusion. *J on catheteriz and cardiovas diag* 2005Dec; 15(2):95-98.
  21. Miyazaki M , Kato T. Third coronary artery. Its development and function. *Acta cardiol* 1988; 43(4):449-457.
  22. Mladen Kocica J, Mile Vranes R, Petar Djukic L, Aleksandar D M, Milos Velinovic, Marija Havelka, Vladimir Kanjuh Giant Pseudoaneurysm From Vieussen's Arterial Ring. *Ana.thorac.surg* 2004; 78:1833-1836
  23. Murli manju Dalbir kaur, Narga nair Morphology and morphometry of coronary ostia in adult human cadaveric hearts. *J Anat. Soc. India* 2006; 56(1).
  24. Olabu, Saidi, Hassanali, Ogenga Prevalence and distribution of the third coronary artery (TCA) in Kenyans. *Int j.of morphol* 2007 Nov; 25(4):851-854.
  25. Pınar Koşar, Elif Ergun, Ugur Koşar Anatomic variations and anomalies of the coronary arteries: 64-slice CT angiographic appearance *Diagn interv.radiog* Dec 2009 ;15(4):275-283.
  26. Subhash Joshi, Sharda S. Joshi, Sunita Arvind Origins of the coronary arteries and their significance. *Clinics* 2010; 65 (1)
  27. Susan Standring, Harold ellis, Jeremiah healy, Andrew william , David Jonn. *Gray's anatomy*, 39<sup>th</sup> ed. London(uk):Elsevier;2006.p.1016.
  28. Takumi Sumimoto, Mareomi Hamada, T. Ohtani, Yuji Shigematsu. A large conus artery in patients with hypertrophic cardiomyopathy. *Journal Heart and Vessels* 1992 mar; 7(1):52- 55.
  29. Tuvia Ben-Gal Samuel Sclarovsky Importance of the Conal Branch of the right coronary artery in patients with acute anterior wall myocardial infarction: Electrocardiographic and Angiographic Correlation. *J Am Coll Cardiol* 1997; 29:506–511.
  30. Von Ludinghausen The clinical anatomy of coronary arteries. *Ava.anat embry cell boil* 2003; 167: 1-111.
  31. Wynn, Noronha B, Burgess M. Functional significance of the conus artery as collateral to an occluded left anterior descending artery demonstrated by stress echocardiography. *International Journal of Cardiology* 2008; 140(1): 14-15.