



RRST- Pharmacology

## A Review on "Churg-Strauss Vasculitis"

K. Kinja\*, S. Rohit, A. Mandloi, D. Gnaneshwari, R.K. Sharma

Department of Pharmacology, NIMS Institute of Pharmacy, Shobha Nagar, Jaipur-303121, Rajasthan, India

Article Info	Abstract
<p><b>Article History</b></p> <p>Received : 12/02/2011            Revised : 18/03/2011            Accepted : 18/03/2011</p> <p><b>*Corresponding Author</b></p> <p>Tel : 9529155588</p> <p>Email:  <a href="mailto:kkinja_pharma@yahoo.com">kkinja_pharma@yahoo.com</a></p>	<p>Churg-Strauss syndrome (CSS) is a systemic disorder characterized by asthma, transient pulmonary infiltrates, hypereosinophilia, and systemic vasculitis. Eosinophilic vasculitis may involve multiple organ systems, including the lungs, heart, skin, gastrointestinal tract and nervous system. Thus allergy and angitis are the two hallmarks of CSS. Conditions in the differential diagnosis of CSS include Wegener's granulomatosis (WG), drug reactions, bronchocentric granulomatosis, eosinophilic granuloma, fungal and parasitic infections, and malignancy. Onset typically occurs in patients aged from 15 to 70 years. On presentation, patients often have pulmonary infiltrates on chest x-ray, but they may also have sinusitis, neuropathy, constitutional symptoms, or gastrointestinal or cardiac manifestations. It is important to establish a tissue diagnosis by biopsy and exclude other diseases in the differential diagnosis of CSS because treatment differs significantly from that of other eosinophilic lung diseases. Untreated, CSS may have a dire prognosis, but treatment with corticosteroids or cytotoxic agents, or both, usually results in clinical remission. Although the exact etiology of CSS is unknown, this syndrome is likely believed to represent an autoimmune process because of the prominence of allergic features and the presence of immune complexes, heightened T-cell immunity and altered humoral immunity, as shown by elevated immunoglobulin (Ig) E and rheumatoid factor. Treatment consists of glucocorticoid (GC)-monotherapy, data on outcome and affectivity is lacking on other immunosuppressive regimens such as cyclophosphamide (CP) or GC plus CP. Treatment with INF-alpha has been effective in patients refractory to GC plus CP.</p> <p><b>Key Words:</b> Systemic vasculitis, Asthma, Pulmonary infiltrates hypereosinophilia, Allergic angitis, and Granulomatosis</p>
©ScholarJournals, SSR	

### Introduction

Churg-Strauss syndrome (CSS) is a systemic disorder characterized by asthma, transient pulmonary infiltrates, hypereosinophilia, and systemic vasculitis. Eosinophilic vasculitis may involve multiple organ systems, including the lungs, heart, skin, gastrointestinal tract and nervous system. The three main histological features found on the pathological examination of CSS cases are extravascular granulomas, tissue eosinophilia, and necrotizing vasculitis. Thus allergy and angitis are the two hallmarks of CSS. The Churg Strauss Syndrome is a rare condition, which causes inflammation in blood vessels, restricting the blood flow to various body organs. Though the disease may affect any body organ, it is seen that usually it is the lungs, nerves and skin which are most affected. The disease may cause temporary or irreversible damage to these organs. The most common feature of Churg Strauss Syndrome is asthma, also known as Allergic Granulomatosis. The disease is also known to show a type of tissue destroying inflammatory response called granuloma. Churg Strauss Syndrome is an autoimmune vasculitis, leading to necrosis, involving the blood vessels of the lungs, gastrointestinal system, peripheral nerves, heart, skin and kidneys. Churg-Strauss syndrome is rare. The cause of this syndrome is not known. But it involves an abnormal over-

activation of the immune system in a person with underlying bronchospastic lung disease (asthma). While Churg-Strauss syndrome has been reported to be associated with certain asthma medications, called leukotriene modifiers. The disease can occur at any age, but it's more commonly diagnosed in middle-aged people. People older than 65 are unlikely to develop Churg-Strauss syndrome. Other common names for CSS are allergic granulomatosis and allergic angitis. Churg-Strauss syndrome causes fever, weight loss, and sinus or nasal passage inflammation in the patient with asthma. Almost all people with CSS have increased numbers of "allergic type" blood cells called eosinophils. Eosinophils are a type of white blood cell. Normally, eosinophils make up 5% or less of the total white blood cell count. In CSS, eosinophils usually make up more than 10% of the total white blood cell count. In addition, most biopsies contain clusters of cells called "granulomas" that may or may not involve blood vessels. The granulomas often include eosinophils and are therefore called "allergic granulomas." In fact, another name for CSS is allergic granulomatosis. Some of the most serious manifestations of CSS are related to the presence of vasculitis. Other names for this disorder are Allergic Angitis and Granulomatosis, Allergic Granulomatosis and Angitis, Eosinophilic Granulomatous

Vasculitis, Churg-Strauss Vasculitis [1, 2]. Churg-Strauss syndrome is rare and is defined by six criteria:

- (1) Bronchial asthma;
- (2) Eosinophilia 10% by differential white cell count;
- (3) Mono- or polyneuropathy;
- (4) Nonfixed pulmonary infiltrates on chest radiography;
- (5) Paranasal sinus abnormalities;
- (6) Biopsy containing blood vessels with extravascular eosinophils.

Presence of 4 out of 6 of these criteria has 99.7% specificity and 85% sensitivity for Churg-Strauss [3].

#### What is vasculitis?

Vasculitis is a general medical term that refers to inflammation of the blood vessels. When blood vessels become inflamed, they can stretch, become thin-walled, or narrow in size. When they weaken and stretch in size, aneurysms can develop. (An aneurysm is an abnormal blood-filled expansion of a blood vessel.) When they thin, the walls can rupture and blood leaks into tissue. Vasculitis can also cause blood vessels to narrow to the point of closing. Organs can be damaged from the loss of oxygen and nutrients that were being supplied by the blood.

#### History

First Description Churg-Strauss Syndrome (CSS) is a systemic vasculitis. This disease was first described in 1951 by Dr. Jacob Churg and Dr. Lotte Strauss [as a syndrome consisting of "asthma, eosinophilia an excessive number of eosinophils in the blood], fever, and accompanying vasculitis of various organ systems" when they reviewed a number of autopsy cases that were previously classified as polyarteritis nodosa. CSS shares many of the clinical and pathological features of polyarteritis nodosa ("PAN", another type of vasculitis). Churg and Strauss discovered that the presence of granulomas as well as the abundance of eosinophils distinguished this disease from PAN. Although no universal agreement on CSS criteria has been reached so far, the most commonly used criteria are those developed by the American College of Rheumatology (ACR). The ACR criteria include both clinical and pathological features and classify CSS as the presence of four of the following six features: asthma, eosinophilia, neuropathy, pulmonary infiltrates, paranasal sinus abnormality and eosinophilic vasculitis [3].

#### Frequency

Onset typically occurs in patients aged from 15 to 70 years and the disease affects both males and females. The mean annual incidence in England is 2.4 per million inhabitants. The estimated prevalence of CSS in Norway is 1.3 per 100,000 inhabitants compared to 5.3 for WG. The annual incidence of the disorder is estimated at 2.4-4 cases per million general population, while among asthma patients, an average of 34.6 cases per million asthma population has been reported [4]. A recent German population-based epidemiological study of a population of nearly 5 million people revealed an incidence of 1 per year per one million compared to 8 for WG. In another German study, the period prevalence rate of CSS in 1994 was 7 per one million compared to 58 for WG. Although CSS has long been considered as a rare disease, there has been a recent increase in case reports in association with different asthma therapies. This has raised the questions of how rare

this disease truly is and whether incidence has indeed increased in association with various forms of asthma therapy. In particular, CSS in association with asthma therapy was first reported in 1998 in patients receiving zafirlukast, but there have since been several reports of the syndrome in association with both montelukast and pranlukast, as well as with various inhaled corticosteroids.

#### Symptoms

- Respiratory symptoms- The most common presenting manifestation of CSS is asthma, although as many as 2% of patients may develop airway symptoms after the onset of systemic vasculitis. Asthma often occurs in individuals who have no family history of atopy. It is severe and requires treatment with oral corticosteroids to control symptoms, which may lead to suppression of vasculitic symptoms. In addition the more common symptoms of cough, dyspnea, sinusitis, and allergic rhinitis, alveolar hemorrhage and hemoptysis may also occur [5].
- Neurological symptoms- Neurological involvement is the second most common manifestation and occurs in approximately 78% of patients. Mononeuritis multiplex most commonly involves the peroneal nerve but may involve the ulnar, radial, internal popliteal and occasionally, cranial nerve. Isolated weakness, such as foot drop, is a common manifestation. Polyneuropathy often develops in the absence of treatment and may be symmetric or asymmetric [5]. Cerebral haemorrhage and infarction may also occur and are important causes of death. Despite treatment, neurological sequelae do not often completely resolve.
- Dermatologic symptoms- Approximately half of CSS patients develop dermatological manifestations. These include palpable purpura, skin nodules, urticarial rashes, and livedo. They usually present on the limb surfaces but can affect any part of the body.
- Cardiovascular symptoms- The heart is a primary target organ in CSS and its involvement often portends a worse prognosis. Granulomas, vasculitis and widespread myocardial damage may be found on biopsy or at autopsy, and cardiomyopathy and heart failure may be seen in up to half of all patients but are often at least partially reversible. Acute pericarditis, constrictive pericarditis, myocardial infarction, and other electrocardiographic changes may occur [6].
- Gastrointestinal symptoms- Gastrointestinal symptoms are common in CSS. They often consist in an eosinophilic gastroenteritis characterized by abdominal pain, diarrhoea, gastrointestinal bleeding, and colitis. Ischemic bowel, pancreatitis, and cholecystitis also have been reported in association with CSS and usually portend a worse prognosis [7].
- Renal symptoms- Renal involvement may include proteinuria, glomerulonephritis, interstitial nephritis, and (but seldom) renal failure. Renal biopsy may show focal segmental glomerulonephritis, crescents or other necrotizing features. Systemic hypertension is also common.
- Constitutional Symptoms- Constitutional symptoms are very common in CSS and include weight loss of 10 to 20 lb, fevers (commonly higher than 38°C for 2 weeks), and diffuse myalgias and migratory polyarthralgias. Myositis may be present, with evidence of vasculitis on muscle biopsy.

- Other symptoms- Constitutional symptoms are very common in CSS and include weight loss of > 10% of the body weight, fever (commonly higher than 38° for 2 weeks), and diffuse

myalgias and migratory polyarthralgias. Myositis may be present with evidence of vasculitis on muscle biopsy. (Figure-1)

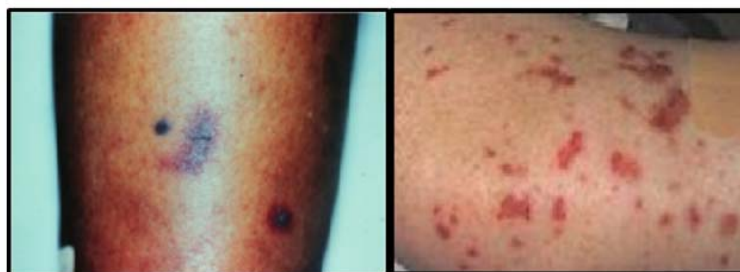

Figure 1- Skin involvement in Churg-Strauss syndrome (CSS). Biopsy showed vasculitis of the skin and abundant eosinophils, which are characteristic in CSS

### Clinical description

CSS has been divided into 3 distinct phases, which may or may not be sequential. The prodromal phase is characterized by asthma with or without allergic rhinitis. The second phase is marked by peripheral blood eosinophilia and eosinophilic tissue infiltration producing a picture similar to simple pulmonary eosinophilia (Loeffler's syndrome), chronic eosinophilic pneumonia, or eosinophilic gastroenteritis. The third, vasculitic phase may involve any organ of these organs: lung, heart, peripheral nervous system, kidney, lymph nodes, muscle, and skin. Skin involvement occurs in more than two thirds of patients.

History-The 3 phases—allergic, eosinophilic, and vasculitic—do not necessarily follow one another in any particular order. Symptoms depend on the phase and organ systems involved. A careful history should include medication usage, infectious symptoms, and/or pre-existing disease [8].

#### 1. Allergic phase of Churg-Strauss syndrome (allergic granulomatosis)

- Rhinitis, sinus pain, headache
- Cough
- Wheezing

#### 2. Eosinophilic phase of Churg-Strauss syndrome (allergic granulomatosis)

- General - Weight loss, fever, sweats
- Gastrointestinal - Abdominal pain, diarrhoea, bleeding
- Pulmonary - Cough

#### 3. Vasculitic phase of Churg-Strauss syndrome (allergic granulomatosis)

- General - Malaise, lassitude, fever
- Cardiac - Chest pain, dyspnoea
- Cutaneous - purpura, papules
- Pulmonary - Cough, hemoptysis
- Rheumatologic - Arthralgia, arthritis, myalgia
- Neurologic - Weakness, numbness

Physical- Clinical findings in Churg-Strauss syndrome (allergic granulomatosis) vary depending on the phase and organ systems involved [9].

#### 1. Allergic phase Churg-Strauss syndrome (allergic granulomatosis)

- Nasal polyps

- Wheezing
  - Cough
  - Rhinitis
  - Sinus tenderness
- #### 2. Eosinophilic phase Churg-Strauss syndrome (allergic granulomatosis)
- General - Weight loss, fever, sweats
  - Pulmonary - Cough, hemoptysis, rales, rhonchi
  - Gastrointestinal - Rebound, masses, obstruction, ascites, bleeding
- #### 3. Vasculitic phase Churg-Strauss syndrome (allergic granulomatosis)
- Constitutional symptoms - Fever, weight loss, adenopathy
  - Cardiac - Gallop, pericardial friction rub, jugular venous distension, peripheral edema
  - Pulmonary - Rales, rhonchi
  - Nervous system - Mononeuritis multiplex, diffuse peripheral neuropathy (most often in a glove-and-stocking distribution), loss of a visual field, cerebral hemorrhage, infarction
  - Renal - Mild proteinuria and hematuria
  - Genitourinary - Obstructive uropathy
  - Ocular - Episcleritis, panuveitis, marginal corneal ulceration, conjunctival infiltration, retinal infarction
  - Musculoskeletal - Joint swelling, muscle tenderness
  - Cutaneous
  - Erythematous macules and papules at times resembling urticaria: Papules are most commonly located symmetrically on the extremities and scalp.
    - Hemorrhagic lesions, including petechiae, extensive ecchymoses, and hemorrhagic bullae
    - Subcutaneous nodules, facial edema, and livedo reticularis.

### Causes

The etiology of Churg-Strauss syndrome (allergic granulomatosis) remains unclear. Several triggers are suspected, including environmental factors and medications. Inhaled allergens, vaccinations, infections (both bacterial and

parasitic), and prescription drugs (eg, carbamazepine, quinine, macrolides, corticosteroid-sparing drugs used to treat asthma) have all been implicated. A class of medications known as leukotriene inhibitors (montelukast, pranlukast, zafirlukast) has also been associated with Churg-Strauss syndrome (allergic granulomatosis). However, whether they are a direct cause or simply associated with the disease remains unclear at this time. Substantial tapering of corticosteroids with the use of leukotriene modifiers may allow unmasking of a previously unsuspected underlying disease, but some patients have never been on corticosteroids [10].

Another possible drug association with Churg-Strauss syndrome (allergic granulomatosis) is omalizumab, an anti-immunoglobulin E (IgE) antibody used to treat asthma. Once again, whether omalizumab use is truly responsible for Churg-Strauss syndrome (allergic granulomatosis) or simply unmasks it after corticosteroid tapering remains unclear [11, 12].

A foreign or infectious agent has been suggested to initiate an inflammatory cascade in an individual with a susceptible genetic background. The inflammation then leads to eosinophilia. High levels of cytotoxic enzymes released by eosinophils have been found in the urine, sera, and bronchoalveolar lavage fluids of Churg-Strauss syndrome (allergic granulomatosis) patients. These enzymes could result in oxidative tissue damage [13]. ANCA antibodies activate neutrophils in vitro, producing greater quantities of reactive oxygen species, which may result in endothelial cell damage. ANCA-positive patients typically have more prominent vasculitic manifestations [10]. However, the etiology of Churg-Strauss syndrome (allergic granulomatosis) remains incompletely understood, particularly in ANCA-negative patients.

### Pathology

Whereas immune complex deposition was initially favoured as the mechanism of vascular injury in CSS (immune-complex vasculitis), we know from more recent studies that most cases show no evidence of immune protein deposition in the vascular wall. In their series, Hattori et al. (1999) clearly demonstrated that IgG and C3d deposits are seen only occasionally in epineuronal vessel walls of the sural nerve (pauci immune vasculitis) [14]. Peen et al. (2000) recently demonstrated the presence of major basic protein in muscle fibers undergoing necrosis in a small bowel biopsy specimen from CSS and discussed the role of other eosinophilic granule proteins such as ECP (eosinophil cationic protein) and

eosinophil-derived neurotoxin (EDN) in the underlying pathological process [15]. These findings are in keeping with the high levels of serum ECP and the excretion of urinary EDN in patients with CSS and reflect ongoing in vivo eosinophil degranulation in active disease due to cell activation. In a case report these authors mention that serial measurements of plasma IL-4, IL-5, and IL-13, serum ECP and blood and urine EDN clearly revealed that IL-13 and EDN, but not IL-4, IL-5, or ECP, paralleled the elevated non-specific inflammatory markers. These results contrast with the findings of others concerning ECP and IL-5. In another case report, IL-5 and ECP were found to be elevated in active CSS and to decline after treatment with interferon  $\alpha$  (IFN- $\alpha$ ) in a therapy (GC plus cyclophosphamide (CP))-resistant situation. Investigating the cytokine production pattern of T-cell lines (TCL) in CSS, Kiene et al. (2001) found significant differences between CSS and WG with respect to phenotype and cytokine profiles, as well as between CSS and healthy controls (HC). Classification of the TCL according to phenotype and IFN- $\alpha$ : IL-4 ratio revealed a polarization toward a CD4+, Th0 pattern in patients with CSS, compared with a CD8+, Th1 pattern in patients with WG, and a CD4+, Th1 pattern in HC. Moreover, a significant increase in IL-4 and IL-13 production was found in TCL of patients with CSS versus TCL derived from patients with another granulomatous disease (e.g WG). In addition, there was a positive correlation between IL-4 production and the eosinophil count in CSS, further substantiating the hypothesis that CSS is a Th2-mediated disease, which in turn activates eosinophils and thus mediates the tissue damage [16]. In T cells the CD95/CD95 ligand system is a major pathway of apoptotic cell death and thus essential for prevention of lymphoproliferative disorders and autoimmunity. Soluble CD95 was identified as a survival factor for eosinophils which rescued them from apoptosis in the absence of growth factors in vitro. Given the role of eosinophils as effector cells in CSS, these findings suggest that soluble CD95 may be mechanistically involved in the disease. The same authors found recurrent oligoclonal T-cell expansions in 5 out of 7 CSS patients: all using a V $\beta$ -gene from the V $\beta$ 21 family associated with similar CDR3 motifs, indicating the predominance of T-cell clones with a similar specificity in these patients. This contrasts markedly with the clonal proliferation of type 2 helper T cells in hypereosinophilic syndrome. These abnormal T cell clones produce IL5 in idiopathic eosinophilia. (Figure- 2)

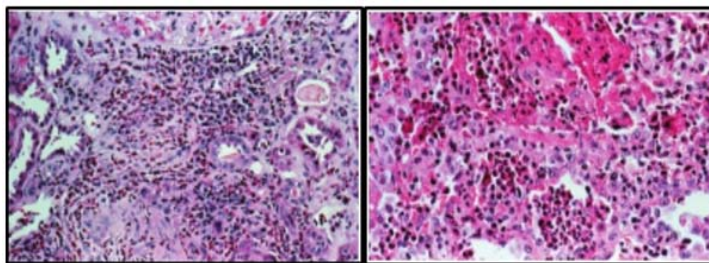


Figure 2- Two tissue biopsy specimens from patients with Churg-Strauss syndrome, demonstrating extensive infiltration of the organs by eosinophils. The image on the left is a kidney biopsy specimen showing eosinophil infiltration, and the one on the right shows a lung biopsy specimen with eosinophil infiltration

**Laboratory Abnormalities**

Systemic eosinophilia is the hallmark laboratory finding in patients with CSS and reflects the likely pathogenic role that the eosinophil plays in this disease. Eosinophilia greater than 10% is one of the defining features of this illness and may be as high as 75% of the peripheral white blood cell count. It is present at the time of diagnosis in more than 80% of patients but may respond quickly (often within 24 hours) to initiation of systemic corticosteroid therapy. Even in the absence of systemic eosinophilia, tissue eosinophilia may be present. Although not specific to CSS, ANCA are present in up to two thirds of patients, mostly with a perinuclear staining pattern [17]. Other nonspecific laboratory abnormalities that may be present in patients with CSS include a marked elevation in erythrocyte sedimentation rate, normochromic normocytic anaemia, elevated IgE levels, hypergammaglobulinemia, and positive rheumatoid factor and antinuclear antibody. Broncho-alveolar lavage often reveals significant eosinophilia, which may be seen in other eosinophilic lung diseases. Similarly, pulmonary function testing often reveals an obstructive defect similar to asthma.

**Radiographic Features**

Radiographic chest abnormalities are extremely common in CSS and consist of bilateral nonsegmental, patchy infiltrates that often migrate and that may be interstitial or alveolar in appearance. Reticulonodular and nodular disease without cavitation can be seen, as can pleural effusions and hilaradenopathy. The most common thin-section computed tomographic (CT) findings include bilateral ground-glass opacity and airspace consolidation that is predominantly subpleural and surrounded by the ground-glass opacity [18]. Other CT findings include bronchial wall thickening, hyperinflation, interlobular septal thickening, lymph node enlargement, and pericardial and pleural effusions. Angiography is often used diagnostically and may show signs of vasculitis in the coronary, central nervous system, and peripheral vasculature.

**Diagnosis and Differential Diagnosis**

Several criteria have been used to classify CSS. However, to diagnose this condition, a combination of clinical, laboratory, pathologic, and radiographic criteria must be used. Generally, the presence of vasculitis and eosinophilia in an individual with airway obstruction is enough to make a diagnosis of CSS. Although a biopsy specimen with eosinophilic vasculitis is the best diagnostic test and desired in most cases, noninvasive surrogates, including electromyogram (EMG), nerve conduction studies, or perinuclear ANCA, often can be used to support the diagnosis. EMG and nerve conduction studies are done when there is muscle pain or weakness or evidence of neuropathy. Testing is done in affected areas but may be considered for no affected areas if there is any suspicion of abnormality in other loci. The most commonly biopsied sites include the skin, nerve, and muscle, although pathologic specimens may be obtained from biopsy of any affected organ system, including the lung (by open-lung or thoracoscopic biopsy; transbronchial biopsy is generally not helpful), heart (by endomyocardial biopsy), gastrointestinal tract (endoscopically), liver, or kidney. When diagnosing CSS, it is generally best to satisfy at least four of the six ACR criteria, which yields a sensitivity of 85% and a specificity of 99.7%. However, several other eosinophilic lung conditions may present with similar findings and constitutional symptoms (Table). For instance, patients with allergic bronchopulmonary aspergillosis or chronic eosinophilic pneumonia may present with airway obstruction, sinus disease, eosinophilia, and pulmonary infiltrates, but they do not necessarily have end-organ evidence of vasculitis that would differentiate them as having CSS. Other conditions in the differential diagnosis of CSS include Wegener's granulomatosis, drug reactions, bronchocentric granulomatosis, eosinophilic granuloma, fungal and parasitic infections, and malignancy. Although each of these disorders may meet ACR criteria for CSS, the treatment algorithm differs significantly for each of these conditions; therefore, it is extremely important to obtain tissue when the diagnosis is unclear before proceeding with therapy (Table-1).

Table 1. Diseases Associated With Pulmonary Infiltrates and Eosinophilia in the Differential Diagnosis of Churg-Strauss Syndrome

S.No	Associated Disease
1	Churg-Strauss syndrome
2	Acute eosinophilic pneumonia
3	Allergic bronchopulmonary aspergillosis (ABPA)
4	Asthma
5	Bronchocentric granulomatosis
6	Chronic eosinophilic pneumonia
7	Eosinophilic granuloma/histiocytosis X
8	Drug reactions
9	Infections: bacterial, fungal, mycobacterial, and parasitic
10	Malignancy
11	Wegener's granulomatosis

**Treatment**

The use of cytotoxic agents and cyclosporine in the treatment of autoimmune diseases was reviewed following a Clinical Staff Conference held in 1997 at the National Institutes

of Health, USA. Churg-Strauss syndrome (CSS) is typically a corticosteroid-responsive disease; hence, they are first-line therapeutic agents. Most patients respond to corticosteroid monotherapy. Intravenous corticosteroids should be considered for patients with extensive disease. Dramatic

response to therapy may be observed with improvement in eosinophilia counts, reduction of the erythrocyte sedimentation rate (ESR), and reduction in muscle enzyme levels within 1-2 weeks of initiation of treatment. Corticosteroids may be tapered once clinical improvement occurs. Importantly, note that patients with Churg-Strauss syndrome (allergic granulomatosis)-related neuropathy respond more slowly to treatment. Residual asthma or other symptoms may require the continuation of low-dose prednisone therapy. Cyclophosphamide should be initiated in severely ill patients who do not respond to initial therapy. Patients with life-threatening disease or those at risk of organ failure are potential candidates. The addition of cyclophosphamide appears to improve outcomes and reduces the incidence of relapses. For patients with systemic disease who are not at risk for major organ failure or death, methotrexate (MTX) may be given as a corticosteroid-sparing agent to reduce the cumulative dose. Other immune-modulatory medications include azathioprine (AZA) and mycophenolatemofetil, which may also be used as corticosteroid-sparing agents [19]. Agents that block tumour necrosis factor (TNF), such as infliximab and etanercept, have been used for a limited period in severe life-threatening cases. These agents, when combined with corticosteroids or other immunomodulatory agents, greatly increase the risk of infection due to immunosuppression. More data are needed to determine whether these drugs have a favourable risk-to-benefit ratio for use in Churg-Strauss syndrome (allergic granulomatosis) patients. Another infrequently used therapy is recombinant interferon (IFN) alfa, which can be effective when given on a short-term basis in otherwise refractory cases. One anecdotal case report has described the use of rituximab in a patient with recalcitrant Churg-Strauss syndrome (allergic granulomatosis). In the future however the targeting of cytokines, e.g. with antibodies against IL5 as is done in asthma, may improve our treatment protocols [20, 21].

#### Medications-

- a. Corticosteroids- Methylprednisolone, Prednisolone.
- b. Immunomodulators- Methotrexate, Azathioprine, Cyclosporine, Interferon alfa 2a and 2b.
- c. Alkylating agents- Cyclophosphamide, Chlorambucil.
- d. Anti-TNF agents- Infliximab, Etanercept.

#### Prognosis

Most patients diagnosed with CSS have previously been diagnosed with asthma, rhinitis, and sinusitis and have received treatment with inhaled or systemic corticosteroids. Because these agents are also the initial treatment of choice for CSS, institution of these therapies in patients with CSS who are believed to have severe asthma may delay the diagnosis of CSS because signs of vasculitis may be masked [22]. Treatment with corticosteroids (starting at 1 mg/kg and tapering over 3 to 6 months) dramatically alters the course of CSS: up to 50% of those who are untreated die within 3 months of diagnosis, 15 whereas treated patients have a 6-year survival of over 70%. Common causes of death include heart failure, cerebral hemorrhage, renal failure, and gastrointestinal bleeding. Recent data suggest that clinical remission may be obtained in over 90% of treated patients; approximately 25% of those patients may relapse, often due to corticosteroid

tapering, with a rising eosinophil count heralding the relapse [23]. Myocardial, gastrointestinal, or renal involvement most often portends a poor prognosis. In such cases, or if there is no improvement with standard doses of corticosteroids, treatment with higher doses (1–1.5 mg/kg) of corticosteroids for longer time periods or the addition of cytotoxic agents such as cyclophosphamide is often warranted. Although survival does not differ between patients treated with cyclophosphamide and those not treated with cyclophosphamide, its use is associated with a reduced incidence of relapse and an improved clinical response to treatment [24, 25].

#### Conclusion

CSS is a relatively rare multisystem disorder that is characterized by airway obstruction, pulmonary infiltrates, systemic eosinophilia, sinusitis, neuropathy, constitutional symptoms, and eosinophilic vasculitis of several organs, including the lungs, heart, gastrointestinal tract, and kidneys. It is important to establish a tissue diagnosis by biopsy to exclude other diseases in the differential diagnosis, because treatment options differ significantly from those of other eosinophilic lung diseases. Untreated, CSS may have a dire prognosis, but treatment with corticosteroids or cytotoxic agents, or both, usually results in clinical remission of the disease. Although it is believed that the eosinophil plays a central role in the pathogenesis of CSS, the etiology of this syndrome remains unknown. Reports of CSS cases in association with the use of leukotriene modifiers and inhaled corticosteroids have increased, but no causative role for these agents in the pathogenesis of CSS has been firmly established. Because the etiology of CSS remains unclear, it is important for physicians to report suspected cases to pharmaceutical companies and to the US Food and Drug Administration. Careful diagnosis and thorough understanding of CSS will enable clinicians to make sound treatment decisions and to provide effective care for patients with this disease.

#### References

1. Churg, J. and L. Strauss. 1951. Allergic granulomatosis, allergic angiitis and periarteritis nodosa. *Am J Pathol.* 27: 277-301.
2. Rackemann, F.M. and E.J. Greene. 1939. Periarteritis nodosa and asthma. *Trans Assoc Am Physicians.* 54:112.
3. Masi, A.T., G.G. Hunder. and J.T. Lie. 1990. The American College of Rheumatology 1990 criteria for the classification of Churg-Strauss syndrome (allergic granulomatosis and angiitis). *Arthritis Rheum.* 33:1094-1100.
4. Pagnoux, C., P. Guilpain. And L. Guillevin. 2007. Churg-Strauss syndrome. *Curr Opin Rheumatol.* 19(1):25-32.
5. Guillevin L., P. Cohen. and M. Gayraud. 1999. Churg Strauss syndrome: clinical study and long-term follow-up of 96 patients. *Medicine.* 78:26-37.
6. Lanham J.G., K.B. Elkon. and C. D. Pusey. 1984. Systemic vasculitis with asthma and eosinophilia: a clinical approach to the Churg-Strauss syndrome. *Medicine.* 63:65-81.
7. Conron, M. and H.L.C. Beynon. 2000. Churg-Strauss syndrome. *Thorax.* 55:870-877.

8. Neumann T., B. Manger. M.Schmid. C. Kroegel. A.Hansch. And W.A. Kaiser.2009 Cardiac involvement in Churg-Strauss syndrome: impact of endomyocarditis. *Medicine (Baltimore)*.88(4):236-43.
9. Chen K.O. and J.A. Carlson.2008. Clinical approach to cutaneous vasculitis". *Am J Clin Dermatol*.9:71-92.
10. Kahn, J.E. O.Bletry.L. and Guillevin. 2008. Hypereosinophilic syndromes. *Best Pract Res Clin Rheumatol*. 22 (5):863-82.
11. Wong, D.A., M.K. Miller.And L. Lawrence-Miyasaki.2009. Churg-Strauss Syndrome in patients treated with omalizumab". *Chest [serial online]*. Available at <http://www.chestjournal.org/content/early/2009/05/01/chest.108-2990.long>.
12. Keogh, K.A. and U. Specks. Churg-Strauss syndrome.2003.Clinical presentation, antineutrophil cytoplasmic antibodies, and leukotriene receptor antagonists". *Am J Med*.115(4):284-90.
13. Peen, E., P. Hahn. G. Lauwers.R.C. Williams Jr. and G. Gleich. G.M. Kephart.2000. Churg-Strauss syndrome: localization of eosinophil major basic protein in damaged tissues. *Arthritis Rheum*.43(8):1897-1900.
14. Hattori, N., M. Ichimura. M. Nagamatsu. M. Li. K. Yamamoto. K. Kumazawa.T. Mitsuma.And G. Sobue. 1999. Clinicopathological features of Churg-Strauss syndrome -associated neuropathy. *Brain*.122:427-39.
15. Peen, E., P. Hahn. G. Lauwers. R.C. Williams Jr. G. Gleich. And G.M. Kephart. 2000. Churg-Strauss syndrome. Localization of eosinophil major basic protein in damaged tissues". *Arthritis Rheum*. 43:1897-900.
16. Kiene, M, E. Csernok. A. Muller. C. Metzler. A. Trabandt. And W.L. Gross.2001. Elevated interleukin-4 and interleukin-13 production by T cell lines from patients with Churg-Strauss syndrome. *Arthritis Rheum*.44:469-73.
17. Hagen, E.C., M.R. Daha. And J. Hermans.1998. The diagnostic value of standardized assays for antineutrophil cytoplasmic antibodies in idiopathic systemic vasculitis. *Kidney Int*. 53:743-753.
18. Choi, Y.H., J.G. Im. And B.K. Han. 2000. Thoracic manifestations of Churg-Strauss syndrome. *Chest*.117:117-124.
19. Gota, C.E. and B.F. Mandell.2008. Systemic necrotizing vasculitis. *Dermatology in General Medicine*". New York: McGraw Hill.7<sup>th</sup> edition:1606-1616/165.
20. Piette W.W.2004. Primary systemic vasculitis. In: Sontheimer R.D. Provost T.T. Cutaneous manifestations of rheumatic diseases. 2nd. New York: Lippincott Williams & Wilkins.2<sup>nd</sup> edition: 159-196.
21. Kaushik, V.V., H.V. Reddy. And R.C. Bucknall.2006. Successful use of rituximab in a patient with recalcitrant Churg-Strauss Syndrome. *Ann Rheum Dis* 65(8):1116-7.
22. Oh, M.J., J.Y. Lee. N.H. Kwon. D.C. Choi.2006. Churg-Strauss syndrome. the clinical features and long-term follow-up of 17 patients. *J Korean Med Sci*. 21(2):265-71.
23. Allen, J.N. and W.B. Davis. 1994. Eosinophilic lung diseases. *Am J Respir Crit Care Med*. 150:1423-1438.
24. Watts, R.A., S.E. Lane. And G. Bentham.D.G.I. Scott. 2000. Epidemiology of systemic vasculitis. *Arthritis Rheum*. 43:414-419.
25. Eustace, J.A., T. Nadasdy. And M. Choi.1999. Disease of the month. The Churg Strauss Syndrome. *J Am Soc Nephrol*. 10:2048-55.