

# Axillobifemoral Bypass: A Brief Surgical and Historical Review

Priti L. Mishall, MD,<sup>1</sup> Jason D. Matakas,<sup>1\*</sup> Keara English,<sup>1\*</sup> Katherine Allyn,<sup>1\*</sup> Diane Algava,<sup>1\*</sup> Ruth A. Howe, MSc,<sup>2</sup> and Sherry A. Downie, PhD<sup>1,3</sup>

<sup>1</sup> Department of Anatomy and Structural Biology, Albert Einstein College of Medicine, Bronx, NY.

<sup>2</sup> Department of Cell Biology, Albert Einstein College of Medicine, Bronx, NY.

<sup>3</sup> Department of Physical Medicine and Rehabilitation, Albert Einstein College of Medicine, Bronx, NY.

\* These authors contributed equally to this work.

Peripheral artery disease (PAD) occurs when plaque accumulates in the arterial system and obstructs blood flow. Narrowing of the abdominal aorta and the common iliac arteries due to atherosclerotic plaques restricts blood supply to the lower limbs. Clinically, the lower limb symptoms of PAD are intermittent claudication, discoloration of the toes, and skin ulcers, all due to arterial insufficiency.

Surgical revascularization is the primary mode of treatment for patients with severe limb ischemia. The objective of the surgical procedure is to bypass a blockage in an occluded major vessel by constructing an alternate route for blood flow using an artificial graft. This article presents information on aortoiliac reconstruction, with an emphasis on axillobifemoral bypass grafting.

## PERIPHERAL ARTERY DISEASE

Peripheral artery disease (PAD) is defined as a narrowing of arteries that are neither cardiac nor intracranial. It is a growing public health concern affecting 8.5 million people in the United States and 200 million people worldwide (Kullo and Rooke, 2016). The major mechanism of PAD is atherosclerosis, a disease in which plaque accumulates inside the arterial intima. Plaque accumulation obstructs the lumen of the vessel causing a reduction in blood flow, which leads to diminished oxygen supply to the recipient tissues. Certain natural branch points and curvatures within the vascular tree are more susceptible to atherosclerosis due to turbulent blood flow and shear stress. Current understanding suggests that turbulent blood flow at very low shear stress compromises the integrity of the endothelial lining. Such hemodynamic changes appear to be linked to the development of focal atherosclerosis (Davies et al., 1986). Areas known to be frequently affected include the aorta, as well as the coronary and carotid arteries (VanderLaan et al., 2003). Other causes of PAD include inflammatory vasculitis and non-inflammatory arteriopathies (Kullo and Rooke, 2016). The main risk factors for developing PAD are diabetes mellitus and smoking (Kullo and Rooke, 2016). The incidence of PAD increases with age; 20% of people over 60 years old have some degree of PAD (National Clinical Guideline Centre, 2012).

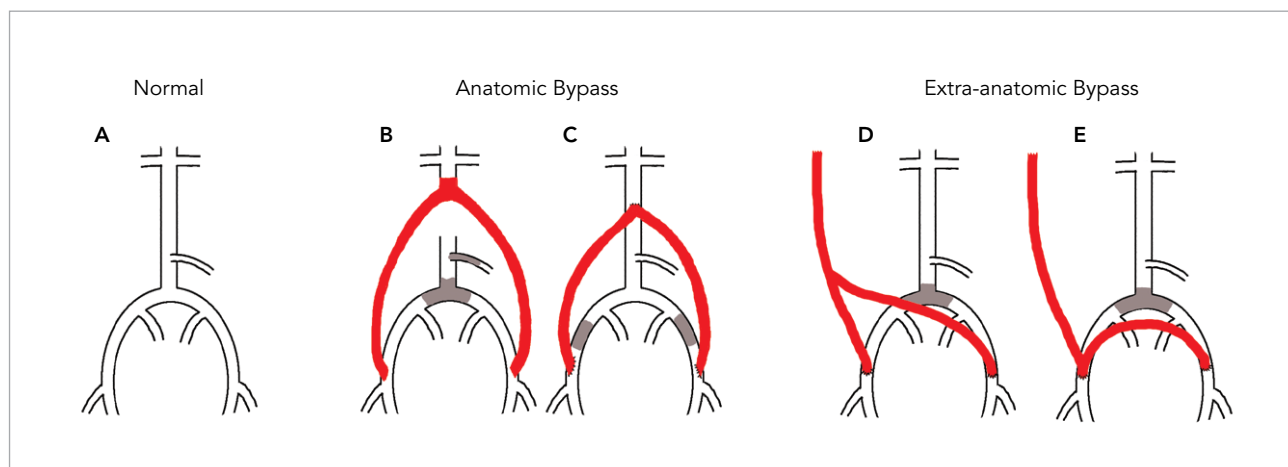
Symptomatic presentation of PAD ranges from leg discomfort and pain at rest, to intermittent claudication, to critical limb ischemia resulting in gangrene and subsequent amputation (Kullo and Rooke, 2016). Other signs of PAD include differences in color and/or temperature of the lower limbs compared with other body parts, as well as pallor on elevation of the lower limb above 60° (Swartz, M. H. 2006).

Diagnosis of PAD typically occurs after symptoms are reported and a thorough physical examination has been

performed. Diagnostic tests include the ankle-brachial index (ABI) test, Doppler ultrasound, the treadmill test, magnetic resonance angiogram, and arteriogram (National Heart, Lung, and Blood Institute, 2015). Upon diagnosis, PAD can be categorized using a number of classification systems. One of the most common, and the most relevant to lower limb ischemia, is the Rutherford classification system (Hardman et al., 2014). This scheme, developed in 1986, distinguishes between PAD-related chronic and acute limb ischemia. The chronic classification system relies on a combination of objective criteria (e.g. ABI) and symptomatic description in determining the classification of PAD. Symptomatic descriptions range from asymptomatic, to increased claudication, to tissue loss (Hardman et al., 2014).

The ABI is the relationship between systolic blood pressure in the ankle and systolic blood pressure in the arm. The normal range is 1.00–1.30. An ABI under 0.90 is indicative of PAD (Kullo and Rooke, 2016). A low ABI suggests that the systolic blood pressure is lower in the legs than in the arms, which indicates possible arterial blockage. The ABI, ultrasound imaging, and treadmill tests are all non-invasive methods of diagnosis.

The objectives of PAD management are to alleviate symptoms, to reduce the risk of adverse cardiovascular events, and to preserve limb function. Smoking cessation, dietary modifications, and other healthy lifestyle changes can improve patient outcomes. Surgical revascularization is required when behavioral modifications are not effective. Often, the initial treatment approach is balloon angioplasty with or without stenting to widen the arterial lumen and improve blood flow (Slovut and Lipsitz, 2012). When an endovascular approach is not feasible, open surgical intervention is necessary to restore adequate blood flow to the lower limbs. The three main open surgical procedures are aortofemoral bypass grafting (AOFBG), axillofemoral bypass



**Figure 1** | Aortoiliac reconstruction bypass configurations. A. Normal arterial configuration. B. Aortoiliac graft for inferior mesenteric and common iliac blockage. C. Aortoiliac graft for external iliac blockage. D. Axillobifemoral graft (early version). E. Axillobifemoral graft (current version).

grafting (AXFBG), and aortoiliac endarterectomy (Slovut and Lipsitz, 2012). AOFBG is classified as an anatomic procedure, meaning that the graft is constructed alongside the diseased artery using a transabdominal or retroperitoneal approach. AXFBG is classified as extra-anatomic because the graft is placed subcutaneously and, therefore, does not have spatial relation to the diseased artery throughout most of its length (Slovut and Lipsitz, 2012). Graft configuration is determined based on the location of the occlusion and surgical risk of the individual patient. Figure 1 demonstrates several bypass configurations. The present article focuses on the history and surgical techniques of the AXFBG bypass and refers to Matakas et al. (2016), a reflection presented in this issue on the discovery of an AXbiFBG upon cadaveric dissection.

#### HISTORICAL CONTEXT AND SURGICAL TECHNIQUE OF AXILLOFEMORAL BYPASS

Prior to the development of the AXFBG, other arterial graft procedures were used to restore adequate blood flow around an area of obstruction. For example, in 1953, Freeman and Leeds published an article describing how the splenic artery was used to bypass the abdominal aorta. In 1960, cross-over grafts were described between the common iliac arteries (McCaughan and Kahn, 1960), and in 1961, thoracic aorta to femoral artery bypass grafts were described (Blaisdell et al., 1961). These procedures were successful in patients with unilateral occlusion; however, they were of limited use for patients with high surgical risk, or those with bilateral occlusion. In 1963, Blaisdell and Hall reported that they successfully performed the first AXFBG. In fact, they performed the procedure on three patients who presented with high surgical risk and bilateral occlusive disease. In one of the patients, AXFBG was performed using only local anesthesia, highlighting the utility of AXFBG in patients who could not tolerate general anesthesia. Further, AXFBG provided a major advantage over other procedures by avoiding abdominal incision and cross-clamping of the

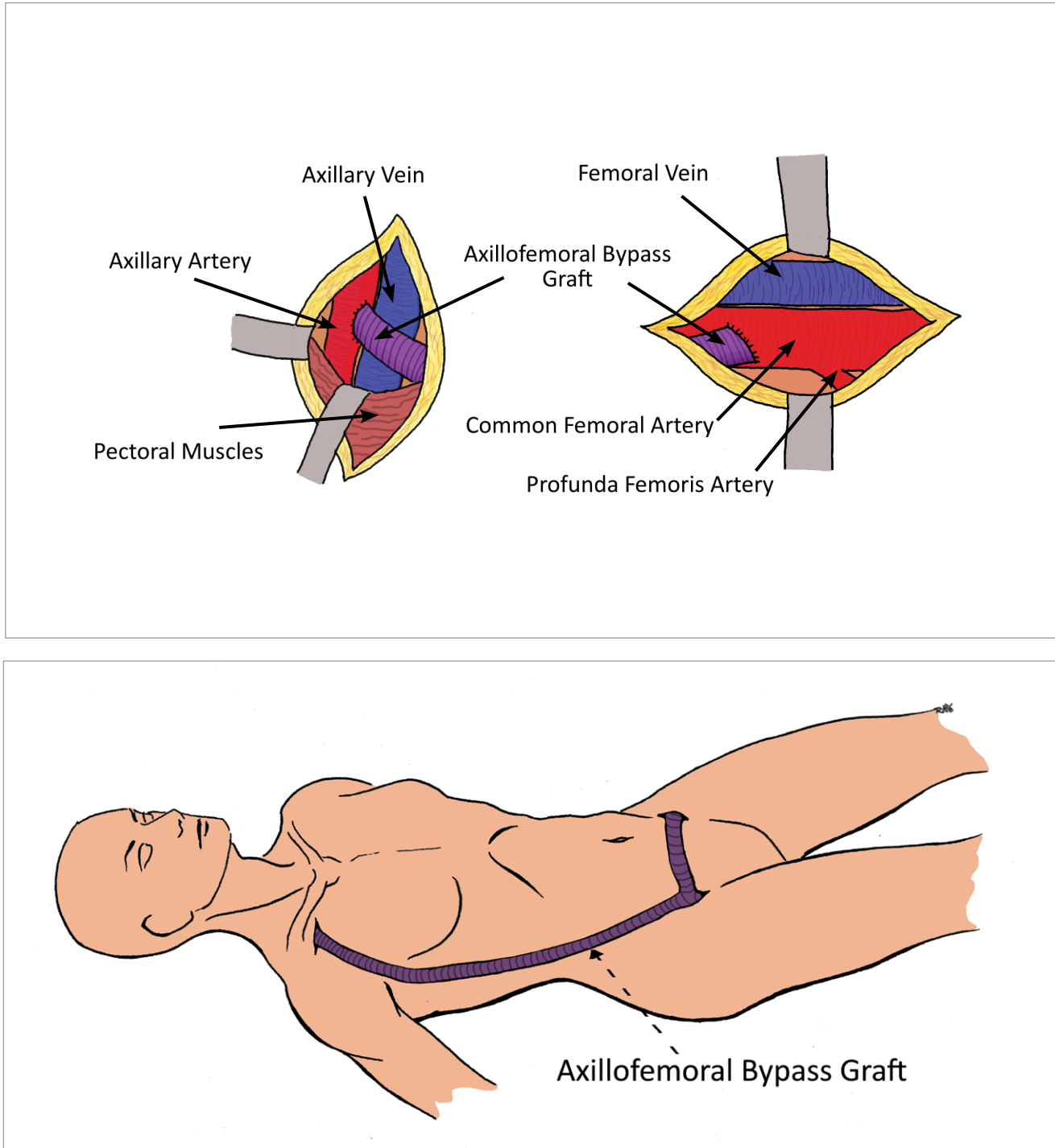
aorta, both of which entail significant physiologic stress to the patient (Blaisdell and Hall, 1963; Al Wahbi, 2010).

In 1966, Sauvage and Wood adapted the AXFBG procedure to accommodate bilateral occlusions and performed the first axillobifemoral bypass graft (AXbiFBG). In the original configuration of these grafts, the bifurcation was placed at the level of the umbilicus (Figure 1D). The flow rates differed to the ipsilateral and contralateral limbs, which affected the patency of these early grafts (Ray et al., 1979). Subsequently, the configuration was changed so that the bifurcation occurred at the femoral hood of the graft (Ray et al., 1979), and this configuration continues to be used today.

Early AXbiFBG grafts were made of crimped, non-supported Dacron®, but problems arose with thromboses due to compression of the graft during sleep (Kenney et al., 1982). Kenney later demonstrated that the use of non-crimped grafts with external support improved the graft's four-year patency rate because they were incompressible (Kenney et al., 1982). Burrell et al. (1982) compared the effectiveness of Dacron® versus polytetrafluoroethylene (PTFE) on graft patency, and found no significant difference in patency rates. These conclusions were replicated and confirmed by Donaldson et al., in 1986.

Other attempts to prevent clot formation in grafts included bonding various agents to the internal surface of the graft material. Some of the agents used were gelatin, collagen, and heparin (Roll et al., 2008; Takagi et al., 2010). It is unclear whether these enhanced grafts had any effect on overall patency rates, as there is limited literature available comparing the functionality of different bonding agents.

The AXbiFBG procedure has been described in the literature several times with slight variations related to the surgeon's preference (Blaisdell and Hall, 1963; Sauvage and Wood, 1966; Mannick and Nabseth, 1968; Al-Wahbi, 2010;



**Figure 2** | Axillobifemoral bypass (AXbiFBG) procedure. Illustrated is the axillary anastomosis (top left), femoral anastomosis (top right), and general configuration (bottom). (After Mannick, J. A., and Nabseth D. C. (1968)).

Slovut and Lipsitz, 2012; Jun and Lopez, 2015). The procedure is typically performed with the patient under general anesthesia, but can be performed with local anesthetic, with or without sedation, according to the needs of the patient (Al-Wahbi, 2010).

A schematic for placing the AXbiFBG is depicted in Figure 2. Proximally, a horizontal incision is made just below the clavicle and a small portion (2.5–5 cm) of the proximal axillary artery is freed from the surrounding tissues. The pectoralis major and/or minor muscles are split to facilitate this dissection. Distally, just below the ipsilateral inguinal ligament, a vertical incision is made and the femoral sheath is entered. The common femoral artery is freed and inspected, along with the superficial and profunda femoral arteries. These arteries are evaluated for disease and local endarterectomy is performed if necessary. If placement of a bifemoral shunt is required, the same inguinal technique is repeated on the contralateral side to access and assess that femoral artery (Sauvage and Wood, 1966).

With the proximal (axillary) and distal (femoral) arteries exposed, a subcutaneous tunnel is made along the midaxillary line, connecting the two arteries. When a bifemoral graft is needed, a horizontal tunnel is prepared connecting the two common femoral arteries. The graft is carefully passed through the tunnel and longitudinal arteriotomies are performed to anastomose the graft and the artery (Blaisdell and Hall, 1963). While premade AXbiFBGs are now available, the bifemoral portion can also be anastomosed to an AXFBG (Jun and Lopez, 2015).

Pre-operative considerations for AXFBG include assessment of the axillary arteries to ensure there is no stenosis or other disease. Resting ankle-brachial pressure indices are taken and the patient's surgical risk is assessed. Those patients who have high surgical risk due to prior abdominal surgeries, age, or other health conditions that would preclude them from an anatomic bypass (AOFBG), are frequently able to withstand AXFBG.

Complications of AXFBG include graft thrombosis or infection (Passman et al., 1996; Ray et al., 1979; Burrell et al., 1982; Donaldson et al., 1986), seroma (Donaldson et al., 1986), plexus lesions (Kempczinski and Penn, 1978), and arterial steal syndrome (Kempczinski and Penn, 1978). Patients may need to undergo a thrombectomy or total graft replacement in order to maintain patency. Complications are most likely to occur within the first 36 months following surgery, with the average being 21.5 months (Donaldson et al., 1986). In some cases, if the graft cannot be fixed, patients will undergo amputation (Donaldson et al., 1986). Due to the possibility of developing these severe complications, some have called into question the usefulness of AXFBG (Donaldson et al., 1986). Despite the complication rate, the five-year primary graft patency rate has been reported in the range of 54% (Martin and Katz, 2000) to 80.4% (Passman et al., 1996; Ray et al., 1979). In patients that undergo thrombectomy, as many as 97% can expect no further complications over the following five-year period (Burrell et al., 1982).

Post-operative care for AXFBG patients may include the use of anti-thrombotic agents, particularly in patients who require multiple reoperations to maintain graft patency (Donaldson et al., 1986). Some evidence has shown that anti-platelet medications such as aspirin can be beneficial for patients with synthetic grafts (Slovut and Lipsitz, 2012; Dorffler-Melly et al., 2003). The use of warfarin, however, has been associated with an increased risk of hemorrhage (Slovut and Lipsitz, 2012). Patients should be routinely monitored for recurrence of symptoms, which indicates the development of thrombosis (Slovut and Lipsitz, 2012).

## SUMMARY

PAD can be managed using multiple modalities. However, in people with severe disease, surgical bypass grafts are the standard of care. This report discusses the history and surgical techniques of the extra-anatomic procedures known as AXFBG and AXbiFBG. Both the literature and the evidence from the case report (Matakas et al., 2016) support the utility of axillobifemoral bypass graft in restoring adequate blood flow to the lower limbs. The first-year medical students who discovered an AXbiFBG in their anatomy cadaver were so curious about the graft, and the disease that it was used to treat, that they were inspired to learn more and, ultimately, to share what they learned with others.

**Corresponding Author:** Priti L. Mishall, MD, PG CertMedEd, MBBS (priti.mishall@einstein.yu.edu).

**Author Contributions:** JDM, KE, KA, DA equally contributed to the literature review and manuscript preparation. JDM and RAH drew the medical illustrations. PLM and SD edited, reviewed, and provided guidance during the preparation of the manuscript.

**Acknowledgements:** RAH was supported by grants from the National Institutes of Health, T32 GM007288 and F30 HL 132613 during this study.

**Disclosure:** The authors have completed and submitted the ICMJE Form for Disclosure of Potential Conflicts of Interest. The authors have no conflicts of interest to report.

## References

- Al-Wahbi, A. (2010). Axillofemoral bypass with local anesthesia: A way forward to enable limb salvage in high-risk patients. *Local Reg Anesth*, 3, 129–132.
- Blaisdell, F. W., Demattei, G.A., and Gauder, P. J. (1961). Extraperitoneal thoracic aorta to femoral bypass graft as replacement for an infected aortic bifurcation prosthesis. *Am J Surg*, 102, 583–585.
- Blaisdell, F. W. and Hall, A. D. (1963). Axillary-femoral artery bypass for lower extremity ischemia. *Surgery*, 54, 563–568.
- Burrell, M. J., Wheeler, J.R., Gregory, R.T., Synder, S.O. Jr., Gayle, R.G., and Mason, M.S. (1982). Axillofemoral bypass: A ten-year review. *Ann Surg*, 195(6), 796–799.
- Davies, P. F., Remuzzi, A., Gordon, E. J., Dewey, C. F., Jr., & M. A., Jr. (1986). Turbulent fluid shear stress induces vascular endothelial cell turnover in vitro. *Proc Natl Acad Sci*, 83(7), 2114–2117.
- Donaldson, M. C., Louras, J.C., and Bucknam, C.A. (1986). Axillofemoral bypass: A tool with a limited role. *J Vasc Surg*, 3(5), 757–763.
- Dorffler-Melly, J., Buller, H.R., Koopman, M.M., and Prins, M.H. (2003). Antithrombotic agents for preventing thrombosis after infrainguinal arterial bypass surgery. *Cochrane Database Syst Rev*, (4), CD000536.
- Freeman, N. E. and Leeds, F. H. (1953). Resection of aneurysms of the abdominal aorta with anastomosis of the splenic to the left iliac artery. *Surgery*, 34(6), 1021–1031.

- Hardman, R. L., et al. (2014). Overview of classification systems in peripheral artery disease. *Semin Intervent Radiol*, 31(4), 378–388.
- Jun Lee, C., and Lopez Rowe, V. (2015, August 13). Axillofemoral bypass. Retrieved March 28, 2016, from [http://emedicine.medscape.com/article/1895225overview](http://emedicine.medscape.com/article/1895225overviewhttp://emedicine.medscape.com/article/1895225-overview)
- Kempczinski, R. and Penn, I. (1978). Upper extremity complications of axillofemoral grafts. *Am J Surg*, 136(2), 209–211.
- Kenney, D. A., Sauvage, L.R., Wood, S.J., Berger, K., Davis, C.C., Smith, J.C., Rittenhouse, E.A., Hall D.G., and Mansfield, P.B. (1982). Comparison of noncrimped, externally supported (EXS) and crimped, nonsupported Dacron prostheses for axillofemoral and above-knee femoropopliteal bypass. *Surgery*, 92(6), 931–946.
- Kullo, I. J. and Rooke, T. W. (2016). Clinical Practice. Peripheral Artery Disease. *N Engl J Med*, 374(9), 861–871.
- Mannick, J. A. and Nabeth, D. C. (1968). Axillofemoral bypass graft. A safe alternative to aortoiliac reconstruction. *N Engl J Med*, 278 (9), 461–466.
- Matakas, J. D., English, K., Allyn K., Algava D., et al. (2016). Axillobifemoral bypass graft: A student dissection experience. *EJBM*, 31(1), 31–33. .
- Martin, D. and Katz, S. G. (2000). Axillofemoral bypass for aortoiliac occlusive disease. *Am J Surg*, 180(2), 100–103.
- McCaughan, J. J. and Kahn, S. F. (1960). Cross-over Graft for Unilateral Occlusive Disease of the Ilio-Femoral Arteries. *Ann Surg*, 151(1), 26–28.
- National Clinical Guideline Centre. Lower limb peripheral arterial disease: diagnosis and management. London (UK): National Institute for Health and Clinical Excellence (NICE); 2012 Aug. 28 p.12 (Clinical guideline; no. 147).
- National Heart, Lung, and Blood Institute (2015). What is Peripheral Artery Disease? Retrieved March 27, 2016 from <https://www.nhlbi.nih.gov/health/health-topics/topics/pad#>.
- Passman, M. A., Taylor, L.M., Moneta, G.L., Edwards, J.M., Yeager, R.A., McConnell, D.B., and Porter, J.M. (1996). Comparison of axillofemoral and aortofemoral bypass for aortoiliac occlusive disease. *J Vasc Surg*, 23(2), 263–269; discussion 269–271.
- Ray, L. I., O'Connor, J.B., Davis, C.C., Hall, D.G., Mansfield, P.B., Rittenhouse, E.A., Smith, J.C., Wood, S.J., and Sauvage, L.R. (1979). Axillofemoral bypass: A critical reappraisal of its role in the management of aortoiliac occlusive disease. *Am J Surg*, 138(1), 117–128.
- Roll, S., Muller-Nordhorn, J., Keil, T., Scholz, H., Eidt, D., Greiner, W., and Willich, S.N. (2008). Dacron vs. PTFE as bypass materials in peripheral vascular surgery—systematic review and meta-analysis. *BMC Surg*, 8, 22.
- Sauvage, L. R. and Wood, S. J. (1966). Unilateral axillary bilateral femoral bifurcation graft: A procedure for the poor risk patient with aortoiliac disease. *Surgery* 60(3), 573–577.
- Slovut, D. P. and Lipsitz, E. C. (2012). Surgical technique and peripheral artery disease. *Circulation*, 126(9), 1127–1138.
- Swartz, M. H. (2006). Textbook of Physical Diagnosis History and Examination (5th ed) Philadelphia, PA: Saunders Elsevier.
- Takagi, H., Goto, S.N., Matsui, M., Manabe, H., and Umemoto, T. (2010). A contemporary meta-analysis of Dacron versus polytetrafluoroethylene grafts for femoropopliteal bypass grafting. *J Vasc Surg*, 52(1), 232–236.
- VanderLaan, P. A., et al. (2004). Site specificity of atherosclerosis: site-selective responses to atherosclerotic modulators. *Arterioscler Thromb Vasc Biol*, 24(1), 12–22.