

ENDGAMES

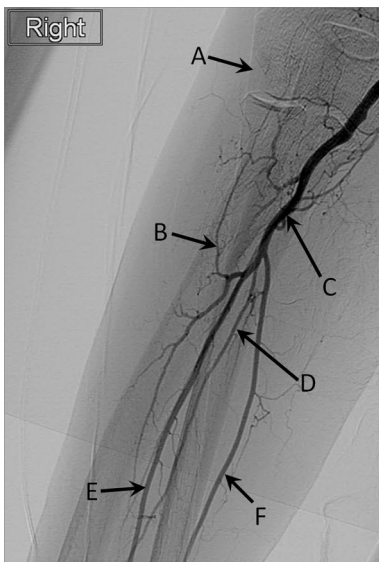
ANATOMY QUIZ

Digital subtraction angiography of the right arm

Rahil H Kassamali *specialist registrar in clinical radiology*

Heart of England NHS Foundation Trust, Birmingham B9 5SS, UK

What are the structures labelled A-F in this digital subtraction angiography image of the right arm centred on the elbow?



Answers

- A: Capitellum of the right humerus
- B: Right recurrent radial artery
- C: Right brachial artery
- D: Right interosseus artery
- E: Right radial artery
- F: Right ulnar artery

Cite this as: [BMJ 2013;346:f208](#)

© BMJ Publishing Group Ltd 2013