

# HISTOCHEMICAL STUDIES ON THE PROCESS OF THE FRESH HIDES TO TANNED LEATHERS. (REPORT I), ESPECIALLY ON THE RIPENING OF THE HIDES IN COLD STORAGE AND THE DIAGNOSIS OF THE DECOMPOSED HIDES

著者	ITIKAWA Osamu, HOSHINO Tadahiko, YAMAGUCHI Takanobu
journal or publication title	Tohoku journal of agricultural research
volume	16
number	2
page range	103-115
year	1965-12-15
URL	<a href="http://hdl.handle.net/10097/29466">http://hdl.handle.net/10097/29466</a>

# HISTOCHEMICAL STUDIES ON THE PROCESS OF THE FRESH HIDES TO TANNED LEATHERS. (REPORT I), ESPECIALLY ON THE RIPENING OF THE HIDES IN COLD STORAGE AND THE DIAGNOSIS OF THE DECOMPOSED HIDES

By

Osamu ITIKAWA, Tadahiko HOSHINO and Takanobu YAMAGUCHI\*

*Department of Animal Husbandry, Faculty of Agriculture,  
Tohoku University, Sendai, Japan*

*(Received on 28 July, 1965)*

## Introduction

Histochemical studies on the process in which fresh hides become tanned leather has been done on hides ripening in cold storage. They have been compared for the degree of freshness, i.e. "not very fresh hides" and "decomposed hides". Also the changes of the hides during soaking, softening in water, liming, deliming, bating, chrome tanning, staining, and oil bathing have been studied. Through these results, the morphology of the process was established histochemically and pathologically.

In the present study an autolytic phenomenon was found with necrobiosis, degeneration, nuclear changes, and the bacterial invasion into the intercellular spaces and cell bodies. No one has investigated the alteration of hides and leathers from a histochemical view.

## Materials and Methods for Studies

The skins used for this experiment were three Swiss steerskins at 40 days after cold storage (well-ripened), three Tokyo steerskins just after cold storage (good quality), and three purulent steerskins of unknown origin which had remained unknown and decomposing for several years in cold storage. These skins were offered us by The Nippon Hide and Leather Co. at Tokyo for our investigation.

The total skins were fixed in buffered formol, and cut with frozen microtome

---

\* Present address: Nippon Hikaku Kenkyusho (Japanese Research, Institute for Hide and Leather), 1-1, Senjyu, Midorimachi, Adachiku Tokyo.

into 15  $\mu$  sections. The stains employed were: PAS-hematoxylin stain with or without saliva digestion for glycogen and general polysaccharides; hematoxylin-eosin stain and azan-stain for general staining; Feulgen's reaction for DNA; Bsrachet's pyronine-methyl green stain for DNA and RNA; Duijn's acrolein-SCHIFF's reaction for protein, and Sudan-III or Sudan balck-B stain for fat.

## Results

### 1. Histochemical comparison with the fresh skins of good quality, well-ripend skins at 40 days after cold storage, and the decomposed skins for several years in cold storage.

Kawamura (1) said that skins like semiprocessed goods such as fresh foods might have some alteration of quality in storage. Okamura (2) devided skin protein nitrogen into four types, such as non-protein nitrogen, coagulated protein nitrogen, lime-water soluble protein, and collagen nitrogen. Also, he found that there were loss of hair, increase of non-protein nitrogen by thirteen times, decrease of collagen nitrogen (9%), coagulated protein nitrogen (45%) and lime-water soluble nitrogen (30%).

In comparing the fresh skin and the 40 days-stored skins, there was a remarkable depolymerization of DNA in the nuclei of the epithelium and epidermis of the latter. The nuclei of the collagenous fibers in the pars reticularis of the corium were round and methyl-green-philic in the fresh skins, but pyknotic and pyroninophilic in the ripend skins. The pyknotic nuclei of the collagenous fibers in the ripend skin were attended with karyolysis. In the putrid skins a remarkable decrease of DNA occurred in the hair follicles, and both stratum corneum et stratum granulosa disappeared.

The decrease of protein in the stratum corneum et granulosum, degeneration in the stratum granulosa, and a decrease of glycogen and protein in the hair follicle appeared in the ripend skins stored for 40 days.

The alterations of DNA, protein and glycogen in the ripening might be caused by the salt- and time- effects, and accompany the softening of the skins.

The putrid skins were indistinguishable in both stratum corneum et granulosum, and some were desquamated only to the stratum basale. DNA and glycogen in the hair follicle decreased. Remarkable bacterial multiplication was found. Also granulation and globulation in the hair-follicles, arrector pili muscules and sebaceous glands was evident.

The results are shown in the Table I

### 2. Patho-histochemical lesions of the hair in the putrid skins stored for several years.

Observing the hairs in the putrid skins, it is noteable that the cellular degeneration, necrosis, karyopyknosis, karyolysis, vacuolization, cavity-formation and

bacterial multiplication in the Huxley's and Henley's layers of the hair shaft, and that in the inner and outer sheaths of the hair root. Although the cortex and medullary of the hair remained ordinal, there were vacuolization, fissure, decomposition, disappearance, globulation of melanin pigments, and bacterial invasion in the severe affected hair. Also there were isolation, swelling and karyolysis of the Huxley's layer; and swelling, separation and liquefaction of stratum spinosum; and the disappearance of the glassy membrane. In the sections stained with VAN-GIESSON'S stain, there were yellow in the inner and outer layer, dark blue in the nuclei and red in the arretor pili muscles, so it is very suitable for the identification of degeneration in the putrid or ripened skins. The putrid skin showed the pyknotic karyorrhexis and karyolysis of the nuclei stained with dark bluish tone, and yellowish cytoplasm with vacuolization and disociation, and light yellow degenerative cytoplasm.

Different lesions in different localities were as the follows:

- 1) Destruction of the Huxley's layer and bacterial multiplication in the internal hair sheath (Fig. 1, 3, 4, 5).
- 2) Disappearance of the stratum spinosum et basale in the external hair sheath (Fig. 1, 3, 5).
- 3) Fusion of the circular layer of the connective tissue in the hair follicle (Fig. 1, 3, 5).
- 4) Remain of the cortex and medullary of the hair shaft and glassy membrane (Fig. 2, 5, 7).
- 5) Isolation of the Huxley's and Henley's layer in the internal hair sheath (Fig. 2)
- 6) Cavity formation with bacterial masses in the destructive external hair sheath (Fig. 2, 7).
- 7) Separation of the circular and longitudinal connective tissue in the hair follicle (Fig. 2).
- 8) Swelling of the connective tissue with collagenous fibers (Fig. 4).
- 9) Loss of the hair and bacterial invasion into the hair roof (Fig. 4, 5, 7).
- 10) Degeneration of the circular connective tissue around the hair follicle (Fig. 5, 6).
- 11) Vacuolized nuclei in the stratum spinosum of the external hair sheath (Fig. 6, 7).
- 12) Severe fissures in the hair cortex and necrosis in the internal hair sheath (Fig. 7).
- 13) Liquefaction in the external hair sheath (Fig. 8).
- 14) Loss of nuclei in the stratum spinosum of the external hair sheath (Fig. 8).
- 15) Bacillus multiplication in the hair shaft, remain of the glassy membrane, and bacterial masses in the internal and external hair sheath (Fig. 9).

Table 1. Histochemical comparison with the fresh skins,

Structure		Quality	Fresh steerskin			
			No. 1	No. 2	No. 3	
Epithelium	Str. corneum	DNA	—	—	—	
		Polysaccharide	—	—	—	
		Protein	+	+	+	
		Fats.	+	—	—	
	Str. granulosum	DNA	##	##	##	
		Polysaccharide	+	+	+	
		Protein	##	+	##	
		Fats.	+	—	—	
	Str. spinosum	DNA	##	##	##	
		Polysaccharide	+	+	+	
		Protein	##	##	##	
		Fats	+	—	—	
	Str. basale	DNA	##	##	##	
		Polysaccharide	##	##	##	
		Protein	##	##	##	
		Fats.	—	—	—	
Epidermis	Str. papillae	DNA	##	##	##	
		Polysaccharide	+	+	+	
		Protein	+	+	+	
		Fats.	—	—	—	
	Str. reticularis	DNA	+	+	+	
		Polysaccharide	##	##	+	
		Protein	##	##	##	
		Fats.	—	—	—	
	Appendage	Hair follicle	DNA	##	##	##
			Polysaccharide	##	##	+
			Protein	##	##	##
			Fats.	##	—	—
Arrector pili muscle		DNA	+	+	+	
		Polysaccharide	##	##	##	
		Protein	##	##	##	
		Fats.	+	—	—	
Sebaceous gland		DNA	##	##	##	
		Polysaccharide	+	+ S	+ S	
		Protein	+	+	+	
		Fats.	##	—	—	
Blood vessels	DNA	+	+	+		
	Polysaccharide	##	##	##		
	Protein	##	##	##		
	Fats.	—	—	—		

Remarks: B indicated the bacterial multiplication; G, granulation; D, of DNA; S, slight degree

40-days sipend skins, and putrid skins

Putrid steerskin			40-day stored steerskin		
No. 1	No. 2	No. 3	No. 1	No. 2	No. 3
-	-	-	-	-	-
-	-	-	-	-	-
-	-	-	-	+	+
-	-	-	-	-	-
-	-	-	-	L #	L #
-	-	-	-	+	#
-	-	-	-	##	#
-	-	-	-	-	-
-	-	-	L ##	L ##	L ##
-	#	#	+	+	#
-	##	##	##	##	#
-	-	-	-	-	-
-	-	-	L ##	L ##	L ##
#	#	##	+	#	##
##	##	##	##	##	#
-	-	-	-	-	-
-	-	-	L #	L ##	L ##
+	+	#	+	#	#
##	##	##	#	#	#
-	-	-	-	-	-
-	-	-	L #	#	L +
#, +	#, +	#~+	#	#	##
##, +	##~+	##~+	##	##	#
-	-	-	-	-	-
+~-	+~-	-(S)	##	##	##
+, -	+~-B	#~-B	##~+	#	##~#
D##~-	D##~-	##~-	##	##	##
-	-	-	-	-	-
-	-	-	-	+	+
#D,G	#D,B	#D,B	-	##	##
# G	-	-	##	##	-
-	-	-	-	-	-
-	-	-	L #	#	#
# B	# B	# B	+ S	+	+ S
#B,G	##B,G	##B,G	+	+	#
-	-	-	-	-	-
-	-	-	#	#	#
#	#	#	#	#	##
#	#	#	##	##	##
-	-	-	-	-	-

decomposition and disappearance of the structure; L, depolymerization

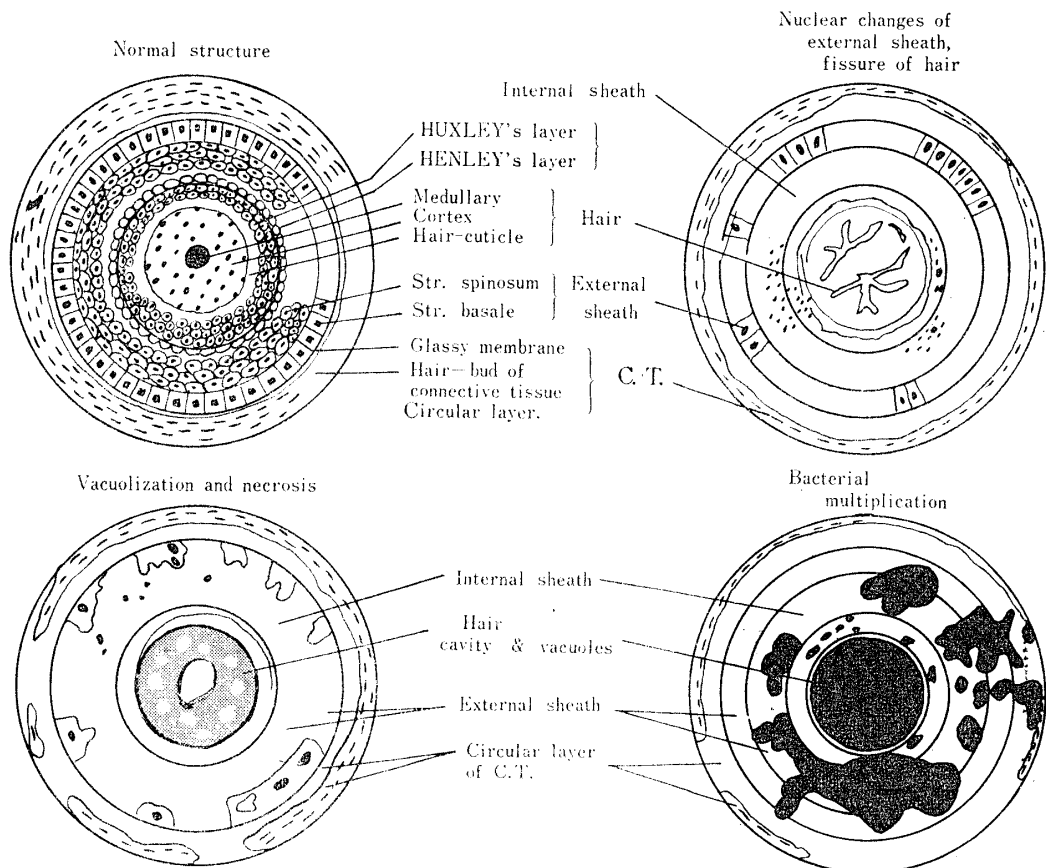
16) Gram positive bacillus in the reverse side and fusion of the collagenous fibers (Fig. 10).

By the McManus's periodic acid Schiff reaction there were observed polysaccharide in the circular connective tissue around the hair follicle, glycogen in the cells of the outer hair sheath, a small amount of polysaccharide in the cortex of the hair and in the swollen epithelium of the desquamated Huxley's layer and stratum spinosum.

Observing protein by Duijn's acrolein-Schiff reaction, a large amount of protein was found in the hair, inner and outer hair sheath, and circular connective fibers of the fresh skin, but disappearance of protein in the vacuoles of the hair and desquamous epithelium, and slight decrease of protein in the circular connective fibers occurred.

It is characteristic to find a large amount of the nuclei in the hair-follicles and outer hair sheath of the fresh skin, and to observe the loss of the nuclei in the degenerative hair follicles by means of the Feulgen reaction for DNA. As a slight degree of this phenomenon was found in the ripend skin, this quantitative observation of the hair follicles with few or no nuclei by the Feulgen reaction seemed to be a valid method for determination of skin-freshness.

**Table 2.** Histopathological lesions of the hair of the putrid steerskin.



### Summary and Conclusion

The process of fresh hides becoming tanned leather has been investigated histochemically. During these investigations, the occurrence of nuclear changes, such as DNA-disappearance and DNA-depolymerization, was noticed in the ripend skins and putrid ones.

The results are summarized as follows:

1) It was noticed that a remarkable depolymerization of DNA found in the nuclei of the epidermis and corium of the 40 day-stored skins in comparison with the fresh skins. The decrease of protein in the stratum corneum et granulosum, the degeneration in the stratum granulosum, and the decrease of glycogen and protein in the hair follicle appeared in the ripend skins stored for 40 days.

2) Stratum corneum et granulosum in the putrid skins were indistinguishable and desquamated to the stratum basale. DNA and glycogen in the hair follicles decreased, and bacterial multiplication in the hair follicles occurred.

3) Observaing the hairs of the putrid skins, there were found: necrosis, cavity formation and bacterial multiplication in the internal hair sheath; necrosis, isolation, decomposition and bacterial invasion in the external hair sheath; remains of the cortex and medullary; necrosis and isolation in the stratum basale and disappearance of the stratum spinosum with cavity-formation, bacterial multiplication, and liquefaction; vacuolization fissure, decomposition, disappearance, and bacterial invasion in the hair.

4) In the putrid skins, there was a decrease or disappearance of protein, glycogen and polysaccharide in the hair and internal or external sheaths. A large amount of nuclei in the hair and hair sheath of the fresh skins were found, but those nuclei disappeared in the putrid skins according to the Feulgen's nuclear reaction test.

The alterations of DNA: protein and glycogen in the ripening might be caused on the salt- and time- effect under the autolytic process, and attended to the softening of the skins. Quantitative observation of the hair follicles with few or no nuclei using the Feulgen reaction test seemed to be useable in determination of skin-freshness.

No one has ever found the presence and significance of the relationships between disappearance of nuclei and bacterial multiplication in the putrid skins and ripend skins. It seemed to have an important role in the ripening and putrefaction of the skins.

In the present study it was described that the onset of the autolytic phenomena with degeneration of the epidermis and corium such as decrease of protein, glycogen and polysaccharide in the 40-days stored skins, and the progress of putrefaction with degeneration of the epidermis, corium, hair and hair follicle such as disappearance or liquefaction of protein and polysaccharides in the putrid skins, were



evident histochemically.

### Acknowledgement

The present authors express their thanks to Dr. Yoshihiro Abiko, Dr. Ikuo USHIGOSHI in Japanese Research Institute for Hide and Leather, Tokyo, Mr. Y. Niwa and Mr. K. Kusumoto, chief engineers of Nippon-Hikaku Manufacturing Plant, Tokyo, for giving the materials used in this study, and Mr. Kiko Goto, Mr. Sadamitsu Yoneya, Miss Yae Kamioka of their laboratory for their valuable technical assistance during the course of this study.

### References

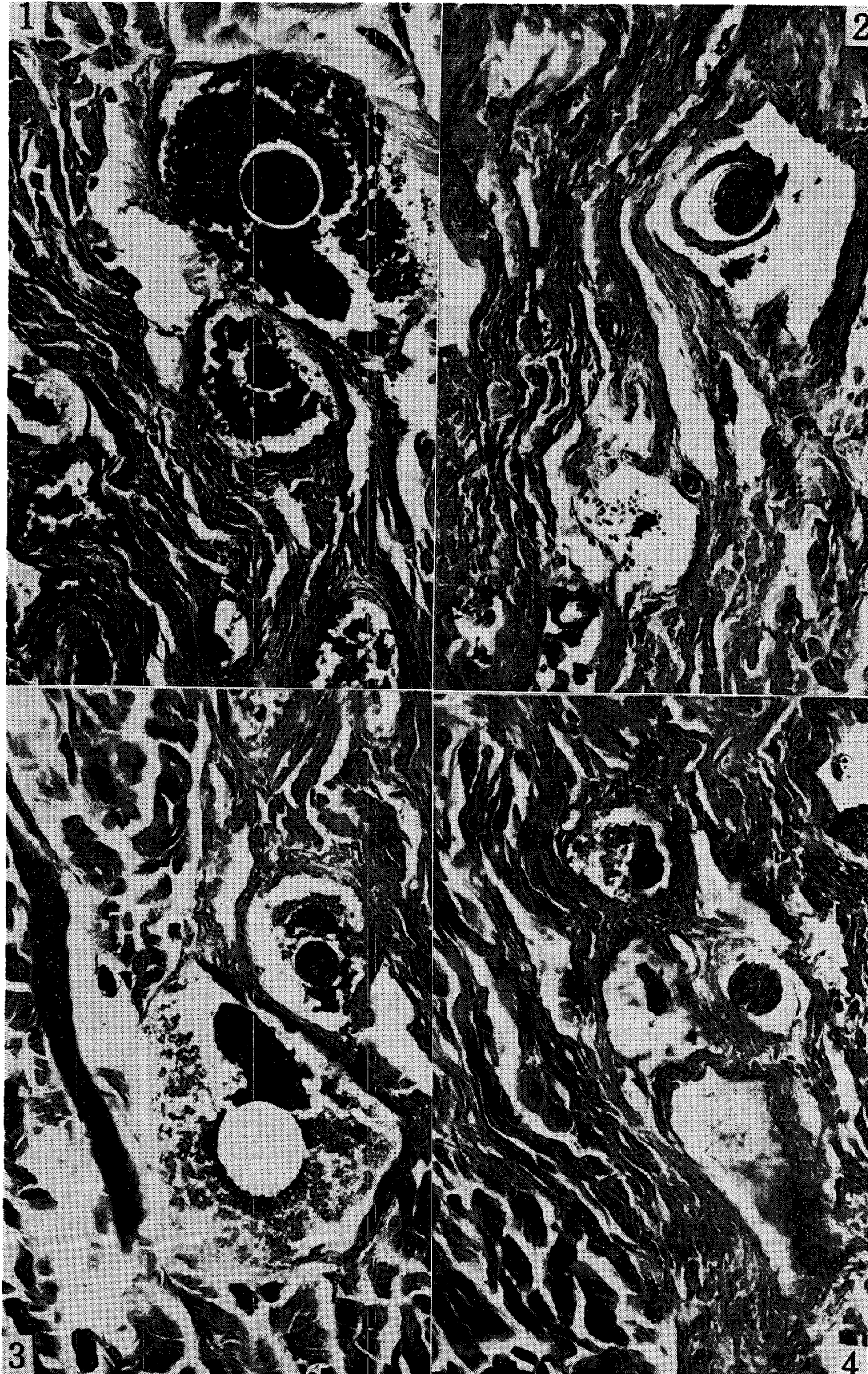
- 1) Kawamura, Ryo. (1962). *Kobunshi (High polymer)*, **129**, 1258-1265.
- 2) Okamura, Hiroshi (1962). *Jap. J. of Zootechn.* **33**, 136.

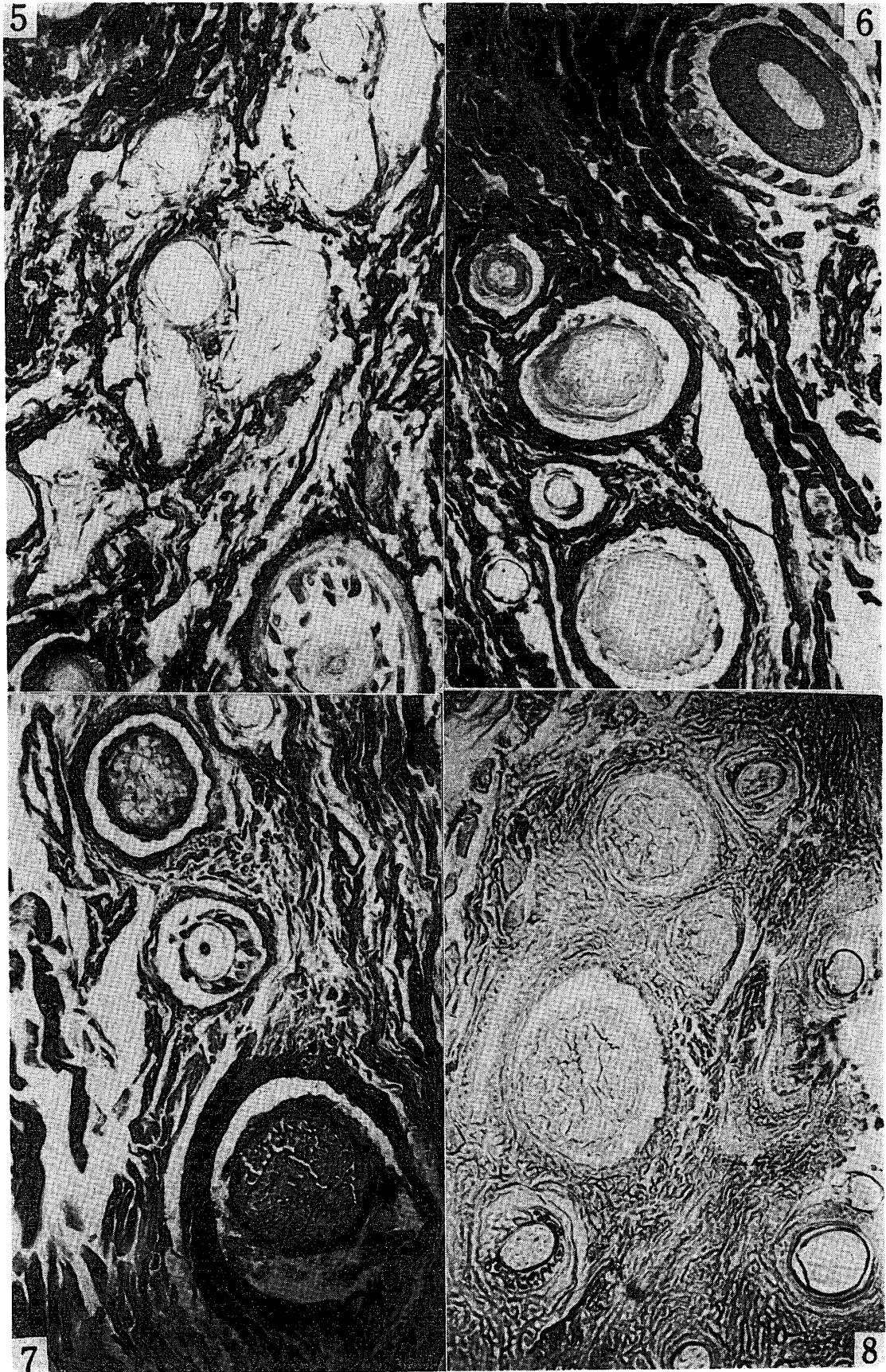
---

### Plate 1.

#### Explanation of Figures

- Fig. 1. Destruction of Huxley's layer, bacterial multiplication in the internal hair sheath, destruction of the stratum spinosum et basale in the external hair sheath, and fusion of the circular layer of the connective tissue in the hair follicle of the putrid steerskin;  $\times 200$ , McManus's PAS reaction for the demonstration of polysaccharide.
- Fig. 2. Remain of the cortex and medullary of the hair and glassy membrane, isolation of Huxley's and Henley's layers in the internal hair sheath, cavity formation with bacterial masses in the destructed external hair sheath, and separation of the circular and longitudinal connective tissue in the hair follicles of the putrid steerskin;  $\times 200$ , McManus's PAS reaction for the demonstration of polysaccharides
- Fig. 3. Same microphoto as the above Fig. 1 was stained with Duijn's acrolein Schiff reaction for the demonstration of protein;  $\times 200$ .
- Fig. 4. Swelling of the collagenous fibers, destruction of the hair, internal and external hair sheaths, loss of the hair, and bacterial invasion into the hair roof;  $\times 200$ , McManus's PAS reaction for the demonstration of polysaccharides





**Plate 2**

**Explanation of the Figures**

- Fig. 5. Remain of the cortex and medullary of the hair, destruction and fusion of the internal hair sheath, swelling and isolation of the stratum spinosum et basale in the external hair sheath, loss of hair substances, destruction in the hair sheaths, and degeneration of the circular connective tissue around the hair follicles.  $\times 200$ , stained with McManus reaction for polysaccharides.
- Fig. 6. Degenerative collagenous fiber bundles stained with Van Gieson's staining, loss of hair, vacuolized nuclei in the stratum spinosum of the external hair sheath, and fusion of the internal hair sheath,  $\times 200$ , Van Gieson's staining for collagenous fibers.
- Fig. 7. Severe fissures in the hair cortex and necrosis in the internal hair sheath, and loss of the external hair sheath contained with bacteria, vacuolization in the hair cortex, remain of the medullary, and grassy membrane, fusion of the internal hair sheath, karyopyknosis and karyolysis of the external hair sheath, and cavity in the one.,  $\times 200$ , Van Gieson's staining for collagenous fibers.
- Fig. 8. Fissures and degeneration in the hairs, degenerated remain of the internal hair sheath, and liquefaction in the external hair sheath, and loss of nuclei in the stratum spinosum of the external hair sheath,  $\times 200$ . Feulgen's nuclear reaction for DNA.

**Plate 3****Explanation of Figures**

- Fig. 9. Bacillus multiplication in the hair shaft, the internal and external hair sheath, and in the space among the longitudinal collagenous fiber bundles; and remain of the glassy membrane alone.  $\times 200$ , stained with pyronine-methyl green staining, Gram-positive bacillus stained pyroninophylic.
- Fig. 10. Gram-positive bacillus in the reverse side of the putrid skin, and fusion of the collagenous fibers.,  $\times 200$ ., Pyronine-methyl green staining for DNA and RNA.
- Fig. 11. The nuclei of the collagenous fibers in the zona reticularis of the fresh steerskin indicated strong positive intensity of Feulgen's reaction.  $\times 400$ , Feulgen's reaction.
- Fig. 12. The nuclei of the collagenous fibers in the zona reticularis of the 50-days stored calfskin indicated weak positive or none intensity of Feulgen's reaction,  $\times 400$ , Feulgen's reaction.

