

## FDG-PET for Diagnosis of an Advanced Jejunal Adenocarcinoma with Distant Metastases, Compared with Gallium Scintigraphy

著者	Yamaura G., Yoshioka T., Yamaguchi K., Fukuda H., Ishioka C.
journal or publication title	CYRIC annual report
volume	2003
page range	203-207
year	2003
URL	<a href="http://hdl.handle.net/10097/50255">http://hdl.handle.net/10097/50255</a>

## VIII. 9. FDG-PET for Diagnosis of an Advanced Jejunal Adenocarcinoma with Distant Metastases, Compared with Gallium Scintigraphy

*Yamaura G., Yoshioka T., Yamaguchi K. \*, Fukuda H. \*\*, and Ishioka C.*

*Department of Clinical Oncology, Institute of Development, Aging and Cancer, Tohoku University  
Cyclotron and Radioisotope center, Tohoku University\**

*Department of Nuclear medicine and Radiology, Institute of Development, Aging and Cancer,  
Tohoku University\*\**

### **Introduction**

Patients with primary adenocarcinoma of the jejunum are very rare<sup>1)</sup>, and there has been no report to our knowledge showing how nuclear medicine techniques may play a role in diagnosis. We have experienced a case of an advanced adenocarcinoma of the jejunum with distant metastases, for which positron emission tomography (PET) with fluorine-18 2-deoxy-2-fluoro-D-glucose (FDG) and gallium-67 citrate scintigraphy were compared.

### **A Case Report**

A 70-year-old woman was referred to our institute because of an adenocarcinoma metastasis to cervical lymph node with unknown primary lesion.

She had found painlessly swelling in her left cervical lymph nodes three months previously and visited her local hospital. Biopsy revealed metastases from an adenocarcinoma and a series of investigations were carried out to find the primary site but failed.

When she visited our institute, she presented no symptoms except for swollen cervical lymph nodes and her laboratory data were unremarkable. Gastroduodenal and colonic endoscopies were carried out but the original site was undetected. Computed tomography (CT) scanned the whole body and revealed the right cervical lymph nodes and para-abdominal aortic lymph nodes and retro-pancreatic lymph node to be swollen (Fig 1). Gallium scintigraphy was carried out and abnormal accumulations in the left cervix, left axillary and the center of the abdomen could be visualized (Fig. 2b). When CT scan

images were checked retrospectively, the lymph nodes in the left axillary were found to be swollen (Fig. 1).

As the next step for diagnosis, FDG PET was carried out and showed accumulation corresponding to all of the swollen lymph nodes and the small intestine (Fig 3). According to these findings, the barium meal fluoroscopy of the small intestine was carried out and showed a defective image near the angle of Treitz (Fig.4). From these findings, the horizontal portion of the duodenum or the jejunum was suspected as the primary site. A gastroduodenal endoscope was therefore introduced into the deep horizontal portion of the duodenum, and a Bormann type II tumor were found. A biopsy was carried out and the histological examination revealed an adenocarcinoma.

Two weeks thereafter, partial resection of jejunum was performed due to the risk of the obstruction and bleeding, and clarified the existence of a Bormann type II tumor, a moderately differentiated adenocarcinoma of the jejunum, 5 cm to the anal side of the Treiz ligament.

## **Discussion**

Small intestinal adenocarcinomas are very rare, accounting for only 2% of gastrointestinal tumors<sup>1)</sup>. In 4995 cases reported to the National Cancer Data Base between 1985 and 1995, 55% of them occurred in the duodenum, 18% in the jejunum, 13% in the ileum and 14% in nonspecified sites<sup>2)</sup>. There are no specific symptoms and diagnosis is frequently very late at an advanced stage. Most common symptoms are pain due to obstruction, weight loss and massive and occult hemorrhage<sup>3)</sup>. In our case, cervical lymph nodes were found to be swollen at first and in the search for the primary site, a jejunal adenocarcinoma was diagnosed.

FDG PET is a noninvasive approach for determination of glycolytic status. PET is able to make an image that shows the tissue distribution of FDG, a structural analog of glucose labeled with the short-lived positron-emitting  $^{18}\text{F}$ <sup>4)</sup>. FDG is transported into the cell via a glucose-transporter, then is converted to FDG-6-phosphate by hexokinase in cells, but it is not a substrate for further metabolism, nor permeable to the cell membrane, and therefore accumulates within the cell<sup>5)</sup>. Enhanced glycolysis is one of the most important characteristics of cancer cells<sup>6)</sup>, and FDG PET has proved successful for imaging various malignant neoplasms<sup>7)</sup>. In our case, FDG PET could detect the primary lesion and apparently all of the metastatic lesions. Koles et al.<sup>8)</sup> and Bohuslavizki et al.<sup>9)</sup> reported that FDG PET is a valuable diagnostic tool in patients with cancer of unknown primary.

In our case, FDG PET is also helpful to find the primary lesion. This is the first report of FDG PET imaging of a jejunal adenocarcinoma, providing support for the conclusion that this approach can greatly contribute to the differential diagnosis of primary lesions in patients with metastatic lymph node deposits. The final diagnosis can then be made on histological examination after endoscopic sampling, advised here.

Gallium scintigraphy was also carried out in our case and succeeded in detecting another lymph node metastasis in the upper body. However, it failed to detect lesions in the abdomen, presumably due to the physiological accumulation of gallium in the liver and the excretion with bile juice into the bowel<sup>10</sup>).

In conclusion, FDG PET should prove helpful in the diagnosis of the small intestinal adenocarcinomas with metastases.

### **Acknowledgment**

The authors thank Mr. Syouichi Watanuki and Mr. Masayasu Miyake for PET operation and the other staffs of the Cyclotron Radioisotope Center, Tohoku University. This work was supported by grants-in-aid for scientific research (No. 13670910 and No. 10670820) from the Ministry of Education, Science, Sport, Culture and Technology, and for Cancer Research (14S-3) from the Ministry of Health, Labour and Welfare, Japan.

### **References**

- 1) Martin R.G., *Surg. Clin. North. Am.* **66** (1986) 779.
- 2) Howe J.R., Karnell L.H., Menck H.R. et al., *Cancer* **86** (1999) 2693.
- 3) Ashley S.W. and Wells S.A., *Semin. Oncol.* **15** (1988) 116.
- 4) Reivich M., Kuhl D., Wolf A. et al., *Circ. Res.* **44** (1979) 127.
- 5) Gallagher B.M., Fowler J.S., Gutterson N.I., MacGregor R.R., Wan C.N. and Wolf A.P., *J. Nucl. Med.* **19** (1978) 1154.
- 6) Warburg O., *Science* **123** (1956) 309.
- 7) Gambhir S.S., Czernin J., Schwimmer J., Silverman D.H.S., Coleman R.E. and Phelps M.E., *J. Nucl. Med.* **42** (2001) 1S.
- 8) Kole A.C., Niewerg O.E., Prium J. et al., *Cancer* **82** (1998) 1160.
- 9) Bohuslavizki K.H., Klutmann S., Kroger S. et al., *J. Nucl. Med.* **41** (2000) 816.
- 10) Togawa T., Tokyo: Kanehara Press, (1999) 518.

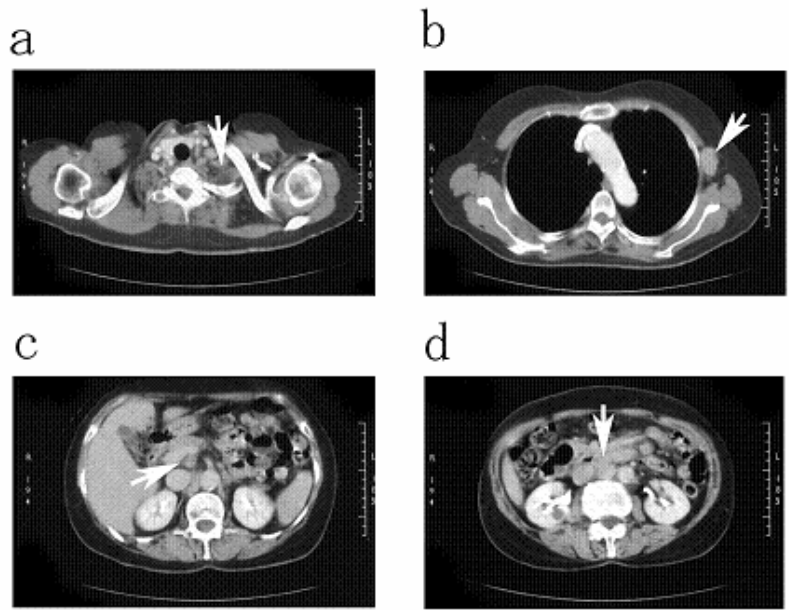


Fig. 1. CT images show lymph nodes swelling in; a: left cervical lymph nodes. b: the left axillary lymph node. c: the retropancreatic lymph node. d: para-aortic lymph nodes.

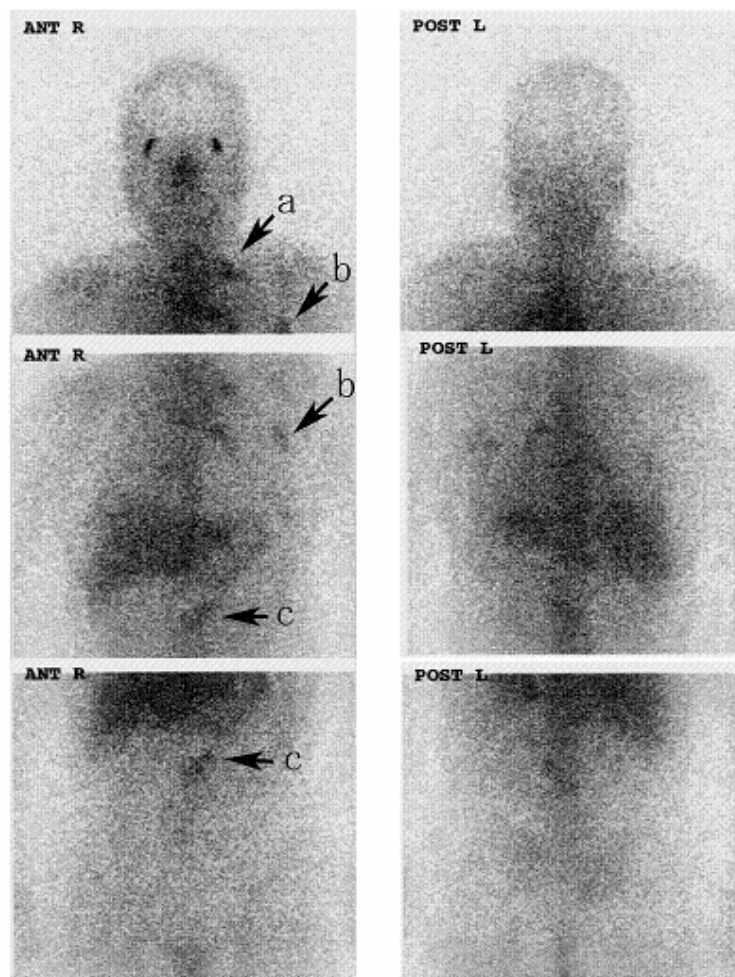


Fig. 2. Gallium scintigraphy shows abnormal accumulations in the left cervix (arrow (a)), left axillary (arrow (b)), and the center of the abdomen (arrow (c)).

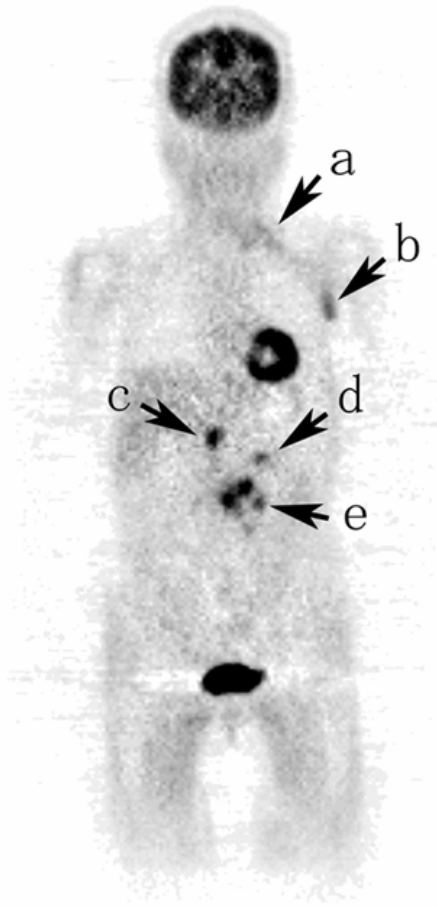


Fig. 3. The image of FDG PET has accumulations corresponding to all lesions. The arrow (d) indicates the slightly high accumulation of FDG that is thought to be corresponding to the primary lesion. All other high accumulations of FDG are corresponding to the metastatic lesions in; a: the cervical lymph nodes. b: the axillary lymph node. c: the retropancreatic lymph node. e: the para-aortic lymph nodes.

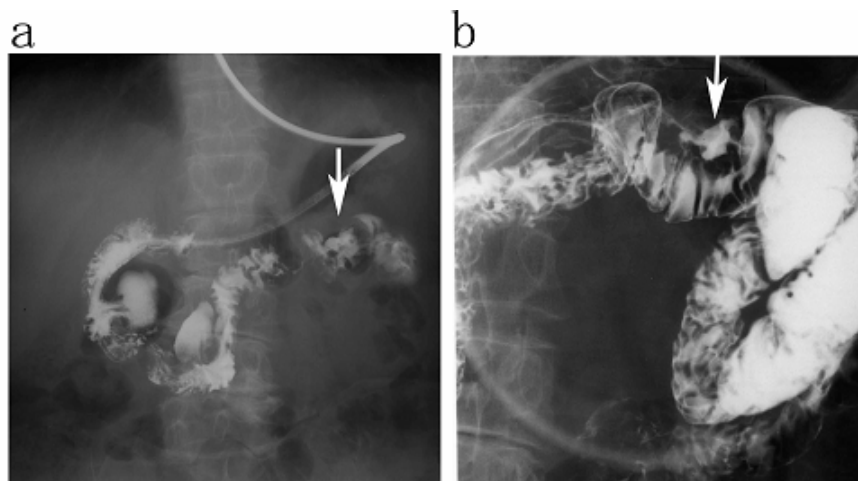


Fig. 4. The barium meal fluoroscopy of the small intestine shows a defective image near the angle of Treitz. a: the image of the whole. B: the enlarged and pressured image of the lesion suspected as a primary lesion. Arrows indicate the lesion.