

Skeletal Class III Severe Openbite Treatment Using Implant Anchorage

著者	Sakaia Yuichi, Kuroda Shingo, Murshid Sakhr A, Takano-Yamamoto Teruko
journal or publication title	Angle Orthodontist
volume	78
number	1
page range	157-166
year	2008
URL	http://hdl.handle.net/10097/51521

doi: 10.2319/103006-445.1

Case Report

Skeletal Class III Severe Openbite Treatment Using Implant Anchorage

Yuichi Sakai^a; Shingo Kuroda^b; Sakhr A. Murshid^c; Teruko Takano-Yamamoto^d

Abstract: A female patient with a skeletal Class III severe anterior openbite was treated using miniplates as the anchorage. The patient was 15 years and 10 months of age when she reported to our university hospital with a chief complaint of anterior openbite and reversed occlusion. The patient had an anterior openbite with an overjet of -3.0 mm and overbite of -5.0 mm and a Class III molar relationship. The cephalometric analysis showed a skeletal Class III relationship (ANB 0°). After the extraction of the bilateral mandibular third molars, miniplates were placed in the mandibular external oblique line. The mandibular dentition was retracted using elastic chain and miniplates. After treatment, an Angle Class I molar relationship was achieved and overjet and overbite had become 2.0 mm and 1.5 mm. A good facial appearance and occlusal relationship were obtained. The total active orthodontic treatment period was 23 months. Wrap-around type retainers were placed on both jaws and a lingual bonded retainer was also attached in the mandibular incisors. After 1 year of retention, the occlusion was stable, and a good facial profile was also retained. The mandibular deviation to the left was improved and the strain in the circumoral musculature during lip closure disappeared. An appropriate interincisal relationship was achieved by the uprighting of mandibular dentition without changing the vertical intermaxillary relationship. A panoramic radiograph showed no marked root resorption. Our results suggest that implant anchorage is useful for correction of skeletal Class III severe anterior openbite cases.

Key Words: Implant anchorage; Skeletal Class III; Openbite

INTRODUCTION

Severe anterior openbite cases are the most difficult orthodontic cases to treat. The first treatment choice has been maxillomandibular surgical orthodontics,

which shows good treatment effects and long-term stability.¹⁻⁴

Recently, as a new treatment method for anterior tooth openbite cases, molar control using implant anchorage has been established.⁵⁻⁹ We have previously reported cases of skeletal Class I^{5,6} and II⁷ openbite, in which improvement in the occlusal height was achieved by molar intrusion using implant anchorage. However, there have been no reports on the treatment of cases of skeletal Class III openbite using implant anchorage.

In this study, a case of alveolar and skeletal openbite with Angle Class III malocclusion and skeletal Class III total crossbite was treated using orthodontic miniplates as an anchorage unit, without premolar extraction or surgical orthodontics, and a good facial profile and occlusal relationship were obtained.

Treatment Summary

The female patient was 15 years and 10 months old at the first examination. She consulted our university dental hospital with a chief complaint of insufficient chewing ability in the anterior tooth area.

As presenting symptoms, the frontal facial appearance showed the left deviation of the mandible, and

^a Research Fellow, Department of Orthodontics and Dentofacial Orthopedics, Graduate School of Medicine, Dentistry and Pharmaceutical Sciences, Okayama University, Okayama, Japan.

^b Assistant Professor, Department of Orthodontics and Dentofacial Orthopedics, Graduate School of Medicine, Dentistry and Pharmaceutical Sciences, Okayama University, Okayama, Japan.

^c Graduate PhD student, Department of Orthodontics and Dentofacial Orthopedics, Graduate School of Medicine, Dentistry and Pharmaceutical Sciences, Okayama University, Okayama, Japan.

^d Professor and Department Chair, Division of Orthodontics and Dentofacial Orthopedics, Graduate School of Dentistry, Tohoku University, Seiryomachi, Aoba-ku, Sendai, Miyagi, Japan.

Corresponding author: Dr Teruko Takano-Yamamoto, Tohoku University Graduate School of Dentistry, Division of Orthodontics and Dentofacial Orthopedics, 4-1, Seiryomachi, Aoba-ku, Sendai, Miyagi, 9808575 Japan
(e-mail: t-yamamo@mail.tains.tohoku.ac.jp)

Accepted: February 2007. Submitted: October 2006.

© 2008 by The EH Angle Education and Research Foundation, Inc.

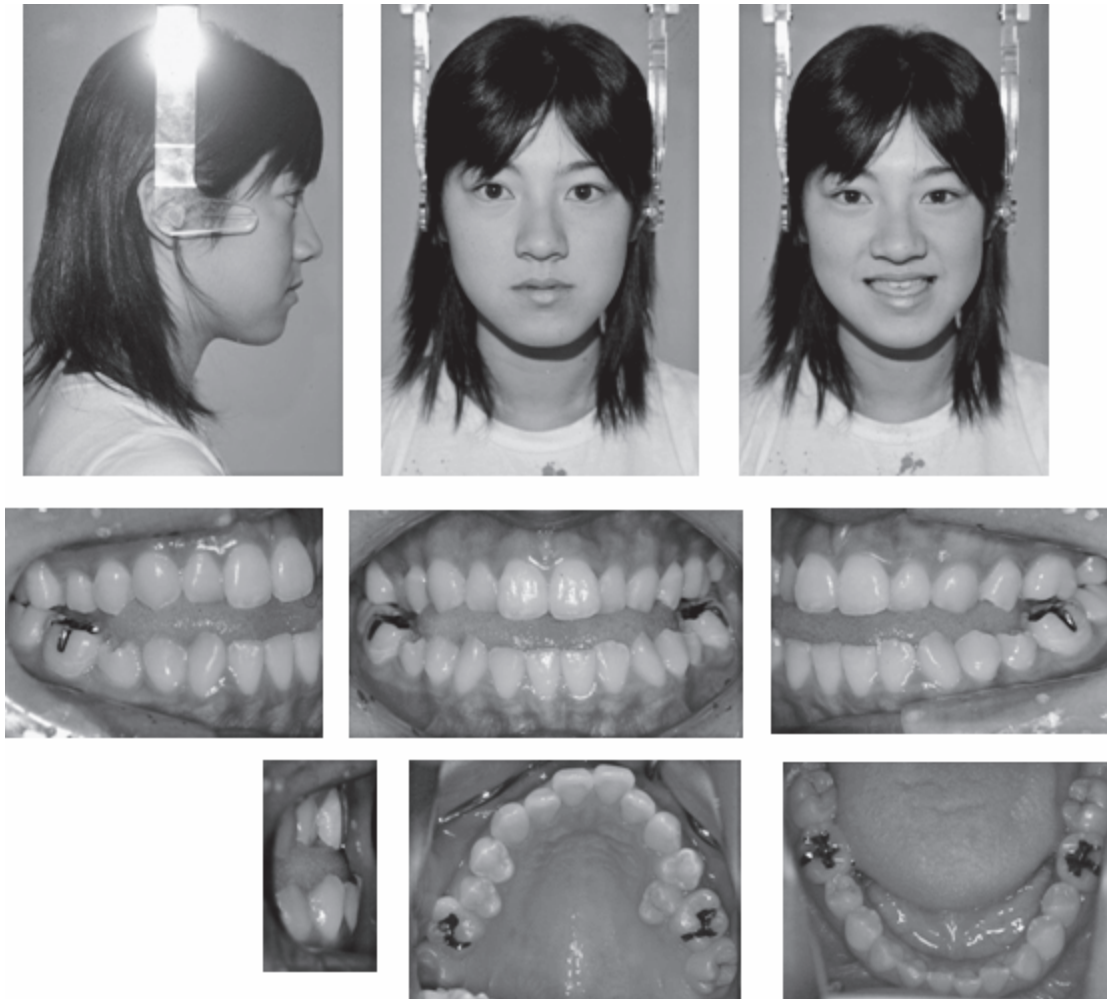

Figure 1. Pretreatment facial and intraoral photographs.

the lateral profile exhibited slight anterior mandibular positioning. Both the frontal facial appearance and lateral profile showed circumoral musculature strain on lip closure. The dental midline of the maxilla and that of the mandible were deviated to the left from the facial midline by 1 mm and 3 mm, respectively. The molars showed crossbite with occlusal interference, and the anteroposterior relationship was Angle Class III, with overjet -3.0 mm and overbite -5.0 mm. Palatal displacement of the maxillary left second premolar, and mesial rotation of the bilateral mandibular second premolars were noted (Figure 1).

The dental arch was symmetrical with a V-shaped type in the maxilla and a U-shaped type in the mandible. The tongue was relatively large. Model analytical findings showed the arch length discrepancy was -11.0 mm in the maxilla and -2.0 mm in the mandible. CT tomograms and an MRI showed no abnormal symptoms in the bilateral temporomandibular joints. The results of examination using a three-dimensional

6-degree-of-freedom jaw movement measurement apparatus (Gnathohexagraph system Version 1.31, Ono Sokki Ltd, Kanagawa, Japan) showed that the range of movement of the bilateral condyles during lateral sliding movement and anterior movement was restricted, with an unstable tracing of the incisal path (Figures 2A and 3A). Using an occlusal force recording system (Dental Prescale & Occluzer, Fuji Film Co, Tokyo, Japan), the maximum occlusal force was measured as low. Impacted bilateral third molars were detected on the panoramic radiograph (Figure 4). Frontal roentgenographic cephalograms showed that the maxillary midline was almost coincident with the cranial midline and that the mandibular midline was deviated to the left by 2.5 mm (Figure 4).

Cephalometric analysis showed that the anteroposterior jaw relationship was skeletal Class III with an ANB angle of 0° compared with the standard values in Japanese women.¹⁰ Vertically, the gonial angle was 130° and was thus larger by more than 1 standard

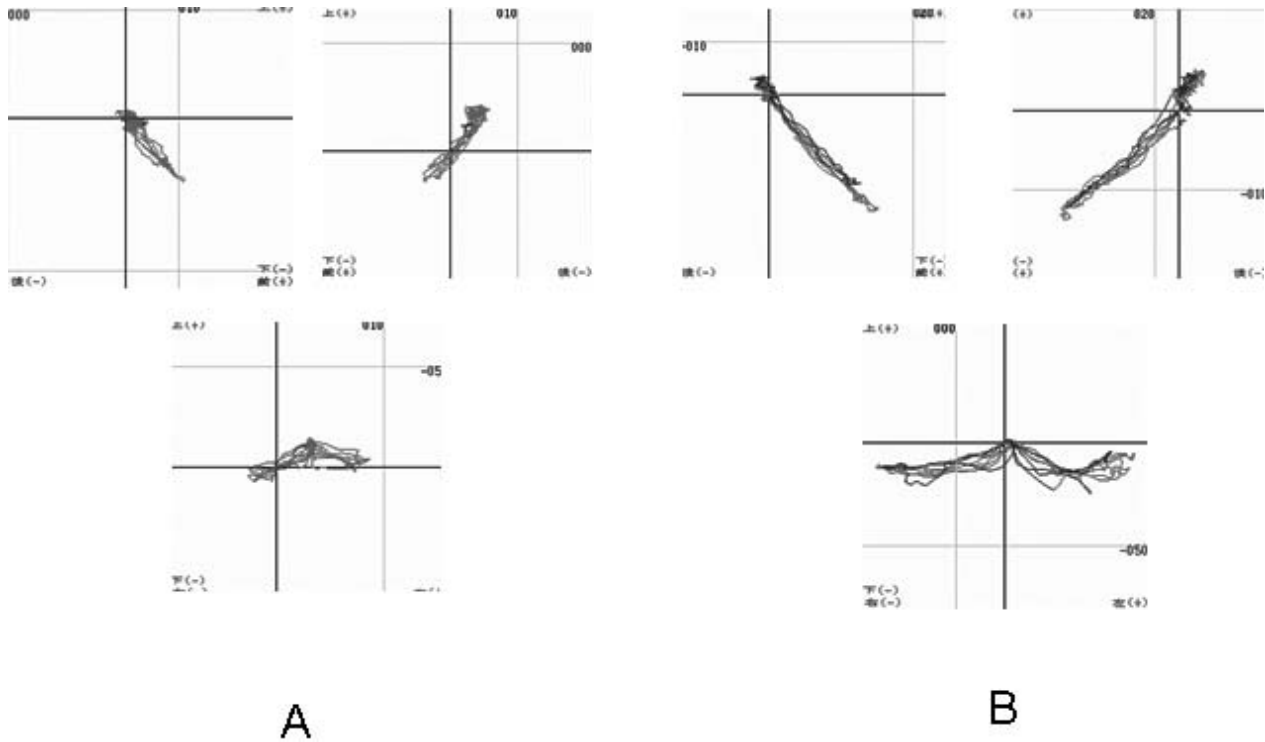


Figure 2. Condylar movement and incisal path during lateral jaw movement as detected using 6-degree-of-freedom jaw movement recording system. (A) Pretreatment. (B) Posttreatment. Above, condylar movement (sagittal view). Rt indicates right side; Lt, left side. Below, incisal path (frontal view).

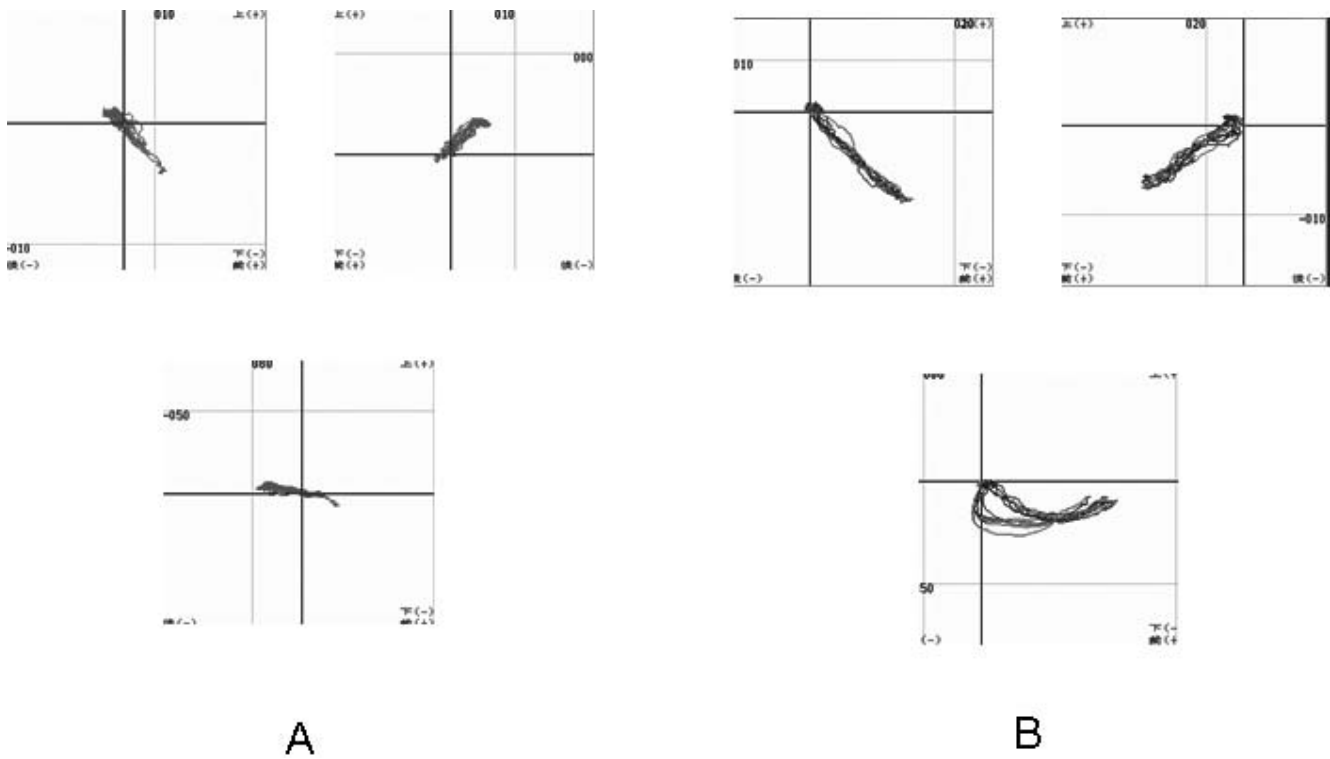


Figure 3. Condylar movement and incisal path during protrusion jaw movement as detected using 6-degree-of-freedom jaw movement recording system. (A) Pretreatment. (B) Posttreatment. Above, condylar movement (sagittal view). Below, incisal path (sagittal view).

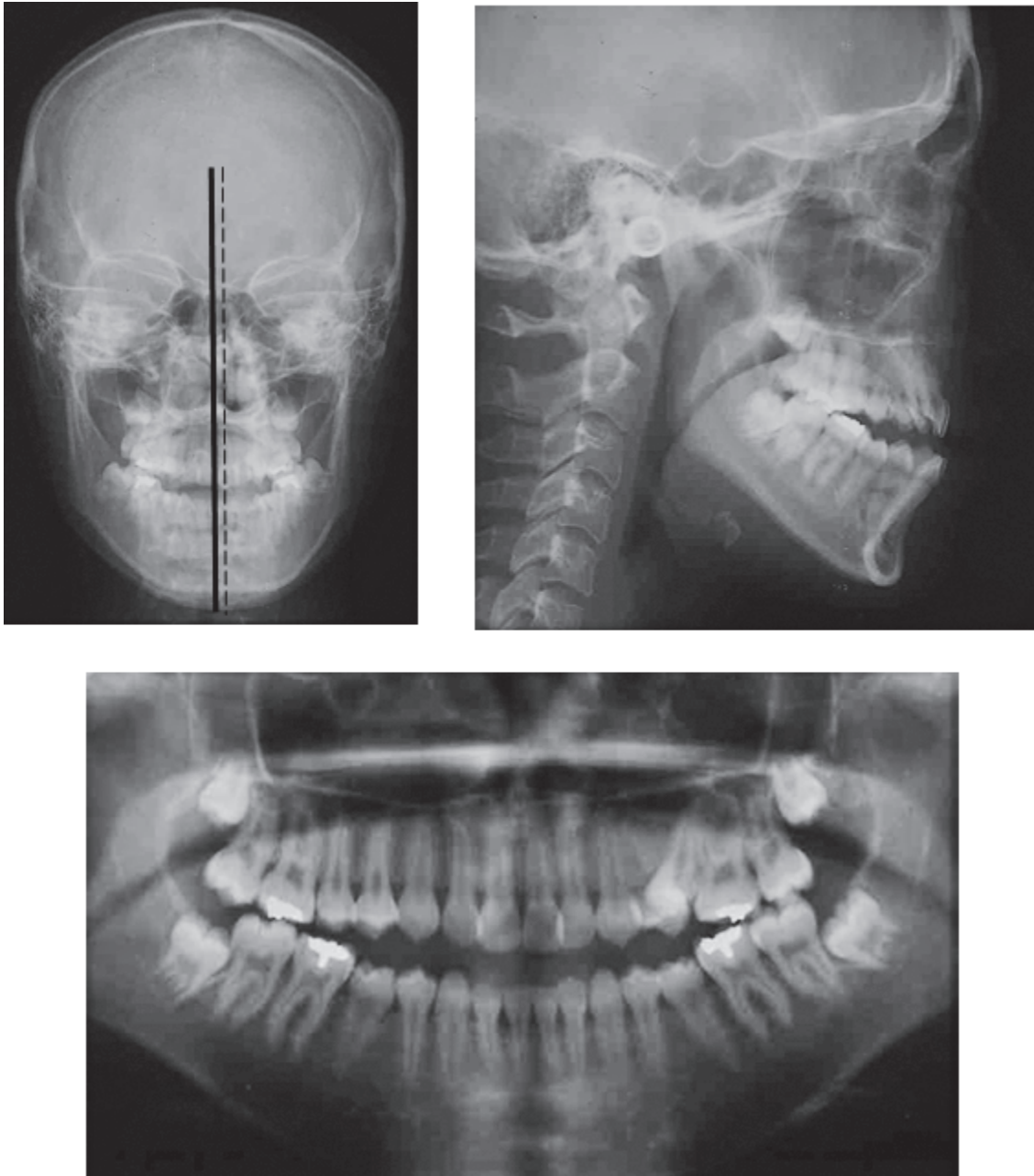


Figure 4. Pretreatment radiographs. Frontal roentgenographic cephalograms showed that the median of the maxillary bone was almost in accordance with the median of the cranium (solid line), and that of the mandibular bone was deviated in the left direction by 2.5 mm (dotted line).

deviation (SD) from the mean; the Y axis angle was 61.2° , which was smaller by more than 2 SD from the mean. The mandibular plane angle and the ratio of the lower facial height to the frontal facial height were within standard values. Although the tooth axial inclination of the maxillomandibular incisors was within standard values, the distance between the palatal plane and the maxillary incisor was 26.0 mm, and the distance between the mandibular plane and the mandibular incisor was 40.0 mm, both of which were small and more than 2 SD from the mean (Figures 4 and 5, Table 1).

Diagnosis

Alveolar and skeletal openbite with Angle Class III malocclusion and skeletal Class III total crossbite was diagnosed.

Treatment Objectives

- Expansion of the maxillary dental arch, using a rapid expansion appliance.
- Implantation and fixation of orthodontic miniplates

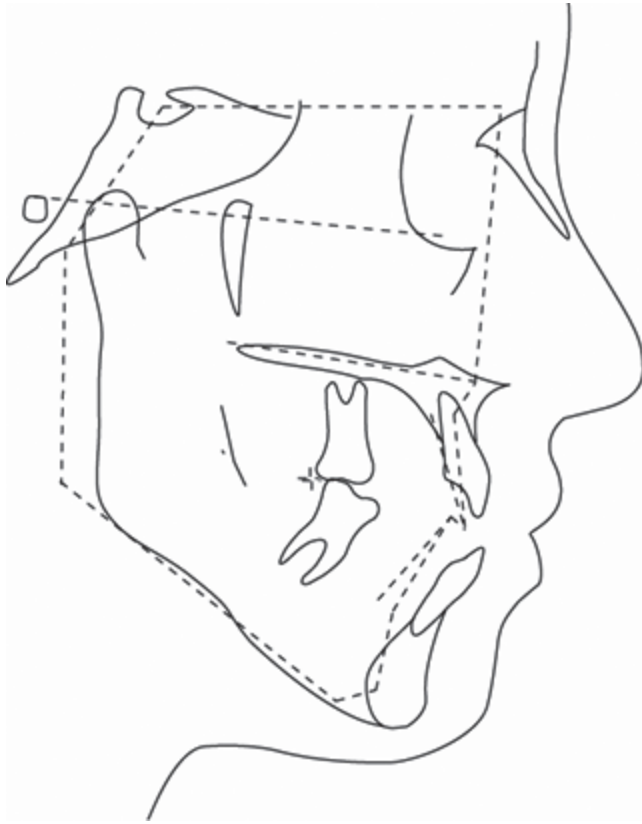


Figure 5. Pretreatment cephalometric tracing (solid line) superimposed on mean profilogram (dotted line).

Table 1. Cephalometric Summary

Variables	Mean	SD	Pretreatment	Posttreatment
Angle, degrees				
ANB	2.8	2.44	0.0	0.7
SNA	80.8	3.61	80.7	80.7
SNB	77.9	4.54	80.7	80.0
Mp-FH	30.5	3.60	30.4	30.6
Gonial, A	122.1	5.29	130.4	130.4
U1-FH	112.3	8.26	114.6	116.8
U1-NF	115.0	6.99	116.4	118.7
L1-Mp	93.4	6.77	91.9	86.5
IIA	123.6	10.64	123.2	126.2
Occlusal, P	16.9	4.40	19.7	16.3
Linear, mm				
S-N	67.9	3.65	72.8	72.8
N-Me	125.8	5.04	126.7	127.2
Me/NF	68.6	3.71	70.6	71.1
Go-Me	71.4	4.14	70.9	71.5
Ar-Me	106.6	5.74	114.3	114.9
Ar-Go	47.3	3.33	53.6	53.6
OJ	3.1	1.07	-3.0	2.0
OB	3.3	1.89	-5.0	1.5
U1/NF	31.0	2.34	26.0	27.3
U6/NF	24.6	2.00	23.1	23.2
L1/Mp	44.2	2.68	40.0	45.3
L6/MP	32.9	2.50	33.4	35.6

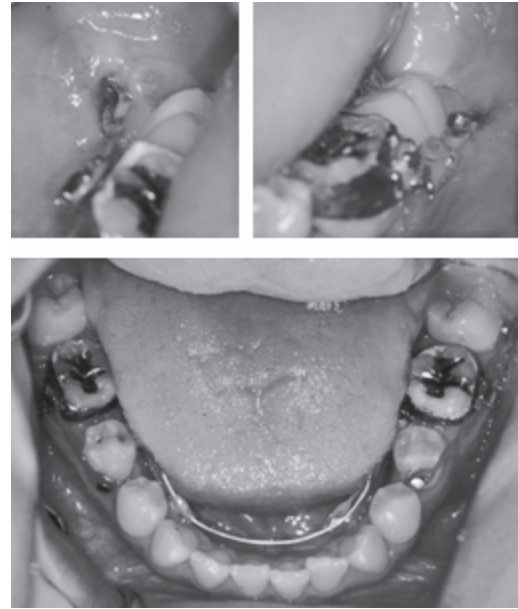

Figure 6. Distal movement of mandibular molars. Above, the mandibular dentition was retracted using elastic chain and miniplates. Rt indicates right side; Lt, left side. Below, intraoral photographs 2 months later of distal molar movement.

in the bilateral mandibular ramus external oblique ridge areas, after extracting the bilateral mandibular third molars.

- Distal movement of the molars, after inserting a lingual arch in the bilateral mandibular first molar areas.
- Lingual movement of the mandibular anterior tooth area toward the space caused by the distal movement of the molars.
- Occlusal adjustment, after obtaining appropriate overjet and overbite using multi-bracket orthodontic appliances.

Treatment Progress

The maxillary dental arch was expanded by 7 mm starting at the age of 16 years and 1 month, using a rapid expansion appliance. After extracting the bilateral mandibular third molars, miniplates (ORTHOANCHOR, Dentsply-Sankin, Tokyo, Japan) were implanted and fixed in the bilateral external oblique ridge areas of the mandibular ramus at the age of 16 years and 7 months. The hooks were adjusted so that they were positioned in the area distal to the second molar. A lingual arch appliance was placed in the mandibular first molars 4 weeks after implantation, and distal movement was initiated using elastic chains to apply an orthodontic force of approximately 200 g on each side (Figure 6).

Preadjusted 0.018-inch edgewise appliances were placed in the maxilla at the age of 16 years and 9

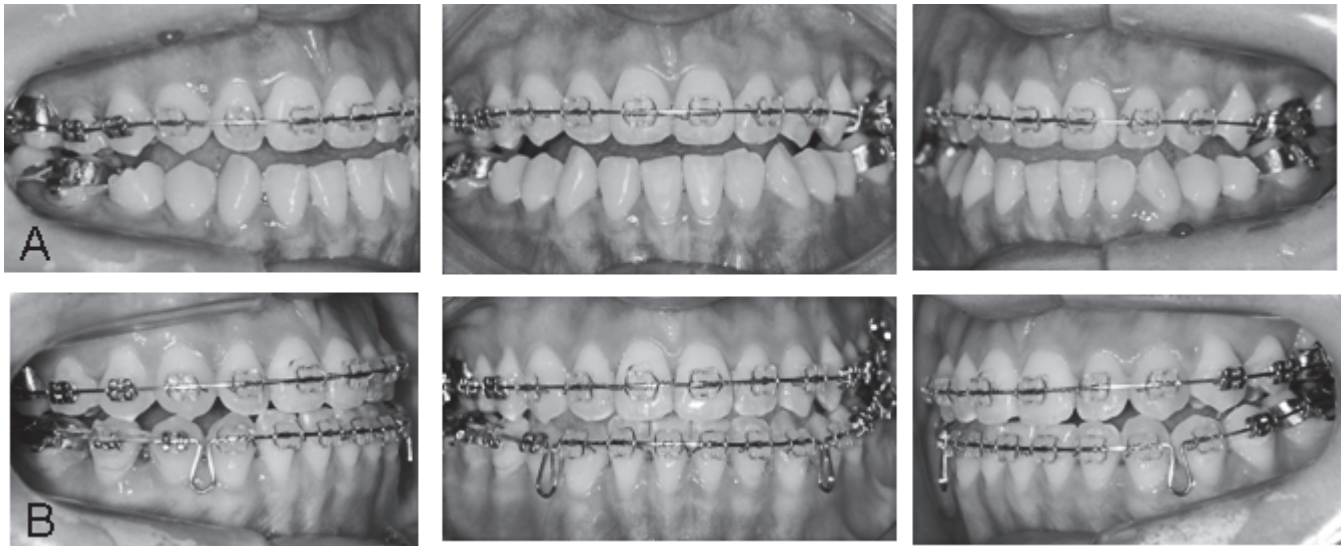


Figure 7. Photographs taken during the course of treatment. (A) The start of leveling and alignment. (B) 13 months later.

months (Figure 7A), and in the mandible at the age of 17 years and 2 months; leveling was initiated. Brackets were placed on the mandibular second molars at the age of 17 years and 5 months, and a shoe-loop was inserted between the mandibular first and second molars to achieve the distal tipping movement of the mandibular second molar, where stationary anchorage was obtained by connecting the mandibular first molar to the miniplate, using ligature wires. Traction of the mandibular anterior teeth toward the first molars was performed using a closing-loop (Figure 7B). A positive anterior tooth overlap was obtained at the age of 17 years and 7 months, and retention started at the age of 18 years and 8 months (Figure 8). The active treatment period was 23 months. Retention consisted of maxillomandibular wrap-around type retainers and a lingual bonded retainer on the mandibular incisors. One year has passed since retention started.

Treatment Results

Comparing the facial appearance before and after treatment, the frontal appearance showed improvement in the left deviation of the mandible, and the frontal appearance and facial profile showed improvement in the circumoral musculature strain on lip closure (Figure 8). Performing labial inclination and extrusion of the maxillary anterior teeth, and lingual inclination and extrusion of the mandibular anterior teeth, a positive relationship of the anterior tooth overlap (overjet 2.0 mm, and overbite 1.5 mm) was obtained, without changing the maxillomandibular anteroposterior and vertical relationship (Figures 9 and 10, Table 1). Furthermore, horizontally, the maxillomandibular dental midline was in accordance with the cranial midline (Figure 9).

A panoramic radiograph showed a good parallelism of the tooth roots, without marked tooth root resorption (Figure 9). No symptoms were noted in the temporomandibular joint during the dynamic treatment or retention during the dynamic treatment or retention period. Three-dimensional 6-degree-of-freedom jaw movement examination showed increases in the bilateral condylar movement range during lateral sliding and anterior movement, and a smooth tracing curve of the incisal path (Figures 2B and 3B).

DISCUSSION

The advantages of implant anchorage, in contrast to extra-oral and intermaxillary anchorages, are that the patient's cooperation is unnecessary and no undesirable reciprocal force occurs with tooth movement.¹¹⁻¹⁵ Therefore, tooth movement is possible according to the treatment plan. Regarding the treatment of openbite cases, if patients are in the growth and development period, reciprocal intrusion of the molars can be achieved by suppressing molar eruption.^{16,17} However, molar intrusion in adults is difficult, and when anterior tooth openbite patients are treated by the conventional mechanism, using extraoral anchorage appliances, intermaxillary elastics, and multi-loop edgewise arch wires,^{18,19} it is not molar intrusion, but anterior tooth extrusion that frequently results. This yields poor esthetics, functionality, and stability. Furthermore, although surgical orthodontic treatment such as maxillomandibular osteotomy is usually indicated in severe skeletal openbite cases, patients do not readily accept surgical orthodontics due to the surgical invasion and accompanying risks.²⁰ Therefore, there have recently been reports on the treatment of skeletal anterior tooth openbite cases in which implant anchorage was used, without performing surgical orthodontics.⁶⁻⁹

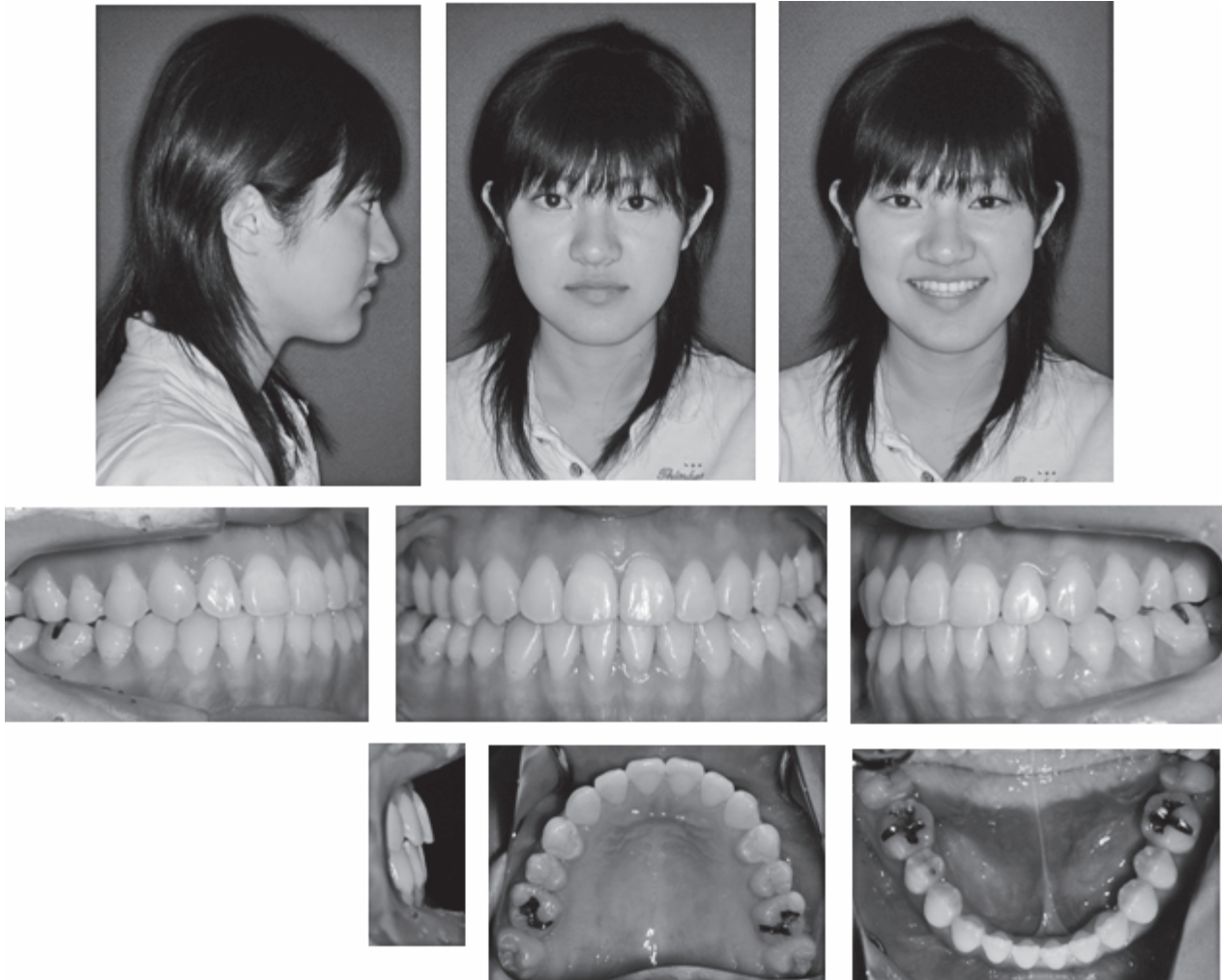


Figure 8. Posttreatment facial and intraoral photographs.

Umemori et al⁵ treated a case of Class I openbite, in which molar intrusion was achieved using miniplates as stationary anchorage. Sherwood et al⁶ and Erverdi et al⁹ reported cases of openbite treated using similar methods, and good results were obtained. We also treated cases of Class I and Class II openbites, using titanium screws as an anchorage unit, and obtained good results.^{6,7} In those reports, molar intrusion caused counterclockwise rotation of the mandible, increased overbite, decreased the lower facial height, and improved the facial profile. Furthermore, anterior tooth extrusion was almost unnecessary for the improvement in overbite. Therefore, in cases of Class I and II openbite, molar intrusion using implants is very useful, and has been established as a new treatment method for cases of anterior openbite.^{6-9,21} However, in cases of skeletal Class III openbite, counterclockwise rotation of the mandible by molar intrusion may increase the protrusion of the menton, resulting in deterioration of the facial profile. Therefore, molar intru-

sion can be inappropriate in such cases. Although the present patient was a case of skeletal Class III, the facial profile at rest was straight. On the other hand, openbite due to the infraversion of the maxillomandibular anterior teeth and reversed occlusion in the anterior tooth area were noted. Therefore, overjet was improved by distally inclining the mandibular molars using implants as orthodontic anchorage, and overbite was improved by extruding the anterior teeth. As a result, a good occlusal condition and facial profile were obtained in our patient. Similar tooth movement may be possible by the use of Class III elastics, but the patient's cooperation is necessary. Such large distal inclination of the mandibular molars as achieved in our case is considered difficult by the use of intermaxillary elastics, even if sufficient cooperation is obtained.

As the reverse occlusion of skeletal Class III was mild in our case, extrusion of the maxillomandibular anterior teeth was diagnosed as possible judging from the facial and cephalometric findings, and treatment

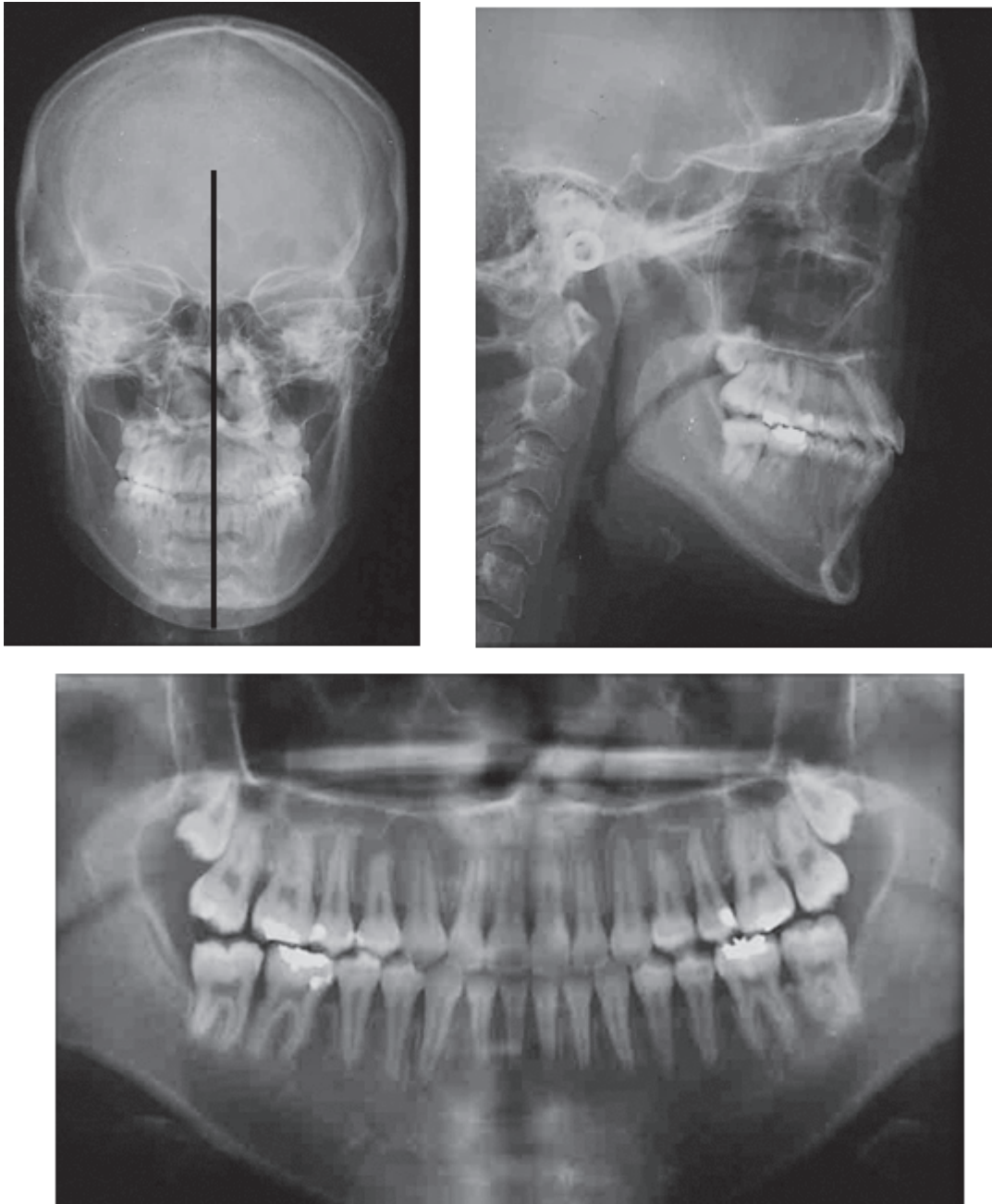


Figure 9. Posttreatment radiographs. Frontal roentgenographic cephalograms showed that the maxillomandibular median was in accordance with the cranial median (solid line).

was performed applying these mechanics. However, in much more severe cases of skeletal Class III openbite, treatment using anterior tooth extrusion is inappropriate, and surgical orthodontic treatment is first indicated. Furthermore, when the anteroposterior disharmony of the maxillomandibular relationship is marked, surgical orthodontics is necessary for improving the facial appearance. Therefore, orthodontic treatment using implant anchorage is not indicated in all cases of skeletal Class III openbite. On the other hand,

some patients do not request surgical orthodontics, considering the surgical risk, hospitalization, and expenses.^{20,22} For those patients, orthodontic treatment using implant anchorage can be a successful camouflage treatment.

In the present case, intra-oral findings showed crossbite of the maxillomandibular molars and frontal roentgenographic cephalograms revealed deviation of the mandible from the cranial midline toward the left side by 2.5 mm. Neither disorders in the temporoman-

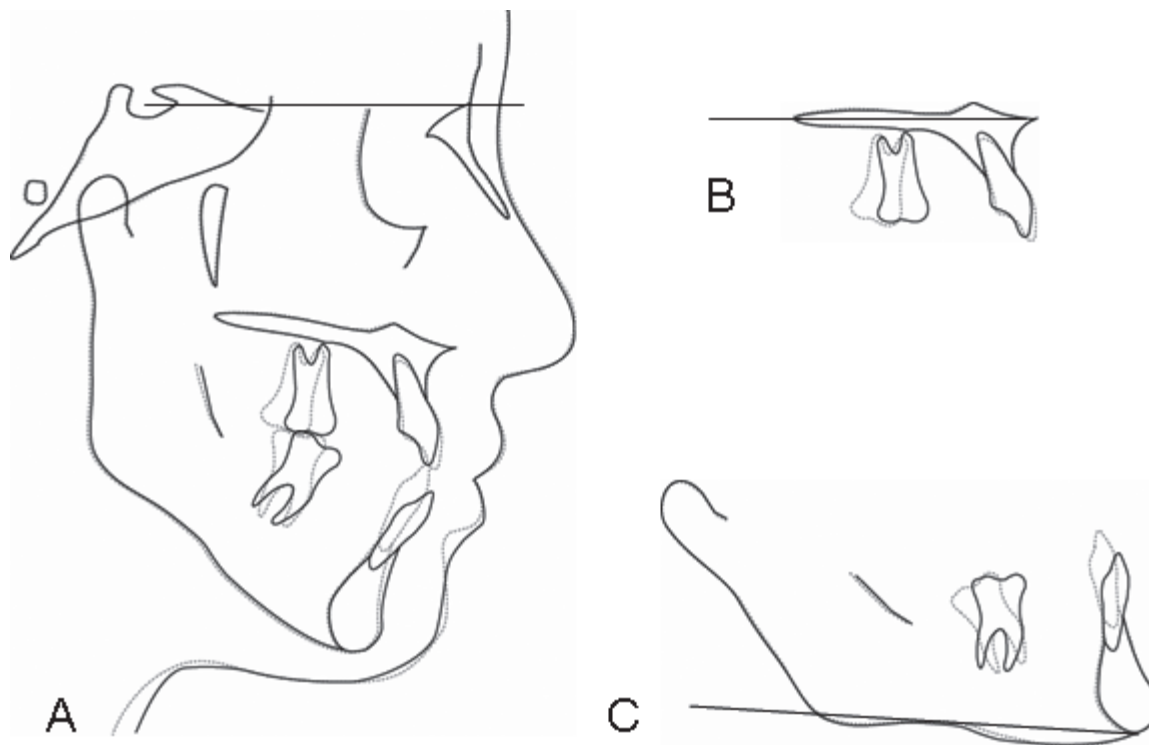


Figure 10. Pretreatment (solid line) and posttreatment (dotted line) cephalometric tracings, superimposed on (A) sella-nasion plane at sella, (B) palatal plane at ANS, and (C) mandibular plane at menton.

dibular joint nor morphological abnormalities in the mandibular body and condyle were detected. Based on these clinical findings, we considered that maxillary bone expansion improved the occlusal interference and relationship, and the position of the mandible became median in accordance with the cranial midline, due to the physiological function of the muscles surrounding the oral cavity. Furthermore, three-dimensional 6-degree-of-freedom jaw movement examination showed increases in the bilateral condylar movement, and a smooth tracing of the incisal path indicated that functional adaptation was also obtained.

Although adult cases of severe anterior tooth openbite treated by surgical orthodontics show long-term stability,¹⁻⁴ there have been no reports on the long-term stability after orthodontic treatment using implant anchorage. Adult patients with skeletal Class I severe anterior tooth openbite treated with implant anchorage⁶ have been reported to show counterclockwise rotation of the mandible improved skeletal openbite, and functional adaptation of the muscles surrounding the oral cavity which was important for retention.^{6,7} In our cases of implant anchorage the anteroposterior and vertical intermaxillary relationships were not changed. However, the function of the muscles surrounding the oral cavity including the tongue²³ and masticatory muscles need to be followed during treatment, and the extruded maxillomandibular anterior teeth, distally in-

clined mandibular molars, and periodontal tissue of the alveolar bone also need to be followed long term .

REFERENCES

1. Epker BN, Fish L. Surgical-orthodontic correction of openbite deformity. *Am J Orthod.* 1977;71:278-299.
2. Hoppenreijts TJ, Freihofer HP, Stoelinga PJ, Tuinzing DB, van't Hof MA, van der Linden FP, Nottet SJ. Skeletal and dento-alveolar stability of Le Fort I intrusion osteotomies and bimaxillary osteotomies in anterior open bite deformities. A retrospective three-centre study. *Int J Oral Maxillofac Surg.* 1997;26:161-175.
3. Proffit WR, Bailey LJ, Phillips C, Turvey TA. Long-term stability of surgical open-bite correction by Le Fort I osteotomy. *Angle Orthod.* 2000;70:112-117.
4. Swinnen K, Politis C, Willems G, et al. Skeletal and dento-alveolar stability after surgical-orthodontic treatment of anterior open bite: a retrospective study. *Eur J Orthod.* 2001; 23:547-557.
5. Umemori M, Sugawara J, Mitani H, Nagasaka H, Kawamura H. Skeletal anchorage system for open-bite correction. *Am J Orthod Dentofacial Orthop.* 1999;115:166-174.
6. Kuroda S, Katayama A, Takano-Yamamoto T. Severe anterior open-bite case treated using titanium screw anchorage. *Angle Orthod.* 2004;74:558-567.
7. Kuroda S, Sugawara Y, Tamamura N, Takano-Yamamoto T. Anterior openbite with temporomandibular disorder treated using titanium screw anchorage: evaluation of morphological and functional improvement. *Am J Orthod Dentofacial Orthop.* In press.
8. Sherwood KH, Burch JG, Thompson WJ. Closing anterior open bites by intruding molars with titanium miniplate an-

- chorage. *Am J Orthod Dentofacial Orthop.* 2002;122:593–600.
9. Erverdi N, Keles A, Nanda R. The use of skeletal anchorage in open bite treatment: a cephalometric evaluation. *Angle Orthod.* 2004;74:381–390.
 10. Wada K, Matsushita K, Shimazaki S, Miwa Y, Hasuike Y, Susami R. An evaluation of a new case analysis of a lateral cephalometric roentgenogram. *J Kanazawa Med Univ.* 1981;6:60–70.
 11. Kuroda S, Sugawara Y, Yamashita K, Mano T, Takano-Yamamoto T. Skeletal Class III oligodontia patient treated with titanium screw anchorage and orthognathic surgery. *Am J Orthod Dentofacial Orthop.* 2005;127:730–738.
 12. Fukunaga T, Kuroda S, Kurosaka H, Takano-Yamamoto T. Skeletal anchorage for orthodontic correction of maxillary protrusion with adult periodontitis. *Angle Orthod.* 2006;76:148–155.
 13. Deguchi T, Takano-Yamamoto T, Kanomi R, Hartsfield JK Jr, Roberts WE, Garetto LP. The use of small titanium screws for orthodontic anchorage. *J Dent Res.* 2003;82:377–381.
 14. Kuroda S, Sugawara Y, Deguchi T, Kyung HM, Takano-Yamamoto T. Clinical use of miniscrew implants as orthodontic anchorage: success rates and postoperative discomfort. *Am J Orthod Dentofacial Orthop.* 2007;131:9–15.
 15. Sugawara J, Baik UB, Umemori M, Takahashi I, Nagasaka H, Kawamura H, Mitani H. Treatment and posttreatment dentoalveolar changes following intrusion of mandibular molars with application of a skeletal anchorage system (SAS) for open bite correction. *Int J Adult Orthodon Orthognath Surg.* 2002;17:243–253.
 16. Alexander CD. Open bite, dental alveolar protrusion, Class I malocclusion: a successful treatment result. *Am J Orthod Dentofacial Orthop.* 1999;116:494–500.
 17. Smith GA. Treatment of an adult with a severe anterior open bite and mutilated malocclusion without orthognathic surgery. *Am J Orthod Dentofacial Orthop.* 1996;110:682–687.
 18. Kim YH. Anterior open bite and its treatment with multiloop edgewise archwire. *Angle Orthod.* 1987;4:290–321.
 19. Enacar A, Ugur T, Toroglu S. A method for correction of open bite. *J Clin Orthod.* 1996;30:43–48.
 20. Al-Bishri A, Barghash Z, Rosenquist J, Sunzel B. Neurosensory disturbance after sagittal split and intraoral vertical ramus osteotomy: as reported in questionnaires and patients' records. *Int J Oral Maxillofac Surg.* 2005;34:247–251.
 21. Kuroda S, Sakai Y, Tamamura N, Deguchi T, Takano-Yamamoto T. Treatment of severe anterior open bite with skeletal anchorage in adult. A comparison with orthognathic surgery outcomes. *Am J Orthod Dentofacial Orthop.* In press.
 22. Panula K, Keski-Nisula L, Keski-Nisula K, Oikarinen K, Keski-Nisula S. Costs of surgical-orthodontic treatment in community hospital care: an analysis of the different phases of treatment. *Int J Adult Orthodon Orthognath Surg.* 2002;17:297–306.
 23. Fujiki T, Inoue M, Miyawaki S, Nagasaki T, Tanimoto K, Takano-Yamamoto T. Relationship between maxillofacial morphology and deglutitive tongue movement in patients with anterior open bite. *Am J Orthod Dentofacial Orthop.* 2004;125:160–167.