

Severe Anterior Open-Bite Case Treated Using Titanium Screw Anchorage

著者	Kuroda Shingo, Katayama Akira, Takano-Yamamoto Teruko
journal or publication title	Angle Orthodontist
volume	74
number	4
page range	558-567
year	2004
URL	http://hdl.handle.net/10097/51518

Severe Anterior Open-Bite Case Treated Using Titanium Screw Anchorage

Shingo Kuroda, DDS, PhD^a; Akira Katayama, DDS^b; Teruko Takano-Yamamoto, DDS, PhD^c

Abstract: Anterior open bite is often caused by a downward rotation of the mandible and/or by excessive eruption of the posterior teeth. In such cases, it is difficult to establish absolute anchorage for molar intrusion by traditional orthodontic mechanics. This article reports the successful treatment of a severe skeletal anterior open-bite case using titanium screw anchorage. A female patient 33 years eight months of age had open bite of -7.0 mm and increased facial height. The titanium screws were implanted in both the maxilla and the mandible, and an intrusion force was provided with elastic chains for 13 months. After active treatment of 19 months, her upper and lower first molars were intruded about 3.0 mm each, and good occlusion was achieved. Her retrognathic chin and convex profiles were improved by an upward rotation of the mandible. Our results suggest that titanium screws are useful for intrusion of molars in anterior open-bite cases. (*Angle Orthod* 2004;74:558–567.)

Key Words: Anterior open bite; Implant anchor; Titanium screw; Congenital missing tooth

INTRODUCTION

Skeletal anterior open bite is one of the most difficult cases to treat in orthodontics. In adult patients, treatment of severe skeletal anterior open bite consists mainly of surgically repositioning both the maxilla and the mandible. This is true in the adult because adults have little growth potential, and often open bites are combined with a long-face tendency.^{1,2} However, there are some patients who do not wish to undergo surgical treatment because of its risks.

For such patients, various alternatives can be used, including multibrackets in conjunction with high-pull headgear therapy,³ extraction therapy,⁴ multiple-loop edgewise archwire (MEAW) therapy,⁵ and nickel-titanium wire with intermaxillary elastics.⁶ These techniques provide acceptable interincisal relationships and increase overbite. However, the skeletal improvements are often poor because it is

difficult to establish absolute anchorage for molar intrusion by traditional orthodontic mechanics such as multibrackets combined with intra- or extraoral anchorage.

To obtain an absolute anchorage, dental implants,^{7–10} screws,^{11–13} and miniplates^{14–16} have been used as orthodontic anchorage. Without the patient's cooperation, these materials can provide absolute anchorage for various tooth movements. There are some reports of screws being used for anchorage in tooth movement, intrusion or retraction of anterior teeth,^{11–13} and protraction of lower molars.¹² However, there have been few cases reported of titanium screws being used as orthodontic anchorage in the treatment of severe skeletal anterior open bites. In addition, there have been few reports of intrusion of molars in both the maxilla and the mandible with absolute anchorage. The present case report demonstrates the usefulness of titanium screws for orthodontic anchorage to intrude the upper and lower molars of an adult patient with severe skeletal anterior open bite.

CASE SUMMARY

A female patient 33 years eight months of age came to the outpatient clinic of our university dental hospital (Figure 1). The patient's chief complaints were a chewing problem and anterior open bite. A convex profile due to a retrognathic mandible was noted. An acute nasolabial angle, increased lower facial height, and circumoral musculature strain on lip closure were observed. A severe anterior open bite with an overjet of 7.1 mm and overbite of -7.0 mm was observed. In addition, two distinct occlusal planes were present in the upper arch. Severe crowding was present in

^a Assistant Professor, Department of Orthodontics and Dentofacial Orthopedics, Graduate School of Medicine and Dentistry, Okayama University, Okayama, Japan.

^b Graduate student, Department of Orthodontics and Dentofacial Orthopedics, Graduate School of Medicine and Dentistry, Okayama University, Okayama, Japan.

^c Professor and Chairman, Department of Orthodontics and Dentofacial Orthopedics, Graduate School of Medicine and Dentistry, Okayama University, Okayama, Japan.

Corresponding author: Teruko Takano-Yamamoto, DDS, PhD, Department of Orthodontics and Dentofacial Orthopedics, Graduate School of Medicine and Dentistry, Okayama University, 2-5-1 Shikata-Cho, Okayama 700-8525, Japan (e-mail: tyamamo@md.okayama-u.ac.jp).

Accepted: August 2003. Submitted: April 2003.

© 2004 by The EH Angle Education and Research Foundation, Inc.

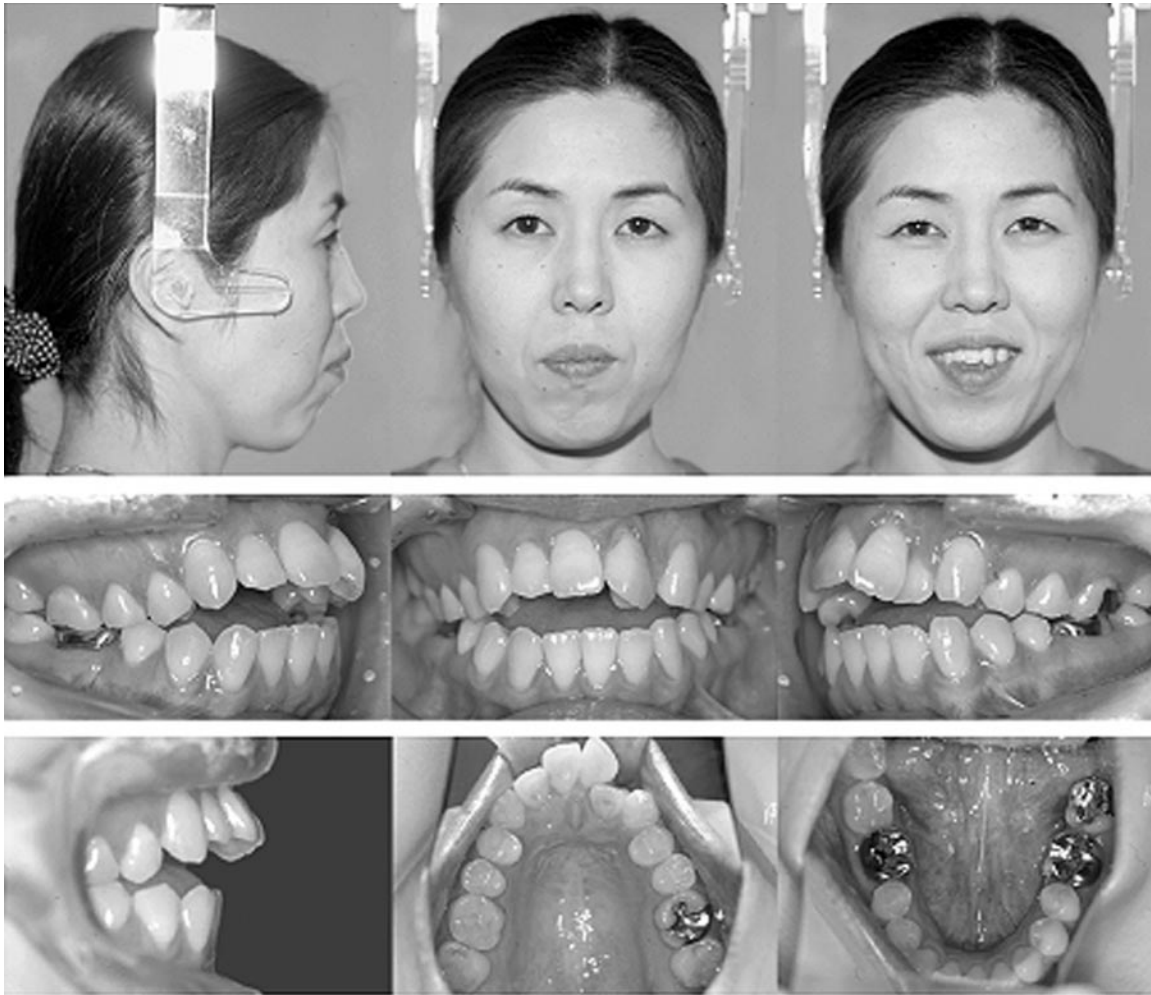

FIGURE 1. Pretreatment photographs (age, 33 years eight months).

the upper arch because of the constricted arch form. Severe gingival recession was found around the upper left central incisor. The lower right lateral incisor and the left third molars in both jaws were congenitally absent. The upper dental midline almost coincided with the facial midline, but the lower dental midline was not coincident because of the congenitally missing lower incisor. In the radiograph findings, a periapical lesion was observed at the lower right first molar.

The cephalometric analysis, when compared with the Japanese norm,¹⁷ showed a skeletal Class I relationship (ANB 4.1) with mandibular retrusion (SNB 73.2) (Figure 2). The mandibular plane angle was steep, and the Gonial angle was large (MP/FH 38.6, Go.A 136.7), but the mandibular body length and ramus height were within the normal range. The lower incisors were labially inclined (U1/FH 128.2, L1-MP 96.4). Both upper and lower molars were significantly extruded (U6/NF 31.6, L6/MP 37.4), and the molar relationship was Angle Class II on both sides.

There were no symptoms of temporomandibular disorder

(TMD) according to the results of an examination using a six-degree-of-freedom jaw movement recording system (Gnathohexagraph system version 1.31, Ono Sokki Ltd, Kanagawa, Japan). Magnetic resonance imaging (MRI) of the temporomandibular joint (TMJ) showed that the positions of the discs on both sides were normal during jaw opening and closing. The maximum interincisal distance on opening was 50 mm.

Diagnosis and treatment objectives

The patient was diagnosed as having an Angle Class II malocclusion, with a skeletal Class I jaw base relationship, a skeletal anterior open bite, and a congenitally absent lower right lateral incisor. The treatment objectives were (1) to correct the anterior open bite and establish ideal overjet and overbite, (2) to achieve an acceptable occlusion with a good functional Class I occlusion, and (3) to correct the retrognathic appearance of the facial profile.

The cause of the anterior open bite was suggested to have

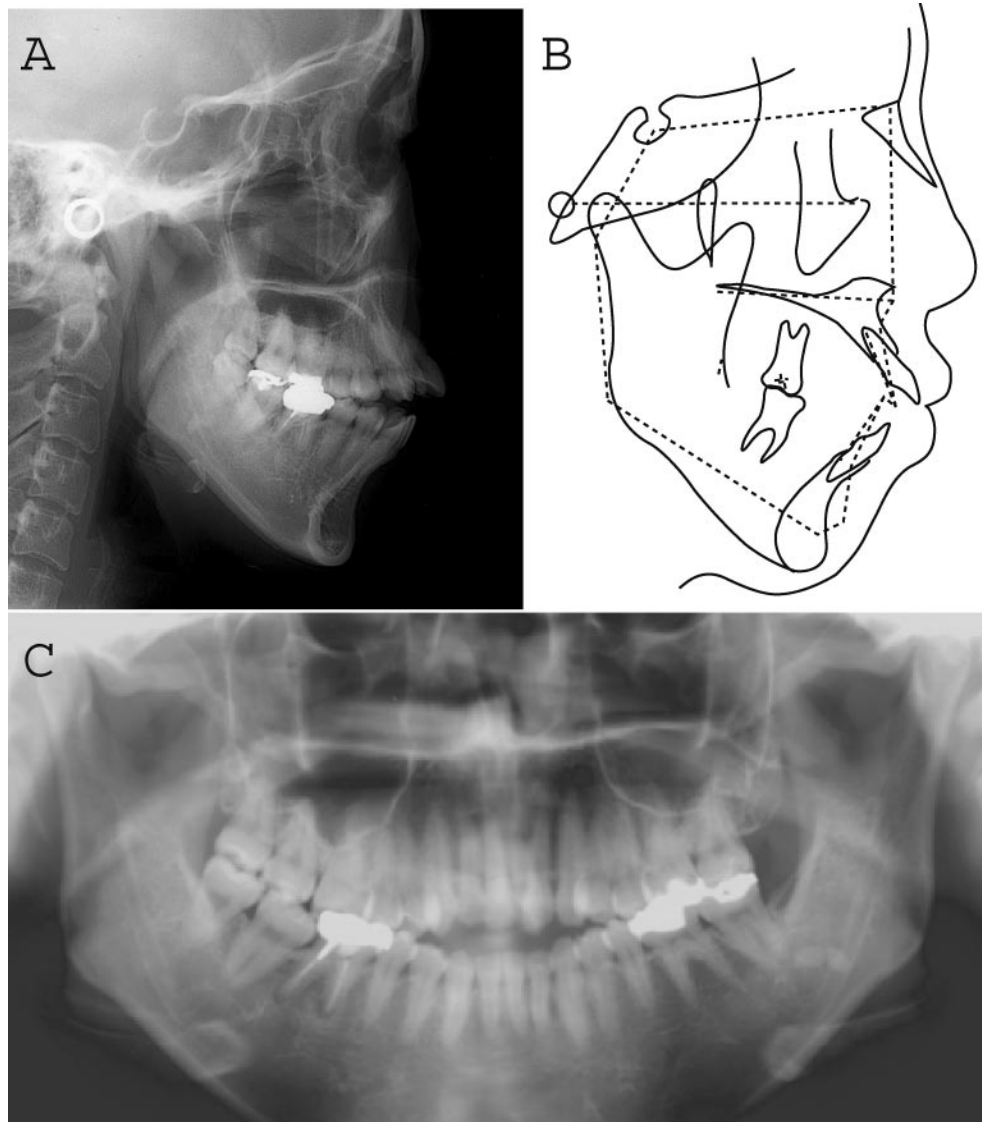


FIGURE 2. (A) Pretreatment cephalograph. (B) Tracing. (C) Panoramic radiograph. Tracing (solid lines) was superimposed with the mean profilogram (dotted line).

been extrusion of both upper and lower molars, and, therefore, we planned to implant titanium screws for use as anchorage to intrude both the upper and the lower molars.

Treatment progress

Before the start of orthodontic treatment, the upper and lower third molars were extracted. The metal prosthetic restorations of the lower first molars were removed because of their unconformable shape and esthetic problems, and provisional restorations were set until active orthodontic treatment was completed. The root canals of the lower left first molar were also treated because of a periapical lesion.

Titanium screws (2.3-mm diameter, 14-mm length; Keisei Medical Industrial Co Ltd, Tokyo, Japan) were inserted bilaterally in the zygomatic process of the maxilla and the

buccal alveolar bone of the mandible through the buccal mucosa (Figure 3). They were implanted after local anesthesia had been administered. Analgesics and antibiotics were prescribed to the patients for 3 days after the implantation.

A transpalatal arch appliance and a lower lingual arch appliance were placed between the first molars to compensate for the crown buccal torque that would be caused by the intrusion force (Figure 4). Then, the upper right first premolar and the left central incisor were extracted, and 0.022-inch slot, preadjusted edgewise appliances were placed in both arches. During the leveling phase, the lower left central incisor was extracted. After leveling and alignment with nickel-titanium archwires, 0.019- × 0.025-inch stainless steel archwires were placed, and retraction of the

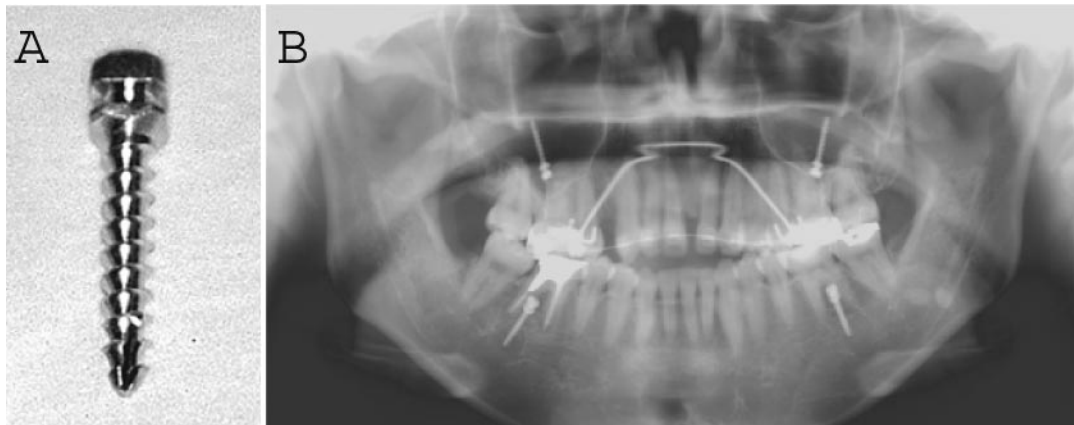


FIGURE 3. (A) Photograph of the titanium screw. (B) Panoramic radiograph after implantation of titanium screws.

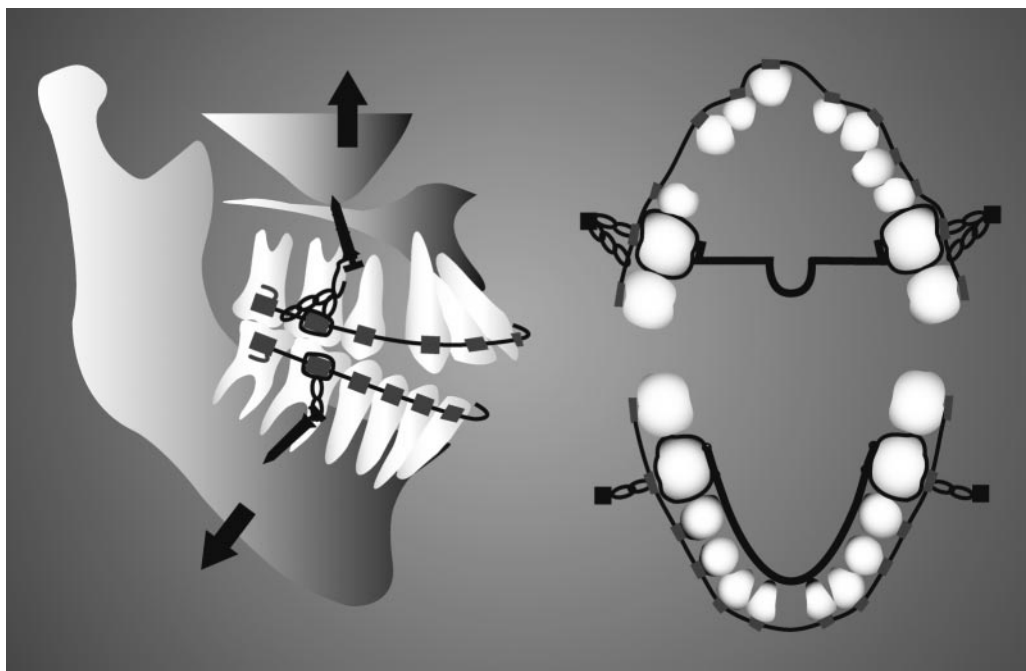


FIGURE 4. Schematic of intrusion molars.

anterior teeth was begun. Three months after the implantation of the titanium screws, loading of the intrusion force was started with elastic chains (Figure 4). Six months after the start of loading, overbite had increased to -1 mm (Figure 5). After the removal of the edgewise appliances, a tooth positioner was placed to retain both arches. The total active treatment period was 19 months.

The implant screw anchorage was stable for the entire duration of the treatment, and the screws were easily removed with a screwdriver during the retention phase. The upper left lateral incisor and the lower first molars were treated with prosthetic restorations.

RESULTS

The posttreatment facial photograph showed a dramatic change in the facial profile when compared with the pretreatment photograph (Figure 6). The retrognathic chin and convex profiles were corrected, resulting in a straight profile. The facial proportions were improved because of the decrease in the lower facial height. The strain in the circumoral musculature during lip closure disappeared.

Posttreatment cephalometric evaluation showed a skeletal Class I jaw base relationship (ANB 1.2). Clockwise rotation of the mandible had occurred (Figures 7 and 8; Table 1), and an Angle Class I molar relationship was achieved

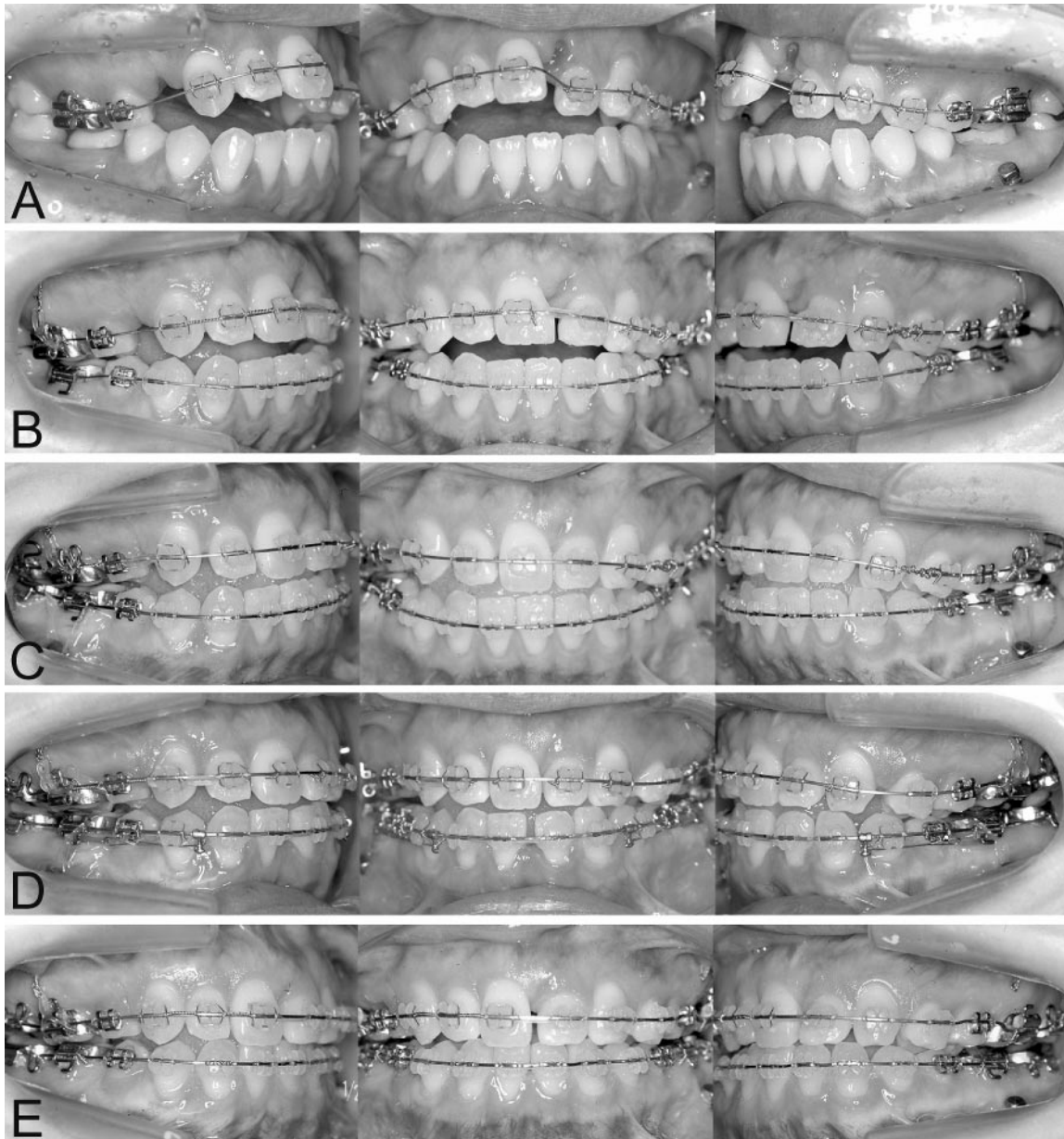


FIGURE 5. Photographs taken during the treatment progress. (A) Starting of the intrusion. (B) Three months after the start of the intrusion. (C) Six months later. (D) Nine months later. (E) 12 months later.

on both sides. Overjet and overbite had become 2.0 mm, and the anterior open bite had been corrected. Both upper and lower first molars were now intruded 3.0 mm toward the palatal plane and the mandibular plane. The upper incisors were minimally extruded, but the lower incisors were intruded. The occlusion was much more stable, and ideal intercuspation of the teeth was achieved. After active orthodontic treatment, functional problems were not observed in the examination for jaw movement. The positions of the TMJ discs on both sides were also normal in the MRI findings.

After one year of retention, the occlusion was stable, and

a good facial profile was also retained (Figure 9). Cephalometric analysis showed little change in mandibular position (Figure 10; Table 1). An esthetic smile was enhanced by the results of a laminate veneer restoration and a gingivoplasty combined with bone plastic surgery around the lateral incisor (Figure 9).

DISCUSSION

An anterior open bite is often caused by downward rotation of the jaws and/or excessive eruption of posterior teeth.² For nonsurgical treatment of these cases, MEAW is

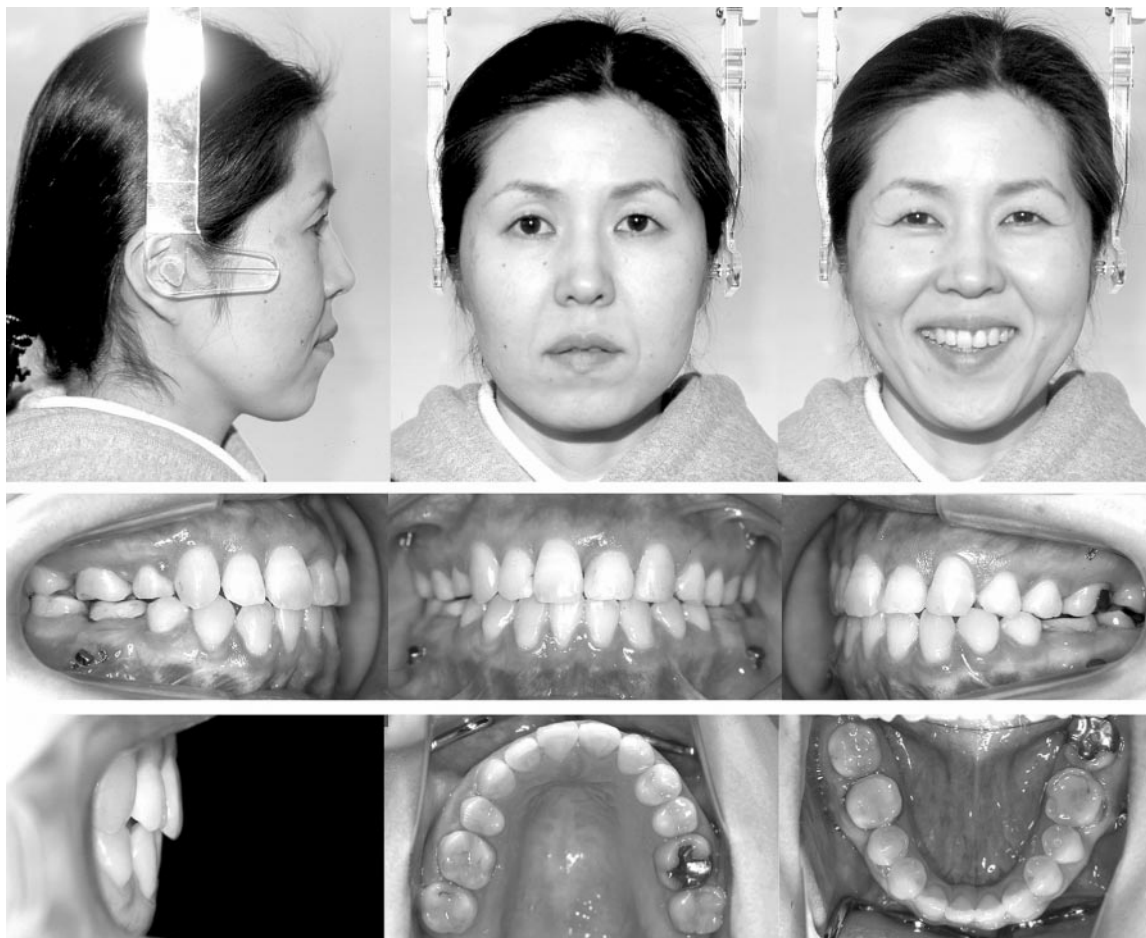

FIGURE 6. Postactive treatment photographs (age, 35 years three months).

sometimes used, and it is available for adequate overbite. The cephalometric evaluation of patients treated with MEAW shows remarkable changes in the dentition, but the changes that occurred in the skeletal pattern were very small.⁵ The intrusion of molars is relative to the extrusion of incisors because the force system depends on intermaxillary elastics. Extrusion of anterior teeth is often undesirable for treatment of skeletal open-bite cases when combined with maxillary vertical excess and a long-face tendency or the compensatory eruption of the anterior teeth. In the present case, the mandible was rotated downward, and the patient had a long-face tendency due to extrusion of both upper and lower molars. Therefore, we considered that absolute anchorage was required for intrusion of the molars.

Several methods to acquire bone anchorage have been reported. Dental implants are strong enough to resist the counteraction of orthodontic tooth movement, but they require complicated surgery for both placement and replacement and also involve higher medical costs.⁷⁻¹⁰ Miniplates have also been used for orthodontic anchorage.¹⁴⁻¹⁶ In anterior open-bite cases, two reports showed the usefulness

of the miniplate as a skeletal anchorage and for closure of the bite without extrusion of the anterior teeth.^{15,16} However, miniplates have the disadvantage of surgical damage and risk because of the need for a mucoperiosteal flap operation for both setting and removing them.¹⁸

When compared with dental implants for abutments, titanium screws, which were originally used for intermaxillary fixation and bone fixation, have the advantages of functioning as rigid anchorage against orthodontic loads, minimal anatomic limitation for placement, lower medical costs, more simple placement surgery, and less discomfort after implantation.^{11-13,18,19} Therefore, titanium screws have gradually come to be used for absolute anchorage for various tooth movements, intrusion or retraction of the anterior tooth,¹¹⁻¹³ and protraction of the lower molars.¹² In the present case, both upper and lower molars were extruded, and titanium screws were placed in the posterior region in both jaws. However, the posterior part of both jaws tends to have a thinner, more porous cortex and finer trabeculae.^{20,21} Therefore, the screws were placed in the zygomatic process in the maxilla. The mandible generally has a denser cortex and thicker trabeculae than the maxilla. However, according

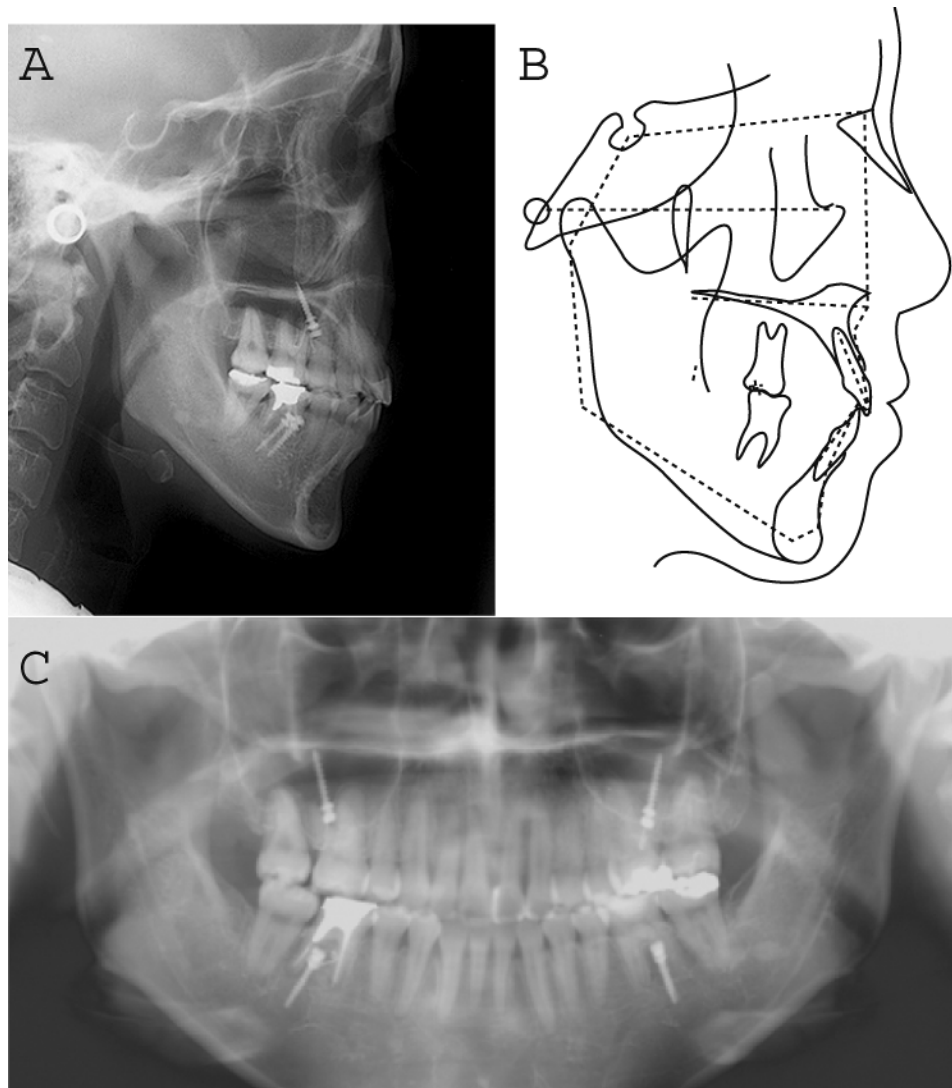


FIGURE 7. (A) Postactive treatment cephalograph. (B) Tracing. (C) Panoramic radiograph. Tracing (solid lines) was superimposed with the mean profilogram (dotted line).

to a recent study, a high-mandibular plane angle was found to be a risk factor for failure of screw-type implant anchors, and the diameter of the screw was significantly associated with its stability.¹⁸ In addition, it was reported that the buccal cortical bone in the case of a high-mandibular plane angle was thinner than that in the case of a low angle in the lower first molar region.²² Therefore, titanium screws, 2.3 mm in diameter and 14 mm in length, were placed for sufficient mechanical interdigitation because the mandibular plane angle was quite steep in this case. After the intrusion, the screws were retained until completion of active treatment to prevent possible relapse. In the retention phase, the screws were easily removed with a screwdriver.

As a result of intrusion of the upper and lower molars, the mandible rotated counterclockwise, and the severe anterior open bite was improved. Rotation of the mandible

caused advancement of the chin 8 mm at pogonion and improved the retrognathic appearance of the facial profile. The anterior facial height was significantly reduced, and straining of the circumoral musculature during lip closure disappeared. By preventing the anterior extrusion, an esthetic smile was achieved.

In previous reports, the intrusion of molars in one jaw was quite effective for overbite correction, but the facial profile improvement was poor because unwanted extrusion of molars occurred in the opposite jaw.^{15,16} In the present case, we intruded both upper and lower molars, and as a result of this treatment, the mandible was significantly rotated in a counterclockwise direction, and major skeletal changes were achieved. Therefore, it is suggested that the intrusion of molars in both jaws is desirable in cases of severe anterior open bite caused by extrusion of the upper

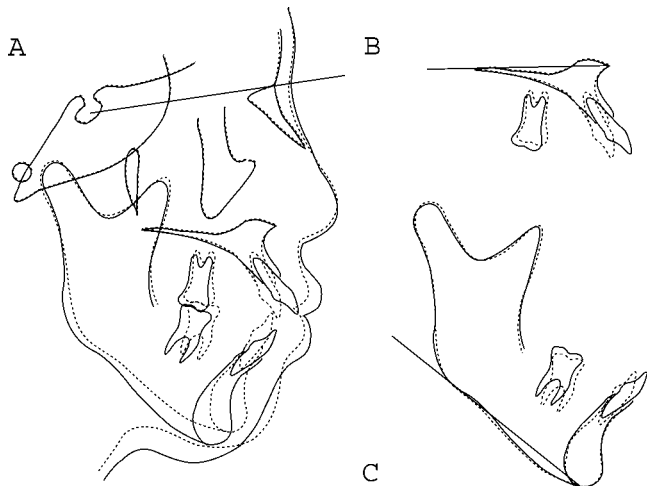


FIGURE 8. Superimposition of cephalometric tracings made before (solid line) and after (dotted line) treatment. (A) Superimposition on the Sella-Nasion plane at Sella. (B) Superimposition on the palatal plane at ANS. (C) Superimposition on the mandibular plane at Menton.

TABLE 1. Cephalometric Summary

Variables	Mean	SD	Pretreatment	Postac-tive treatment	Post-retention
Angle (°)					
ANB	2.8	2.44	4.1	1.2	1.0
SNA	80.8	3.61	77.3	77.0	77.0
SNB	77.9	4.54	73.2	75.8	76.0
Mp-FH	30.5	3.60	38.6	33.0	33.0
Go.A	122.1	5.29	136.7	136.6	136.4
U1-FH	112.3	8.26	128.2	111.5	111.8
L1-Mp	93.4	6.77	96.4	84.5	85.0
IIA	123.6	10.64	96.6	131.0	129.5
Occl.P	16.9	4.40	16.9	17.2	17.0
Liner (mm)					
S-N	67.9	3.65	70.9	71.0	70.8
N-Me	125.8	5.04	137.9	133.0	132.2
Me/NF	68.6	3.71	81.3	78.0	77.5
Go-Me	71.4	4.14	68.8	68.4	68.4
Ar-Me	106.6	5.74	113.5	113.6	113.5
OJ	3.1	1.07	7.1	2.3	2.1
OB	3.3	1.89	-7.0	2.2	2.0
U1/NF	31.0	2.34	33.1	35.4	34.6
U6/NF	24.6	2.00	31.6	28.8	28.9
L1/Mp	44.2	2.68	50.2	47.6	47.3
L6/Mp	32.9	2.50	37.4	34.8	35.0

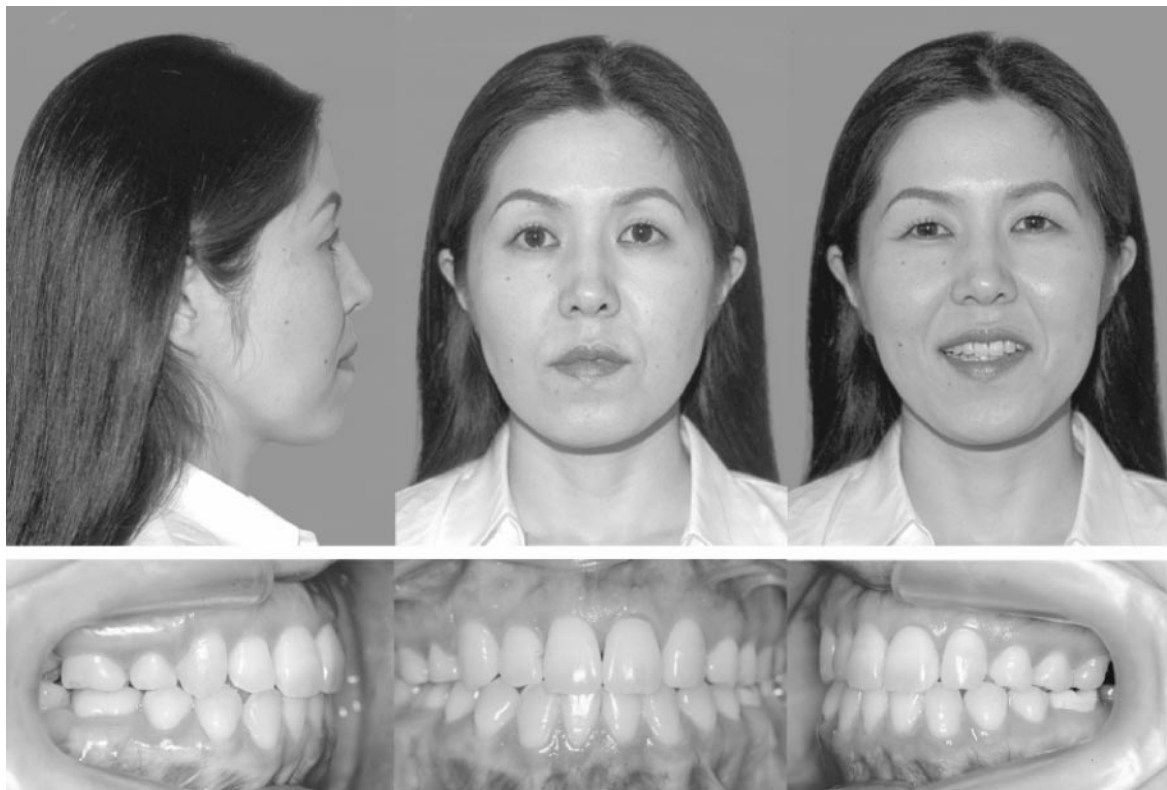

FIGURE 9. One-year postretention photographs (age, 36 years three months). The laminate veneer restoration and gingivoplasty combined with bone plastic surgery were performed around the upper left lateral incisor.

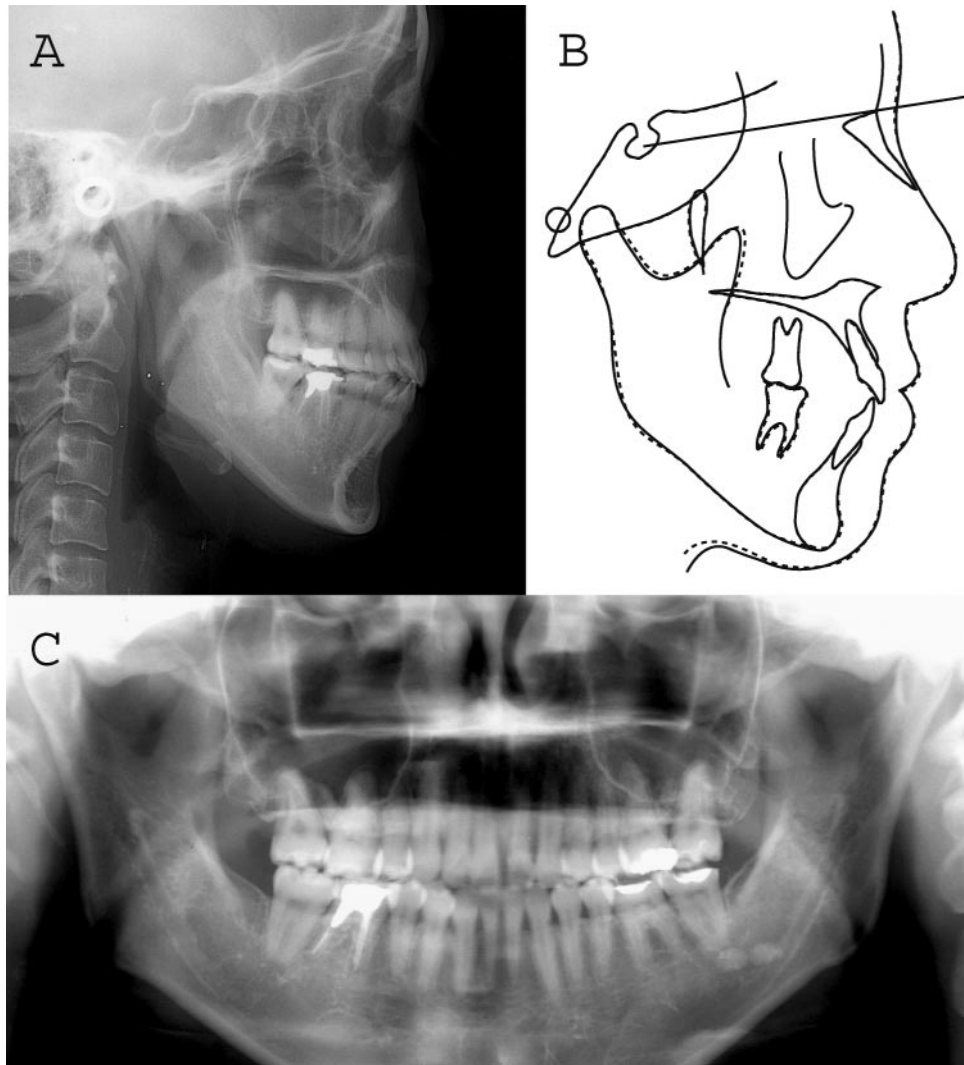


FIGURE 10. (A) One-year postretention cephalograph. (B) Superimposition of cephalometric tracing. (C) Panoramic radiograph. Tracing (solid lines) was superimposed with posttreatment tracing (dotted line) on the Sella-Nasion plane at Sella.

and lower molars. Our treatment results were acceptable and similar to those obtained by two-jaw orthognathic surgery, ie, rotation of the mandible after impaction of the maxilla.²³ Moreover, treatment using implant anchorage is minimally invasive and requires a shorter treatment period than orthognathic surgery. Therefore, there is a possibility that this method will become an alternative to orthognathic surgery.

In the present case, there were no TMD symptoms or functional problems before treatment. Nevertheless, after treatment a significant change in mandibular position occurred as a consequence of the molar intrusion, and functional adaptation was also achieved. It is well known that long-term stability can be achieved after surgical treatment for anterior open bite.^{23,24} In a recent report of one year of retention for anterior open-bite cases treated with miniplate

skeletal anchorage, 30% of the lower molar intrusion showed relapse.²⁵

In our case, little relapse was observed after a 1-year retention period, although molars in both jaws had been intruded approximately 3 mm. As a result of a significant counterclockwise rotation of the mandible caused by the intrusion of molars in both jaws, the functional adaptation in circumoral musculature may be easily achieved. We suggest that the functional adaptation in musculature should be an important factor in the retention of the correction of anterior open bites. However, long-term stability after the treatment for anterior open bite using implant anchorage remains unknown, and this remains a topic for future study in implant orthodontics.

This case had some problems specific to adult orthodontic treatment, ie, gingival recession, worn teeth, and many

prosthetic restorations. Because of the gingival recession around the upper left central incisor and the congenital absence of the lower left central incisor, we planned asymmetrical extraction of the upper left central incisor, upper right first premolar, and lower right central incisor. During active orthodontic treatment, composite resin was applied to the upper left lateral incisor for esthetic considerations. This resin filling also served to provide and maintain the mesiodistal crown width like that of the central incisor. After active orthodontic treatment, laminate veneer restoration and gingivoplasty combined with bone plastic surgery around the lateral incisor were performed. For esthetic requirements, grinding of the incisal edge of the upper left cuspid was also done. Before orthodontic treatment, the metal-covered crowns of the lower first molars were removed because of their uncomfortable shape and esthetic problems. Porcelain jacket crowns were set in both first molars during retention. As a result of these esthetic procedures combined with the orthodontic treatment, an excellent appearance was achieved.

REFERENCES

1. Epker BN, Fish LC. Surgical-orthodontic correction of openbite deformity. *Angle Orthod.* 1977;71:278–299.
2. Proffit WR, Phillips C, Dann C IV. Who seeks surgical-orthodontic treatment? *Int J Adult Orthod Orthognath Surg.* 1990;5:153–160.
3. Alexander CD. Open bite, dental alveolar protrusion, Class I malocclusion: a successful treatment result. *Am J Orthod Dentofacial Orthop.* 1999;116:494–500.
4. Smith GA. Treatment of an adult with a severe anterior open bite and mutilated malocclusion without orthognathic surgery. *Am J Orthod Dentofacial Orthop.* 1996;110:682–687.
5. Kim YH. Anterior open bite and its treatment with multiloop edgewise archwire. *Angle Orthod.* 1987;4:290–321.
6. Enacar A, Ugur T, Toroglu S. A method for correction of open bite. *J Clin Orthod.* 1996;30:43–48.
7. Turley PK, Kean C, Schur J, Stefanac J, Gray J, Hennes J, Poon LC. Orthodontic force application to titanium endosseous implants. *Angle Orthod.* 1988;58:151–162.
8. Ödman J, Lekholm U, Jemt T, Brånemark P-I, Thilander B. Osseointegrated titanium implants: a new approach in orthodontic treatment. *Eur J Orthod.* 1988;10:98–105.
9. Prosterman B, Prosterman L, Fisher R, Gornitsky M. The use of implants for orthodontic correction of an open bite. *Am J Orthod Dentofacial Orthop.* 1995;107:245–250.
10. Roberts WE, Helm FR, Marshall KJ, Gongloff RK. Rigid endosseous implants for orthodontic and orthopedic anchorage. *Angle Orthod.* 1989;59:247–256.
11. Creekmore TD, Eklund MK. The possibility of skeletal anchorage. *J Clin Orthod.* 1983;17:266–269.
12. Costa A, Raffaini M, Melsen B. Miniscrews as orthodontic anchorage: a preliminary report. *Int J Adult Orthod Orthognath Surg.* 1998;3:201–209.
13. Park HS, Bae SM, Kyung HM, Sung JH. Micro-implant anchorage for treatment of skeletal Class I bialveolar protrusion. *J Clin Orthod.* 2001;35:417–422.
14. Jenner JD, Fitzpatrick BN. Skeletal anchorage utilizing bone plates. *Aust Orthod J.* 1985;9:231–233.
15. Umemori M, Sugawara J, Mitani H, Nagasaka H, Kawamura H. Skeletal anchorage system for open-bite correction. *Am J Orthod Dentofacial Orthop.* 1999;115:166–174.
16. Sherwood KH, Burch JG, Thompson WJ. Closing anterior open bites by intruding molars with titanium miniplate anchorage. *Am J Orthod Dentofacial Orthop.* 2002;122:593–600.
17. Wada K, Matsushita K, Shimazaki S, Miwa Y, Hasuike Y, Susami R. An evaluation of a new case analysis of a lateral cephalometric roentgenogram. *J Kanazawa Med Univ.* 1981;6:60–70.
18. Miyawaki S, Koyama I, Inoue M, Mishima K, Sugahara T, Takano-Yamamoto T. Factors associated with the stability of titanium screws placed in the posterior region for orthodontic anchorage. *Am J Orthod Dentofacial Orthop.* In press.
19. Deguchi T, Takano-Yamamoto T, Kanomi R, Hartsfield JK Jr, Roberts WE, Garetto GP. The use of small titanium screws for orthodontic anchorage. *J Dent Res.* 2003;82:377–381.
20. Adell R, Lekholm U, Rockler B, Braunemark PI. A 15 year study of osseointegrated implants in the treatment of the edentulous jaw. *Int J Oral Surg.* 1981;10:387–416.
21. Hobos S, Ichida E, Garcia LT. *Osseointegration and Occlusal Rehabilitation.* London, UK: Quintessence Publishing Co; 1989: 33–54.
22. Tsunori M, Mashita M, Kasai K. Relationship between facial types and tooth and bone characteristics of the mandible obtained by CT scanning. *Angle Orthod.* 1998;68:557–562.
23. Proffit WR, Bailey LJ, Phillips C, Turvey TA. Long-term stability of surgical open-bite correction by Le Fort I osteotomy. *Angle Orthod.* 2000;70:112–117.
24. Hoppenreijts TJ, Freihofer HP, Stoelinga PJ, Tuinzing DB, van't Hof MA, van der Linden FP, Nottet SJ. Skeletal and dento-alveolar stability of Le Fort I intrusion osteotomies and bimaxillary osteotomies in anterior open bite deformities. A retrospective three-centre study. *Int J Oral Maxillofac Surg.* 1997;26:161–175.
25. Sugawara J, Baik UB, Umemori M, Takahashi I, Nagasaka H, Kawamura H, Mitani H. Treatment and posttreatment dentoalveolar changes following intrusion of mandibular molars with application of a skeletal anchorage system (SAS) for open bite correction. *Int J Adult Orthod Orthognath Surg.* 2002;17:243–253.