

Orthodontic Treatment of a Patient with an Impacted Maxillary Second Premolar and Odontogenic Keratocyst in the Maxillary Sinus

著者	Tanimoto Yuko, Miyawaki Shouichi, Imai Mikako, Takeda Ryoko, Takano-Yamamoto Teruko
journal or publication title	Angle Orthodontist
volume	75
number	6
page range	1077-1083
year	2005
URL	http://hdl.handle.net/10097/51514

Orthodontic Treatment of a Patient with an Impacted Maxillary Second Premolar and Odontogenic Keratocyst in the Maxillary Sinus

Yuko Tanimoto^a; Shouichi Miyawaki^b; Mikako Imai^c; Ryoko Takeda^d; Teruko Takano-Yamamoto^e

Abstract: An eight-year-, four-month-old girl was brought to the orthodontic clinic of Okayama University Medical and Dental Hospital. The patient had an impacted upper left second premolar because of an odontogenic keratocyst and showed a skeletal Class II jaw base relationship. At the age of six years four months, marsupialization of a cyst was performed at the Okayama University Medical and Dental Hospital because the patient had shown a swelling of the left cheek because of the cyst. The upper left second premolar was located in the roof of the maxillary sinus. The cyst was histopathologically diagnosed as an odontogenic keratocyst. At the age of nine years 10 months and after regaining the space for eruption of the premolar, the impacted premolar erupted without traction. At the age of 12 years five months, edgewise treatment was initiated, which continued for three years. After removing the edgewise appliance, an optimum occlusion was achieved. The occlusion was maintained without recurrence of the keratocyst after a retention period of five years. (*Angle Orthod* 2005;76:1077–1083.)

Key Words: Impacted tooth; Odontogenic keratocyst; Marsupialization

INTRODUCTION

The odontogenic keratocyst was first described by Philipsen in 1956.¹ The incidence of odontogenic keratocyst among all cysts is reported to be 7.6%.² For the exact diagnosis, histopathological examination is

generally necessary.³ The keratocyst was more frequently observed in the mandible, particularly in the mandibular third molar region, than in the maxilla.^{4,5} The mean age of affected patients is approximately 34.5 years, and the incidence was approximately 1.3 times higher in male patients than that in female patients.^{2,4} It is known that the odontogenic keratocyst frequently recurs after enucleation,^{4,6} particularly within the first five years,⁷ because complete enucleation of a keratocyst is often difficult. Although complete resection of a keratocyst, including the associated tooth, decreases the recurrence rate, the procedure often causes morbidity.^{8,9} Recently, it has been reported that marsupialization is a better alternative for the treatment of keratocyst.^{5,10}

Few reports have described the eruption of an impacted tooth associated with an odontogenic keratocyst in the maxillary sinus.¹¹ Furthermore, there have not been any case reports in which orthodontic treatment was performed in a patient with an impacted tooth associated with a keratocyst, although there was a case report in which a keratocyst occurred during orthodontic treatment.¹² This case report describes the successful orthodontic treatment of a patient with an impacted maxillary second premolar and odontogenic keratocyst in the maxillary sinus without recurrence of the keratocyst, even five years after retention.

^a Assistant Professor, Department of Orthodontics and Dentofacial Orthopedics, Okayama University Graduate School of Medicine and Dentistry, Okayama, Japan.

^b Associate Professor, Department of Orthodontics and Dentofacial Orthopedics, Okayama University Graduate School of Medicine and Dentistry, Okayama, Japan.

^c Postgraduate student, Department of Orthodontics and Dentofacial Orthopedics, Okayama University Graduate School of Medicine and Dentistry, Okayama, Japan.

^d Instructor, Department of Orthodontics and Dentofacial Orthopedics, Okayama University Graduate School of Medicine and Dentistry, Okayama, Japan.

^e Professor and Chairperson, Department of Orthodontics and Dentofacial Orthopedics, Okayama University Graduate School of Medicine and Dentistry, Okayama, Japan.

Corresponding author: Teruko Takano-Yamamoto, DDS, PhD, Department of Orthodontics and Dentofacial Orthopedics, Okayama University Graduate School of Medicine and Dentistry, 2-5-1 Shikata-Cho, Okayama 700-8525, Japan (e-mail: tyamamo@md.okayama-u.ac.jp).

Accepted: January 2005. Submitted: December 2004.

© 2005 by The EH Angle Education and Research Foundation, Inc.

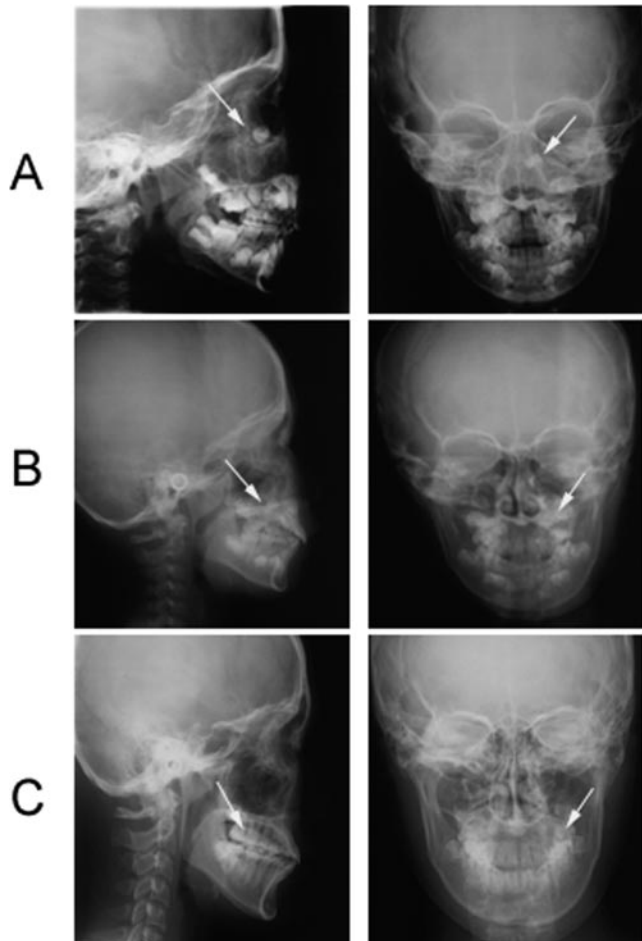


FIGURE 1. Cephalometric radiographs. Arrows indicate the impacted premolar. (A) Before marsupialization: (six years three months). (B) Pretreatment: (eight years four months). (C) Posttreatment: (15 years four months). Left: lateral view; right: frontal view.

CASE REPORT

A six-year-, two-month-old girl was brought to the clinic of Oral and Maxillofacial Surgery I of Okayama University Medical and Dental Hospital with complaints of left cheek swelling and ipsilateral nasal obstruction. The upper left second premolar was located around the roof of the sinus because of the cyst (Figure 1A). The cyst was surgically marsupialized by oral and maxillofacial surgeons. The cyst was histopathologically diagnosed as an odontogenic keratocyst.¹¹

After marsupialization, the patient was introduced to the orthodontic clinic when she was eight years and four months old (Figures 1B, 2A, 3A, and 4A). The patient exhibited an asymmetric face because of the swelling due to the keratocyst, and her facial profile was convex because of the mandibular retroposition. Mentalis strain was observed when the lips were closed (Figure 3A). The molar relationship was Class I on the right side and Class II on the left side. The upper left first molar was inclined mesially and was prevented from erupting by the presence of the deciduous second molar. The overjet was 3.4 mm, and overbite was 4.3 mm (Figure 4A). The upper dentition was asymmetrical because of the impacted second premolar, and the lower dentition was symmetrical. The mandibular anterior teeth were mildly crowded.

Panoramic radiographs showed the impacted premolar located in the maxillary sinus. Both the root formation of the impacted left premolar and that of the right premolar were less than one-fifth that of a normal root. The upper left first molar was tilted mesially, and the root apex contacted the germ of the upper left second molar (Figure 2A).

Lateral cephalometric radiographs showed a skele-

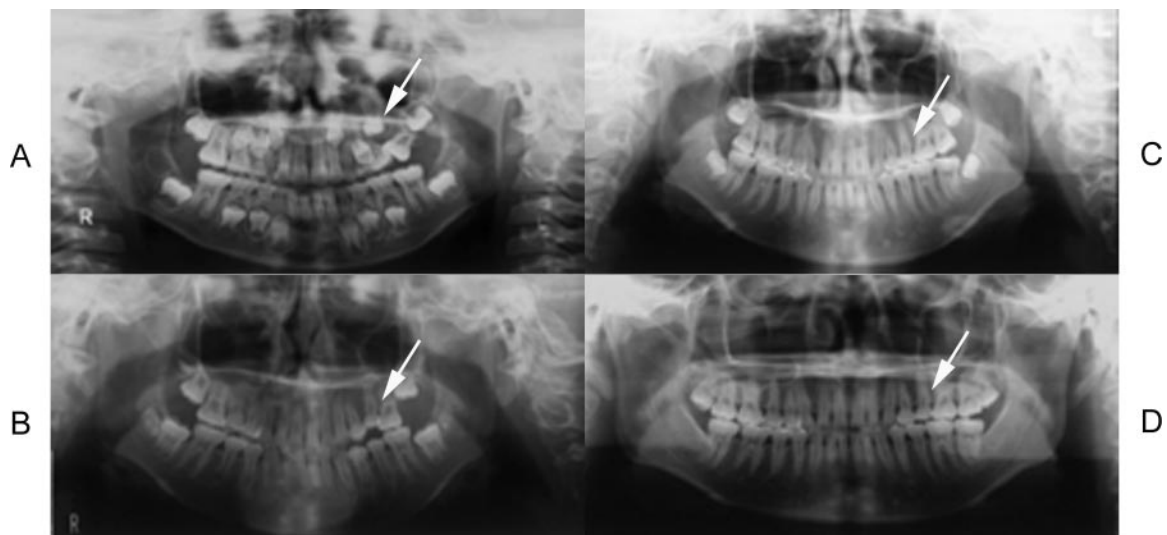


FIGURE 2. Panoramic radiographs. Arrows indicate the impacted premolar. (A) Pretreatment: (eight years four months). (B) Pre-edge-wise treatment: (11 years two months). (C) Posttreatment: (15 years four months). (D) After five years of retention: (20 years six months).

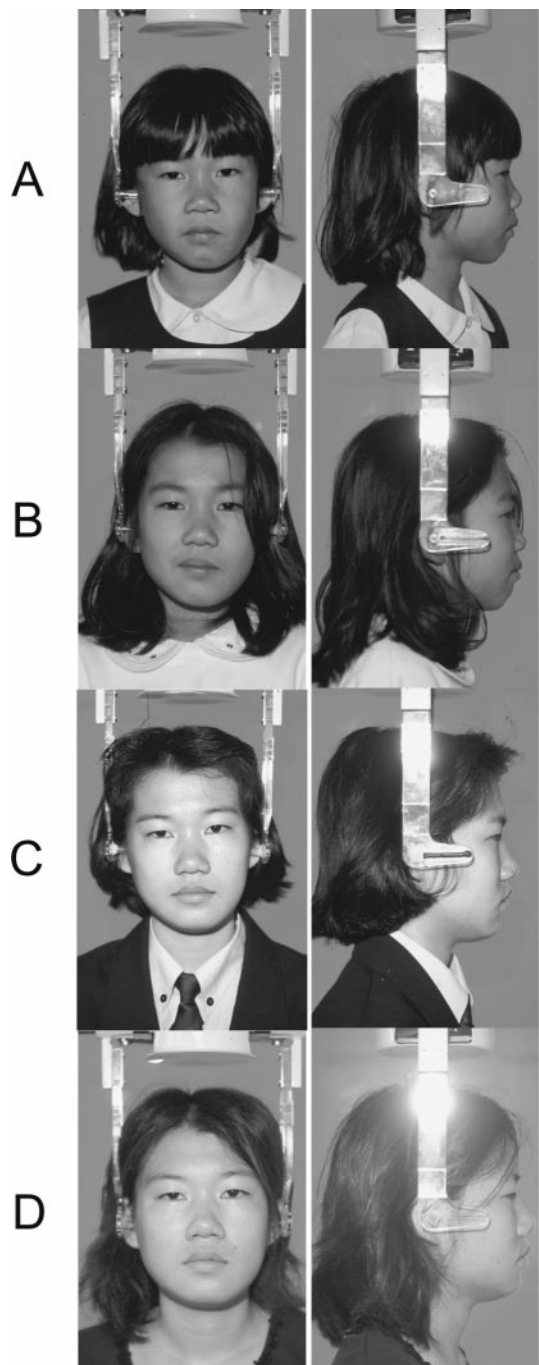


FIGURE 3. Facial photographs. (A) Pretreatment: (eight years four months). (B) Pre-edgewise treatment: (11 years two months). (C) Posttreatment: (15 yrs four months). (D) After five years of retention: (20 yrs six months). Left: frontal view; right: lateral view.

tal Class II jaw base relationship (ANB: 8.5°), the retrognathic mandible (SNA: 83.0° , SNB: 74.5°), and average mandibular plane angle (Mp-FH: 39.4°) compared with the normative values for Japanese females of a corresponding age¹³ (Figure 6; Table 1). Slight lingual inclination of the maxillary incisors and labial

inclination of the mandibular incisors were observed (U1-SN: 101.3° ; L1-MP: 99.0° ; Table 1).

Treatment planning

In the mixed dentition, treatment was planned as follows.

- Correction of the skeletal Class II jaw base relationship using a functional appliance such as an activator.
- Correction of the mesially inclined upper left first molar.
- Regaining eruption space for the impacted upper left second premolar.
- Correction of the molar relationship using a straight pull headgear.
- Careful observation after marsupialization of the keratocyst by serial radiographs for five years.

In the early permanent dentition, and when there was no recurrence of the keratocyst, orthodontic treatment was planned as follows.

- Alignment of teeth and achievement of an ideal occlusion using an edgewise appliance.
- Retention after edgewise treatment.

Treatment progress

A functional appliance (activator) was applied at the age of eight years four months for a period of six months. The upper left second deciduous molar was extracted, and brackets were bonded onto the upper left first premolar and first molar. Using a sectional arch and distal extension lingual arch appliance, the first molar was moved to an upright position (Figure 5).¹⁴ The maxillary left first molar was improved, and space for eruption of the impacted second premolar was gained.

The impacted premolar gradually erupted into the space without traction (Figure 5E). The upper left second premolar half erupted at the age of 11 years two months. A headgear was applied at the age of 11 years two months (Figures 2B, 3B and 4B), and edgewise treatment was initiated at the age of 12 years five months. At the age of 15 years two months, all appliances were removed. A Begg-type retainer and spring retainer were inserted in the upper and lower dentitions, respectively (Figures 1C, 2C, 3C, and 4C).

Treatment results

Optimal intercuspation of teeth was achieved without recurrence of the keratocyst (Figure 4C). The root of the impacted second premolar showed normal morphology without root deformation (Figure 2C). A Class I molar relationship was achieved (Figure 4C). The fa-

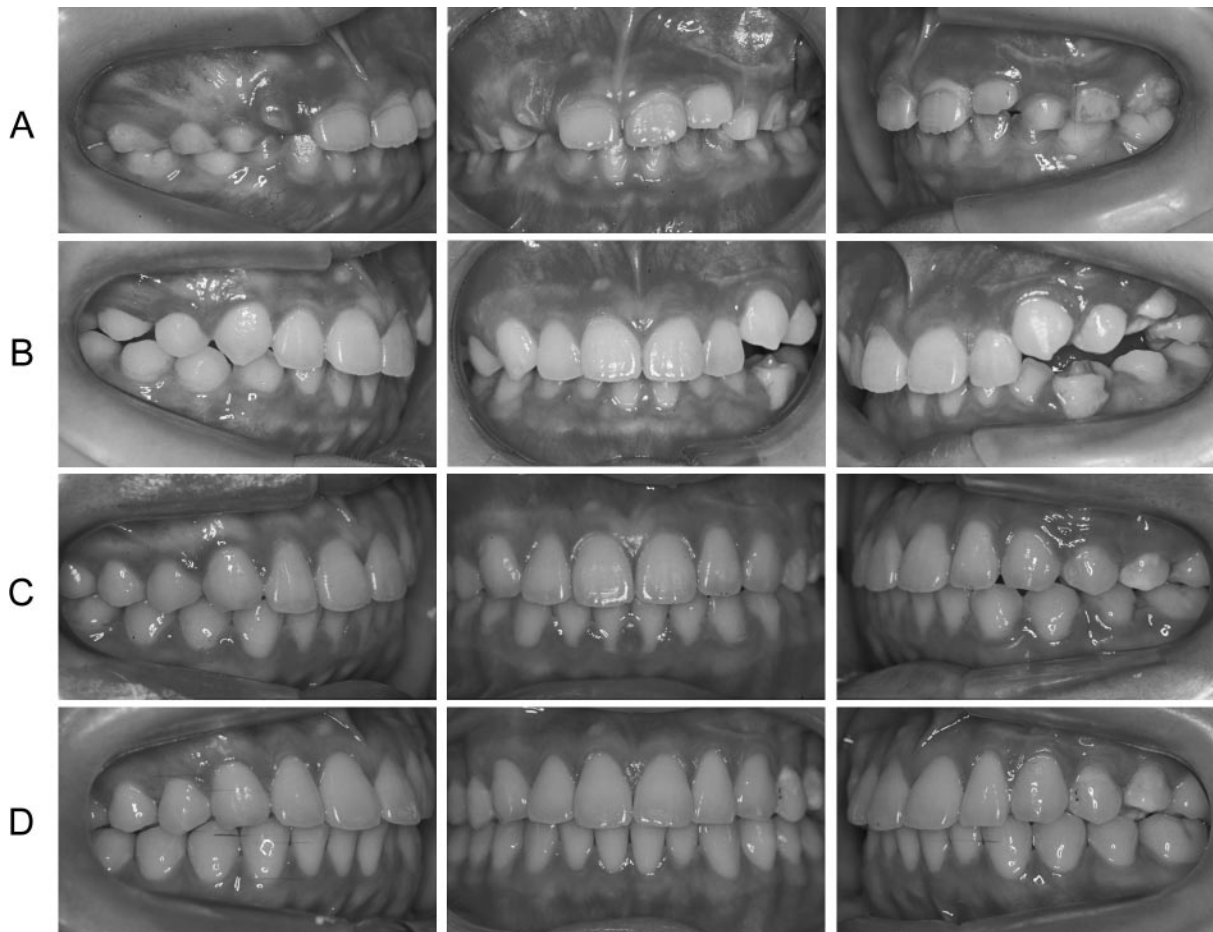

FIGURE 4. Intraoral photographs. (A) Pretreatment: (eight years four months). (B) Pre-edge-wise treatment: (11 years two months). (C) Posttreatment: (15 years four months). (D) After five years of retention: (20 years six months). Left: lateral view on the right side; center: frontal view; right: lateral view on the left side.

cial profile changed from convex to straight, and the mentalis strain disappeared (Figure 3C). The mandibular body length increased, and a skeletal Class I jaw base relationship was achieved (ANB: 3.8°; Figure 6; Table 1).

Acceptably good occlusion and facial profile were maintained after a retention period of five years two months (Figures 2D, 3D, and 4D) without recurrence of keratocyst. During the retention period, the ANB angle increased from 3.8 to 4.6° (ANB). The maxillary incisors were inclined labially (from 111.9° to 114.3° of U1-SN; Table 1). The patient did not have any TMD symptoms such as TMJ pain, TMS sound and difficulty in jaw-opening throughout the treatment period including the retention period.

DISCUSSION

Regarding treatment of an odontogenic keratocyst, removal of the cyst including the associated tooth and surrounding bone has been generally performed.^{8,12} In the present case, marsupialization of the cyst was per-

formed¹¹ because the patient was still growing. If the cyst and the associated tooth were surgically removed, maxillary growth might have been disrupted because of surgical invasion. Recently, it has been reported that marsupialization of the keratocyst is an effective alternative.^{5,10} Because the recurrence rate of keratocyst is higher than that of other cysts,⁶ we considered that long-term careful observation is necessary after marsupialization of the keratocyst. Therefore, although orthodontic treatment cannot prevent the recurrence of keratocyst, we consider that the periodic dental examination with panoramic radiographs is useful to detect a recurrence of the keratocyst earlier.

It has been reported that the eruption speed of the impacted tooth associated with a cyst is faster three months after marsupialization than that at other times, regardless of the degree of root formation or kind of cyst.¹⁵ In the present case, the impacted premolar rapidly moved downward during the first three months after marsupialization, as was reported previously.¹⁵

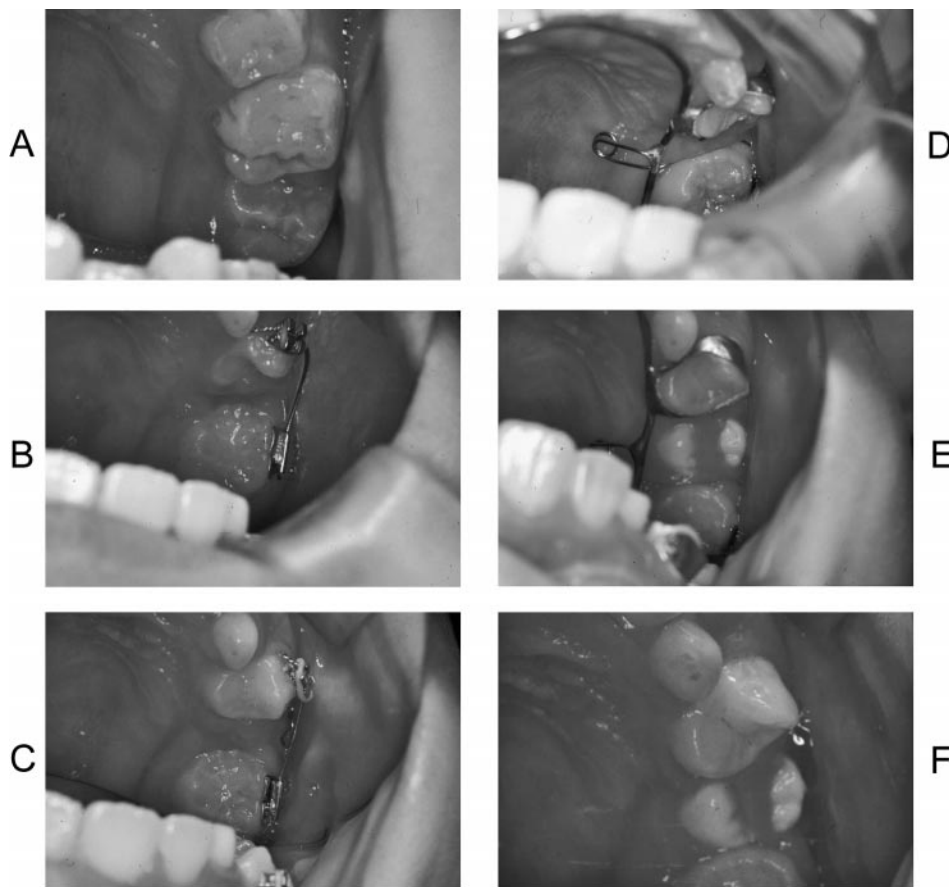


FIGURE 5. Intraoral photographs during the space regaining for the impacted tooth eruption. (A) Pretreatment: (eight years four months). (B) During treatment with sectional arch wire appliance: (nine years zero months). (C) During treatment with sectional archwire appliance: (nine years four months). (D) During treatment with lingual arch appliance: (nine years seven months). (E) During treatment with lingual arch appliance: (10 years zero months). (F) After treatment with lingual arch appliance: (10 years two months).

TABLE 1. Changes in Cephalometrical Data

Measurements	8 y 4 mo		11 y 4 mo		15 y 2 mo		20 y 6 mo	
	Value	Z-Score ^a	Value	Z-Score ^a	Value	Z-Score ^a	Value	Z-Score ^a
N-S (mm)	66.1	1.09	68.5	1.07	71.6	1.04	72.3	1.06
Ar-Me (mm)	91.4	0.00	101.7	0.90	114.9	1.39	114.2	1.27
N-Me (mm)	111.6	0.68	118.0	0.85	126.3	0.11	126.1	0.01
SNA (°)	83.0	0.46	83.8	0.78	83.6	0.58	84.6	0.83
SNB (°)	74.5	-1.01	77.7	0.03	79.8	0.26	80.0	0.19
ANB (°)	8.5	2.43	6.1	1.42	3.8	0.41	4.6	0.73
MP-SN (°)	39.4	0.13	35.2	-0.81	34.0	-0.68	32.0	-0.81
Gonial angle (°)	126.9	-0.08	123.8	-0.67	124.4	0.32	121.7	-0.32
Overjet (mm)	3.4	0.81	5.2	0.84	2.0	-0.84	3.1	-0.18
Overbite (mm)	4.3	1.04	4.9	1.01	1.3	-1.21	2.8	-0.31
U1-SN (°)	101.3	-0.46	107.7	0.11	111.9	0.61	114.3	0.72
L1-MP (°)	99.0	1.18	98.3	1.13	105.1	1.93	105.3	1.96

^a Z-score was calculated as (value - norm)/1 SD using the norms and SDs of normal Japanese females of the corresponding age.¹³

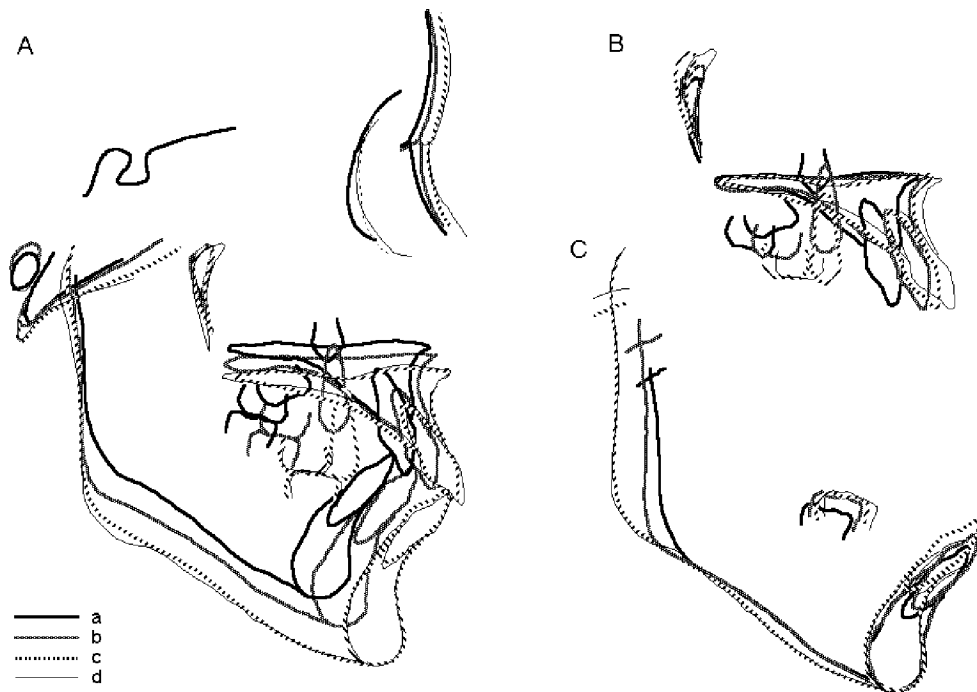


FIGURE 6. Superimposition of cephalometric tracings. (A) Superimposition on the SN Plane registered at S. (B) Superimposition on the palatal plane registered at Ptm. (C) Superimposition on the mandibular plane registered at Me. a: pretreatment: (eight years four months); b: pre-edge-wise treatment: (11 years two months); c: posttreatment: (15 years four months); d: after five years of retention: (20 years six months).

The traction on an impacted tooth with an immature root, often causes root resorption, root deformation, and pulpitis.¹⁶ In the present case, the root length of the impacted premolar was less than one-fifth that of a normal root, and the root apex was open at the initial stage. Therefore, we did not apply traction to the impacted premolar because a normal eruption was expected, and we only observed the impacted tooth although we were creating a space for tooth eruption. As a result, the impacted tooth erupted naturally. The present case was successful, but we considered that there is a possibility that orthodontists should apply traction to an impacted tooth if the eruption power is lost. Furthermore, the present case of odontogenic keratocyst was rare because the region of the cyst, patient age, and sex did not coincide with those reported in the majority of patients with keratocyst.^{2,4,5} Therefore, it is suggested that careful observation and orthodontic treatment during optimal times is necessary in a growing patient with an impacted tooth and odontogenic keratocyst.

ACKNOWLEDGMENT

The authors would like to express their gratitude to the surgeons of the clinic of Oral and Maxillofacial Surgery I of Okayama University Medical and Dental Hospital.

REFERENCES

1. Philipsen HP. Om keratocyster (Kolesteatomer) i kaeberne. *Tandlaegebladet*. 1956;60:963.
2. Browne RM. The odontogenic keratocyst. Clinical aspects. *Br Dent J*. 1970;128:225–231.
3. Browne RM. The odontogenic keratocyst. Histological features and their correlation with clinical behavior. *Br Dent J*. 1971;131:249–259.
4. Voorsmit RA, Stoelinga PJ, van Haelst UJ. The management of keratocysts. *J Maxillofac Surg*. 1981;9:228–236.
5. Zhao YF, Wei JX, Wang SP. Treatment of odontogenic keratocysts: a follow-up of 255 Chinese patients. *Oral Surg Oral Med Oral Pathol Oral Radiol Endod*. 2002;94:151–156.
6. Zachariades N, Papanicolaou S, Triantafyllou D. Odontogenic keratocysts: review of the literature and report of sixteen cases. *J Oral Maxillofac Surg*. 1985;43:177–182.
7. Stoelinga PJ. Long-term follow-up on keratocysts treated according to a defined protocol. *Int J Oral Maxillofac Surg*. 2001;30:14–25.
8. Ephros H, Lee HY. Treatment of a large odontogenic keratocyst using the Brosch procedure. *J Oral Maxillofac Surg*. 1991;49:871–874.
9. Blanas N, Freund B, Schwartz M, Furst IM. Systematic review of the treatment and prognosis of the odontogenic keratocyst. *Oral Surg Oral Med Oral Pathol Oral Radiol Endod*. 2000;90:553–558.
10. Nakamura N, Mitsuyasu T, Mitsuyasu Y, Taketomi T, Higuchi Y, Ohishi M. Marsupialization for odontogenic keratocysts: long-term follow-up analysis of the effects and changes in growth characteristics. *Oral Surg Oral Med Oral Pathol Oral Radiol Endod*. 2002;94:543–553.
11. Takagi S, Koyama S. Guided eruption of an impacted second premolar associated with a dentigerous cyst in the maxillary sinus of a 6-year-old child. *Oral Maxillofac Surg*. 1998;56:237–239.
12. Banks PA. Pathologically induced molar extrusion—a report

- of an unexpected odontogenic keratocyst. *Br J Orthod.* 1990;17:119–125.
13. Wada K. An evaluation of a new case analysis of a lateral cephalometric roentgenogram. *J Kanazawa Med Univ.* 1981;6:60–70.
 14. Sakuda M, Taki S, Hayashi I, Wada K, Kim S, Ozawa Y, Otsuka T, Yamakawa M. An idea for distal movement of molar teeth: a distal extension lingual arch. *Nippon Kyosei Shika Gakkai Zasshi.* 1974;33:195–201.
 15. Miyawaki S, Hyomoto M, Tsubouchi J, Kirita T, Sugimura M. Eruption speed and rate of angulation change of a cyst-associated mandibular second premolar after marsupialization of a dentigerous cyst. *Am J Orthod Dentofacial Orthop.* 1999;116:578–584.
 16. Ohya N, Ohya T. Tooth movement of an impacted lower 2nd premolar in the root developmental stage—a follow-up radiographic observation on the root formation. *Nippon Kyosei Shika Gakkai Zasshi.* 1990;49:379–391.