

## Impairment of the swallowing reflex in exacerbations of COPD.

著者	Kobayashi Seiichi, Kubo Hiroshi, Yanai Masaru
journal or publication title	Thorax
volume	62
number	11
page range	1017-1017
year	2007
URL	<a href="http://hdl.handle.net/10097/52719">http://hdl.handle.net/10097/52719</a>

doi: 10.1136/thx.2007.084715

various potential confounders across the life course. What about children with respiratory symptoms early in life? Studies have shown that there is an association between initial airway symptoms and later lung function and respiratory illnesses,<sup>3</sup> and that subjects with asthma have persistent reduced lung function.<sup>4</sup> Finally, did the authors account for family history of asthma and/or atopy or allergic sensitisation? In my opinion, many confounders and factors that may have an effect on the outcome were not addressed adequately in this paper, so the conclusions drawn may not be relevant.

#### Chandra Sekhar Devulapalli

Department of Paediatrics, Ringerike Hospital, NO-3504 Hønefoss, Norway; c.s.devulapalli@medisin.uio.no

Competing interests: None.

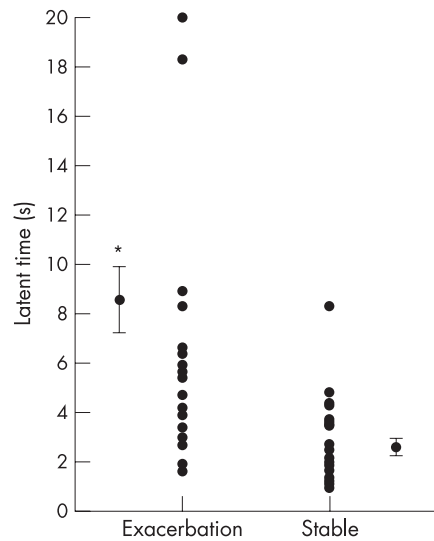
#### References

- 1 Canoy D, Pekkanen J, Elliott P, *et al*. Early growth and adult respiratory function in men and women followed from the fetal period to adulthood. *Thorax* 2007;**62**:396–402.
- 2 Laerum BN, Svanes C, Gulsvik A, *et al*. Is birth weight related to lung function and asthma symptoms in Nordic-Baltic adults? *Respir Med* 2004;**98**:611–8.
- 3 Martinez FD, Wright AL, Taussig LM, *et al*. Asthma and wheezing in the first six years of life. The Group Health Medical Associates. *N Engl J Med* 1995;**332**:133–8.
- 4 Sears MR, Greene JM, Willan AR, *et al*. A longitudinal, population-based, cohort study of childhood asthma followed to adulthood. *N Engl J Med* 2003;**349**:1414–22.

### Impairment of the swallowing reflex in exacerbations of COPD

An exacerbation of chronic obstructive pulmonary disease (COPD) has a serious impact on disease progression and is associated with high medical costs, but the cause of about one-third of exacerbations cannot be identified.<sup>1</sup> Adequate protective reflexes in the airways play an important role in the prevention of aspiration of bacteria-containing oropharyngeal or gastric secretions. Impairment of these reflexes, such as the swallowing reflex, therefore represents a potential risk factor for exacerbations of COPD. We have conducted a cross-sectional survey to evaluate the prevalence of impairment of the swallowing reflex in patients with COPD and to determine whether this is a risk factor for COPD exacerbations.

Fifty clinically stable patients with COPD were enrolled from the outpatient clinic of Ishinomaki Red Cross Hospital, Ishinomaki, Japan. Patients who were current smokers and those with oral corticosteroid use, oral and pharyngeal cancer, previous head and neck surgery, neuromuscular disease and oesophageal disease were excluded. Twenty-five patients (22 men and 3 women) had at least one exacerbation during the previous year, while the other 25 patients (21 men and 4 women) were stable. In the exacerbation group the patients had 2.4 (range 1–10) exacerbations per year, and 20 patients (80%) required hospital admission. There was no significant difference between the stable group and the exacerbation group in age (mean (SE) 75.0 (1.3) years vs 77.2 (1.0) years), forced expiratory volume in 1 s (FEV<sub>1</sub>) (mean (SE) 1.11 (0.11) l vs 1.07 (0.09) l), percentage predicted



**Figure 1** Comparison of latent time of the swallowing reflex in patients with exacerbations of chronic obstructive pulmonary disease and those with stable disease.

value of FEV<sub>1</sub> (mean (SE) 47.1 (3.7)% vs 50.1 (3.7)%) and the rate of home oxygen therapy (4% vs 20%). All patients were eating an entirely oral diet without complaining of dysphagia prior to enrolment.

We evaluated the swallowing reflex on the basis of the latency of response to the onset of the swallowing action timed from the injection of 1 ml distilled water into the pharynx through a nasal catheter.<sup>2</sup> The mean (SE) latent time of the swallowing reflex was significantly longer in the exacerbation group than in the stable group (8.6 (1.3) s vs 2.6 (0.3) s,  $p < 0.001$ ; fig 1). We classified a response as normal or impaired according to whether the swallowing reflex was induced within 3 s of the injection. In the exacerbation group 22 of 25 patients (88%) exhibited an impaired response compared with 8 of 25 patients (32%) in the stable group ( $p < 0.001$ ). Impairment of the swallowing reflex was significantly associated with an exacerbation of COPD (relative risk 2.8, 95% confidence interval 1.5 to 5.0).

These results indicate that there is a high incidence of impairment of the swallowing reflex in patients with COPD and this is a risk factor for an exacerbation of COPD. To date, there are few published reports available on swallowing dysfunction in patients with COPD.<sup>3–5</sup> The impact of impairment of the swallowing reflex in COPD exacerbations has not been clarified. The findings of our study highlight a novel risk factor for exacerbations of COPD and raise the possibility that precautions against aspiration could be useful to prevent these exacerbations.

#### Acknowledgements

The authors thank Dr Naoya Fujino for data collection.

#### Seiichi Kobayashi

Department of Respiratory Medicine, Ishinomaki Red Cross Hospital, Ishinomaki, Japan

#### Hiroshi Kubo

Department of Geriatrics and Respiratory Medicine, Tohoku University School of Medicine, Sendai, Japan

#### Masaru Yanai

Department of Respiratory Medicine, Ishinomaki Red Cross Hospital, Ishinomaki, Japan

Correspondence to: Dr Seiichi Kobayashi, Department of Respiratory Medicine, Ishinomaki Red Cross Hospital, 71 Nishimichishita, Hebata, Ishinomaki, Miyagi 986-8522, Japan; skoba-thk@umin.ac.jp

doi: 10.1136/thx.2007.084715

Funding: None

Competing interests: None.

#### References

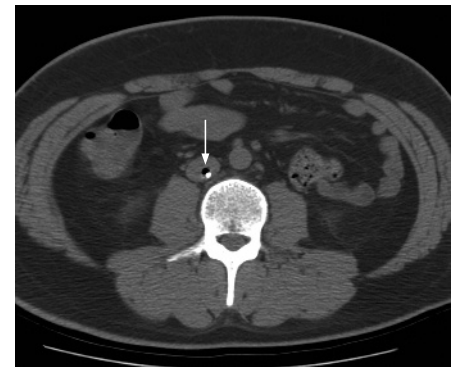- 1 Donaldson GC, Wedzicha JA. COPD exacerbations. 1: Epidemiology. *Thorax* 2006;**61**:164–8.
- 2 Ebihara T, Sekizawa K, Nakazawa H, *et al*. Capsaicin and swallowing reflex. *Lancet* 1993;**341**:432.
- 3 Stein M, Williams AJ, Grossman F, *et al*. Cricopharyngeal dysfunction in chronic obstructive pulmonary disease. *Chest* 1990;**97**:347–52.
- 4 Good-Fratturelli MD, Curlee RF, Holle JL. Prevalence and nature of dysphagia in VA patients with COPD referred for videofluoroscopic swallow examination. *J Commun Disord* 2000;**33**:93–110.
- 5 Mokhlesi B, Logemann JA, Rademaker AW, *et al*. Oropharyngeal deglutition in stable COPD. *Chest* 2002;**121**:361–9.

### Intravascular air and CT

Dr Ku and co-workers wrote an interesting article describing a patient with air emboli in the superior vena cava surrounding a central venous catheter (CVC) and bilateral pulmonary opacities recognised on contrast enhanced chest CT.<sup>1</sup> The round pulmonary opacity was noted on chest radiograph soon after insertion of the CVC. From these findings, they suggest that this is a rare case of venous air pulmonary infarction mimicking round pneumonia. However, further evidence should be obtained to support this assumption.

CT is highly sensitive for the detection of small amounts of intravascular air, which can be found in the central veins in up to 23% of patients on contrast-enhanced CT and it rarely results in symptoms unless there is a right to left shunt.<sup>2–4</sup> It is introduced during insertion of the venous catheter or more frequently accidental injection of air during intravenous injections (fig 1).

Normal lung tissue receives dual blood supply from pulmonary and bronchial arteries. Pulmonary infarct is infrequent after acute obstruction of the pulmonary artery because the bronchial circulation plays an important role



**Figure 1** Air bubble trapped around the central venous catheter in the inferior vena cava (arrow) was incidentally noted on non-enhanced CT scan of the abdomen.



## Impairment of the swallowing reflex in exacerbations of COPD

Seiichi Kobayashi, Hiroshi Kubo and Masaru Yanai

*Thorax* 2007 62: 1017

doi: 10.1136/thx.2007.084715

---

Updated information and services can be found at:

<http://thorax.bmj.com/content/62/11/1017.1.full.html>

---

*These include:*

### References

This article cites 5 articles, 3 of which can be accessed free at:

<http://thorax.bmj.com/content/62/11/1017.1.full.html#ref-list-1>

Article cited in:

<http://thorax.bmj.com/content/62/11/1017.1.full.html#related-urls>

### Email alerting service

Receive free email alerts when new articles cite this article. Sign up in the box at the top right corner of the online article.

---

### Notes

---

To request permissions go to:

<http://group.bmj.com/group/rights-licensing/permissions>

To order reprints go to:

<http://journals.bmj.com/cgi/reprintform>

To subscribe to BMJ go to:

<http://group.bmj.com/subscribe/>