

12-1966

## Extraskeletal Osteogenic Sarcoma - Case Report

Klaus Hoffmann

Gerald Fine

J. L. Ponka

J. Keith Welborn

Follow this and additional works at: <https://scholarlycommons.henryford.com/hfhmedjournal>



Part of the [Life Sciences Commons](#), [Medical Specialties Commons](#), and the [Public Health Commons](#)

---

### Recommended Citation

Hoffmann, Klaus; Fine, Gerald; Ponka, J. L.; and Welborn, J. Keith (1966) "Extraskeletal Osteogenic Sarcoma - Case Report," *Henry Ford Hospital Medical Bulletin* : Vol. 14 : No. 4 , 381-386.

Available at: <https://scholarlycommons.henryford.com/hfhmedjournal/vol14/iss4/3>

This Article is brought to you for free and open access by Henry Ford Health System Scholarly Commons. It has been accepted for inclusion in Henry Ford Hospital Medical Journal by an authorized editor of Henry Ford Health System Scholarly Commons.

## EXTRASKELETAL OSTEOGENIC SARCOMA — CASE REPORT

KLAUS HOFFMANN, M.D.\*, GERALD FINE, M.D.\*\*\*, J. L. PONKA, M.D., F.A.C.S.\*\*\*  
AND J. KEITH WELBORN, M.D.\*\*\*\*

Primary malignant bone formation in extraskeletal soft tissue is most commonly seen with other neoplastic elements (smooth or striated muscle, blood vessels or fat) as part of a malignant mesenchymoma; infrequently, it occurs as an osteogenic sarcoma. Until 1956 there were only 46 primary extraskeletal osteogenic sarcomas reported in the world literature. Their infrequency has made difficult the assessment of criteria for their diagnosis, biological behavior and response to therapy as a group and according to morphologic type (fibroblastic, lytic, sclerotic). This makes the documentation and reporting of these cases of greater importance than other, more commonly encountered, soft tissue tumors.

### CASE REPORT

A 59-year-old man presented himself in August of 1964, with an 8 centimeter non-tender, painless, firm, subcutaneous mass in the left lateral chest at the level of the fourth rib. The lesion was not attached to the chest wall or the skin. It had been present for approximately one month. X ray of the chest did not reveal any involvement of the underlying bone or lungs. Exploration and excision of the tumor was performed on August 31, 1964. The lesion was located in the left latissimus dorsi muscle, with no attachment to bone. The patient remained asymptomatic until January 1965, when he noted enlarged lymph nodes in the left axilla. These were excised and showed lymphoid hyperplasia. Repeated physical examinations were negative until July 1965, when a mass was discovered at the site of the original tumor. Chest X ray disclosed a 4 cm spherical mass in the lower lobe of the right lung. In addition, there was a 1 cm nodule in the right middle lobe of the lung (Fig. 1). A metastatic bone survey, liver scan, liver function studies, serum alkaline, acid phosphatase, and blood calcium and phosphorus were normal. Subsequently, a small recurrent tumor was excised with a generous margin of normal muscle; also, a left axillary node dissection was carried out.

---

\*Resident Surgeon  
\*\*Associate Pathologist  
\*\*\*Chief, Fourth Surgical Division  
\*\*\*\*Associate Surgeon, Fourth Surgical Division

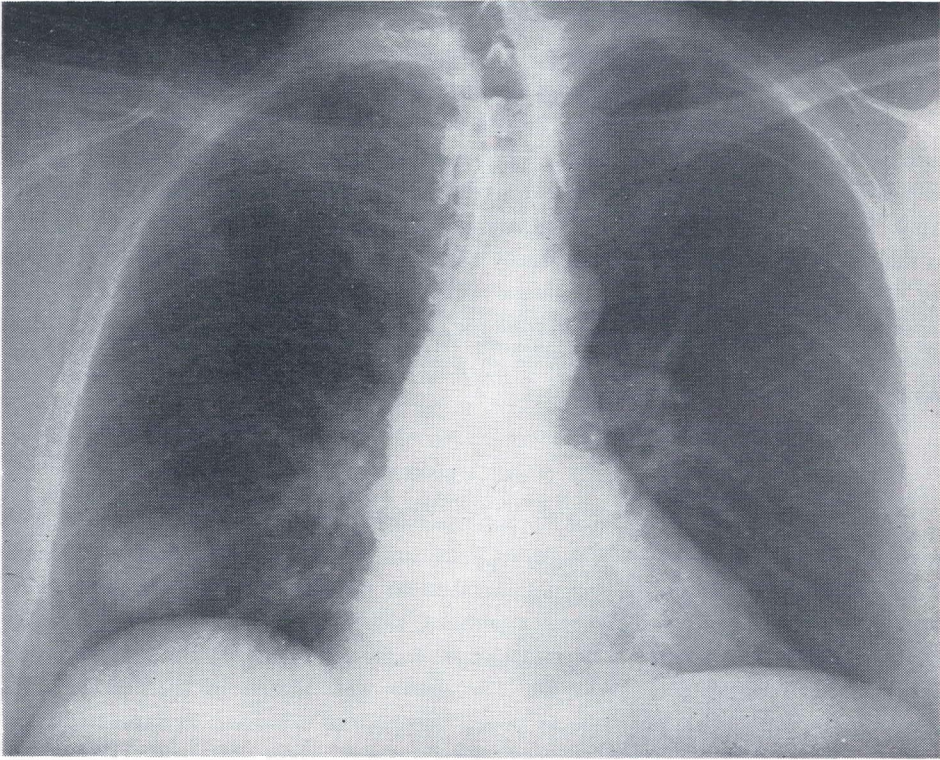


Figure 1

Metastatic tumor in the right lower and middle lobe of the lung.

*EXTRASKELETAL OSTEOGENIC SARCOMA*

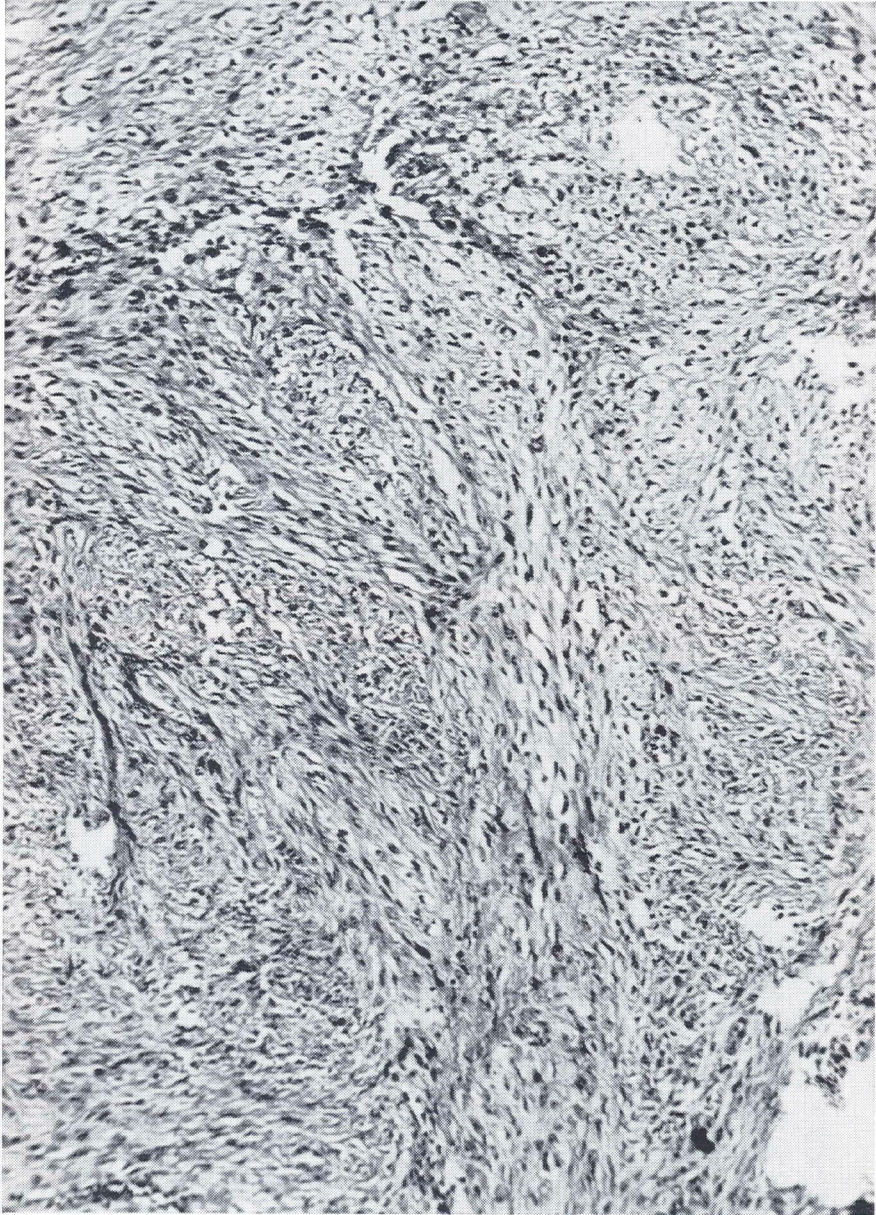


Figure 2

Fibrosarcoma appearance with bundles of cells and abundant intervening collagen. H&E x 150.

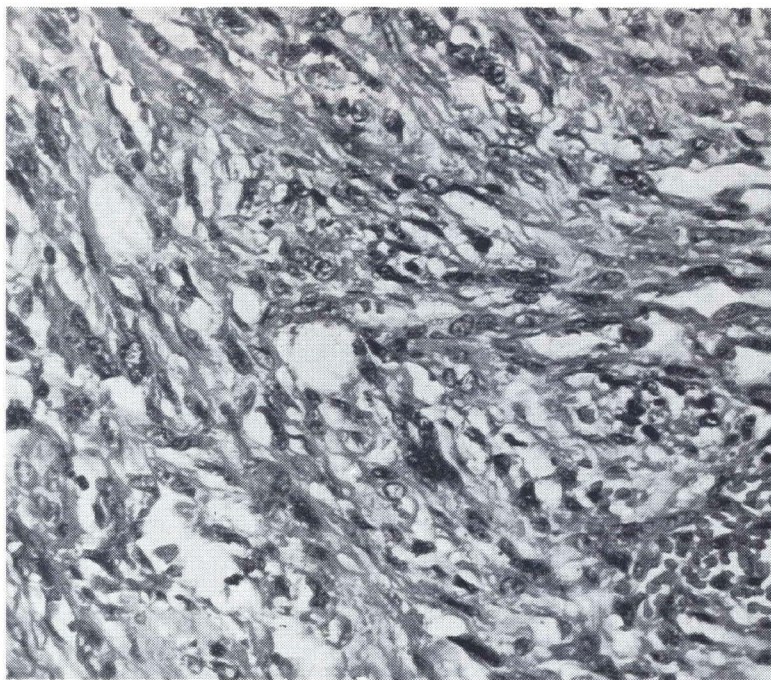


Figure 3

Magnification of Fig. 2 showing the cellular pleomorphism of the more malignant-appearing areas. H&E x 390.

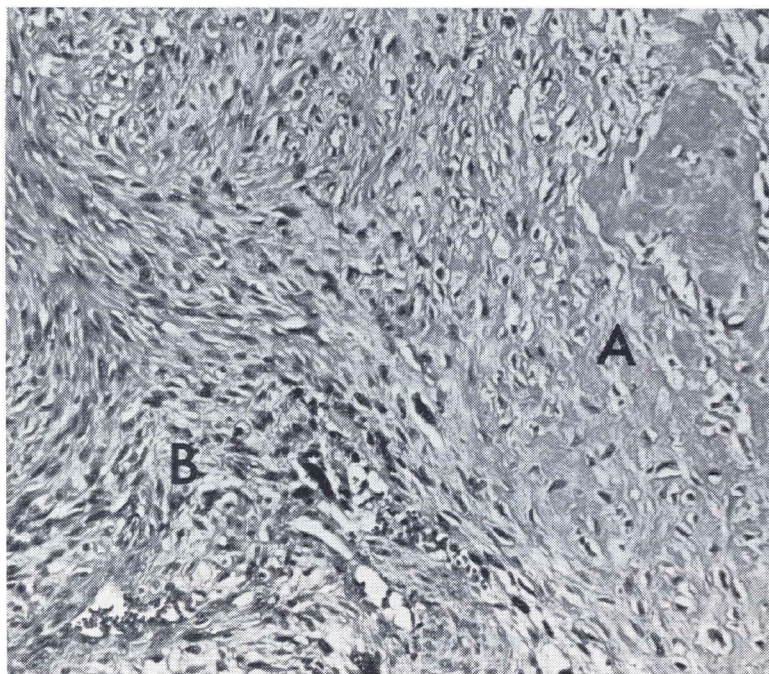


Figure 4

Focus of osteoid (A) blending with the fibrosarcoma tissue (B) indication of the tumor's osteogenic properties. H&E x 150.

## EXTRASKELETAL OSTEOGENIC SARCOMA




Figure 5

Abundant alkaline phosphatase activity depicted in black is present in nonosteogenic areas. Gomori's alkaline phosphatase stain x 150.

Laminograms of both lung fields in October of 1965 revealed considerable enlargement of the nodules in the right lung and a normal left lung. On November 30, 1965 a right lower lobectomy and wedge resection of the right middle lobe was carried out by Drs. R. E. Taber and A. Manzor.

### PATHOLOGY

All the tumors were greyish tan and firm, with focal hemorrhagic cystic areas. The gross tumor circumscription was not confirmed microscopically; the tumor infiltrated the surrounding muscle and fat freely. Tumor from all involved sites was similar, having abundant fusiform cells which were most often aligned parallel to one another, and separated by varying amounts of an eosinophilic fibrillar stroma. In areas this merged with irregular poorly fibrillar or nonfibrillar similarly stained tissue, interpreted as osteoid, in which were isolated cells lying within spaces (Figs. 2-4). At the periphery of the osteoid the cells were frequently ovoid and in apposition to its surface. Cellular and nuclear pleomorphisms were prominent and mitoses moderately frequent. Alkaline phosphatase stains using the Azodye (pH 8.3) and cobalt (pH 9.2) methods revealed abundant phosphatase activity rather evenly distributed in the tumor cells associated or unassociated with the osteoid (Fig. 5).

DISCUSSION

Bone formation within neoplasms often represents a secondary change within the tumor stroma or host tissue, manifested by preexisting calcification. Usually it is easily recognized. Nondegenerative ossification resulting from fibrous transformation or osteoid deposition presents a greater diagnostic problem, as it may be the product of the neoplasm or a reaction of the host tissue. Generally, a typical osteoid and cellular features of malignancy are readily interpreted as malignant neoplastic osteogenesis. However, orderly bone formation without cellular criteria of malignant disease in its immediate vicinity is often interpreted as metaplastic benign osteogenesis. Such an interpretation might be given to the present case if one considers the spindle-celled portions of the lesion as a differentiated fibrosarcoma. While most of the tumor cells have the morphologic attributes of fibroblasts, they are enzymatically functioning as osteoblasts, producing alkaline phosphatase even in the areas not forming osteoid. The tumor's designation as an ossifying fibrosarcoma or an osteogenic sarcoma, fibroblastic type, is of little import as long as one is aware of its biological potential. Although cases of this type are infrequent, the neoplasm appears to be more aggressive and it metastasizes more frequently than the differentiated fibrosarcoma.

Since the primary neoplasm under discussion did not involve bone or arise in close proximity to it, one must invoke the pluripotentiality of the mesenchymal tissue to explain the tumor's histogenesis. Such a function for fibroblasts is acceptable since they are not infrequently altered in this fashion in the repair of fractures, in subperiosteal osteogenesis, and in myositis ossificans.

SUMMARY

An extraosseous osteogenic sarcoma of fibroblastic type is reported. It arose in the left lateral chest wall of a 59-year-old white man, then recurred and metastasized 12 months later. Treatment consisted of excision of the primary tumor, then removal of the recurrent tumor and dissection of the axillary lymph node in continuity. In addition, excision of the metastatic pulmonary lesions by right lower lobectomy and wedge resection of the right middle lobe were performed. Evidence of neoplastic osteogenesis is supported morphologically and histochemically by the presence of abundant alkaline phosphatase in the tumor cells.

REFERENCES

1. Fine, G. and Stout, A. P.: Osteogenic sarcoma of the extraskeletal soft tissues. *Cancer* 9:1027-1043, Sept.-Oct., 1956.
2. Stout, A. P.: Pathology and classification of tumors of the soft tissue. *Amer. J. Roentgen.* 66:903-909, Dec. 1951.
3. Umiker, W. and Jaffe, H. L.: Ossifying fibrosarcoma (extraskeletal osteogenic sarcoma) of the thigh muscle. *Ann. Surg.* 138:795-800, Nov. 1953.