

6-1965

Psoriatic Arthritis

Howard Duncan

Darrell Oberg

William R. Eyer

Follow this and additional works at: <https://scholarlycommons.henryford.com/hfhmedjournal>



Part of the [Life Sciences Commons](#), [Medical Specialties Commons](#), and the [Public Health Commons](#)

Recommended Citation

Duncan, Howard; Oberg, Darrell; and Eyer, William R. (1965) "Psoriatic Arthritis," *Henry Ford Hospital Medical Bulletin* : Vol. 13 : No. 2 , 173-181.

Available at: <https://scholarlycommons.henryford.com/hfhmedjournal/vol13/iss2/6>

This Article is brought to you for free and open access by Henry Ford Health System Scholarly Commons. It has been accepted for inclusion in Henry Ford Hospital Medical Journal by an authorized editor of Henry Ford Health System Scholarly Commons. For more information, please contact acabrer4@hfhs.org.

PSORIATIC ARTHRITIS*

HOWARD DUNCAN, M.D.,** DARRELL OBERG, M.D.,** AND
WILLIAM R. EYLER, M.D.***

Dr. Howard Duncan. It is apparent from these meetings that rheumatologists are not alone in having troubles with dissension amongst the hierarchy in arriving at a decision as to whether a disease exists or not. The problem is the relationship between arthritis and psoriasis. Our first approach will be to demonstrate that there is an entity "psoriatic arthritis" which is distinct from rheumatoid arthritis with psoriasis. I'll ask Dr. Oberg to illustrate the situation.

Dr. Darrell Oberg. Our patient is a 49 year old white female who was first seen in this hospital in 1960, at which time she was admitted with malignant hypertension, which has subsequently been controlled by treatment prescribed in the Hypertension Division. The illness under discussion began in the fall of 1929 when she had the onset of "inflammatory rheumatism" (as it was then called). She was then 14 years old. In the spring of 1930 she had the onset of psoriasis. About the time the psoriasis began her arthritis was subsiding. The psoriasis was quite flagrant for about a year and then it almost cleared. At the age of 21, she had had a return of the arthritis in her feet, ankles, knees, elbows, hands, and her hip joints. She was under treatment for approximately 18 months at that time without much success. During this period the psoriasis was localized to the scalp. She did fairly well until the age of 29 when she again developed arthritis of the feet and ankles. At that time, she had a slight, but persistent, enlargement of the distal interphalangeal joints of her fingers and first noted some nail changes. She was hospitalized at the University of Michigan for 7½ weeks because of a flare of the psoriasis. This was chiefly in the scalp, but there were a few patches elsewhere. She was treated with gold injections and large doses of aspirin which, during the next 3 years, usually resulted in some improvement. In 1949, she again had difficulty with arthritis involving her feet. She noticed that her toes were beginning to get a little bit floppy, and she developed a numbness in the third toe of the left foot. In 1950, at age 35, she again had a flare of psoriasis and also arthritis. Again salicylates effected

**Division of Rheumatology.

***Department of Radiology.

*An abridged transcript of Medical Grand Rounds edited by W. S. Haubrich, M.D., Chairman, Medical Clinic Committee.

significant improvement. In July of 1964, at the age of 49, again she had a similar flare. At this time, she also experienced some difficulty with pain in her back. When she was at rest, there would be a pain between the shoulder blades, and on movement, more pain in the lumbosacral region. During the years, she has noted that sunlight tends to exacerbate the psoriatic plaques, but she finds that the sunlight or warmth will tend to make her joints feel quite a bit better.

On the present admission, her blood pressure was 230/110. Other physical findings were a symmetrical and bulbous enlargement of the distal interphalangeal joints of most of her fingers and some erythema, particularly the 3rd finger of both hands. There was longitudinal ridging and pitting of the fingernails and a scalloped appearance, or "spooning", of the nails. There was an extension contracture of the distal interphalangeal joint of the right thumb and a flexion contracture of the proximal interphalangeal joint. There was marked limitation of hyperextension around the MCP joints of both hands, as well as a symmetrical enlargement of these joints. There was a little tenderness over both of her wrist joints, but not an appreciable effusion. There was a tenderness over the anterior capsule of both of her shoulder joints. There was a minimal limitation of flexion over the lower lumbar spine and a fairly symmetrical and knobby enlargement of both of her knee joints without much limitation of motion. There has been a soft tissue swelling over the dorsum of her right foot, a nonpitting phenomenon. The toes (you will see photographs of these which Dr. Duncan will present) are rather lax and tend to "telescope" as sometimes seen in this condition. She has numerous psoriatic plaques scattered over the trunk and extremities, including some on the hands and on the feet. There have been no subcutaneous nodules. Among the laboratory studies, I would like to point out that the rheumatoid factor (by the latex fixation test) has been absent. She does have a markedly elevated sedimentation rate. The serum protein electrophoretic pattern shows minimal changes in the globulin fraction. Her serum uric acid on admission was 10.8 mg. At this time, the patient was taking Hygroton. Following her admission she was changed to Triamterene, and a week later the uric acid was 4.2 mg. Her present medications consist of Triamterene, Tofranil, Ascriptin in large doses, Sodium Amytal, Ismelin, and the Chlor-Trimeton. Her blood pressure since admission has measured about 160/100. (*To the patient.*) Can you tell me what sort of joint problems you had back in 1929?

Patient. My hands were almost completely stiffened. I couldn't use them very well. My feet and my ankles and my knees, also. No, my knees were before that.

Dr. Oberg. During your illness have you noted a relationship between the arthritis and the psoriasis?

Patient. It always seems that psoriasis will break out worse after the flare-up of the arthritis. It has happened this way ever since it first started.

Dr. Oberg. When you are having trouble with your joints, are they usually the same joints on either side?

PSORIATIC ARTHRITIS

Patient. It usually starts with one and works over to the other one; many times, it's both at the same time.

Dr. Oberg. Do you usually have several joints involved at the same time?

Patient. Yes.

Dr. Oberg. At any time during your illness have you noted any small nodules or little lumps underneath the skin, in particular, around the elbows?

Patient. No, I haven't.

Dr. Oberg. Have you noticed them anywhere else?

Patient. No, just a deformation in the fingers and the toes, that's about it.

Dr. Oberg. At any time during your illness, have you had any difficulty with your eyes?

Patient. I don't know. Here for a while, my eyes were awfully dry. I would wake up during the night and put drops in them and they wouldn't tear too much.

Dr. Oberg. At the time when your eyes were dry, did you notice that there was a dryness of your mouth at this time?

Patient. That's right, yes.

Dr. Oberg. Approximately how long did that last?

Patient. That was a few weeks back and that lasted about 5 or 6 weeks or more.

Dr. Oberg. Do you find that your joints or your psoriasis will tend to flare up at any particular time of the year?

Patient. No.

Dr. Oberg. Has anyone in your family, either immediate family or aunts or uncles, ever had difficulty with either psoriasis or with arthritis?

Patient. No, not that I know of.

(The patient is dismissed.)

Dr. Duncan. I think this case has quite a few illuminating features. The association between arthritis and psoriasis can be variable. Our patient makes the simple point that every time she has a flare of her joints, her skin flares as well. Her arthritis began a year before the skin condition itself developed.

We can see there are features here (Figure 1) which on first sight would suggest it to be a typical rheumatoid hand. She has swelling over the metacarpal

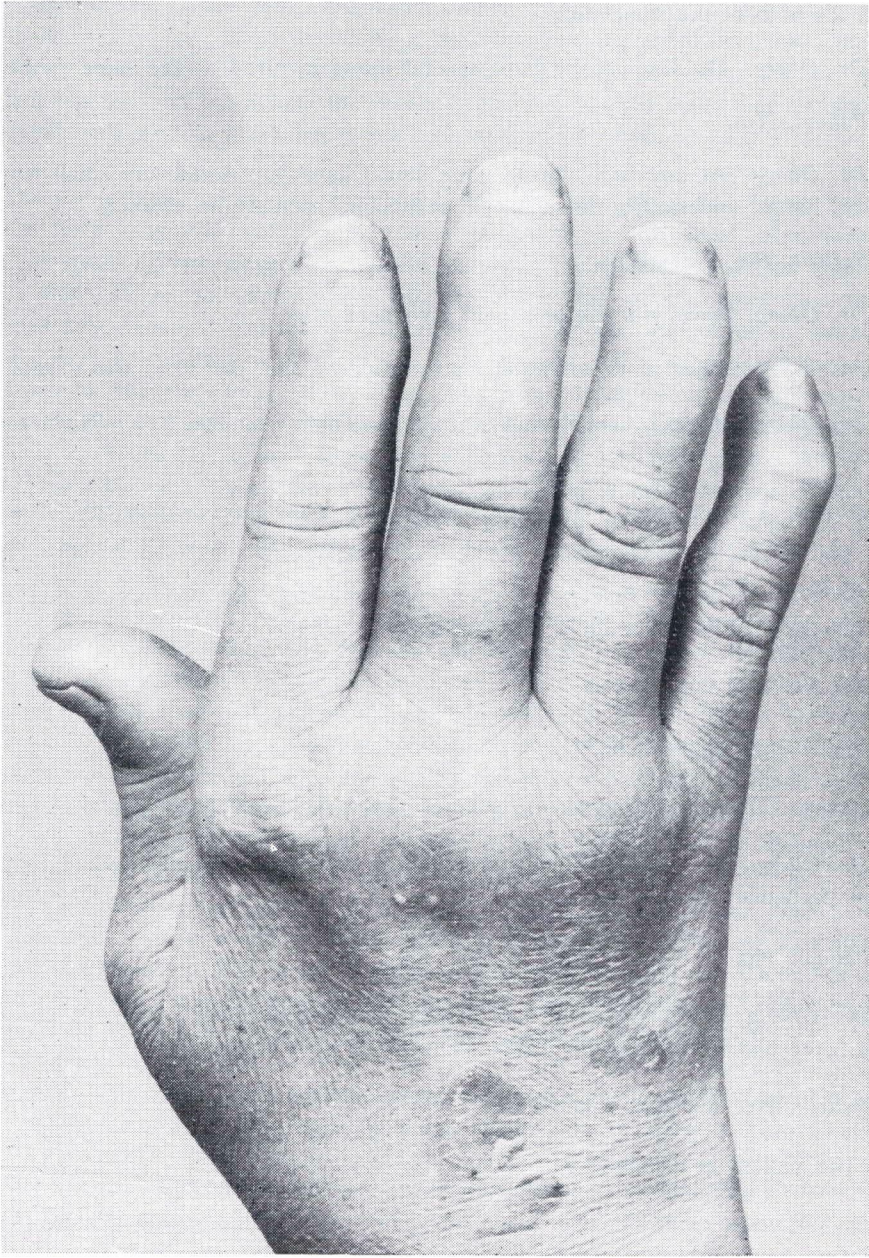


Figure 1

This patient's hand is characteristic of psoriatic arthritis. Note the enlargement of the distal interphalangeal joints and, especially, the psoriasis affecting the fingernails and the skin over the dorsum of the hand.

joints. She has a tendency to ulnar deviation. This is another good time to mention that ulnar deviation occurs in conditions other than rheumatoid arthritis and here is one such condition. We are rather adamant in stating that this is not rheumatoid arthritis in the general sense. You notice here that the proximal interphalangeal joints are relatively well spared, but the particular feature is the enlargement of all distal interphalangeal joints. Yes, you can say there are Heberden's nodes, too, but we find at the same time involvement of the fingernails with a psoriatic process itself. The wrist is also involved on this hand. On the other hand, we see features not quite so marked, but we do see in the 3rd finger the flare of a tender, red, swollen, distal, interphalangeal joint. Again, any swollen tender joint can look like psoriasis, rheumatoid arthritis, and acute Heberden's node. However, the distinguishing feature is the presence of the skin rash itself as well as the involvement of the corresponding fingernails. You'll appreciate that the fingernails are markedly involved in the absence of actual rash on the digits themselves. This is a feature which seems always to occur in the presence of distal joint involvement, either of the hands or the feet. It is much more difficult to appreciate dystrophy of nails in the feet than it is in the hands. The foot (Figure 2) is rather typical of this condition and not commonly appreciated. The toes are swollen in what is called "sausage-like" appearance; they are bulbous. They have no stability as you will see from the x-rays. The rash is psoriasis. The ankles are both involved, and on the x-rays Dr. Eyerler will show you some changes in that area, also. The base of the great toe and the interphalangeal joints of the toes are also involved, and this latter is very uncommon or rare in rheumatoid arthritis (where the chief involvement is the metatarsal heads). The interphalangeal joints are the picture of what is termed "arthritis mutilans" or disintegration of the joint and of the bone within the digits. They just flop around and have no useful purpose or support at all. We do have dystrophy of the nails. We do have this telescoping appearance; that is, you can extend and regress the digits, and from the x-rays you will be able to see exactly why and how. The toes are shrunken and almost elastic. This does not occur with rheumatoid arthritis (with very rare exceptions). Subluxation and elevation of the proximal joints in the toes is common in rheumatoid arthritis. We do get an arthritis mutilans in rheumatoid arthritis, but it takes many years longer to develop, is usually much more painful and discomforting, and there are the distinguishing features which we will show on the x-rays. At this stage, I will ask Dr. Eyerler to show the x-rays and follow those with some particularly interesting slides of Dr. John Sigler's. I feel rather like the sorcerer's apprentice here. This is really Dr. Sigler's territory since he is writing a chapter of a book about psoriatic arthritis and, in his absence, I have been elected to discuss the situation.

Dr. William Eyerler. Dr. Duncan has given an excellent description of the clinical picture, and as one would expect, the radiographic manifestations correspond closely.

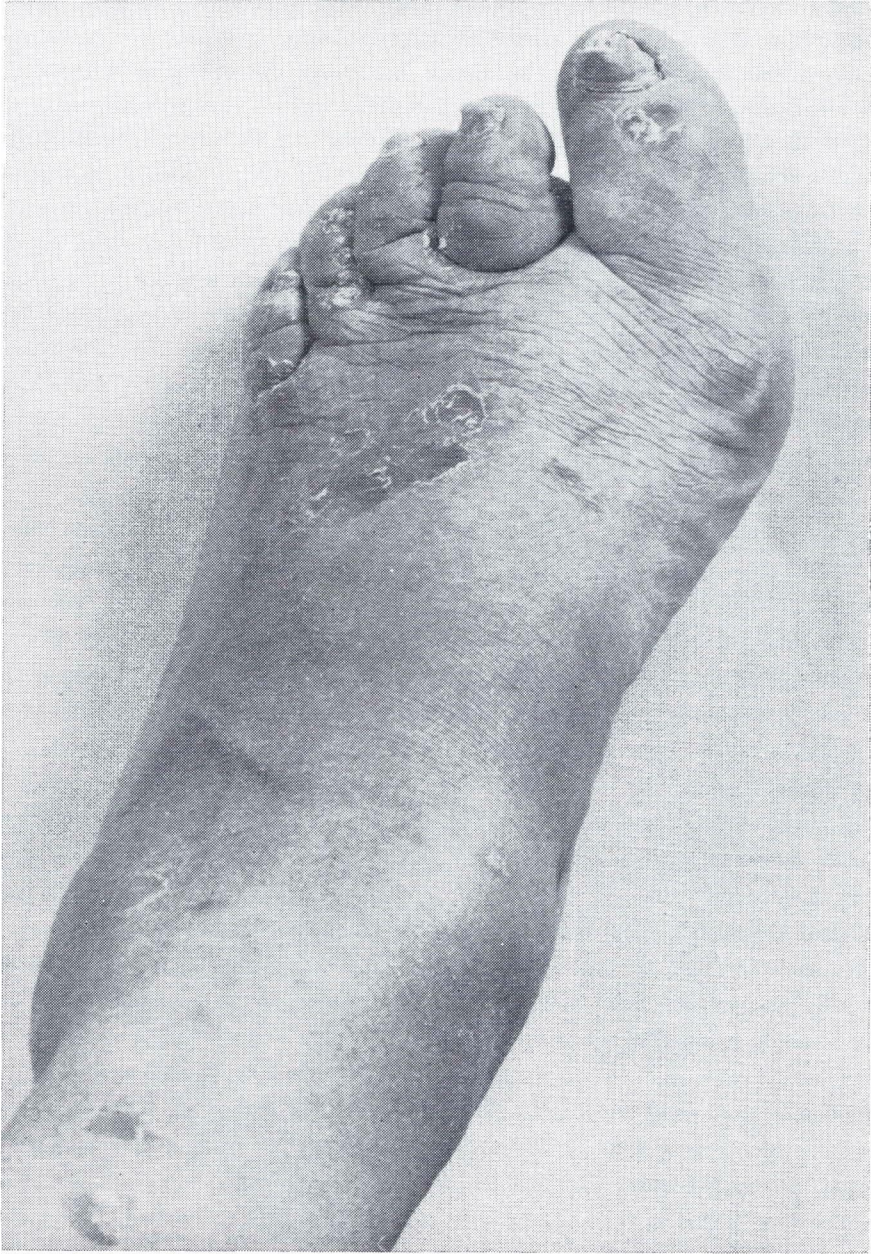


Figure 2

Psoriatic arthritis is even more strikingly depicted in this patient's foot. Note the stubby, "telescoped" toes and the typical skin and nail changes.

PSORIATIC ARTHRITIS

The films of the patient (Figure 3) show marked involvement of distal interphalangeal joints of the hands with narrowing and destruction. One would not confuse this with rheumatoid arthritis, but might possibly consider an atypical osteoarthritis in the differential diagnosis. The general mineralization of the bones is well preserved, and this feature also contrasts with rheumatoid arthritis. The films of the feet show involvement of the great toes with some widening of joint space, bone proliferation at the margins with formation of small spikes and marked absorption of terminal tufts giving a pointed appearance of the terminal phalanges. There is slight bone proliferation along the medial aspect of the distal tibia which may or may not be related to the psoriatic arthritis. Films of the spine in our patient show none of the abnormalities of the apophyseal joints recently described in the literature but there is sclerosis about the sacroiliac joints, predominantly on the iliac side. There is also some ossification of the ligaments between the lower lumbar spine and pelvis. These features could be confused with rheumatoid arthritis.

Avila, Pugh, Slocumb and Winkelmann¹ described five radiographic features of psoriatic arthritis as follows: (1) destructive arthritis of the distal interphalangeal joints, (2) bony ankylosis of the interphalangeal joints of hands and feet, (3) destruction of interphalangeal joints with abnormally wide joint spaces and sharply demarcated adjacent bony surfaces, (4) destruction of the interphalangeal joint of the great toe with bony proliferation at the base of the distal phalanx, and (5) resorption of the tufts of the distal phalanges of hands and feet. You notice that the patient under discussion shows all these features except for the fusion of interphalangeal joints.

Dr. Duncan. Thank you, Dr. Eyler. To just reiterate the points of distinction in this particular syndrome: first, we have the involvement of the distal interphalangeal joints in the presence of psoriatic nail and skin lesions; also, sacro-iliac disease, negative rheumatoid factor, and possible arthritis mutilans. There is no necessity that the arthritis and the psoriasis be active at the same time. There are several series which demonstrate that about 20 to 40 per cent are simultaneously active. It is important, too, to distinguish this group from the rheumatoid picture by noting absence of subcutaneous nodules, and also a constant absence of the rheumatoid factor. The involvement of the sacro-iliac joints is a feature which is far more prominent in this condition than in rheumatoid arthritis. Sacro-iliac joints do become involved in the later stages of peripheral rheumatoid arthritis. In addition, the rate of destruction of the joints may be extraordinarily fast. In the psoriatic type of arthritis, when it does start to flare, within 6 months or 12 months joint destruction can appear such as you have seen here. In rheumatoid disease, joint destruction usually takes far longer and, in addition, is far more discomforting to the patient. There is surprisingly little discomfort in psoriatic arthritis for the same degree of deformity and bone resorption.

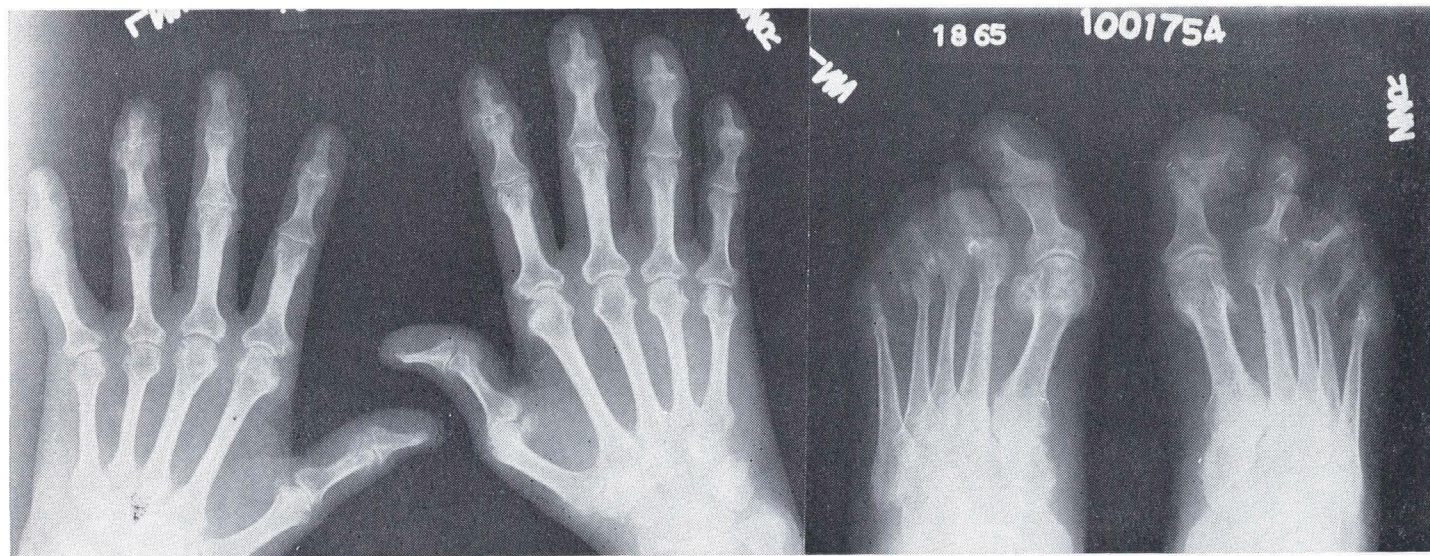


Figure 3

Radiographs of the hands and feet clearly distinguish psoriatic arthritis from rheumatoid arthritis (cf. text). The bony changes visible by x-ray explain the peculiar physical features noted in the toes.

PSORIATIC ARTHRITIS

We noted a serum uric acid level of 10.8 mg. in our patient. It is important to remember that about 7 to 14 per cent of patients who have active diffuse psoriasis may have elevated uric acid levels. This is allegedly related to the high turnover of nuclear protein in the skin.

Management is essentially the same as rheumatoid arthritis during the acute flares. Salicylates in heavy doses, as a rule, have been used in this case. Independently, the psoriasis itself is treated. Ultraviolet light has been one of the mainstays in therapy of psoriasis. Our patient, interestingly enough, has been found to be sensitive to sunlight.

Although there is still some dissension in other centers, we feel quite certainly that psoriatic arthritis or psoriatic arthropathy (as some people prefer to call it) is a specific entity clinically, radiographically, and pathologically distinct from rheumatoid arthritis.

REFERENCE

1. Avila, R., Pugh, D. G., Slocumb, C. H., and Winkelmann, R. K.: "Psoriatic arthritis: a roentgenologic study". *Radiology*, 75:691, 1960.