

12-1962

## The Effect Of Degree Of Hypoxia On The Electroencephalogram In Infants, II

A. Robert Bauer

Philip J. Howard

Follow this and additional works at: <https://scholarlycommons.henryford.com/hfhmedjournal>



Part of the [Life Sciences Commons](#), [Medical Specialties Commons](#), and the [Public Health Commons](#)

---

### Recommended Citation

Bauer, A. Robert and Howard, Philip J. (1962) "The Effect Of Degree Of Hypoxia On The Electroencephalogram In Infants, II," *Henry Ford Hospital Medical Bulletin* : Vol. 10 : No. 4 , 573-588.

Available at: <https://scholarlycommons.henryford.com/hfhmedjournal/vol10/iss4/7>

This Article is brought to you for free and open access by Henry Ford Health System Scholarly Commons. It has been accepted for inclusion in Henry Ford Hospital Medical Journal by an authorized editor of Henry Ford Health System Scholarly Commons. For more information, please contact [acabr4@hfhs.org](mailto:acabr4@hfhs.org).

## THE EFFECT OF DEGREE OF HYPOXIA ON THE ELECTROENCEPHALOGRAM IN INFANTS, II

A. ROBERT BAUER, M.D. AND PHILIP J. HOWARD, M.D.\*

LEVELS OF HYPOXIA frequently occur in newborn or young infants due to birth injury of the central nervous system, congenital deformity of the lungs, or heart, atelectasis or hyaline pneumonia, anemia, or to multiple conditions. Studies have been made to relate the level of oxygenation to the EEG. The purpose of this report is to supplement our original paper with a more complete presentation of the data for those who desire further details.<sup>1</sup>

### MATERIAL AND METHODS

Material and methods have been previously described.<sup>1</sup> Of the 14 cases of degrees of hypoxia described, charts were shown for only cases 3 and 7. Charts for cases 1, 2, 4 to 6, and 8 to 14 are therefor included in this report. As stated before, each of these cases showed an increase in oxygen saturation of at least 10 percent between the minimum and maximum levels. Also in addition the electrograms are reproduced for cases 4, 6, 8, 9, 11, 12 and 14.

Studies on seven normal newborn infants were carried out for the effect of CO<sub>2</sub> on the EEG. Inasmuch as the chart of only one has been published previously,<sup>1</sup> those of the other six are included here.

The type of waves has been shown in the form of a graph expressing the space occupied on an EEG tracing by each type of wave. For instance, a 1 per second wave is a 30 mm wave, a 2 per second wave is a 15 mm wave, etc.

To show the space occupied by a given wave, we counted the number occurring in a 10 second sample of the EEG, and multiplied this figure by the number of millimeters characteristic of that wave. The resultant product was designed as summation value and was plotted on the graph as a vertical column using black for the slow (1-4 per sec.) waves, and cross hatched for the more rapid (5-10 per second) waves. No attempt has been made to chart waves over 10 per second, and our conclusions are based on 1-4 per second waves only. The ordinate represents this summation value and the abscissa the wave type.

---

\*Department of Pediatrics, Henry Ford Hospital.

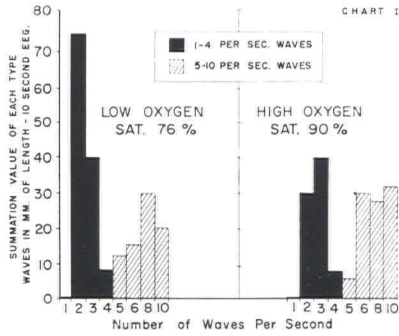


Chart 1

Analysis of waves in a 10 second EEG in low oxygen compared with a 10 second EEG in high oxygen. Infant aged 4 days. Lesion low tricuspid valve, divided right ventricle, interauricular defect. Time between observations 14 minutes.

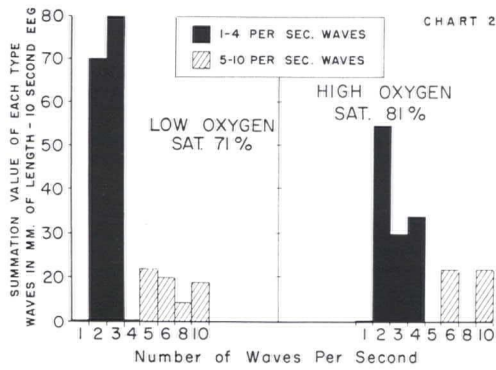


Chart 2

Analysis of waves in a 10 second EEG in low oxygen compared with a 10 second EEG in high oxygen. Infant aged 24 days. Lesion interventricular defect, transposition of great vessels. Time between observations 25 minutes.

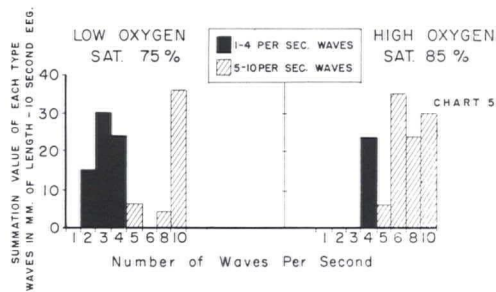


Chart 5

An analysis of waves in a 10 second EEG in low oxygen compared with a 10 second EEG in high oxygen. Infant aged 16 days. Lesion transposition of great vessels. Time between observations 13 minutes.

EFFECT OF DEGREE OF HYPOXIA

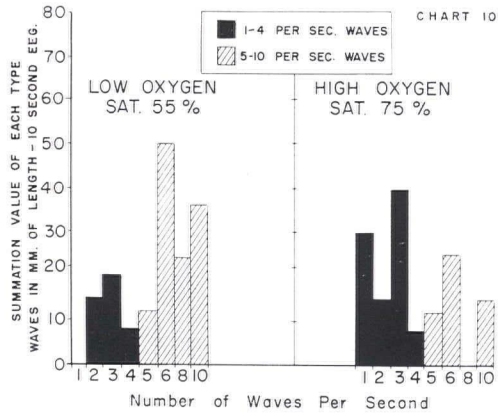


Chart 10

An analysis of waves in a 10 second EEG in low oxygen compared with a 10 second EEG in high oxygen. Infant aged 9 days. Lesion situs inversus, levocardia. Time between observations 38 minutes.

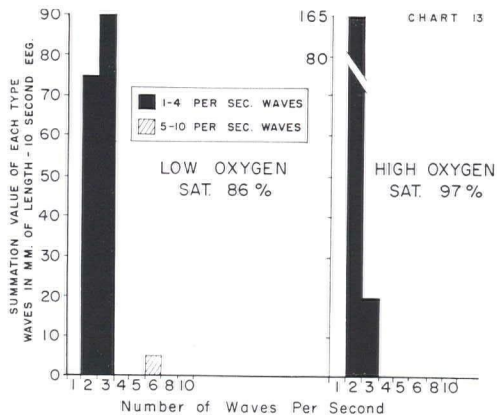


Chart 13

An analysis of waves in a 10 second EEG in low oxygen compared with a 10 second EEG in high oxygen. Infant aged 25 days. Lesion ventricular septal defect. Time between observations 4 minutes.

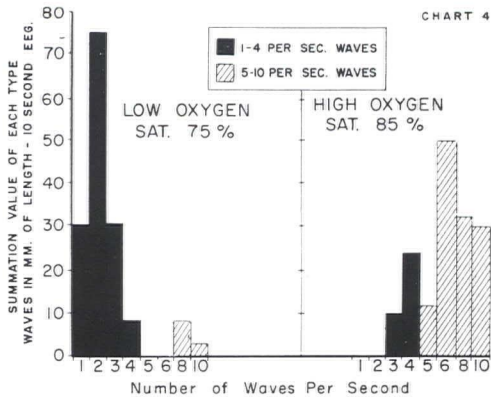
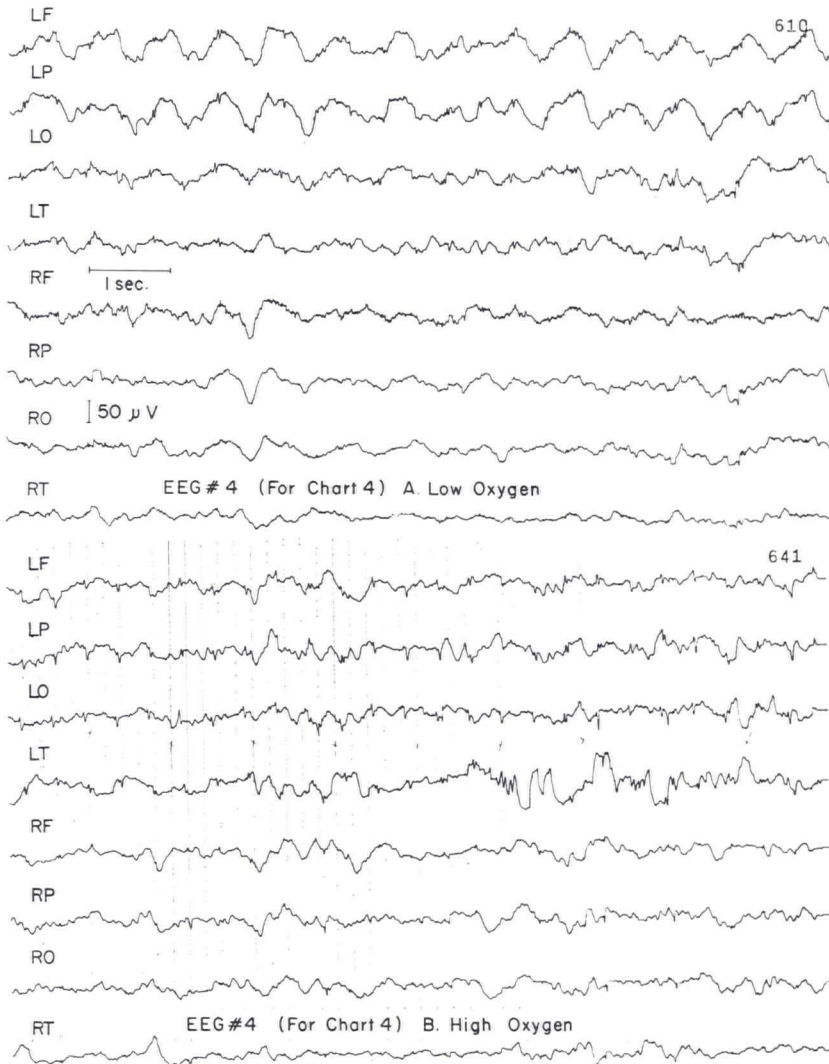


Chart 4

An analysis of waves in a 10 second EEG in low oxygen compared with a 10 second EEG in high oxygen. Infant aged 18 days. Lesion transposition of great vessels. Time between observations 18 minutes.





EFFECT OF DEGREE OF HYPOXIA

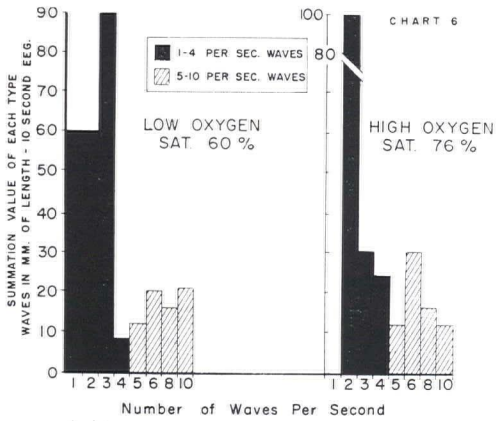
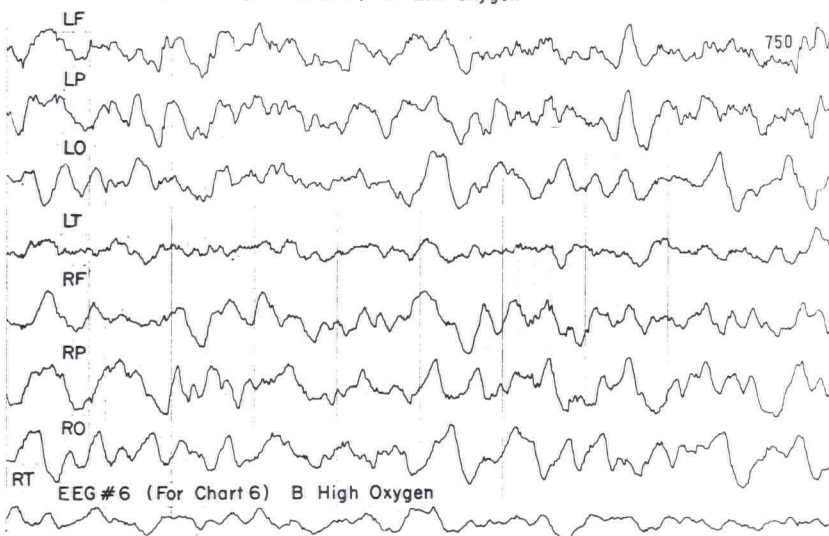
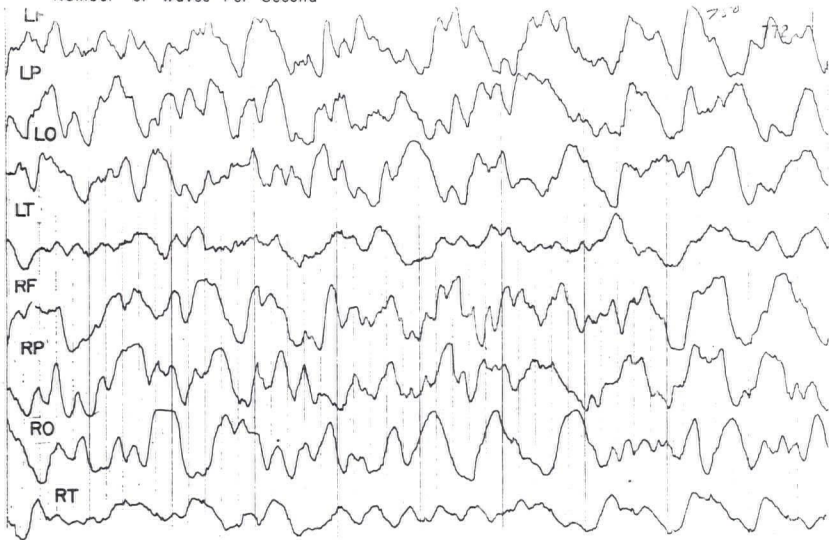


Chart 6

An analysis of waves in a 10 second EEG in low oxygen compared with a 10 second EEG in high oxygen. Infant aged 150 days. Lesion transposition of great vessels. Time between observations 12 minutes.



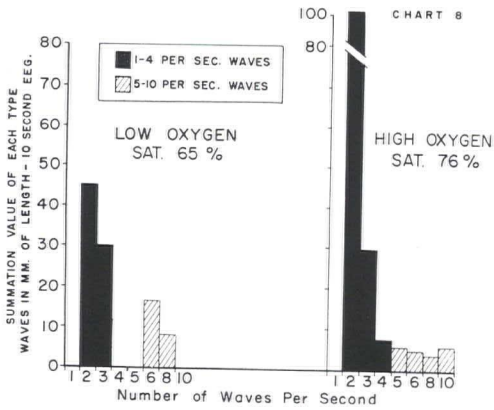
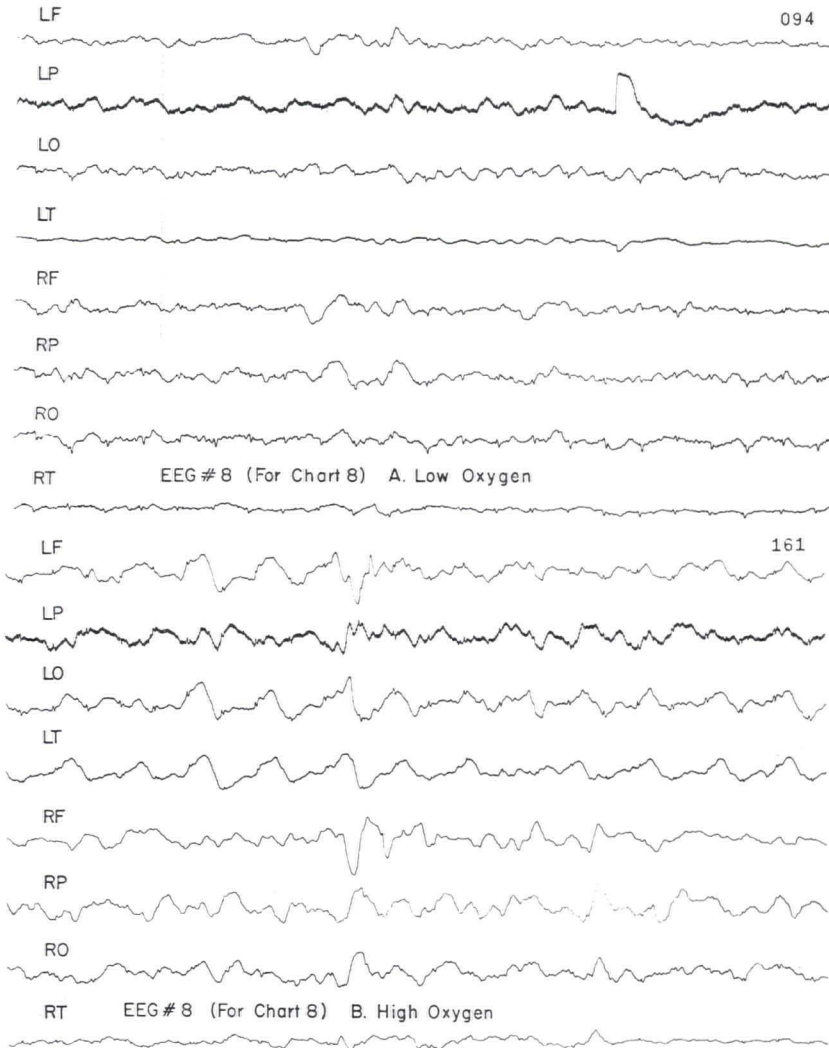


Chart 8

An analysis of waves in a 10 second EEG in low oxygen compared with a 10 second EEG in high oxygen. Infant aged 16 days. Lesion interauricular defect, pulmonary hypertension interventricular defect. Time between observations 26 minutes.



EFFECT OF DEGREE OF HYPOXIA

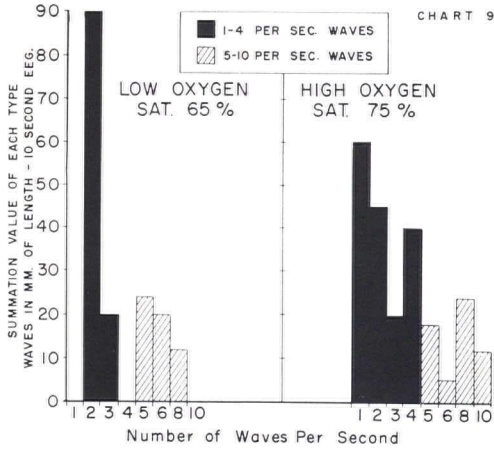
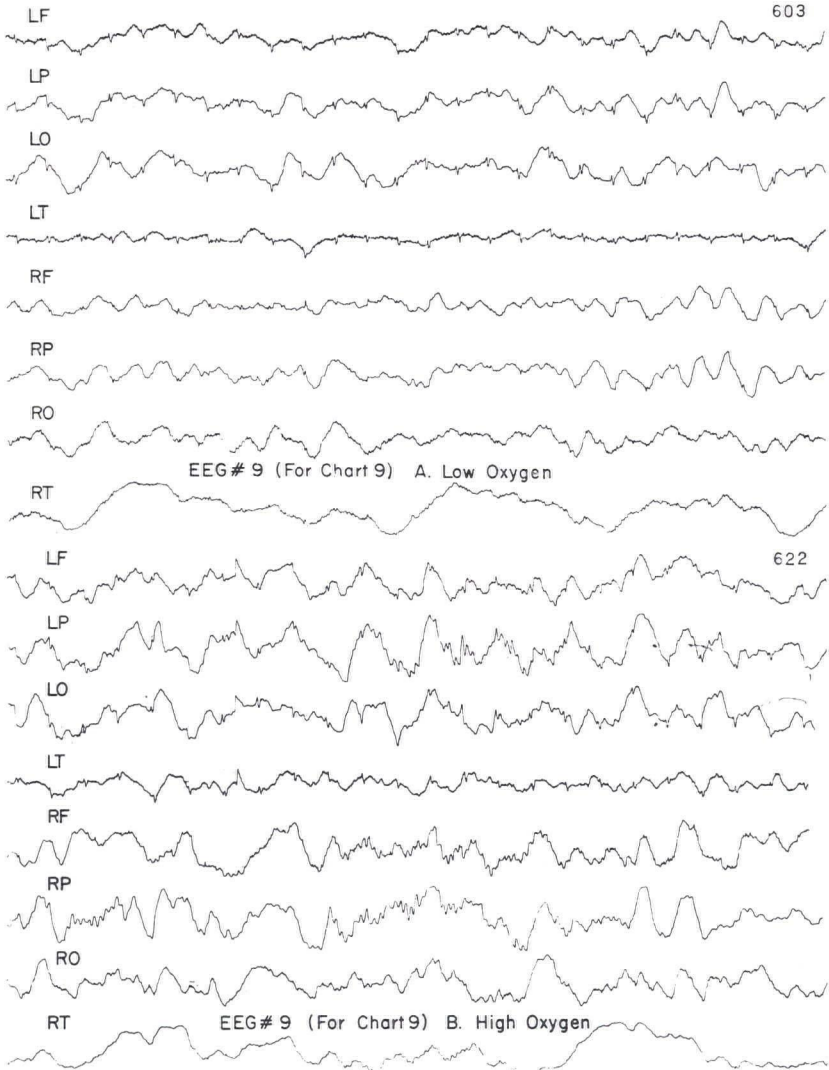


Chart 9

An analysis of waves in a 10 second EEG in low oxygen compared with a 10 second EEG in high oxygen. Infant same as #8, aged 83 days, time between observations 11 minutes.





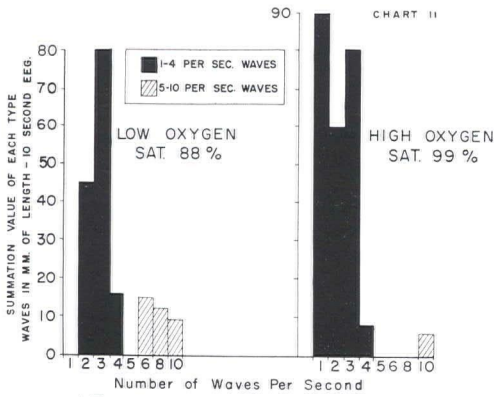
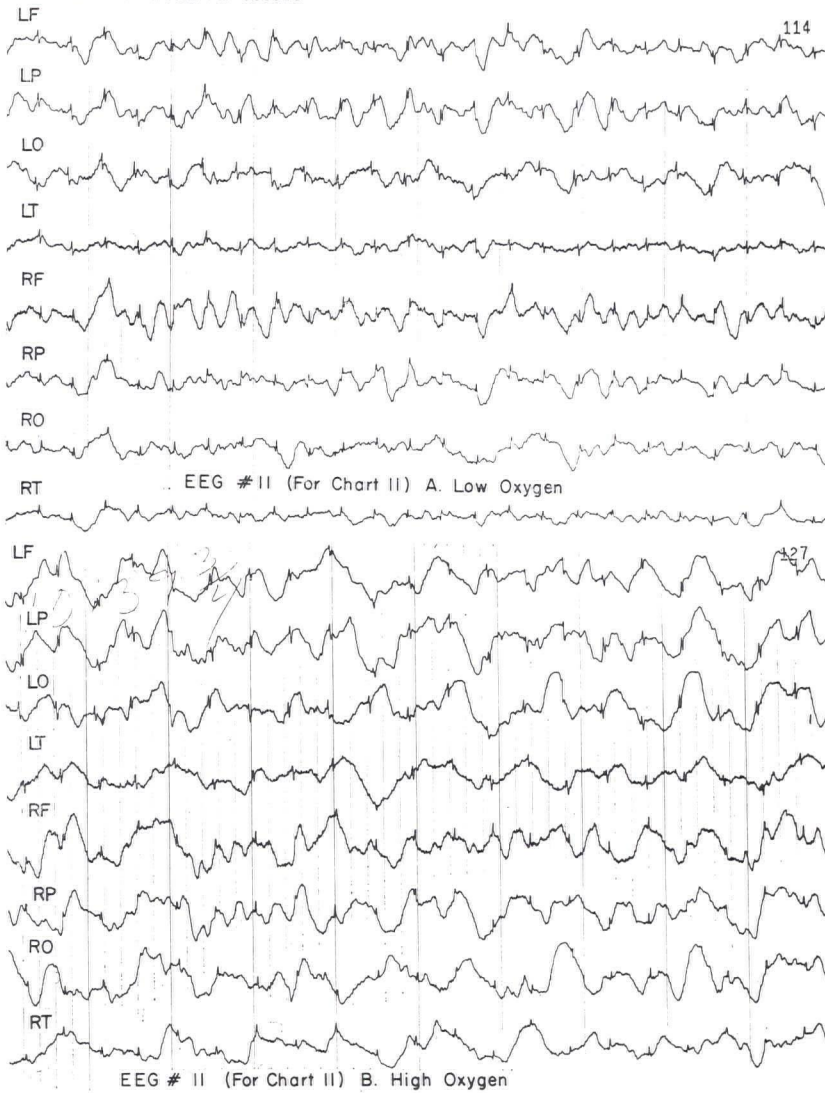


Chart 11

An analysis of waves in a 10 second EEG in low oxygen compared with a 10 second EEG in high oxygen. Infant aged 83 days. Lesion tetralogy of Fallot. Time between observations 5 minutes.



EFFECT OF DEGREE OF HYPOXIA

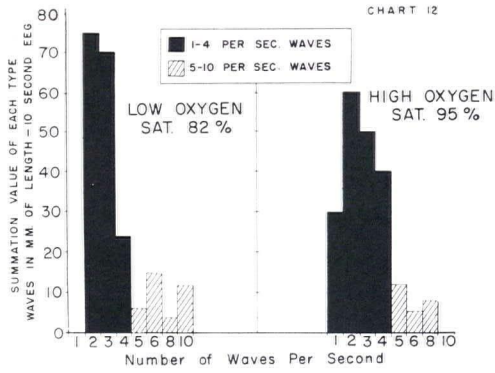
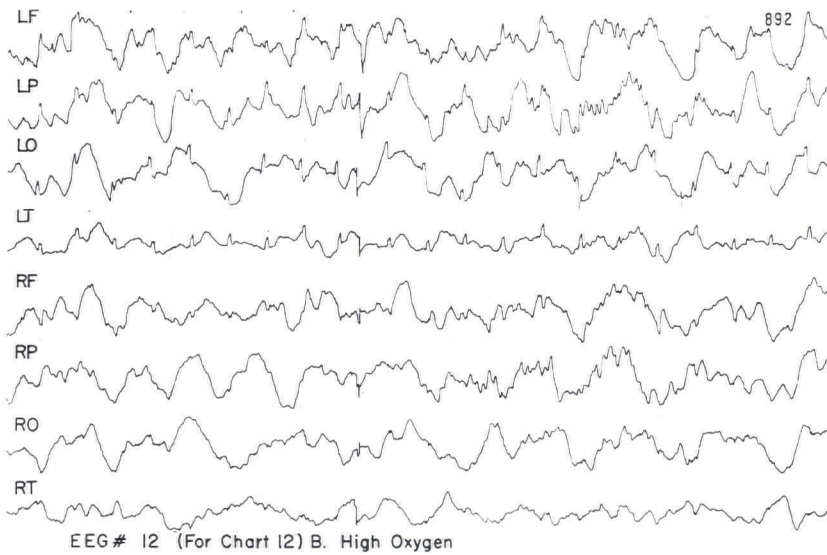
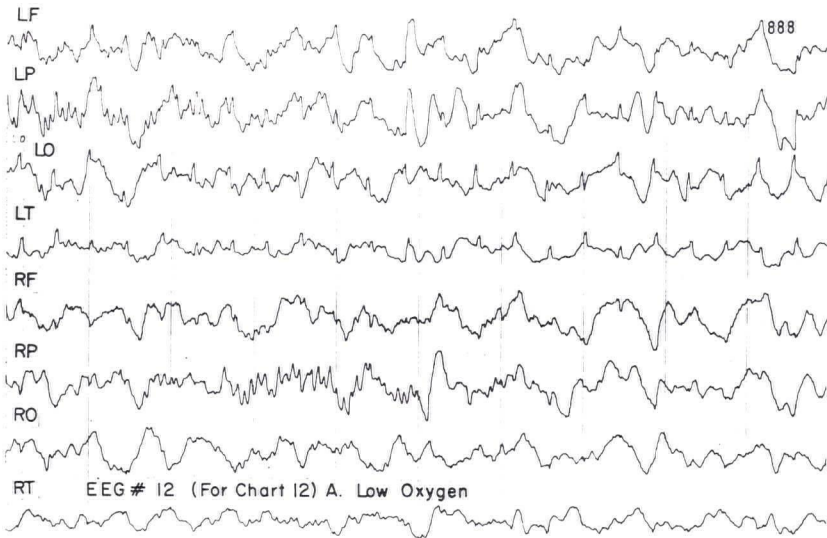


Chart 12

An analysis of waves in a 10 second EEG in low oxygen compared with a 10 second EEG in high oxygen. Infant aged 88 days. Lesion anomalous venous return. Time between observations 9 minutes.



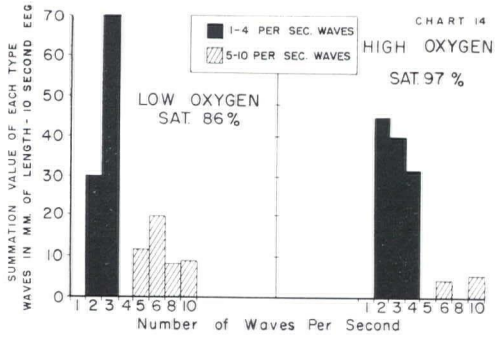
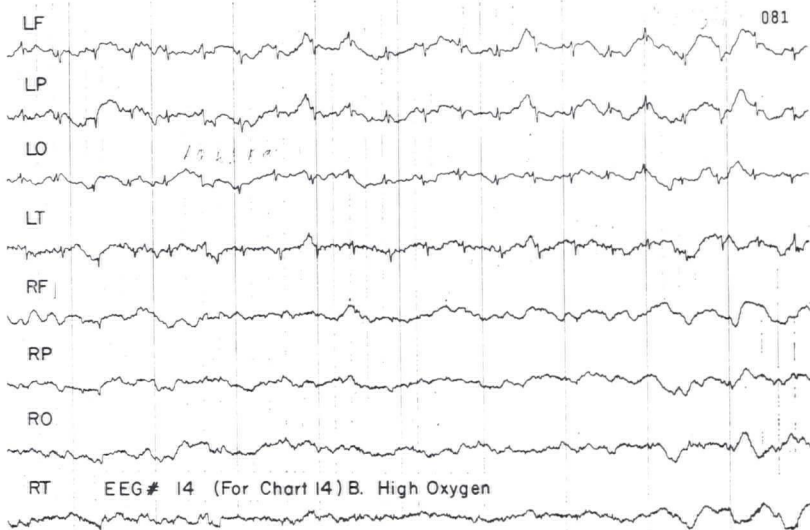
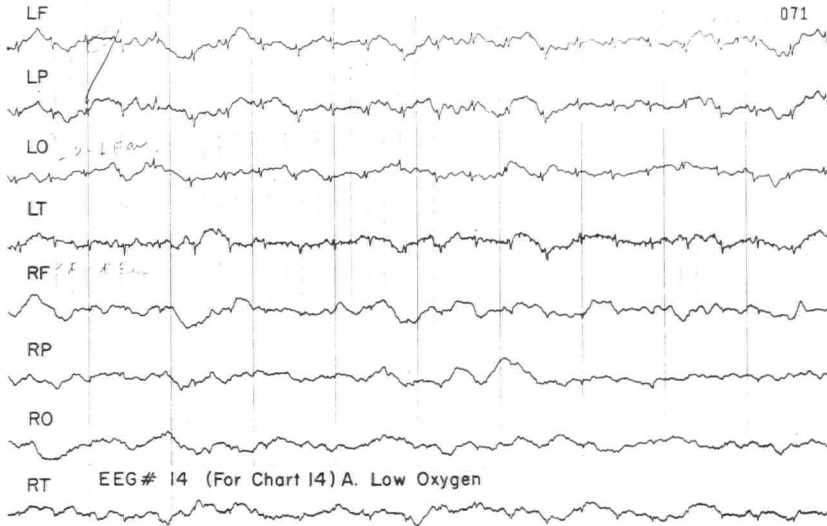
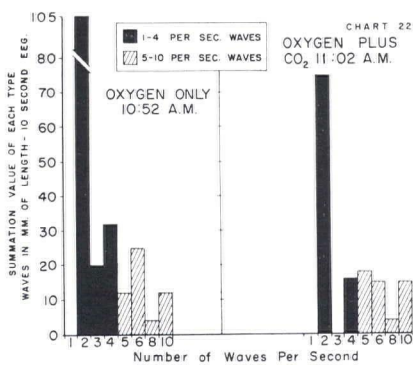
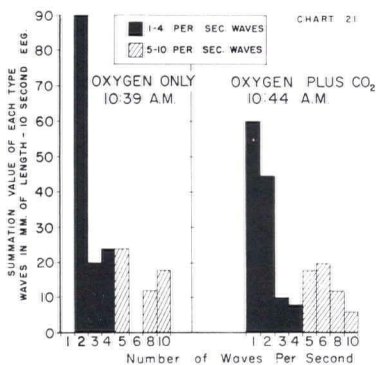
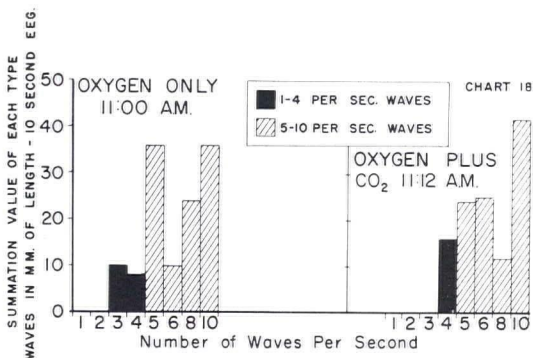
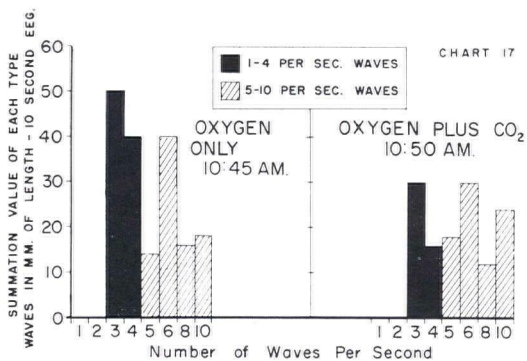


Chart 14

An analysis of waves in a 10 second EEG in low oxygen compared with a 10 second EEG in high oxygen. Infant aged 30 days. Lesion transposition of great vessels. Time between observations 11 minutes.



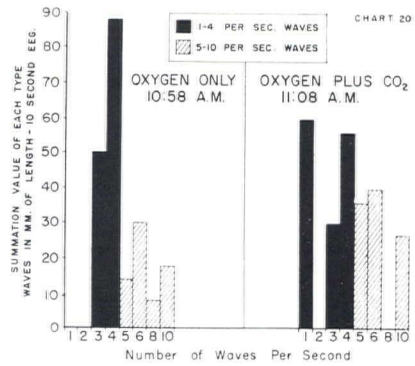
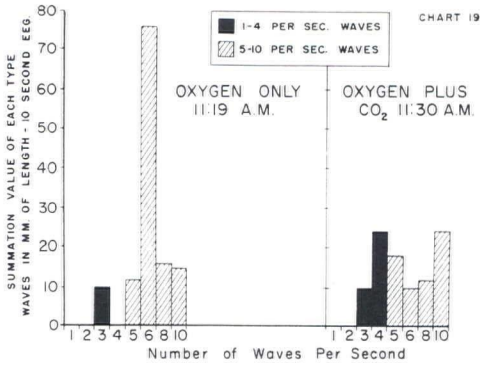
EFFECT OF DEGREE OF HYPOXIA



Charts 17, 18, 21, 22

Analyses of waves in a 10 second EEG while giving 100% oxygen compared with a 10 second EEG while giving 95% oxygen and 5% CO<sub>2</sub>. Normal infants. Blood oxygen saturation stable at 99-100% throughout. Improved with CO<sub>2</sub>.





Charts 19, 20

Analysis of waves in a 10 second EEG while giving 100% oxygen compared with a 10 second EEG while giving 95% oxygen and 5% CO<sub>2</sub>. Normal infants. Blood oxygen saturation stable at 99-100% throughout. Impaired with CO<sub>2</sub>.

EEGs

Unipolar technique used. Reference point in each case is the symmetric ear, left points to left ear, right points to right ear. The calibration is constant throughout this series of EEGs.

EEGs 4, 6, 8, 9, 11, 12, 14

Basic EEGs for corresponding charts.

DISCUSSION

The variation of the EEG from normal through slow waves to electrical silence may sometimes be seen in a short segment of tracing. These changes from 15 to 30 waves per second through progressively slower waves of 1 to 4 per second to gross irregularity and silence are the accompaniment of increasing hypoxia to a final state of anoxia. Three samples of this series of changes seem so important and interesting that they are reproduced here by permission of the authors and publishers, Borkowski and Bernstine,<sup>2</sup> Gastaut and Gastaut,<sup>3</sup> and Gronquist, Seldon and Falconer.<sup>4</sup>

Borkowski and Bernstine<sup>2</sup> studied immature fetuses by the EEG as the supply of oxygen diminished to none, and demonstrated the progression from normal waves to slow irregular waves, and finally to electrical silence. It is evident as shown in Plate 1, taken with the legend from their report, that there is a deteriorating spectrum of activity in decreasing oxygen supply to the point of electrical silence.

Studies during induced cardiac standstill, and during certain anesthetic accidents show also the effect of increasing anoxia although other factors also are involved.

Gastaut and Gastaut<sup>3</sup> in their study of 174 convulsive children found certain ones in whom a typical seizure could be reproduced by vagal stimulation. This provided a chance to obtain an EEG shown in Plate II during a prolonged cardiac arrest of 18 seconds. A few seconds of minimal EEG activity were followed by



EFFECT OF DEGREE OF HYPOXIA

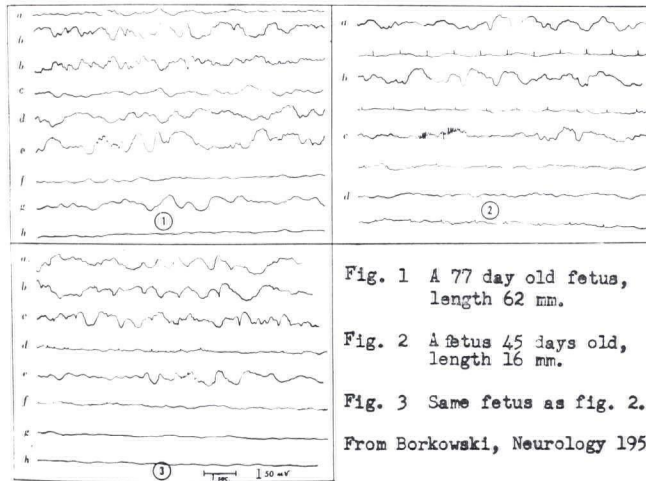


Plate 1. (From Borkowski)<sup>4</sup>

Figure 1

A 77 day old fetus, CR length 62 mm. All bipolar readings from fronto-parietal areas. (40) a. recording from surface of head, superficially placed electrodes, (depth of 3 mm). (50) b. irregular rhythm. (57) c. diminished activity. Deeply placed electrodes (depth of 1 cm). (70) d. usual rhythm. (74) e. usual rhythm. (80) f. diminished activity (85) g. paroxysmal bursts of slow activity. (90) h. end of activity. (Numbers in parenthesis represent time in minutes) after ligation of blood supply to fetus.

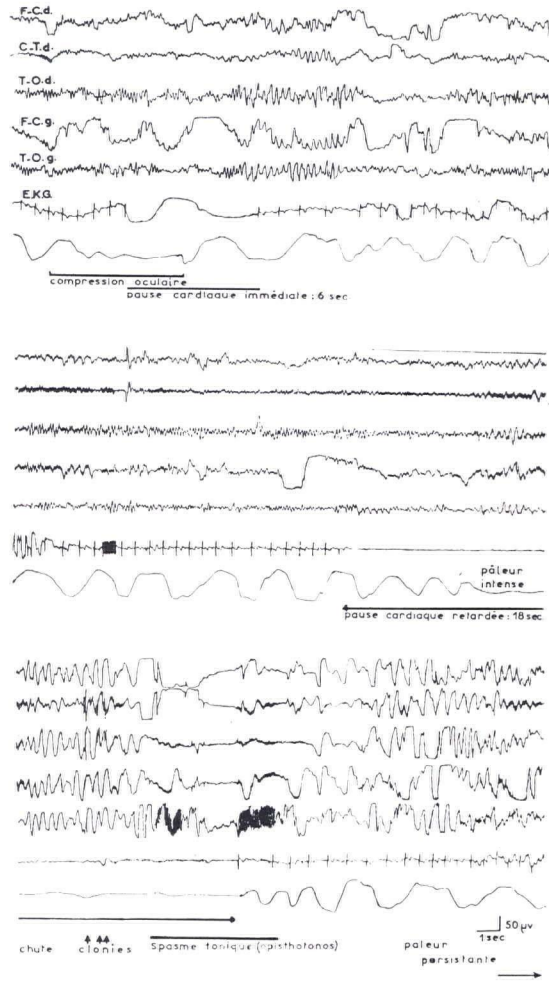
Figure 2

A fetus 43 to 45 days old, CR length 16 mm. All bipolar leads from fronto-parietal areas. Superficially placed electrodes (depth 3 mm). (30) a. usual rhythm. (35) b. paroxysmal discharge of slow activity. (42) c. sleep spindles. (65) d. diminished activity. Electrocardiogram at corresponding time is seen below each line of EEG.

Figure 3

Same fetus as Fig. 2. All bipolar readings from fronto-parietal areas. Deeply inserted electrodes (depth of 1 cm) (72) a. usual activity. (72) b. usual activity. (74) c. paroxysmal discharge of slow activity. (74) d. marked slowing of EKG with irregularity of rhythm. (80) e. diminished activity with occasional fast wave discharge. (77) f. very occasional EKG seen; (78) g. absence of activity (78) h. absence of EKG.

complete recovery. Gronquist, Seldon and Falconer<sup>4</sup> give an example of recovery after unexpected breathing arrest as a complication of anesthesia, the EEG tracing of which is reproduced. It shows recovery although the EEG record had progressed to a "considerable decrease in wave forms". This tracing is reproduced in Plate III. It will be noted that tracing B is marked only by one 1-per-second wave upon which are superimposed 6 fine waves. There were also two fine waves near the start and 2 near the end, with periods of electrical silence interspersed which constituted most of this record. The patient then went on to a clinical recovery from this serious condition. Torres, Frank, Cohen, Lellehei and Kasper<sup>5</sup> relate the EEG changes during cardiac arrest to increasing hypoxia in six stages; 1. no slowing below 4-6 per second;



EEG Clin. Physiol. 10:609 1958

Plate 2 (From Gastaut)<sup>5</sup>

With cardiac standstill slow EEG waves increase, become slower, and irregular and stop, and then start again as slow irregular waves progressing to normal.

2. occasional slowing below 4-6 per second; 3. slowing to 1-3 per second for short infrequent periods; 4. slowing to 1-3 per second for prolonged or repeated periods; 5. slowing to 1-3 per second for prolonged and repeated periods and showing decreasing amplitude; 6. periods of electrical silence.

The EEG spectrum of increasing hypoxia in the newborn infant differs from that observed in the adult due to relative immaturity of the cerebral cortex in the infant. Because of this the newborn infant has central nervous system functions of

EFFECT OF DEGREE OF HYPOXIA

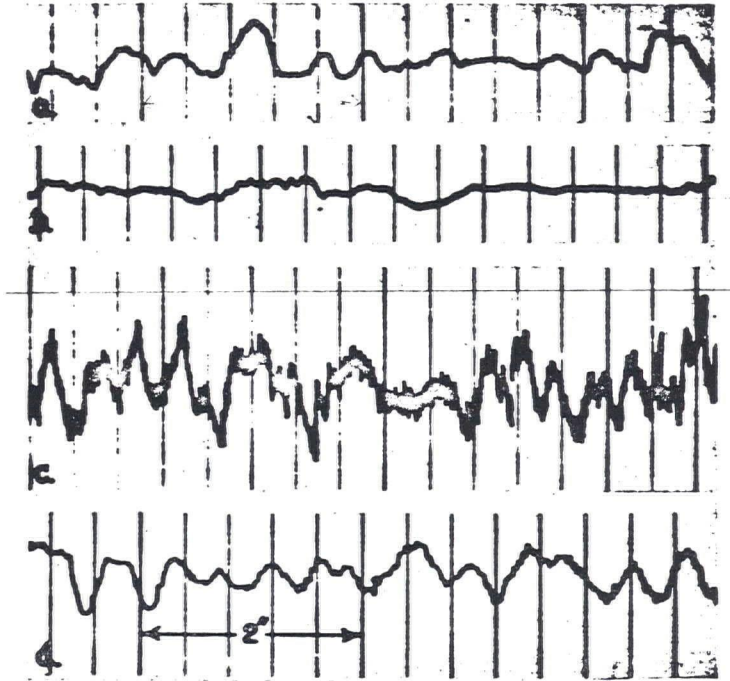


Plate 3 (From Gronqvist)

A 6-second EEG sample taken in a patient unconscious as a result of an anesthetic accident 1-1/2 hours previously in which she was apnoeic and cyanotic for about 6 minutes. Patient made complete clinical recovery.

a lower subcortical level which are characterized in the EEG by a production of relatively more slow waves. These in turn are subject to considerable variation being readily influenced by arterial oxygen saturation plasma CO<sub>2</sub>, blood glucose, level of sleep, and less importantly by factors such as muscular contraction. In fact, Bernstine, Borkowski and Price<sup>6</sup> have shown in their study of fetal EEGs that 23 of 32 had waves as slow as 1/2 per second, subjects in whom sleep should not be interfering, but the other factors may be operative. Even though the EEG pattern should parallel the oxygen saturation, within the limits of these observations, based on a 10 percent change in oxygen saturation, the authors were unable to show it in a predictable way. Admittedly none of our cases showed the low oxygen saturation level of 40 percent suggested by Clowes, Kretchmer, McBurney and Simeone<sup>7</sup> as the level below which EEG changes due to hypoxia become evident.

SUMMARY

An attempt was made to employ EEG techniques to determine the effect of relative hypoxia on brain cells of newborn or young infants. The cases consisted of fourteen infants aged one week to five months who were suffering from congenital heart disease and had oxygen saturations of 49 percent to 88 percent. Administration of oxygen



caused an increase of saturation to levels of 65 to 99 percent which reflected an increase of at least 10 percent in each infant from lowest to highest level, over a period of 4 to 38 minutes. EEG tracings were taken at the lowest and highest attained levels.

The results showed that 6 infants had a decrease in slow waves (1-4 cps) interpreted as improvement, whereas eight had an increase interpreted as impairment. The effect of carbon dioxide on the EEG tracing was studied by administering 5 percent carbon dioxide in 95 percent oxygen to infants who were already in 95 percent oxygen. This was done in seven infants, five of whom showed a decrease in 1-4 cps, the other two demonstrating an increase. We concluded that an increase of oxygen saturation of 10 percent at the levels studied did not produce indisputable evidence of improvement in EEG tracings.

#### REFERENCES

1. Howard, P. J., and Bauer, A. R.: The effect of degree of hypoxia on the electroencephalogram infants. *J. Pediat.* 61:511, 1962.
2. Borkowski, H. J., and Bernstine, R. L.: Electroencephalography of the fetus, *Neurology* 5:362, 1955.
3. Gastaut, H., and Gastaut, Y.: Electroencephalographic and clinical study of anoxic convulsions in children, *Electroencept. Clin. Neurophysiol.* 10:607, 1958.
4. Gronqvist, Y. K. J., Seldon, T. H., and Faulconer, A., Jr.: Cerebral anoxia during anesthesia, prognostic significance of electroencephalographic changes. *Ann. chir. gyn. fenn.* 41:149, 1952.
5. Torres, F., Frank, G. S., Cohen, M. M., Lillehei, C. W., and Kaspar, N.: Neurologic and electroencephalographic studies in open heart surgery, *Neurology* 9:174, 1959.
6. Bernstine, R. L., Borkowski, W. J., and Price, A. H.: Prenatal fetal electroencephalography, *Am. J. Obst. & Gynec.* 70:623, 1955.
7. Clowes, G. H. A., Jr., Kretchmer, H. E., McBurney, R. W., and Simeone, F. A.: The electroencephalogram in the evaluation of the effects of anesthetic agents and carbon dioxide accumulation during surgery, *Ann. Surg.* 138:558, 1953.