

12-1959

Marlex Mesh - A New Plastic Mesh For The Repair Of Hernia

Joseph L. Ponka

John H. Wylie

Leo Chaikof

Charles Sergeant

Brock E. Brush

Follow this and additional works at: <https://scholarlycommons.henryford.com/hfhmedjournal>

 Part of the [Life Sciences Commons](#), [Medical Specialties Commons](#), and the [Public Health Commons](#)

Recommended Citation

Ponka, Joseph L.; Wylie, John H.; Chaikof, Leo; Sergeant, Charles; and Brush, Brock E. (1959) "Marlex Mesh - A New Plastic Mesh For The Repair Of Hernia," *Henry Ford Hospital Medical Bulletin* : Vol. 7 : No. 4 , 278-280.

Available at: <https://scholarlycommons.henryford.com/hfhmedjournal/vol7/iss4/9>

This Article is brought to you for free and open access by Henry Ford Health System Scholarly Commons. It has been accepted for inclusion in Henry Ford Hospital Medical Journal by an authorized editor of Henry Ford Health System Scholarly Commons. For more information, please contact acabr4@hfhs.org.

MARLEX MESH — A NEW PLASTIC MESH FOR THE REPAIR OF HERNIA

JOSEPH L. PONKA, M.D., JOHN H. WYLIE, M.D., LEO CHAIKOF, M.D.,
CHARLES SERGEANT, M.D. AND BROCK E. BRUSH, M.D.*

The introduction of new plastic materials has been one of the most fascinating developments of the past decade. The medical uses of these new plastic materials have been widespread. As each new plastic is introduced, its potential uses in the medical field are soon investigated. Some have physical qualities which lend themselves very readily to insertion into the body for various purposes. Of these, Dacron, Ivalon, Teflon and Polyethylene have become most useful. Polyethylene in the form of tubing has been widely used since its early introduction, and its many advantages over rubber tubing soon appreciated. A new Polyethylene plastic mesh named Marlex 50 was introduced several years ago in the hope that it would be useful for the repair of hernia.¹ A monofilament mesh, it has outstanding chemical resistance to acids and alkalis. It has a high tensile strength, creates very little foreign body reaction and is well tolerated in tissues.

ADVANTAGES OVER METAL MESH

This plastic material has many advantages over any type of metal since it is more pliable and readily inserted to any sized defect. It does not have the disadvantage of fragmenting or breaking up which the metal meshes do. It thus can be used in an inguinal area, or in any other area in the body, where it is subjected to considerable bending, without resulting in distress or discomfort to the patient. This plastic material is less affected by infection than are the metal types of prosthetics. Infection studies in animals showed that granulation tissue will grow through the mesh in the presence of purulent infection without slough of the graft or sinus formation.¹ A further significant advantage is that it is much more easily handled, and easier to work with in every way. These advantages make it seem likely that Marlex will completely replace types of metal mesh previously in use.

LABORATORY INVESTIGATIONS

This new plastic mesh had been previously tested.^{2,3} However, we implanted it in dogs and guinea pigs, completely removing a segment of the abdominal wall and then using the Marlex mesh to bridge the gap. This material was left in place for six months and then the areas were examined. A rectangular area of 6 cm. x 8cms., of the rectus muscle and peritoneum which had been excised and the Marlex inserted to close this gap was completely firm and intact giving a normal appearing abdominal wall when later examined (Figure 1). In all cases, the wounds healed without infection and a very excellent support was obtained. Cross section and microscopic examination of the removed specimen showed that there was very little foreign body reaction to the material. It was well tolerated in the animal tissues. These favorable properties make this Marlex Mesh the best prosthesis for replacing tissue defects which we have yet encountered.

CLINICAL MATERIAL

The first operation in which Marlex mesh was used was done by one of us

*Division of General Surgery.

Marlex Mesh

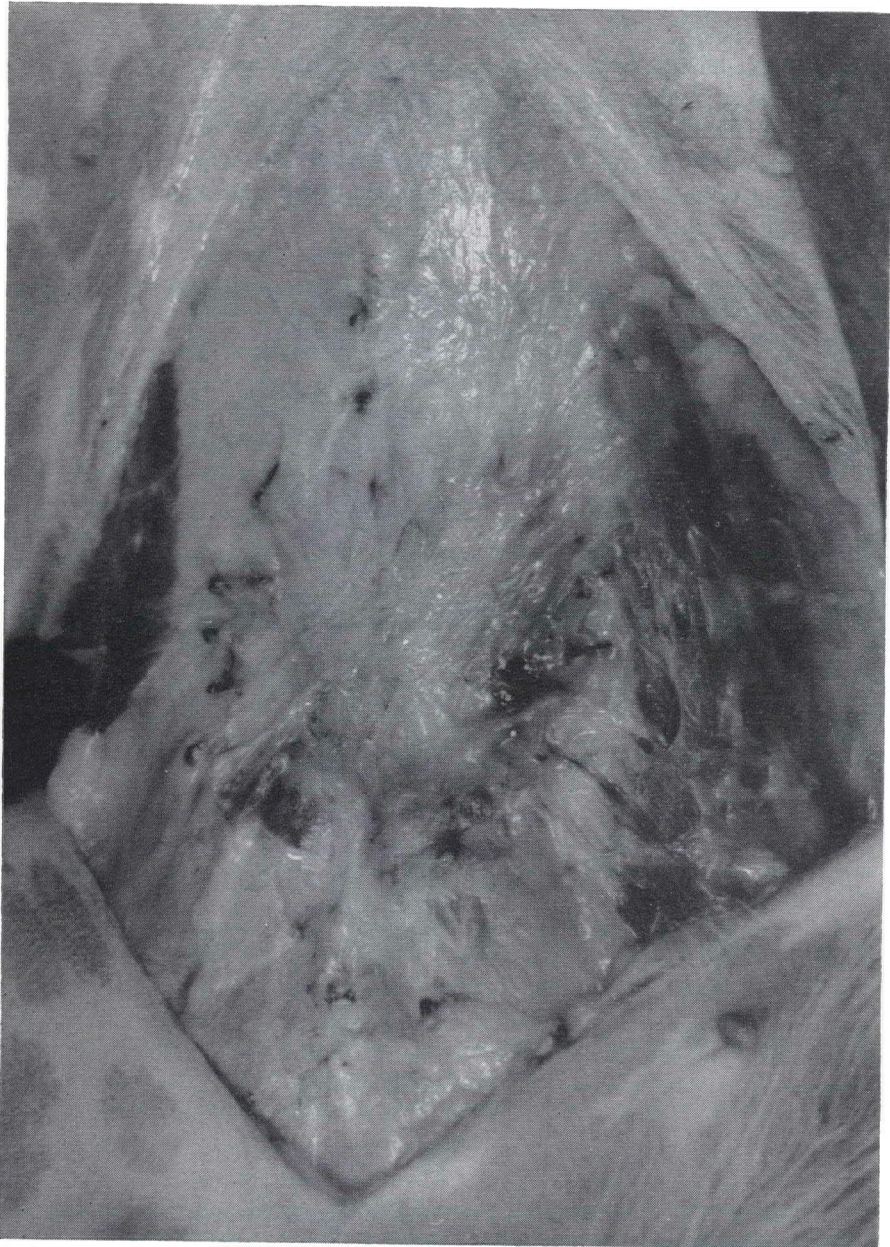

Figure 1

The appearance of the abdominal wall of a dog six months after the total thickness of the wall was replaced by marlex mesh.

(BEB) on 1/14/59. This was a large incisional hernia occurring through an old appendectomy scar. There had been perforation of the appendix with a lot of purulent drainage resulting in a large hernia at the location of the incision. There

was such loss of tissue that when the layers were developed at the time of the operation, they could not be satisfactorily approximated without tension. Relaxing incisions were used and the tissues could then be more satisfactorily approximated, however, a very weak area remained. A Marlex prosthesis 8 inches by 6 inches was sutured under the anterior layer of the fascia, completely covering the weak area of the repair (Fig. 2). The patient's postoperative course was uneventful. The wound healed very well and has remained healed. The abdominal wall is strong and in excellent condition.

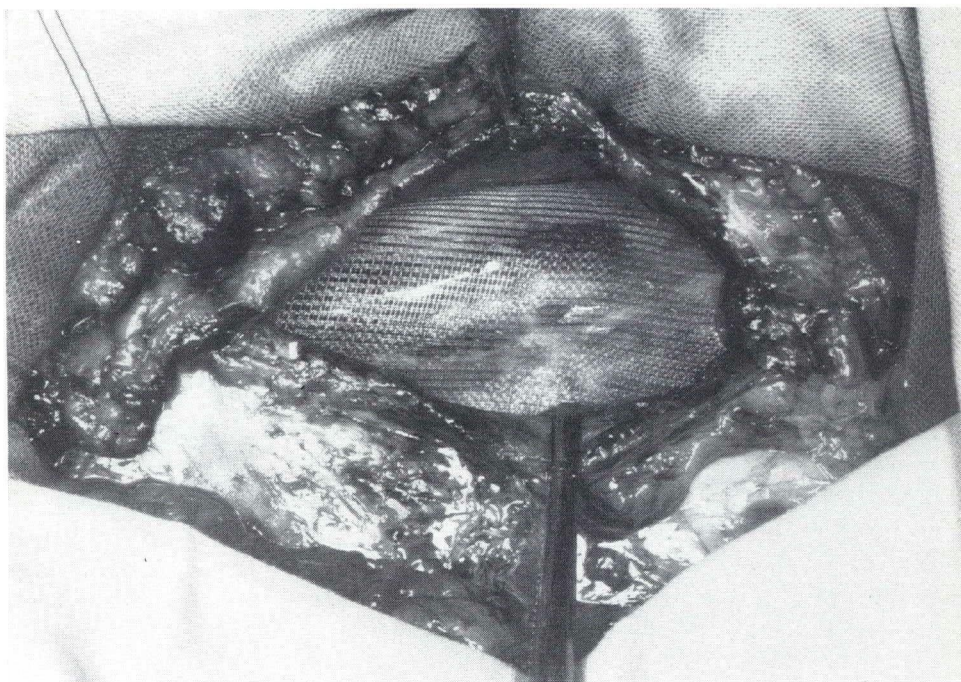


Figure 2

Marlex Mesh inserted between fascial layers of patient.

CONCLUSIONS

The unusual physical properties of Marlex — a polyethylene mesh — make it a very valuable plastic for surgical prosthesis. We have been well pleased with the results obtained with its use in the laboratory and in clinical practice as an adjunct in the repair of difficult herniae. Its advantages over metal meshes previously used make it likely to become the most popular material in its field.

REFERENCES

1. Usher, F. C., Ochsner, J., and Tuttle, L. L. D., Jr.: Use of Marlex mesh in the repair of incisional hernias, *Am. Surgeon* 24:969, 1958.
2. Usher, F. C. and Wallace, S. A.: Tissue reaction to plastics; comparison of nylon, orlon, dacron, and teflon, *A.M.A. Arch. Surg.* 76:997, 1958.
3. Usher, F. C., and Gannon, J. P.: Marlex mesh; a new plastic mesh for replacing tissue defects; I. Experimental studies, *A.M.A. Arch. Surg.* 78:131, 1959.