

3-1953

## Heteropic Pancreatic Tissue In The Gastric Wall

Robert J. Priest

Follow this and additional works at: <https://scholarlycommons.henryford.com/hfhmedjournal>



Part of the [Life Sciences Commons](#), [Medical Specialties Commons](#), and the [Public Health Commons](#)

---

### Recommended Citation

Priest, Robert J. (1953) "Heteropic Pancreatic Tissue In The Gastric Wall," *Henry Ford Hospital Medical Bulletin* : Vol. 1 : No. 1 , 21-25.  
Available at: <https://scholarlycommons.henryford.com/hfhmedjournal/vol1/iss1/6>

This Article is brought to you for free and open access by Henry Ford Health System Scholarly Commons. It has been accepted for inclusion in Henry Ford Hospital Medical Journal by an authorized editor of Henry Ford Health System Scholarly Commons. For more information, please contact [acabrer4@hfhs.org](mailto:acabrer4@hfhs.org).

## HETEROPIC PANCREATIC TISSUE IN THE GASTRIC WALL

ROBERT J. PRIEST, M.D.\*

In 1859 Klob first identified heterotopic pancreatic tissue. This ectopic tissue has been found in all portions of the gastrointestinal tract and in adjacent organs. In an excellent review in 1950, Busard and Walters (1) tabulated 149 cases of heterotopic pancreatic tissue in the gastric wall. Since their review there have been 13 additional cases recorded in the literature (2,3,4,5,6,7,8). The following case presented the typical x-ray appearance of this lesion and offered perplexing symptoms mimicking peptic ulcer.

### CASE REPORT

J.B.K., a 29 year old, white male, boiler fireman was seen in the Henry Ford Hospital gastro-intestinal clinic on September 19th, 1949. He complained of symptoms of one month's duration with a fluttering feeling in the abdomen, a constant hunger sensation in the epigastrium, and gnawing dull distress when the stomach was empty. The distress was completely, but temporarily, relieved by eating food or by taking baking soda. He had night distress, but no pain radiating to the back.

Physical examination revealed weight of 135 pounds, height of 70 inches. Eyes, ears, nose and throat were normal. There was no thyroid enlargement or lymphadenopathy. The chest was clear. The heart was not enlarged, no murmurs, or irregularities. The blood pressure was 115/60. The abdomen presented no palpable masses or tenderness. Genitalia and rectal examinations were normal.

Laboratory: The blood count and urinalysis were normal. Serology was negative. Fractional gastric analysis revealed a fasting free acid of 12 degrees, and a top free acid of 24 degrees after stimulating test meal.

X-ray of the chest was normal. An x-ray of the stomach was normal except that the duodenal cap filled with difficulty and a persistent defect with incisura was noted. In six hours the stomach emptied normally. X-ray of the colon revealed non-rotation of the cecum with the appendix lying in the upper right quadrant of the abdomen (see fig. 1).

The patient was placed on a strict ulcer management regime. He remained free from symptoms for three months. After an episode of nervous tension at his job, the typical ulcer rhythm returned. He had epigastric distress, relieved by eating. There was some pain at night. Progress x-ray of the stomach and duodenum in six months was similar to the first examination. Seven months later

\*Associate in the Division of Gastroenterology.

he witnessed an attack of syncope in a neighbor. The epigastric burning distress returned and persisted for a week. During this recurrence a third x-ray of the stomach revealed a polypoid filling defect with smooth outline on the greater curvature of the pyloric antrum (see fig 1). In the center of the polypoid filling

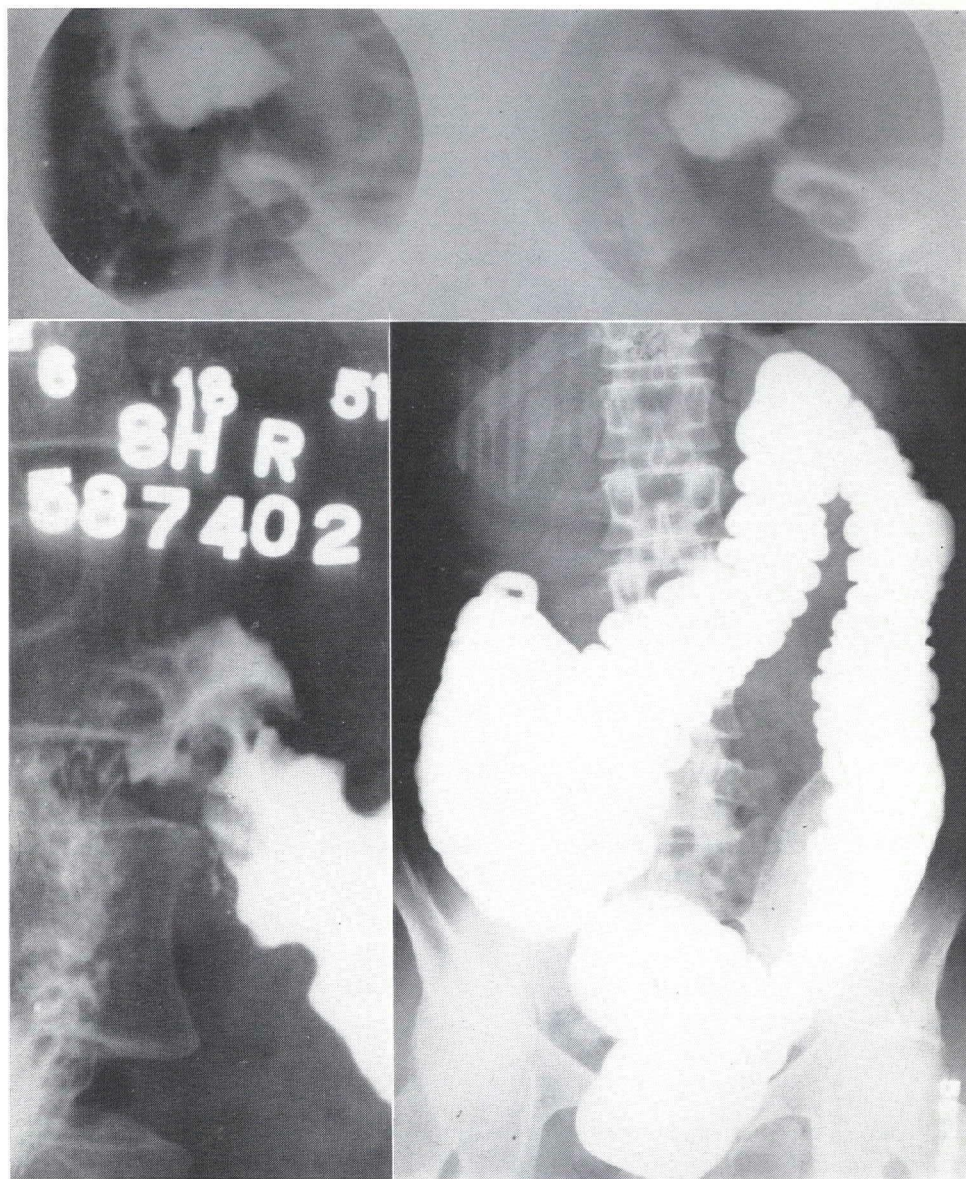

Figure 1

Above: Note small fleck of retained barium in center of the defect.  
Below, left: Smooth contour of filling defect on greater curvature near the pylorus.  
Below, right: Non-rotation of the cecum with appendix in upper right quadrant.

defect there was retained a small fleck of barium. The lesion was found on fluoroscopy to be well fixed in this location. There was no delay in emptying the stomach.

Gastroscopy was done and the pylorus was observed to open and close, with shortening of the distal stomach. Slightly below the angulus on the greater curvature wall was observed a raised area at the convergence of several gastric rugal folds. This lesion did not appear to be a typical gastric polyp. The possibility of an intramural lesion was considered.

The patient was operated and the stomach palpated. A button-like, freely movable, small tumor was felt 2 cm. in diameter, and extending from a point 2.5 cm. proximal to the pyloric region. This was believed to be a benign lesion. Therefore a conservative resection of the distal stomach was performed at the junction of the lower and middle thirds of the stomach with anastomosis to the duodenum. The duodenum itself was normal to inspection and palpation. Vagotomy was not done. The appendix was removed because of its abnormal location and malrotation of the cecum.

The gross specimen presented a small raised area of mucosa near the pyloric end of the resected stomach. It was a well circumscribed submucosal mass. At

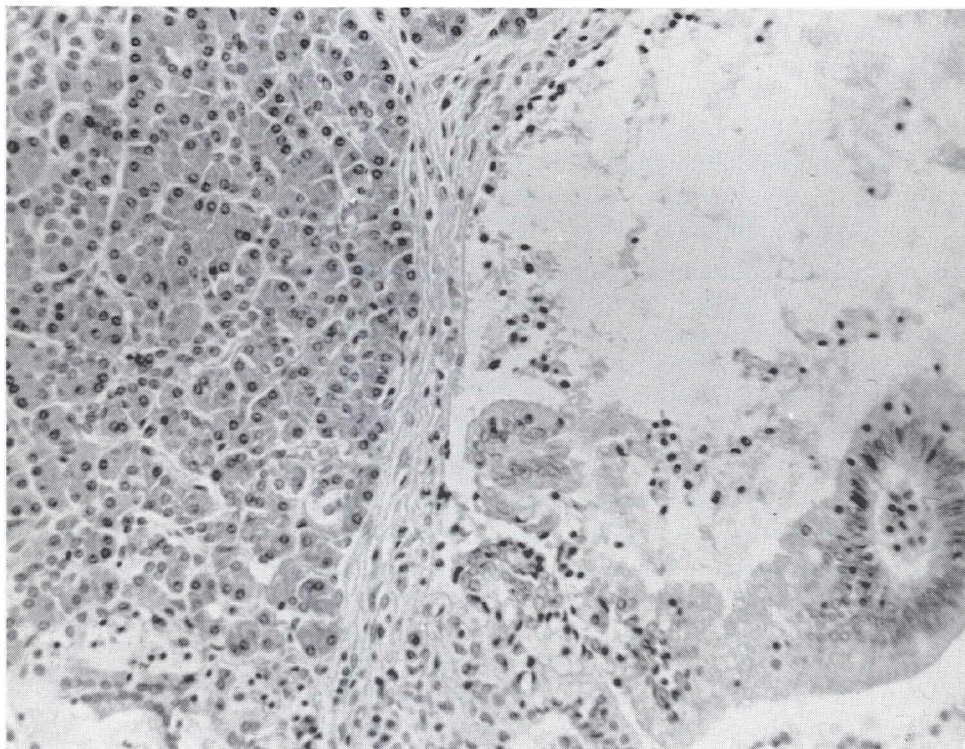


Figure 2

Pancreatic acini and ducts within the gastric mucosa and muscle.

its apex the mucosa was dimpled and appeared to have a pseudo-ostium. In cut section the mass was grayish white in appearance.

Microscopic examination of the tumor revealed a gastric mucosa without significant alteration. Within the mucosa, and more marked within the muscle, were numerous islands of pancreatic acini and ducts (see fig. 2). The ducts were lined by orderly epithelium, surrounded by well formed stroma, containing a very slight infiltrate of chronic inflammatory cells. There were no islets of Langerhans identified.

The patient recovered promptly from the operative procedure and has remained symptom free for eighteen months.

#### COMMENT

Cases of heterotopic pancreatic tissue in the stomach are not rare. They offer a challenge in diagnosis to the roentgenologist and to the surgeon. Their recognition as benign tumors is important, if unduly radical gastric surgery is to be avoided. Several authors have drawn attention to the wisdom of a more conservative operative procedure than subtotal gastrectomy (6,8,13,15).

The aberrant pancreatic tissue in the stomach may be subject to all the complications which affect the pancreas proper. Thus hemorrhage, carcinoma, and necrosis have been described. Jacobs (5) has considered those cases in which the heterotopic pancreatic tissue causes an ulcer-like syndrome, as perhaps the most perplexing. Many cases have been reported with symptoms similar to peptic ulcer (1,2,3,4,5,6,7,8,9,11,12,13). Symptoms may also be suggestive of pyloric obstruction, cholecystitis, or malignant gastric neoplasm. Pancreatic rests may be found in the presence of histamine-refractory achlorhydria (14).

Benner (6) and Littner (8) have recently emphasized the gross appearance of these lesions as a guide to their recognition during surgery. The gross morphology has been described in the literature, as a mucosal nodule like a nipple (7), a pedicle (11), a papillary projection (2), umbilicated (10), mucosal diverticulum (1), or the summit of lesion notched (9). Benner preferred to call the mucosal depression a pseudodiverticulum. The heterotopic pancreatic tissue is usually a relatively firm mass in the submucosa. Overlying is the moundlike mucosa, at the apex of which is a centrally located pit or pouch.

The roentgen appearance of this mucosal dimple has been described by Kjellman (3,4) and Littner (8). When a barium fleck is caught in the dimple of the pseudodiverticulum, the finding is highly suggestive of heterotopic pancreatic tissue. The smooth filling defect of this lesion is usually less than 2-4 cm. in diameter and is located in the antrum. Differentiation from leiomyoma may be difficult; the latter is usually much larger. Many reported cases have had normal x-ray studies of the stomach and duodenum, prior to the definitive x-ray which demonstrated the filling defect of this lesion. Jacobs (5) reported a case similar to the one presented here, in which a deformed and irregular duodenal bulb was found to be entirely normal at laparotomy.

The explanation for symptoms mimicking peptic ulcer has been attributed by Waugh and Harding (13) to various factors: (a) pyloric obstruction with polypoid excrescence into the lumen, (b) although no organic stenosis, the presence of the tissue in the muscular wall may interfere with peristaltic activity, (c) peptic ulceration may actually arise from the discharge of pancreatic juice through a duct into the submucosa.

### SUMMARY

A case is presented of heterotopic pancreatic tissue in the gastric antrum. This condition gave symptoms simulating peptic ulcer. Surgery verified the tumor, but not the ulcer.

The gross appearance of the lesion with dimpled mucosa and a pseudodiverticulum, enabled the surgeon to select less radical surgery for this benign lesion. When present, the x-ray finding of a fleck of barium in the central depression of the polypoid defect may help in the differential diagnosis.

### BIBLIOGRAPHY

1. Busard, J. M. and Walters, W., Heterotopic pancreatic tissue; report of case presenting symptoms of ulcer and review of recent literature, *ARCH. SURG.* 60:674, 1950.
2. Wheelock, M. C., Atkinson, A. J. and Teloh, H. A. Case report: Aberrant pancreatic tissue in the stomach wall, *GASTROENTEROLOGY* 13:594, 1949.
3. Kjellman, L. Aberrant pancreas, *ACTA RADIOL.* 34:225, 1950.
4. Kjellman, L. Further cases of aberrant pancreas, *ACTA RADIOL.* 36:89, 1951.
5. Jacobs, L. G., Richmond, T. E. and Tucker, J. M. Aberrant pancreatic tissue in the gastric wall, *CALIFORNIA MED.* 75:221, 1951.
6. Benner, W. H. Diagnostic morphology of aberrant pancreas of stomach; report of 5 cases, *SURGERY* 29:170, 1951.
7. Allen, R. K., Rosenak, B. D. and Permer, E. Aberrant pancreatic tissue in the stomach, *GASTROENTEROLOGY* 21:148, 1952.
8. Littner, M. and Kirsch, I. Aberrant pancreatic tissue in the gastric antrum; report of seven cases, *RADIOLOGY* 59:201, 1952.
9. Chapman, B. M., Vogel, W. F. and Schomaker, T. P. Massive gastric hemorrhage associated with aberrant pancreas in stomach, *GASTROENTEROLOGY* 8:367, 1947.
10. Roach, J. F. and Poppell, M. H. Roentgen demonstration of aberrant pancreatic nodule in stomach; report of 3 cases, *AM. J. ROENTGENOL.* 56:586, 1946.
11. Collett, R. W. Prepyloric polypus in stomach of child diagnosed histologically as aberrant pancreatic tissue; report of case and review of literature, *AM. J. DIS. CHILD.* 72:545, 1946.
12. Barbosa, J. J. deC., Dockerty, M. B. and Waugh, J. M. Pancreatic heterotopia; review of literature and report of 41 authenticated surgical cases, of which 25 were clinically significant, *SURG., GYNEC. & OBST.* 82:527, 1946.
13. Waugh, T. R. and Harding, E. W. Heterotopic pancreatic tissue in region of pyloric orifice; radiological and pathological analysis of 5 cases of clinically suspected peptic ulcer in which only pancreatic rests were found, *GASTROENTEROLOGY* 6:417, 1946.
14. Kalfayan, B. Duodenitis with diverticulum and ectopic pancreatic tissue, *ARCH. PATH.* 42:228, 1946.
15. Barbosa, J. J. deC. and Waugh, J. M. Heterotopic pancreatic tissue, clinically significant, in gastric wall of boy 6 years of age, *PROC. STAFF MEET., MAYO CLIN.* 22:25, 1947.