

Henry Ford Health System

Henry Ford Health System Scholarly Commons

Otolaryngology Articles

Otolaryngology - Head and Neck Surgery

2-1-2018

Asymptomatic Septal Mass.

Richard L. Arden

Zachary H. Griggs

Henry Ford Health System, ZGRIGGS1@hfhs.org

Elizabeth A. Wey

Follow this and additional works at: https://scholarlycommons.henryford.com/otolaryngology_articles

Recommended Citation

Arden RL, Griggs ZH, and Wey EA. Asymptomatic Septal Mass JAMA Otolaryngol Head Neck Surg 2018 Feb 1;144(2):169-170.

This Article is brought to you for free and open access by the Otolaryngology - Head and Neck Surgery at Henry Ford Health System Scholarly Commons. It has been accepted for inclusion in Otolaryngology Articles by an authorized administrator of Henry Ford Health System Scholarly Commons.

Asymptomatic Septal Mass

Richard L. Arden, MD; Zachary H. Griggs, DO; Elizabeth A. Wey, MD

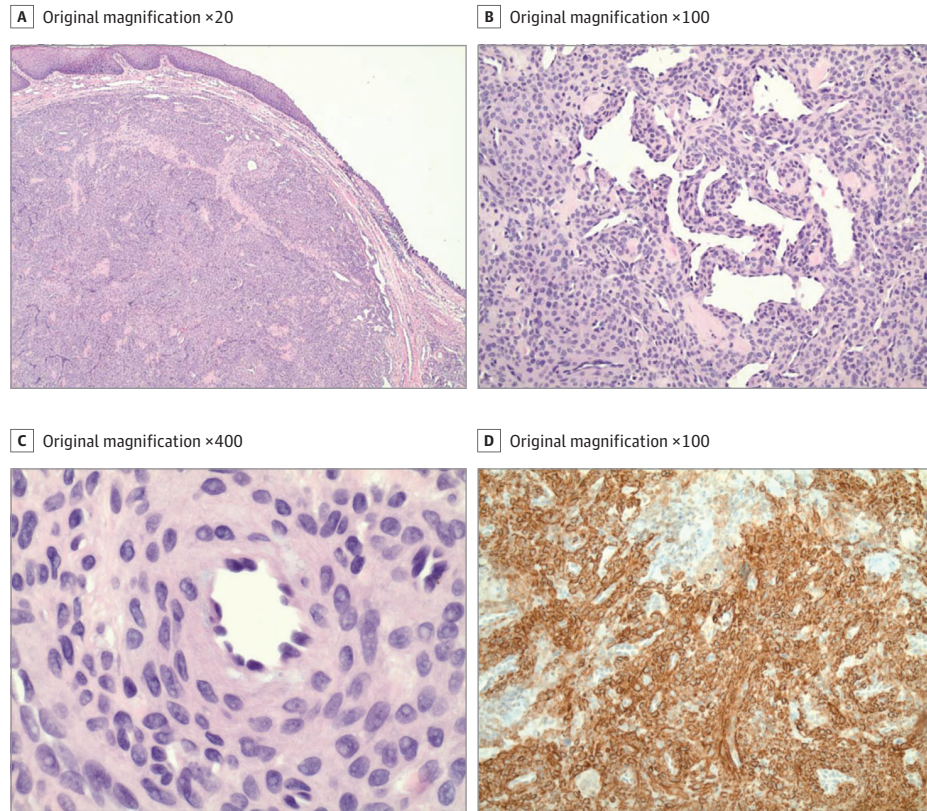


Figure. Histopathology of asymptomatic septal mass shows (A) a well-circumscribed, unencapsulated lesion based in the submucosa with an intact overlying squamous and respiratory mucosa (hematoxylin-eosin); (B) bland, vaguely spindled cells arranged around prominent thin-walled vessels with a "staghorn" branching configuration (hematoxylin-eosin); (C) the lesional cells are oval to spindle shaped with abundant cytoplasm and ill-defined cell borders (hematoxylin-eosin); (D) the lesional cells are stained diffusely with myoid markers, including smooth muscle actin and muscle-specific actin (muscle-specific actin stain).

A woman in her 40s presented with a 2-month history of a slowly enlarging, asymptomatic anterior septal mass. She denied a history of localized trauma, substance abuse, or prior endonasal surgery. Examination revealed a nontender, 8-mm, pink-red, soft, fleshy growth just posterior to the membranous septum near the nostril apex. Histopathological analysis demonstrated a well-circumscribed submucosal lesion comprised of bland, round, syncytial cells, arranged in a concentric fashion around variably sized slit-like vascular spaces, a minority of which were staghorn in appearance (Figure, A-C). No significant perivascular hyalinization was identified. The overlying nasal mucosa and surrounding submucosal glands were unremarkable. Immunohistochemical stains demonstrate the cellular population to be strongly positive for smooth-muscle actin (SMA), muscle-specific actin, and CD34 (Figure, D), but negative for B-catenin and epithelial membrane antigen.

WHAT IS YOUR DIAGNOSIS?

- A. Glomus tumor
- B. Myofibroma
- C. Solitary fibrous tumor
- D. Myopericytoma

Diagnosis

D. Myopericytoma

Discussion

The new World Health Organization (WHO) classification of soft tissue tumors (previously reported in 2002) was updated in 2013 and

now acknowledges that myofibroma and/or myofibromatosis represents morphological points along the spectrum of myopericytic neoplasms.¹ Myopericytoma (MPC) is a mesenchymal tumor derived from the perivascular myoid cell, sharing features with smooth-muscle and glomus cells.² Previously encompassed under the broad category of hemangiopericytomas, these perivascular myomas can

be categorized based on the predominant histologic pattern: myofibromatosis, glomangiopericytoma, and myopericytoma.³ Ultimately, diagnosis is based on these characteristic morphological features and supportive immunohistochemistry, recognizing that some overlap exists with the exception of glomangiopericytoma, which is histologically distinct and occurs in the sinonasal region.

Myopericytoma occurs mainly in childhood to mid-adult years with a male predominance and predilection for dermal and subcutaneous locations in the lower extremities. Of the roughly 15.0% that occur in the head and neck, only 2.5% are represented in the nose and paranasal sinuses, accounting for less than 1.0% of sinonasal tumors overall.⁴ This typically benign, slowly growing neoplasm, often presents as a solitary painless mass that can cause epistaxis and nasal obstruction. On examination, the lesion appears nodular to polypoid, soft and fleshy, friable, circumscribed, possesses a gray-pink to beefy red color, and can be mistaken for an inflammatory polyp.

Myopericytoma are well circumscribed (usually <2 cm) but unencapsulated neoplasms with bland and relatively monomorphic oval to spindle-shaped cells that are arranged in a concentric or whorling perivascular pattern. They differ from glomus cells by their larger size, more abundant cytoplasm, and lack of a clearly demarcated cell border.² Immunostaining is characteristically strong for vimentin and SMA expression but limited to small vessels for CD34.^{3,5} Pericytes are SMA positive. Staining is characteristically negative for EMA, cytokeratins, and usually desmin. By contrast, the rare sinonasal solitary fibrous tumor exhibits a patternless proliferation of spindle cells admixed with variable amounts of rosy keloidal collagen, increased perivascular and stromal collagen, haphazardly arranged cells, and thin-walled vascular spaces. Strong diffuse immunoreactivity for CD34 and CD99 is seen, with variably positive to absent SMA expression.^{3,4,6} Unlike MPC, perivascular concentric growth with accentuated perivenule myoid proliferation is not a prominent feature of myofibroma. Diagnosis of myofibroma is typically based on a characteristic biphasic zonal architecture with pericytoid and myoid features, whose whorled multiple nodules may

display prominent stromal hyalinization. Similar to MPC, glomus tumor (GT) is a pericytic neoplasm with immunoreactivity for smooth muscle and muscle-specific actin, as well as usual negativity for CD34. However, these are very rare in the sinonasal region, and classic GT is morphologically composed of compact, uniform, polyhedral, epithelioid cells organized in sheets, nests, or cords, and usually do not possess staghorn-like vessel proliferation.⁷ Admittedly, it is recognized that GT, particularly variants of GT (eg, glomangiomyoma), may overlap with MPC and that clear distinction may not always be possible. In the past, most myopericytic neoplasms lacked well-defined genetic abnormalities, impeding their objective classification; however, recent studies have identified recurrent gene abnormalities, including *SRF-RELA* fusions among a subset of cellular variant myofibromas and myopericytomas⁸ and fusions involving members of the NOTCH family among GTs.⁹ These and future genetic discoveries will hopefully clarify the relationship among the different myopericytic tumors and improve upon the current morphologic classification.

Standard treatment for MPC is complete local resection, which prognostically has proven more important than tumor size or location. Despite this, local recurrence rates have been reported at 10% to 20%^{4,7} and likely related to incomplete excision and deep soft tissue lesions. While the vast majority of these neoplasms are benign with excellent prognosis, cases of malignant MPC have been reported.¹⁰ Markers for poor prognosis and increased recurrence rates (local and metastatic) include prominent mitotic activity (>4 of 10 per high-powered field), Ki-67 proliferation index greater than 10%, focal necrosis, cellular atypia, and tumor size larger than 5 cm, similar to features for malignancy in solitary fibrous tumor. Metastatic disease (typically disseminated hematogenously to lung, liver, and bone) and disease-related mortality is extremely rare. Attributable to the generally radioresistant nature of MPC, palliative radiation therapy has been reserved for unresectable and recurrent tumor. Chemotherapy has demonstrated limited efficacy and considered for inoperable tumors or metastases.

ARTICLE INFORMATION

Author Affiliations: William Beaumont Hospital, Troy, Michigan (Arden, Wey); Otolaryngology–Head and Neck Surgery, Henry Ford Health System, Charter Township of Clinton, Michigan (Griggs).

Corresponding Author: Zachary H. Griggs, DO, Otolaryngology–Head and Neck Surgery, Henry Ford Health System, 15855 19 Mile Rd, Charter Township of Clinton, MI 48038 (zack.griggs1@gmail.com).

Section Editor: Edward B. Stelow, MD.

Published Online: November 30, 2017.
doi:10.1001/jamaoto.2017.2431

Correction: This article was corrected on February 15, 2018, to add a missing acknowledgment.

Conflict of Interest Disclosures: All authors have completed and submitted the ICMJE Form for Disclosure of Potential Conflicts of Interest and none were reported.

Additional Contributions: We would like to thank Jonathan B. McHugh, MD, (Department of Pathology, University of Michigan Health System) for providing outside consultation on this case. He was not compensated for his contributions.

REFERENCES

1. Jo VY, Fletcher CDM. WHO classification of soft tissue tumours: an update based on the 2013 (4th) edition. *Pathology*. 2014;46(2):95-104.
2. Dray MS, McCarthy SW, Palmer AA, et al. Myopericytoma: a unifying term for a spectrum of tumours that show overlapping features with myofibroma: a review of 14 cases. *J Clin Pathol*. 2006;59(1):67-73.
3. Granter SR, Badizadegan K, Fletcher CD. Myofibromatosis in adults, glomangiopericytoma, and myopericytoma: a spectrum of tumors showing perivascular myoid differentiation. *Am J Surg Pathol*. 1998;22(5):513-525.
4. Duval M, Hwang E, Kilty SJ. Systematic review of treatment and prognosis of sinonasal hemangiopericytoma. *Head Neck*. 2013;35(8):1205-1210.
5. Mentzel T, Dei Tos AP, Sapi Z, Kutzner H. Myopericytoma of skin and soft tissues: clinicopathologic and immunohistochemical study of 54 cases. *Am J Surg Pathol*. 2006;30(1):104-113.
6. Thompson LDR, Miettinen M, Wenig BM. Sinonasal-type hemangiopericytoma: a clinicopathologic and immunophenotypic analysis of 104 cases showing perivascular myoid differentiation. *Am J Surg Pathol*. 2003;27(6):737-749.
7. Brandwein-Gensler M, Siegal GP. Striking pathology gold: a singular experience with daily reverberations: sinonasal hemangiopericytoma (glomangiopericytoma) and oncogenic osteomalacia. *Head Neck Pathol*. 2012;6(1):64-74.
8. Antonescu CR, Sung Y-S, Zhang L, Agaram NP, Fletcher CD. Recurrent *SRF-RELA* fusions define a novel subset of cellular myofibroma/myopericytoma: a potential diagnostic pitfall with sarcomas with myogenic differentiation. *Am J Surg Pathol*. 2017;41(5):677-684.
9. Mosquera J-M, Sboner A, Zhang L, et al. Novel *MIR143-NOTCH* fusions in benign and malignant glomus tumors. *Genes Chromosomes Cancer*. 2013;52(11):1075-1087.
10. McMenamin ME, Fletcher CDM. Malignant myopericytoma: expanding the spectrum of tumours with myopericytic differentiation. *Histopathology*. 2002;41(5):450-460.