

DISSERTATION ON

MOLECULAR STUDIES AND CLINICAL EVALUATION
OF PRIMARY CONGENITAL GLAUCOMA

Submitted in partial fulfillment of requirements of

M. S. OPHTHALMOLOGY

BRANCH – III

REGIONAL INSTITUTE OF OPHTHALMOLOGY

MADRAS MEDICAL COLLEGE

CHENNAI – 600 003



THE TAMILNADU DR. M. G. R. MEDICAL UNIVERSITY

CHENNAI

APRIL 2016

CERTIFICATE

This is to certify that this dissertation titled “**MOLECULAR STUDIES AND CLINICAL EVALUATION OF PRIMARY CONGENITAL GLAUCOMA**” is a bona fide record of the research work done by **Dr.RAJAKUMARI. M**, Post graduate in the Regional Institute of Ophthalmology & Government Ophthalmic Hospital, Madras Medical College and Government General Hospital, Chennai-03, in partial fulfillment of the regulations laid down by the Tamil Nadu Dr. M. G. R Medical University for the award of M.S. Ophthalmology, Branch III, under my guidance and supervision during the academic year 2013 – 2016.

Prof. Dr. P. S. MAHESWARI, M.S., D.O.,
CHIEF, GLAUCOMA SERVICES,
Regional Institute of Ophthalmology &
Government Ophthalmic Hospital,
Madras Medical College,
Chennai-600 008.

Prof. Dr. K. NAMITHA
BHUVANESWARI, M.S., D.O.,
DIRECTOR AND SUPERINTENDENT,
Regional Institute of Ophthalmology &
Government Ophthalmic Hospital,
Madras Medical College,
Chennai-600 008.

Prof. Dr. R. VIMALA, M.D.,
DEAN,
Madras Medical College &
Government General Hospital,
Chennai-600 003.

DECLARATION BY THE CANDIDATE

I hereby declare that this dissertation entitled “**MOLECULAR STUDIES AND CLINICAL EVALUATION OF PRIMARY CONGENITAL GLAUCOMA**”, is a bona fide and genuine research work carried out by me under the guidance of **Prof. Dr. P. S. MAHESWARI, M.S., D.O.**

DATE:

Dr. RAJAKUMARI. M

PLACE:

ACKNOWLEDGEMENTS

Prima facie, I am grateful to God for the good health and wellbeing that were necessary to complete this book.

I express my sincere thanks and gratitude to **Prof. Dr. R. Vimala, M.D.**, DEAN, Madras Medical College, for permitting me to conduct this study.

I have great pleasure in thanking **Prof. Dr. K. Namitha Bhuvanewari, M.S., D.O.**, Director & Superintendent, and Head of the Department of Cornea services, Regional Institute of Ophthalmology and Government Ophthalmic Hospital, Madras Medical College, for her valuable advice in preparing this dissertation.

I express my profound gratitude to **Prof. Dr. P. S. Maheswari, M.S., D.O.**, chief of my unit, and my guide for her valuable guidance and constant support at every stage throughout the period of this study.

I am very grateful to my co-guide **Dr. Ashok Kumar**, assistant professor in my unit, for rendering his valuable advice and guidance for the study.

I would like to express the deepest appreciation and gratitude to **Dr. Prince R. Prabhu, B. Pharm., M.B.A., M.Tech., Ph.D.**, my co-guide and Teaching/Research Faculty, Centre for Biotechnology, Anna University, Chennai, **Dr. Satya Narayan Pradhan**, Teaching/Research Faculty, Anna University, and **Mr. Richard Jason** and **Mr. Antony**, for their work on genetic analysis of samples.

I extend my sincere thanks to **Dr. Gautam, Ph.D.**, Head of the Department, Department of Biotechnology, Anna University, Chennai, for giving permission to use the research lab for the purpose of my study.

I am extremely thankful to **Prof. Dr. Waheedha Nazir**, former chief, Glaucoma services, Regional Institute of Ophthalmology and Government Ophthalmic Hospital, Madras Medical College, my unit assistant professors, **Dr. N. Sharmila** and **Dr. B. Kalaiselvi** for guiding me in my initial stages at this institute and instilling an interest in the field of Ophthalmology. I am very grateful to **Dr. R. Saravanan, Dr. B. Meenakshi, Dr. M.S.Gokila, Dr. V. Sharmila Devi** and **Dr. T. Vimala** for their valuable suggestions and guidance during the course of this study.

I express my heartfelt thanks to my husband **Mr. Ajanth Naveen** for his constant support, without which this study would not have been possible. I am indebted to **Dr. Nithya Selvaraja** for her cheering support throughout the study.

I wish to express my sincere thanks to all my colleagues who had helped me in bringing out this study.

I am indebted to all the patients for their sincere cooperation for the completion of this study.

INSTITUTIONAL ETHICS COMMITTEE
MADRAS MEDICAL COLLEGE, CHENNAI-3

EC Reg No.ECR/270/Inst./TN/2013
Telephone No. 044 25305301
Fax : 044 25363970

CERTIFICATE OF APPROVAL

To
Dr.M.Rajakumari
Postgraduate M.S.(Ophthalmology)
Madras Medical College
Chennai 600 003

Dear Dr.M.Rajakumari,


The Institutional Ethics Committee has considered your request and approved your study titled "**Mutation of CYP1B1 in Primary Congenital Glaucoma patients in South India**" No.11062015.

The following members of Ethics Committee were present in the meeting held on 09.06.2015 conducted at Madras Medical College, Chennai-3.

- | | |
|--|----------------------|
| 1. Prof.C.Rajendran, M.D., | : Chairperson |
| 2. Prof.R.Vimala, M.D., Dean, MMC, Ch-3 | : Deputy Chairperson |
| 3. Prof.B.Kalaiselvi, M.D., Vice-Principal, MMC, Ch-3 | : Member Secretary |
| 4. Prof.B.Vasanthi, M.D., Prof. of Pharmacology, MMC | : Member |
| 5. Prof.P.Raghumani, M.S., Professor of Surgery, MMC | : Member |
| 6. Prof.Md.Ali, M.D., DM., Prof. & HOD of MGE, MMC | : Member |
| 7. Prof.Baby Vasumathi, Director, Inst.of O&G, Ch-8 | : Member |
| 8. Prof.Ramadevi, Director, Inst.of Bio-chemistry, MMC | : Member |
| 9. Prof.Saraswathy, M.D., Director, Pathology, MMC, Ch-3 | : Member |
| 10.Prof.K.Srinivasagalu, M.D.,Director, I.I.M. MMC, Ch-3 | : Member |
| 11.Thiru S.Rameshkumar, B.Com., MBA | : Lay Person |
| 12.Thiru S.Govindasamy, B.A., B.L., | : Lawyer |
| 13.Tmt.Arnold Saulina, M.A., MSW., | : Social Scientist |

We approve the proposal to be conducted in its presented form.

The Institutional Ethics Committee expects to be informed about the progress of the study and SAE occurring in the course of the study, any changes in the protocol and patients information/informed consent and asks to be provided a copy of the final report.


Member Secretary, Ethics Committee
INSTITUTIONAL ETHICS COMMITTEE
MADRAS MEDICAL COLLEGE
CHENNAI-600 003



Digital Receipt

This receipt acknowledges that Turnitin received your paper. Below you will find the receipt information regarding your submission.

The first page of your submissions is displayed below.

Submission author: 221313008.ophtalmology Rajakum..
Assignment title: TNMGRMU EXAMINATIONS
Submission title: Molecular Studies and Clinical Eval..
File name: raj_plag_sub.docx
File size: 1.76M
Page count: 76
Word count: 10,184
Character count: 58,565
Submission date: 27-Sep-2015 07:42AM
Submission ID: 572207656

MOLECULAR STUDIES AND CLINICAL EVALUATION OF CONJUGATED GLAUCOMA

INDEX

Abstract 1
Introduction 2
Materials and Methods 3
Results 4
Discussion 5
Conclusion 6

Abstract 1
Introduction 2
Materials and Methods 3
Results 4
Discussion 5
Conclusion 6

Abstract 1
Introduction 2
Materials and Methods 3
Results 4
Discussion 5
Conclusion 6

Abstract 1
Introduction 2
Materials and Methods 3
Results 4
Discussion 5
Conclusion 6

Match Overview

MOLECULAR STUDIES AND CLINICAL EVALUATION OF CONGENITAL GLAUCOMA

INTRODUCTION

Glaucoma is defined as a disturbance to the structural or functional integrity of the optic nerve which can be arrested or diminished by adequately lowering IOP¹. It can also be described as chronic progressive optic neuropathy with characteristic optic nerve head changes and corresponding field defects, with the only modifiable risk factor being elevated IOP². In Greek, the word Glaucoma means 'clouded'.

Glaucomatous atrophy is characterized by progressive death of retinal ganglion cells which appears as excavation of the cup and is functionally apparent as sequential visual field deterioration in specific patterns.

Primary Glaucomas are generally not associated with known ocular or systemic disorders leading to increased resistance to aqueous outflow; usually, they are bilateral and reflect genetic

1	www.ncbi.nlm.nih.gov Internet source	4%
2	R STAMPER, "Develop..." Publication	3%
3	www.movis.org Internet source	2%
4	deLuise, V.P., "Primary ..." Publication	2%
5	shpomeru Internet source	1%
6	Shields, M., "Aventfeld-..." Publication	1%
7	Zimmerman, Thom J., ... Publication	1%
8	AFadhli, S., "Molecular ..." Publication	1%

CONTENTS

PART – I

S. No.	Content	Page No.
1	Introduction	1
2	Historical Review	3
3	Terminology	5
4	Classification	7
5	Epidemiology of Primary Congenital Glaucoma	15
6	Genetics	16
7	Anatomy of Normal Angle	19
8	Embryogenesis	20
9	Theories of Abnormal Development in PCG	23
10	Evaluation of PCG	27
11	Differential Diagnosis of PCG	33
12	Management	35
13	Review of Literature	48

PART – II

S. No.	Content	Page No.
1	Aims and Objectives of the Study	51
2	Materials and Methods of Genetic Analysis	53
3	Results and Analysis of Clinical Evaluation	56
4	Results of Genetic Analysis	65
5	Discussion	72
6	Conclusion	75

PART – II

S. No.	Content	Page No.
1	Bibliography	78
2	Proforma	82
3	Master Chart	84
4	Key to Master Chart	86
5	Abbreviation	87

PART I

MOLECULAR STUDIES AND CLINICAL EVALUATION OF CONGENITAL GLAUCOMA

INTRODUCTION

Glaucoma is defined as a disturbance to the structural or functional integrity of the optic nerve which can be arrested or diminished by adequately lowering IOP¹. It can also be described as chronic progressive optic neuropathy with characteristic optic nerve head changes and corresponding field defects, with the only modifiable risk factor being elevated IOP². In Greek, the word Glaucoma means 'clouded'.

Glaucomatous atrophy is characterized by progressive death of retinal ganglion cells which appears as excavation of the cup and is functionally apparent as sequential visual field deterioration in specific patterns.

Primary Glaucomas are generally not associated with known ocular or systemic disorders leading to increased resistance to aqueous outflow; usually, they are bilateral and reflect genetic predispositions. However, Secondary Glaucomas are associated with ocular or systemic abnormalities responsible for elevated IOP; these are usually unilateral and acquired diseases.

Congenital Glaucoma

According to Sir Stewart Duke-Elder (1963): "Buphthalmos (hydrophthalmos) is the condition wherein developmental abnormalities offer an obstruction to the drainage of the intra-ocular fluids so that the pressure of the eye is raised and a condition of Congenital Glaucoma results. The essential clinical feature of the anomaly is that the coats of the eye are of sufficient

plasticity to stretch under this increment of pressure with the results that the whole globe enlarges, producing an appearance which is said to resemble the eye of an ox”³.

Shaffer and Weiss (1970) describes Primary Congenital Glaucoma as, “The most common hereditary Glaucoma of childhood, inherited as an autosomal recessive pattern, with a specific angle anomaly consisting of absence of angle recess with iris insertion directly into the trabecular surface. There are no other major abnormalities of development. Corneal enlargement, clouding, and tears in Descemet’s Membrane result from elevated intraocular pressure.”⁴

Loss of retinal ganglion cells leading to irreversible blindness is caused by increased IOP, which is bilateral in 80% of cases. Over 80% of cases are diagnosed by the first year of life. Of this, the disease is diagnosed in 25% of the cases in the neonatal period, and in 60% of cases by the first six months. Primary Congenital Glaucoma is the most common type, and it accounts for 55% of primary pediatric glaucoma.

HISTORICAL REVIEW

460–377 BC: Congenital enlargement of the eye was identified by Hippocrates, later by Celsus and Galen. The relationship between glaucoma and IOP was not known.

1744: Increased IOP associated with Congenital Glaucoma was described by Berger

1869: Buphthalmos which was classical within in a family was described by Von Muralt. However, it was believed to be caused by a primary intraocular inflammation according to both Von Muralt and Von Graefe.

Precise anatomical dissections were performed and the etiopathology was found to be related to various malformations of the structures of the angle of the anterior chamber (AC) only in the late **1800s**. Similar studies were done by von Hippel, Parsons, Siegrist, Reis and many others.

Congenital Glaucomas were considered not treatable in the early **1900s**. Anderson said, “the future of patients with Hydrophthalmia is dark” and “one seeks in vain for a best operation in the treatment of Hydrophthalmia”.⁵ Infantile Glaucoma had poor prognosis until Otto Barkan introduced Goniotomy⁶. He created an internal cleft in the trabecular tissue and incised it with a knife under visualization through a specialized glass contact lens. The operation remains unchanged, except for instrumental and microscopic development.

Barkan (**1949**) described a fetal membrane persisting over the trabecular tissue. Worst (**1966**) confirmed this and named it Barkan’s Membrane. However the presence of such a glassy membrane was not evident by electron microscopic study.

Goniotomy remained the standard for Congenital Glaucoma until **1960**, when Burian and Smith, on different occasions, described a new technique called “trabeculectomy ab externo”. Burian performed the first external trabeculectomy without the aid of an operating microscope, in **March 1960**⁷. Redmond Smith described a new procedure called “nylon filament trabeculotomy”. Later, Harms (**1969**), Dannheim (**1971**) and McPherson (**1973**) modified the surgical technique of trabeculotomy ab externo.

TERMINOLOGY

General Description

1. Buphthalmos literally means Ox eye. It is described as any type of marked enlargement occurring as a result of Glaucoma since birth.
2. Hydrophthalmos means increased fluid content which is present in a prominently enlarged eye due to Glaucoma in infancy⁸. Buphthalmos and Hydrophthalmia are outdated terms.

Terms describing developmental pattern:

Developmental Glaucoma: it is a condition that is related to anomalous development of the eye at birth, which includes primary congenital glaucoma and Secondary Glaucomas associated with ocular or systemic developmental anomalies. The terms Congenital Glaucoma and Developmental Glaucoma are synonymous.

Primary Developmental Glaucoma: caused by the maldevelopment of the aqueous outflow system. Primary Congenital Glaucoma is a specific term which refers to eyes with an isolated maldevelopment of the trabecular meshwork, and where other developmental ocular anomalies or diseases that can raise intraocular pressure are absent.

Secondary developmental glaucoma: Secondary Glaucoma in infants refers to Glaucoma due to acquired ocular diseases. It is caused by impedance in the aqueous outflow system due to defective development of any other part of the eye, such as, ectopia lentis, microspherophakia, pupillary block in a small eye, or as an anterior displacement of the lens-iris diaphragm in any other developmental posterior segment pathology.

Terms describing structural anomalies

1. Goniodysgenesis, maldevelopment of irido-corneal angle
2. Trabeculodysgenesis, maldevelopment of trabecular meshwork
3. Irido-dysgenesis, maldevelopment of iris, and
4. Corneodysgenesis: maldevelopment of cornea.

They have varied mode of presentation. It could be present either as a single entity or in combination with other conditions. Trabeculodysgenesis alone is a pathognomonic feature of primary developmental glaucoma.

Relating to age of onset

Infantile Glaucoma is a term used in different contexts. Some use it to indicate Primary Congenital Glaucoma, while some use it to indicate any glaucoma occurring in the early years of life. Hence, its context should be specified or it should be avoided. Primary Infantile Glaucoma and Primary Congenital Glaucoma are synonymous.

Juvenile Glaucoma is a non-specific term that refers to any type of Glaucoma occurring after the age of 5 and up to the third and fourth decades. Juvenile Glaucoma associated with myopia with autosomal dominant inheritance has been linked to the short arm of the first human chromosome (1q), coding for the myocilin gene (MYOC)¹.

CLASSIFICATION

SYNDROME CLASSIFICATION OF CONGENITAL GLAUCOMA

I. Primary glaucoma

A. Congenital open-angle Glaucoma

B. Juvenile Glaucoma (AD inheritance)

C. Glaucoma presenting with systemic manifestations

1. Axenfeld-Rieger syndrome

2. Chromosomal disorders

3. Congenital rubella

4. Fetal alcohol syndrome

5. Mucopolysaccharidosis

6. Neurofibromatosis

7. Oculocerebrorenal (Lowe) syndrome

8. Hepatocerebrorenal (Zellweger) syndrome

9. Oculodermal vascular malformations

a. Sturge-Weber syndrome

b. Klippel-Trenaunay-Weber syndrome

c. Oculodermal melanocytosis

d. Phakomatosis pigmentovascularis

e. Cutis marmorata telangiectasia congenita

10. Prader-Willi syndrome

11. Rubenstein-Taybi (broad-thumb) syndrome

12. Pierre Robin and Stickler syndromes

13. Skeletal dysplastic syndromes

a. Kniest syndrome

b. Michel syndrome

c. Oculodentodigital syndrome

D. Glaucoma in other ocular pathological conditions

1. Aniridia

2. Axenfeld-Rieger syndrome

3. Congenital ectropion uveae

4. Congenital hereditary endothelial dystrophy

5. Microcornea syndromes

6. Familial iris hypoplasia

7. Peter's syndrome

8. Posterior polymorphous dystrophy

9. Sclerocornea

II. Secondary glaucoma

A. Glaucoma in ocular trauma

B. Glaucoma associated with intraocular malignancies

1. Retinoblastoma

2. Juvenile xanthogranuloma

3. Leukemia

4. Iris rhabdomyosarcoma

C. Glaucoma in Uveitis

D. Lens-induced Glaucoma

1. Subluxation – dislocation with pupillary block

a. Marfan syndrome

b. Homocystinuria

2. Spherophakia with pupillary block

a. Weill-Marchesani syndrome

b. GEMSS syndrome

E. Glaucoma following cataract surgery

1. Chronic open-angle (aphakic or pseudophakic)

2. Lens debris or uveitic blockade of trabeculum

3. Pupillary blockade

F. Glaucoma in Steroid responders

G. Neovascular Glaucoma

1. Retinoblastoma

2. Coats' disease

3. Medulloepithelioma

4. Familial exudative vitreoretinopathy

H. Secondary angle-closure Glaucoma

1. Retinopathy of prematurity

2. Microphthalmos

3. Nanophthalmos

4. Retinoblastoma

5. Persistent hyperplastic primary vitreous

6. Congenital papillary-iris lens membrane

7. Aniridia

8. Iridoschisis

9. Cornea plana

I. Glaucoma associated with episcleral venous hypertension

1. Sturge-Weber syndrome
2. Idiopathic or familial elevated episcleral venous pressure
3. Orbital vascular malformations

J. Glaucoma following infections in eye

1. Acute Toxoplasmosis
2. Acute herpetic iritis
3. AIDS related infections
4. Congenital rubella

DeLuise–Anderson (1983) classification of Congenital and Infantile Glaucoma⁹

1. Primary Infantile Glaucoma (Congenital Glaucoma, trabeculo-dysgenesis)
2. Secondary Infantile Glaucoma

A. Associated with mesodermal neural crest dysgenesis

1. Iridocorneotrabeculodysgenesis
 - a. Axenfeld's anomaly
 - b. Rieger's anomaly
 - c. Peter's anomaly
 - d. Systemic hypoplastic mesodermal dysgenesis (Marfan's syndrome)

e. Systemic hyperplastic mesodermal dysgenesis (Weill –
Marchesani syndrome)

2. Iridotrabeculodysgenesis (aniridia)

B. Associated with phakomatoses and hamartomas

1. Neurofibromatosis (Von Recklinghausen's disease)

2. Encephalotrigeminal angiomatosis (Sturge–Weber syndrome)

3. Angiomas of retina (von Hippel-Lindau syndrome)

4. Oculodermal melanocytosis (Nevus of Ota)

C. Associated with metabolic disease

1. Oculocerebrorenal syndrome (Lowe's syndrome)

2. Homocystinuria

D. Associated with inflammatory disease

1. Maternal rubella syndrome (congenital rubella)

2. Herpes simplex iridocyclitis

E. Associated with mitotic disease

1. Juvenile xanthogranuloma (nevus xanthoendothelioma)

2. Retinoblastoma

F. Associated with other congenital disease

1. Trisomy 13-15 syndrome (Patau's syndrome)
2. Rubinstein–Taybi syndrome
3. Persistent hyperplastic primary vitreous

Hoskins–Shaffer–Hetherington (1984) clinical anatomic classification of the Developmental Glaucomas¹⁰.

I. Isolated trabeculodysgenesis (malformation of trabecular meshwork in the absence of iris or corneal anomalies)

A. Flat iris insertion

1. Anterior insertion
2. Posterior insertion
3. Mixed insertion

B. Concave (wrap-around) iris insertion

C. Unclassified

II. Iridotrabeculodysgenesis (trabeculodysgenesis with iris anomalies)

A. Anterior stromal defects

1. Hypoplasia
2. Hyperplasia

B. Anomalous iris vessels

1. Persistence of tunica vasculosa lentis

2. Anomalous superficial vessels

- C. Structural anomalies

1. Holes

2. Colobomata

3. Aniridia

- III. Corneoidotrabeculodysgenesis (malformation of trabecular meshwork with iris and corneal anomalies)

- A. Peripheral

- B. Midperipheral

- C. Central

- D. Corneal size

Anomalies of the anterior segment may comprise the trabecular meshwork singly or it can be associated with defective development of the iris and cornea.

Isolated trabeculodysgenesis is the only developmental ocular anomaly found in nearly half of infantile and juvenile Glaucoma. It is the characteristic defect in Primary Congenital Glaucoma.

EPIDEMIOLOGY OF PRIMARY CONGENITAL GLAUCOMA

Primary Congenital Glaucoma (PCG) is a rare disorder of the eye accounting for 0.01–0.04% of total blindness. It generally manifests at birth or before the age of 3. The degree of occurrence differs with different populations. In developed western countries, the occurrence is reported to be about 1 out of 10,000 births¹¹. The PCG is more prevalent in the presence of “founder effect” or a higher incidence of consanguinity in the community. The “founder effect” is described as a genetic mutation noticed prominently in a particular community due to the mutation seen in the gene of a single progeny or small group of progeny.

The occurrence of PCG is reported to be 1 in 1250 among the Gypsies of the Slovakia¹². While in the Middle Eastern countries, the incidence was found to be 1 in 2500¹³. In a retrospective study conducted at the Glaucoma unit at King Abdulaziz University Hospital (KAUH, Riyadh, Saudi Arabia) covering the period from 2006 to 2010, where approximately 600 new Glaucoma patients are seen annually, Pediatric Glaucoma accounts for about 3% of which 2.7% are PCG¹⁴. In Andhra Pradesh, India, the incidence of PCG is 1 in 3300, accounting for 4.2% of all childhood blindness¹⁵. About 60% of the patients manifested the disease in the first 6 months of life while 80% were recognized to have the disease by first year of life. Males account for about 65%⁸.

Inheritance of PCG is usually sporadic in nature. In familial cases of Primary Congenital Glaucoma autosomal recessive pattern prevails, the penetrance of which can be incomplete or variable. The inheritance can also be multifactorial. Few cases of autosomal dominant and occasionally pseudo-dominant pattern of inheritance has also been identified. 10–40% of cases reported with the disease is familial with variable penetrance (40–100%)¹¹.

GENETICS

GLC3 has been designated by HUGO as the label for the gene(s) causing PCG. The chromosomal loci linked to PCG are GLC3A (2p21), GLC3B (1p36), GLC3C (14q24.3).

GLC3A loci which harbors the human cytochrome P450 gene *CYP1B1* (OMIM 601771), has been characterized¹⁶. More than 40 different mutations have been identified in *CYP1B1* to be causative of PCG in various ethnic backgrounds thus highlighting the allelic heterogeneity of the condition.

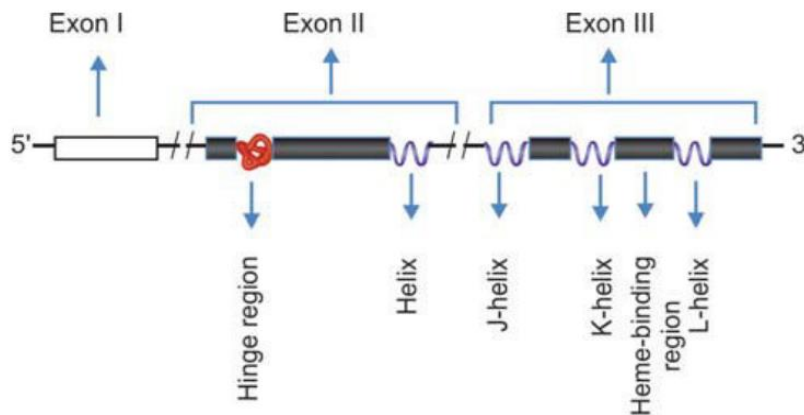
The autosomal recessive inheritance pattern of PCG is well documented showing more prevalence in boys than in girls. Cases of incomplete penetrance have also been reported. Sarfarazi and associates 1995 mapped the locus GLC3A (MIM 231300) for PCG to the short arm of chromosome 2p22 to 21. However, some other PCG families in the same study failed to show linkage to the 2p22 to 21 region, implying locus heterogeneity for this condition. An additional PCG locus, GLC3B¹⁷, has been localized to chromosome 1p36.2-p36.1 in some families not showing linkage to the chromosome 2 markers. Confirmation of linkage between *CYP1B1* and PCG in different populations have verified the GLC3A locus (*CYP1B1*) as a major cause of PCG accounting for 85%–90% of all familial cases and 27% of sporadic cases¹⁸.

Cytochrome p450 1B1 (CYP1B1)

The Cytochrome p450 1B1 (*CYP1B1*) gene is located on chromosome 2 at position 2p21-22. It contains two introns and three exons and the open reading frame starts with exon II and ends within exon III. The protein product of this gene metabolizes a variety of xenobiotics and endogenous intermediary substrates. It is expressed in the ciliary body, nonpigmented ciliary epithelium, iris and TM. *CYP1B1* is also involved in signaling pathways thereby regulating expression of many genes involved in growth, development and differentiation of various ocular

structures particularly those of the anterior chamber. Pathogenic mutations in CYP1B1 occur in PCG in varying frequencies; some are highly prevalent and others appear with different frequencies across population, mutations in CYP1B1 gene are the most common cause of PCG.

(Fig. 1) Schematic representation of CYP 1B1 gene



MYOCILIN

MYOC (chromosome 1 at 1q25) codes for myocilin/TIGR (trabecular meshwork-induced glucocorticoid response) protein. MYOC gene consists of two introns and three exons. Most tissues of the eye (trabecular meshwork, sclera, ciliary bodies, retina, etc.) express this protein. MYOC has been located in extracellular matrix of normal as well as glaucomatous trabecular meshwork. It codes for a sticky stress protein, which covers TM. Mutations in MYOC gene occur in a many types of eye disorders accounting for 2 to 5% cases of POAG and 5.5% of PCG cases.

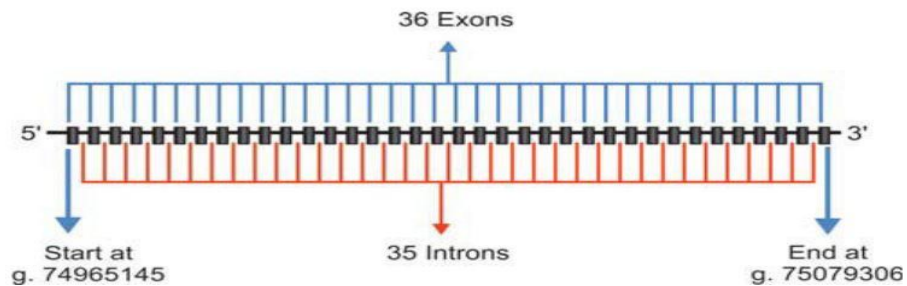
FOXC1

Another gene that is thought to play a role in the pathogenesis of PCG is Forkhead-related transcription factor C1 (FOXC1 or FKHL7). It is located on p-arm of chromosome 6 (6p25).

LTBP2

Recently linkage analysis of PCG in consanguineous Pakistani PCG families was reported with involvement of a new chromosomal locus adjacent to GLC3C on 14q24.2-24.3. The candidate gene identified was latent transforming growth factor-b-binding protein 2 (LTBP2). Truncating mutations were identified in this gene in PCG patients. The expression pattern of LTBP2 in the trabecular meshwork, ciliary body and ciliary process has increased the complexity of the pathophysiological mechanism involved in PCG.

(Fig 2) Schematic diagram of the LTBP2 gene



ANATOMY OF NORMAL ANGLE

NORMAL ANGLE CONFIGURATION AT BIRTH

Gonioscopy done in a neonate's eye shows the iris to be inserted into the angle wall behind the scleral spur with the visualization of the ciliary body band in front of the insertion of iris. Flat insertion of iris can be noted as the angle recess has not deepened.

In the first 6 to 12 months of life, posterior sliding of the uveal tissue takes place as a continuous process, and can be seen as formation of angle recess gonioscopically⁸.

Hence, adult angle configuration where the iris turns slightly posteriorly before inserting into the ciliary body is not usually found at the time of birth, and is reported to develop only in the first year of life.

Deep angle recess with visualization of the ciliary body band is a striking feature of the neonates eye which is not a feature of eyes with trabeculodysgenesis.

EMBRYOGENESIS

The mesenchymal cells of neural crest cell origin gives rise to structures in the angle of the anterior chamber that are related to the aqueous drainage. The anterior chamber angle is occupied by loosely arranged mesenchymal cells and is undifferentiated until 8th month of intra uterine life, and the anterior chamber appears to be a slit-like opening.

Some hypotheses proposed to explain the formation of anterior chamber angle are:

1. *Atrophy* or progressive resorption of a part of fetal tissue
2. *Cleavage* or separation of two pre-existing layers of tissue due to differential growth rate, and
3. *Rarefaction*: mechanical distention resulting from the growth of anterior ocular segment.

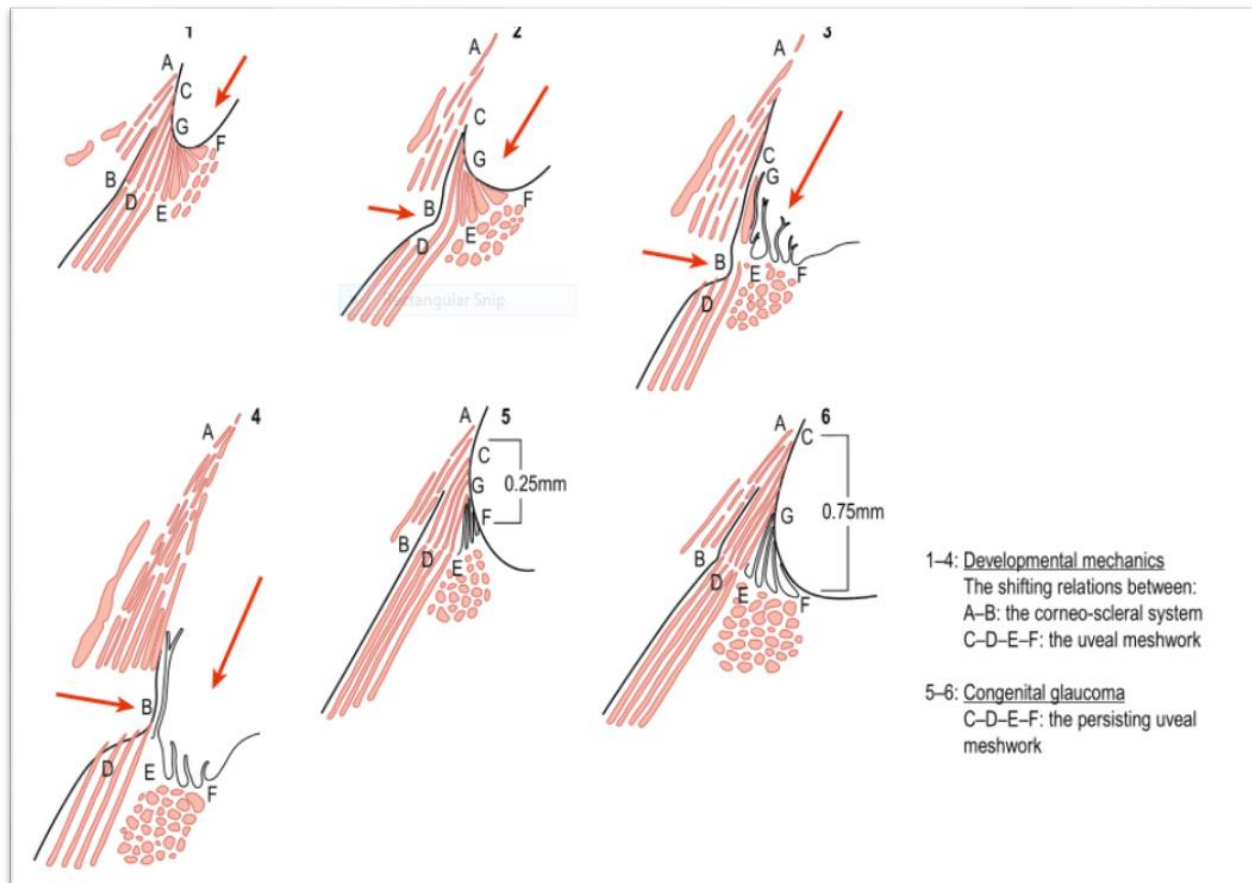
According to the various studies that have been conducted to analyse the development of the angle structures, none of the above concepts are completely correct.

Anderson did extensive light and electron microscopic studies of 40 normal fetal and infant eyes and found that the anterior surface of the iris inserts at the edge of the corneal endothelium at 5 months of intra uterine life, covering the cells that eventually become the trabecular meshwork¹⁹.

Worst coined the term “fetal pectinate ligament” which delineates the corneoscleral meshwork primordium from the anterior chamber angle²⁰. Just cleavage or atrophy does not include the developmental process. If so, the uveal tract would just split away from the corneoscleral shell and trabecular tissue.

Trabecular meshwork gains exposure to the anterior chamber with the deepening and posterior movement of the angle recess. In progressively older tissue specimens, Anderson found a posterior repositioning of the anterior uveal structures which might be because of the differential growth rate. Hansson and Jerndal²¹ used scanning electron microscopy to study human fetal eyes and reported that at the beginning of the 5th fetal month, a single layer of endothelium, continuous with that of the cornea forms, extending over the angle of primitive anterior chamber and iridopupillary structures, forming a closed cavity. They also noted that, by the 7th fetal month, the endothelial layer of the anterior chamber angle begins to flatten, with indistinct margins. The endothelial layer becomes fenestrated and these cells start migrating into the underlying uveal meshwork by the final weeks of gestation and in the initial few weeks after birth.

Shields' theory of development of Anterior Chamber Angle: Shields observed the anterior chamber angle development and found that during gestation, at 5 months, a continuous layer of endothelium creates a closed cavity, and the anterior surface of the iris inserts in front of the primordial trabecular meshwork²². The endothelial membrane disappears from the pupillary membrane, iris, and anterior chamber angle progressively, possibly incorporated into the trabecular meshwork, during the third trimester. The peripheral uveal tissue begins to slide posteriorly in relation to the anterior chamber angle structures. The trabecular meshwork development begins in the inner, posterior aspect of the primordial tissue, progressing toward Schlemm's canal and Schwalbe's line. The normal anterior chamber angle becomes fully developed at the age of 1.

(Fig 3) Developmental mechanics of chamber angle

Development of the normal angle structures comprises of bi directional growth. Scleral spur shows an inward growth represented by the horizontal arrow accompanied by receding uveal meshwork represented by the vertical arrow. As the growth progresses there is obliteration of the fetal uveal meshwork leaving behind a few fine residual iris processes. When this normal developmental process comes to a halt, it results in persistence of the uveal meshwork leading to Congenital Glaucoma.

THEORIES OF ABNORMAL DEVELOPMENT IN PCG

Elevation of intraocular pressure in Primary Congenital Glaucoma is considered to be due to abnormal development of the angle structures causing reduced facility of aqueous outflow. Several major theories have been put forward.

Mann's Theory:

Mann in 1928, proposed that the arrest of the process of formation of the anterior chamber angle by atrophy of mesenchyme results in retention of abnormal tissue blocking aqueous outflow in PCG²³.

Incomplete Cleavage Theory:

Allen, Burian, and Braley (1955) noted that incomplete cleavage of mesoderm causes absence of angle recess in PCG, though cleavage theory for normal development is not proved²⁴.

Barkan's theory:

Barkan in 1955 suggested that incomplete resorption of the mesodermal cells led to membrane formation across anterior chamber angle²⁵. According to Barkan and Worst, a thin membrane, later termed as the Barkan's membrane, is said to be covering the trabecular meshwork surface. Anderson and Maumenee were unable to prove the presence of this membrane despite extensive histologic studies with light and electron microscopy. Anderson suggests that thickened, compact trabecular beams in the meshwork area close to the anterior chamber resembles a membrane when visualized under the operating microscope.

Maumenee's theory:

In Infantile Glaucoma eyes, Maumenee (1958) noted an abnormal insertion of the ciliary muscle anteriorly over the scleral spur²⁶. The ciliary muscle's longitudinal and circular fibers inserts at the level of the trabecular meshwork instead of the scleral spur. He postulated that the scleral spur might be compressed forward and externally by these changes, thus narrowing the Schlemm's canal. The absence of Schlemm's canal in some histopathologic specimens was noted by Maumenee (1963), who suggested that this might be the cause of aqueous outflow being obstructed in Congenital Glaucoma.

Worst theory:

Worst in 1966 proposed some of the atrophy and resorption concepts, rejecting the cleavage theory, and suggested that a high insertion of ciliary muscle's longitudinal portion on the trabeculum is caused by an incomplete scleral spur development.

He also felt that during gestation, the anterior chamber angle is covered by a single layer of endothelial cells, and that '*Barkan's Membrane*' is constituted by its abnormal retention in PCG. Worst still believed this theory despite the lack of evidence to it.

Smelser and Ozanics' theory of failure of rearrangement:

Smelser and Ozanics (1971) explained that the anterior chamber angle mesoderm's failure to become properly rearranged into the normal trabecular meshwork in PCG, a theory favored by light and electron microscopic studies.

Kupfer's theory:

Kupfer and associates (1978) suggested that migration of abnormal neural crest cell and a defect of terminal induction by embryonic inducers causes several forms of congenital glaucoma.

Anderson's theory:

Anderson in 1981, histopathologically proposed the high insertion of the anterior uvea into the trabecular meshwork, due to a developmental arrest in the uvea's normal migration across the meshwork in the third trimester of gestation. He stated that, in PCG eyes the iris and ciliary body have failed to recede posteriorly, and hence the posterior portion of the trabecular meshwork is overlapped by the insertion of the iris and anterior band of ciliary body. He also believed that the normal posterior migrations of ciliary body and iris root is prevented by thickened trabecular beams in infantile glaucoma.

Beauchamp's theory:

Beauchamp and co-workers (1985) have postulated that abnormal extracellular matrix and glycoproteins interferes with adductors, inductors, receptors and specific time sequencing which leads to abnormal anterior segment development. According to them, the defects in morphogenesis and differentiation (capacitation) in Primary Congenital Glaucoma requires a minor 'remodeling' to become functional such as goniotomy. McMenamin (1991) noticed a marked increase in the extracellular matrix volume during development. Tawara and Inomata in 1994 found extensive accumulations of basal lamina-like material containing heparan sulfate-type proteoglycans in the thick subcanalicular tissue in trabeculectomy specimens from patients with Developmental Glaucoma.

In summary, primary congenital glaucoma appears to be a result of anterior chamber angle tissue's a developmental abnormality derived from neural crest cells, one or more of various mechanisms causing aqueous outflow obstruction.

The arrest of development may cause an anterior insertion of iris and the ciliary muscle directly into trabecular meshwork, and only a rudimentary scleral spur may be seen. The trabecular beams may be compressed due to the high insertion of the ciliary body and iris into the posterior portion of the trabecular meshwork and the extracellular matrix could be abnormal. There may also be primary developmental defects at various levels of the meshwork and in Schlemm's canal in certain cases, although, a true membrane over the meshwork does not appear to be a feature of this disorder.

EVALUATION OF PCG

PCG is a characteristic type of Developmental Glaucoma caused by an isolated anomalous development of the trabecular meshwork, not involving other ocular maldevelopment or pathology that can elevate the intraocular pressure.

Symptoms: The 'classic triad' of symptoms²⁷ in Congenital Glaucoma includes

1. Epiphora
2. Photophobia
3. Blepharospasm (attributed to IOP-induced corneal epithelial edema).
4. Ocular enlargement occurs because the neonatal globe is still distensible. The corneal and scleral collagen have not hardened sufficiently to prevent their expansion with increased intraocular pressure. This change includes stretching in all parts of the infant eye, including the cornea, the anterior chamber angle, the sclera, the optic nerve, the scleral canal, and the lamina cribrosa²⁸. However, presence of prominent eyeball and cloudy cornea which is the result of corneal edema are the common presentations of the condition in the Indian population.

A mandatory thorough clinical evaluation is required. Child's response to light can be checked by using a dim light source. Vision should be assessed by age-appropriate methods. Posterior segment pathology should be looked for, using ultrasonography when fundus cannot be visualized.

The primary method of evaluation involves an examination under anesthesia (EUA), preferably under the operating microscope. Examination under sedation is often adequate for

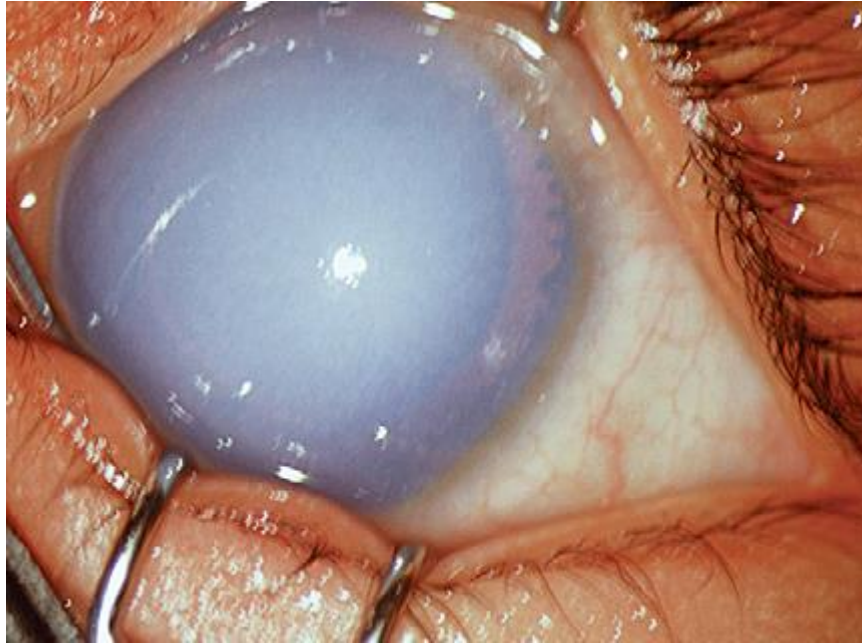
brief examinations, and general anaesthesia may be needed when a prolonged examination and surgery are required. The following are to be documented during EUA:

1. **Corneal findings:** to measure corneal diameter to look for corneal clarity, Haab's striae
 - a. A corneal diameter more than 12 mm before the age of 1 is indicative of PCG. Enlargement of the cornea in PCG basically occurs until the age of 3, but the sclera can undergo stretching upto the age of 10. Separate measurements of the corneal diameters are to be taken in both the horizontal and vertical meridians. Calipers should be used for the measurement.

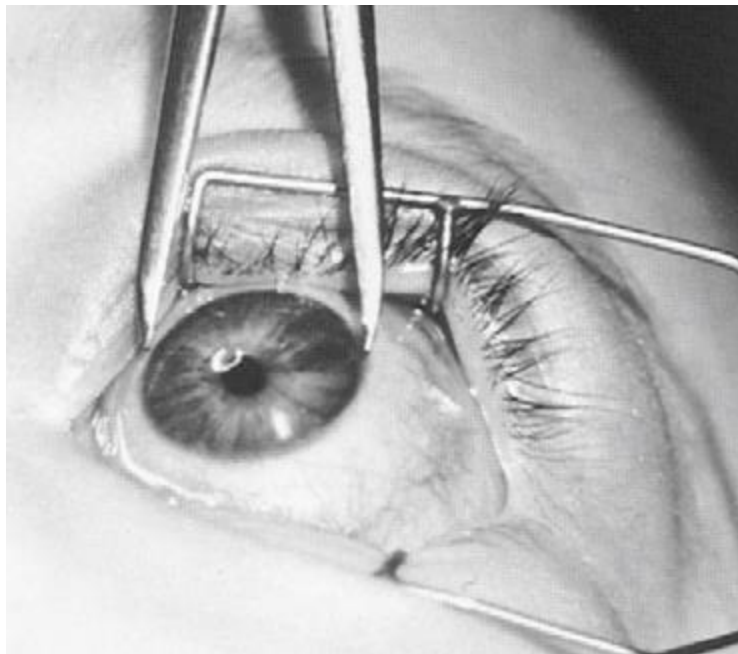
Age	Corneal diameters (mm)	
	Normal	Possible Glaucoma
Newborns	9.5–10.5	11.5–12.0
1 year	10–11.5	12.0–12.5
2 years	11.5–12	12.5–13.0
3 years	12	13.0–14.0
**Data obtained from Morin <i>et al</i>		

- b. Edema of the cornea in PCG starts at the epithelial level due to raised IOP which eventually results in permanent stromal edema. If not treated promptly, the edema worsens leading to permanent scarring of the stroma and thus increases the astigmatic index.
 - c. The acute elevation of IOP results in damage to the corneal endothelium and stretching of the Descemet's membrane leading to breaks in these layers³⁰. Since this was first described by Haab, these striae are named after him. These striae are typically horizontal and linear when they occur centrally in the cornea, but parallel or curvilinear to the limbus when they occur peripherally.

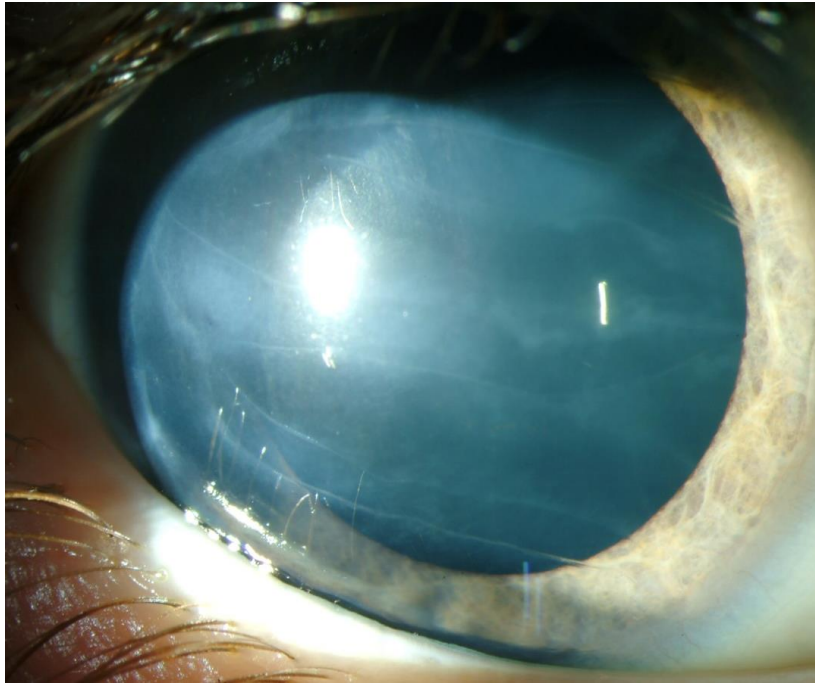
(Fig 4) Corneal edema in a case of congenital glaucoma



(Fig 5) Measurement of corneal diameter using calipers



(Fig 6) Haab's Striae



Direct Gonioscopic lenses used in infants:

Fig 7) Richardson-Shaffer lens (L) is a miniature of Koeppel lens (R)



2. **IOP:** The mode of anesthesia and the method of tonometry are of utmost value. Almost every anesthetic agents varies the IOP, seemingly in relation to the level of anesthesia and as a direct function of their effect on cardiovascular tone. A rapid lowering of IOP occurs particularly with halothane, while transient elevation can occur with cyclopropane or succinylcholine. In recent years, halothane has been largely replaced by sevoflurane because of its rapid onset of action, faster recovery time and lower incidence of reported side effects. However, sevoflurane shares the IOP-lowering effect of halothane and it has been suggested that IOP should be checked immediately after intubation to avoid falsely low recordings. Anesthetic drugs that achieve only light anesthesia and those that induce deeper anesthesia only slowly, such as diethyl ether, cyclopropane or ketamine³¹, allow the IOP to be measured somewhere between the artificially elevated IOP of “excitement” stage of anesthesia and the artificially lowered pressure of deep anesthesia observed with halothane. The possible effect of ketamine on IOP has been controversial. Some studies report that ketamine elevates IOP, whereas others suggest that the impact on IOP is comparatively modest. Regarding the type of tonometer, Perkins hand-held applanation tonometer or electronic (Tonopen) tonometer is commonly employed. Our preference is the Perkins tonometer. The normal IOP in an infant is slightly lower than in an adult, but 21 mm Hg remains a useful upper limit.
3. **Gonioscopy:** Direct gonioscopic lens with a hand-held illuminating source and binocular microscope provides a good view of the angle. In the normal newborn eye, the iris usually inserts posterior to the scleral spur. In PCG, the iris commonly inserts anteriorly directly into the trabecular meshwork. This iris insertion is most commonly flat, although a concave insertion may be rarely seen.

Loch Ness Monster phenomenon³²: Although the angle is usually avascular, loops of vessels from the major arterial circle may be seen above the iris producing a “*sea serpent appearance*”. Sometimes, the peripheral iris may be covered by a fine, fluffy tissue which is termed “*Lister’s morning mist*” sign.

4. ***Ophthalmoscopy***: The Infant Glaucomatous Cup usually has a configuration different from Adult Glaucomas. Although it can be oval, it is more commonly round, steep-walled and central, surrounded by a uniform pink rim. The cup tends to enlarge circumferentially with glaucomatous progression, which probably results from stretching of the scleral canal. Although this pattern of cupping can develop early and rapidly in infants with Glaucoma, striking reversal of cupping may result with IOP reduction after successful surgery³³. But this reversal of cupping is not evident in adults and children (especially older ones) with advanced glaucoma suffer irreversible thinning/notching of neuro-retinal rims.

5. ***Refraction, using streak retinoscope***

Interpretation of examination findings:

After EUA, increased corneal diameter, increased cup disc ratio and prominent eye balls proves the presence of PCG indicating the need for surgery. The effect of various anesthetic agents on the IOP should be kept in mind while interpreting the result. In the absence of characteristic features of PCG, diagnosis and treatment may be postponed, and after 3–4 weeks, a repeat EUA may be done to confirm progression, if any.

DIFFERENTIAL DIAGNOSIS OF PCG

I. Other causes of Glaucomas

A. Glaucoma associated with any congenital anomaly

B. Secondary Glaucoma

II. Other causes of prominent/ hazy cornea

A. Megalocornea

B. Sclerocornea

C. High myopia

D. Metabolic diseases

1. Cystinosis

2. Mucopolysaccharidoses

3. Hand-Schüller-Christian disease (histiocytosis)

4. Acrodermatitis enteropathica

5. Peroxisomal disorders

6. Zellweger syndrome

E. Posterior polymorphous dystrophy

F. Congenital hereditary endothelial dystrophy

G. Birth trauma

H. Inflammatory conditions of the eye

III. Other causes of watering of eyes or photophobia

A. Congenital Nasolacrimal duct obstruction

B. Conjunctivitis

C. Corneal abrasion

D. Meesman's corneal dystrophy

E. Reis-Buckler's dystrophy

IV. Other causes of optic nerve head changes

A. Pit

B. Coloboma

C. Hypoplasia

D. Tilted disc

E. Large physiologic cup

MANAGEMENT

Overview of management

Primary goals in the management of Congenital Glaucoma includes the following.

1. To control the intraocular pressure in order to prevent loss of visual acuity
2. To preserve visual field
3. To maintain the ocular integrity
4. To stimulate the development of binocular stereoscopic vision in the affected child.

Anxiety of the parents should be addressed first. Proper sensitization regarding the nature of the disease and the progression should be given to the parents. Emphasis on regular follow up examinations, drug compliance and possibilities of re-surgeries. The physician should never forget the importance of amblyopia management in recalcitrant cases.

Medical therapy is usually a supportive management. Laser therapy is not of much benefit in these cases. Surgical treatment is the ideal treatment of choice in most of the developmental Glaucomas. Goniotomy or trabeculotomy are the initial lines of management. In India, hazy cornea precludes goniotomy in most of the cases. In case of failure of prior procedures combined trabeculotomy with trabeculectomy has proved to be helpful. In refractory cases pharmacologically modified trabeculectomy or glaucoma drainage implants may be needed.

Medical therapy

Medical therapy is a temporary management. Topical drugs help in alleviating the IOP, to reduce the corneal edema so that surgical intervention can be carried out.

1. Beta-blockers: Beta-blockers reduces IOP by decreasing aqueous formation with little or no effect on the outflow facility. Beta-blockers used in congenital glaucoma include Betaxolol 0.25%, Levobunolol 0.25%, Timolol solution 0.25%, and Timolol gel-forming solution 0.25%. Plasma timolol levels in children after treatment with 0.25% timolol greatly exceed those in adults after instillation of 0.5% timolol, especially in infants. Increased plasma timolol levels in children are explained by the volume of distribution of the drug, which is much smaller in children compared with adults. Higher plasma levels of drug would be expected to be associated with an increased risk of systemic side effects in children, especially young children, compared with adults.

The drug should be used with extreme caution in neonates due to the possibility of apnea and other systemic side effects³⁵. Exacerbation of bronchial asthma can occur in children. Hence it is not recommended in pediatric age group. Betaxalol which is a selective β_1 antagonist is preferred.

2. Carbonic anhydrase inhibitors (CAIs): this can be used both systemically and topically in the management of Glaucoma. It acts by reducing the aqueous humour formation by reversible non-competitive binding with the enzyme type2 C-type carbonic anhydrase which is the predominant enzyme in ciliary process. Growth suppression in children has been associated with oral acetazolamide therapy, and infants may experience a severe

metabolic acidosis. Oral administration of acetazolamide suspension at a dosage of 10 (range 5–15) mg/kg/day given in divided doses (three times daily) is safe and well tolerated by children, lowers IOP and may reduce corneal edema prior to surgery. Topical versus oral CAI therapy has been evaluated for Pediatric Glaucoma in a crossover design study. The mean IOP was reduced by 36 and 27% compared with baseline, after treatment with oral acetazolamide and topical dorzolamide, respectively. All eyes showed an increase in IOP when switched from acetazolamide to dorzolamide, with a mean increase of 3.7 mm Hg. Although not as effective as acetazolamide in this group of patients, topical dorzolamide caused a significant reduction of IOP and was well tolerated.

3. Prostaglandin analogues: Latanoprost (0.005%) and travoprost (0.004%) act on the FP receptors and produce a decrease in IOP by increasing the uveoscleral outflow without any effect on aqueous production, trabecular outflow and episcleral venous pressure. Several studies also indicate that they also produce a change in the structure of the uveoscleral meshwork - ECM remodelling, widening of intermuscular spaces in the longitudinal ciliary muscle and dissolution of type 1 & 3 collagen. Bimatoprost (0.03%) is a prostamide, which does not act through PG receptors. It acts by inhibiting the enzymes metabolising PGs which increases both uveoscleral and trabecular outflows. According to various studies latanoprost proved to cause sufficient reduction in IOP in children. Parents should be educated about the probable side effects of the drug.
4. Alpha-2 agonists: Brimonidine should be avoided in pediatric patients under the age of 5.
5. Other drugs: IOP may be reduced temporarily before surgery in patients with developmental glaucomas by administering osmotic drugs such as mannitol.

Surgical Management

Introduction

Prompt surgical intervention is the definitive treatment of congenital glaucoma. Goniotomy may be performed if cornea is relatively clear to permit view of the angle structures at the time of referral for treatment. Goniotomy cannot be done if patients present with corneal clouding. In such cases, the procedure of choice is initial external trabeculotomy. If initial trabeculotomy is not successful, trabeculotomy combined with trabeculectomy may be performed.

Most patients present with characteristic features of congenital glaucoma soon after birth or within 6 months of birth. But some cases can present late in the first year. In advanced cases, combined procedures proved to be beneficial.

Goniotomy

The goal of Goniotomy is to eliminate the hindering element that causes impedance to aqueous outflow, hence it restores the conventional outflow of aqueous through the trabecular meshwork in to the Schlemm's canal.

Various surgical gonioscopic lenses are available. Swan-Jacob lens is very convenient to use. Barraquer knife, Worst knife, Swan blade can be used to perform goniotomy. Under general anesthesia (GA), under the operating microscope, goniotomy is to be done after fixing the globe with bridle suture.

The surgeon should sit opposite to the angle that is to be incised. The goniotomy knife is used to do the paracentesis, through clear peripheral part of the cornea, about 1 mm inside the

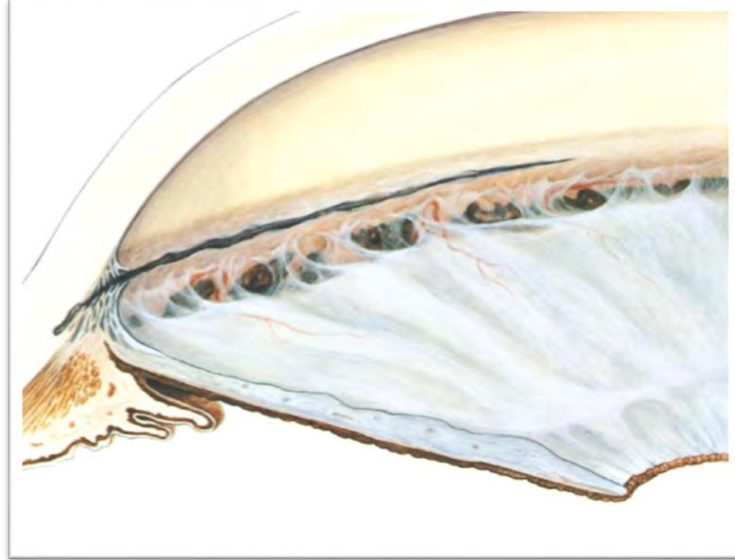
limbus. Once the anterior chamber is entered, the blade must be clearly seen throughout the procedure. The goniotomy knife must be advanced above and parallel to the surface of the iris, across the pupil toward the trabecular meshwork near the opposite limbus.

The knife tip must be directed slightly ahead of the middle portion of the trabecular meshwork. It should be made to depress the trabecular meshwork and then circumferential sweeping movement should be done with the knife as it cuts the trabecular tissue over 90 to 120°. Cut of uniform depth throughout the incision.


Following the incision, a white line is visible posterior to the blade, which is accompanied by posterior movement of the iris as the angle deepens. Mild hyphema usually occurs on withdrawing the blade. Goniotomy surgery is reported to have a success rate of 80% in congenital glaucoma³⁷.

Even though goniotomy is more successful when glaucoma is recognized early and treated promptly before one year of age, successful control is achieved in patients up to 2 years of age. Endoscope assisted goniotomy is tried to improve the results.

(Fig 7) Goniotomy: The illustrated gonioscopic cross-section shows exact location of incision in abnormal trabecular meshwork.



(Fig 8) Swan Jacob Goniolens



Advantages of Goniotomy:

1. Conjunctiva is preserved, hence this procedure doesn't interfere with the success of future filtering surgery, if needed.
2. Precise location of the incision is aided by direct visualization of the angle
3. It is a safe procedure as its less traumatic
4. Duration of the surgery is less
5. Procedure can be repeated
6. Incidence of significant hypotony is low
7. Bleb related complications are avoided

Disadvantages of Goniotomy:

1. Technically difficult
2. Need for special instrumentation
3. Procedure cannot be done if the details of the angle structures are not clearly seen.

Trabeculotomy ab externo

A fornix-based or limbus-based conjunctival flap is made, followed by a partial thickness scleral flap as it is done in trabeculectomy, and Schlemm's canal is then deroofed by incising midway between the anterior bluish-gray area and the posterior white scleral area.

The lower arm of the Harms' trabeculotome is introduced into the canal using the upper parallel arm as a guide. Once 90% of the trabeculotome is within the canal, it is rotated into the anterior chamber. Rotation of the trabeculotome is continued until 75% of the probe arm length has entered the chamber, then the rotation is reversed and the instrument is withdrawn. About 2

to 2 1 / 2 clock hours of the internal wall of Schlemm's canal and trabecular meshwork are disrupted by the rotation of the trabeculotome into the anterior chamber. The trabeculotome is then passed into the Schlemm's canal on the other side of the radial incision and rotated into the anterior chamber.

In total, about 100 to 120 degrees of trabecular meshwork is ruptured by this technique. This establishes direct contact between the anterior chamber and Schlemm's canal. Scleral flap must be sutured tightly with 10-0 nylon and the conjunctival flap with 8-0 vicryl. Various studies have proved that trabeculotomy outstands goniotomy, as the initial procedure however in few studies both the procedures fared equally well

Trabeculotomy ab externo has a lot of advantages over Goniotomy³⁸.


1. It can even be done in edematous or scarred cornea.
2. Breakthrough of the inner wall of the Schlemm's canal and trabecular meshwork can be more accurately.
3. Sharp instruments need not be introduced into the AC.
4. Can be performed under operating microscope thus it precludes the need for special gonioscopic lens.
5. Can be repeated
6. Can be converted to trabeculectomy if needed
7. Can be combined with trabeculectomy to achieve better results

Disadvantages of Trabeculotomy includes

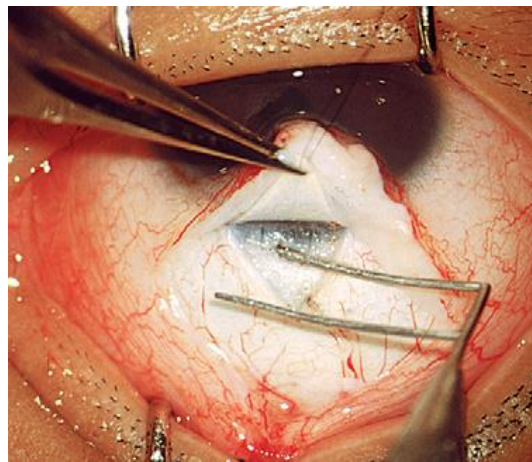
1. Damage to the conjunctiva can interfere with the outcome of future filtering surgery
2. Special trabeculotomy probes are needed
3. Altered limbal anatomy especially in severe cases of buphthalmos makes the identification of sclermm's canal difficult
4. Schlemm's canal is not found in 4 to 20 % of the cases
5. Conversion of trabeculotomy entry site to trabeculectomy makes the sclerostomy site very close to the root of iris which predisposes to iris tissue incarceration
6. Undesirable external filtration can occur

Anomalous angle type is found to be the only factor influencing the success of trabeculotomy ab externo. However, the success of Goniotomy relies upon the stage of glaucoma, corneal diameter or the presence or absence of hazy cornea. Studies have proved that goniotomy is successful in about 64–77% of eyes, while trabeculotomy controls IOP in over 90% of eyes. However, no prospective, controlled trials are available to compare the success rate of both the procedures in the same study.

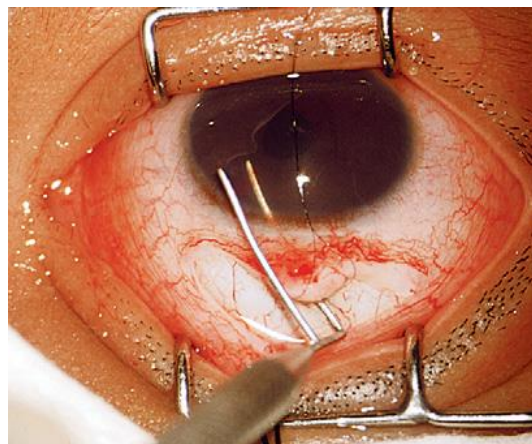
(Fig 9) The Harms' trabeculotomes



(Fig 10) The trabeculotome is passed into Schlemm's canal



(Fig 11) The trabeculotome is rotated into the anterior chamber



Modifications of Trabeculotomy:

Beck and Lynch introduced a modification in trabeculotomy using prolene suture. 360 degree trabeculotomy can be done in a single procedure by threading a 6-0 polypropylene suture through the schlemm's canal in patients with Primary Congenital Glaucoma. The refined technique can be performed via a single nasal surgical site. Advantages of this technique are this avoids many of the difficulties encountered with metal trabeculotomes and preserves conjunctiva for future filtering Glaucoma surgery. Disadvantages includes difficulty in threading the suture throughout the canal length, hypotony and misdirected sutures.

Gonioscopy-assisted transluminal trabeculotomy (GATT)

This is a new, minimally invasive, ab interno procedure using a fiberoptic catheter with illuminated tip which allows visualization of the tip of the catheter as it is threaded through the canal of Schlemm³⁹. It is demonstrated to be safer than suture trabeculotomy. Most common complication was transient hyphema.

Primary Trabeculectomy

Though it is technically easier than goniotomy or trabeculotomy it is not a first-line procedure in congenital glaucoma, due to higher incidence of bleb related complications and lower rates of success.

Trabeculectomy with mitomycin-C

Filtering surgery is indicated when one or more angle surgeries failed to control the disease progression. Fornix-based flaps are preferred in both infants and children. Intraoperative use of mitomycin-C improves the outcome of this procedure to some extent, however with side

effects of its own. IOP control was achieved in 66% at 30 months in a series of 38 eyes, which mostly had uncontrolled PCG was reported by Mandal and associates⁴⁰. Varied outcomes were reported in multiple studies using mitomycin-C doses ranging from 0.2 to 0.5 mg/ml applied for about 2 to 5 minutes has been reported by other authors; in most of these series, bleb-related infections have been reported.

Combined Trabeculotomy with Trabeculectomy

As in a routine trabeculectomy, Kelly's descemet's punch can be used in removing a small rectangular strip of sclera from the deep scleral flap by after performing a trabeculotomy

Drainage Devices:

These devices may be inserted under the conjunctiva to make a communication between the anterior chamber and the subconjunctival space in recalcitrant cases. Glaucoma drainage implants are useful when other surgical treatments have a poor prognosis for success, prior conventional surgery fails, or when significant conjunctival scarring precludes filtration surgery. Available types of drainage implants may be characterized as open tube (non-restrictive) devices or valved (flow-restrictive) devices. Open tube implants include the Molteno and Baerveldt implants, whereas the Krupin implant and the Ahmed Glaucoma Valve are flow-restrictive devices. Reported complications include hypotony with shallow anterior chamber and choroidal detachments, tube–cornea touch and corneal edema, obstructed tube, exposed tube or plate, endophthalmitis, and retinal detachment.

Follow-up:

Emphasis should be laid on amblyopia treatment resulting from scars in the visual axis and anisometropia. Although stretching of the globe is compensated by the flattening of the cornea, there is still some amount of residual myopia which must be corrected. Many cases land up with irregular astigmatism. As the anisometropia is varies with time repeated cycloplegic refraction should be done. Need for frequent change of spectacles must be instructed.

Recognition of amblyopia warrants occlusion therapy. Hence a collaborative approach including ophthalmologist and pediatrician maximizes the child's visual rehabilitation.

REVIEW OF LITERATURE

1. Molecular and Clinical Evaluation of Primary Congenital Glaucoma in Kuwait; Suad Alfadhli; Am J Ophthalmol 2006; 141:512–516

Mutations in CYP1B1 gene were identified in more than 85% of PCG-affected families in Saudi Arabia. Mutation in this gene was also found to be common in Turkey and Slovakia. Only 48% of patients with PCG in France had the CYP1B1 gene mutations, whereas Curry and associates in 2004 concluded that mutations of CYP1B1 are not a major cause of PCG in Ecuador. A cohort of 17 PCG patients was screened for the presence of mutations in the coding part of this gene in Kuwait. The overall mutation rate of the CYP1B1 gene in Kuwaiti PCG patients was 22 out of 34 studied chromosomes (64.7%).

2. Molecular genetics of primary congenital glaucoma; Mansoor Sarfarazi, Ivaylo Stoilov; Eye (2000) 14, 422-428

The primary molecular defect underlying the majority of PCG cases has been determined as mutations in the enzyme cytochrome P4501B1. The CYP1B1 gene has been found and reported to be expressed in the tissues of the anterior chamber angle of the eye. Molecular modelling experiments have suggested that the mutations observed in PCG patients interfere with the integrity of the CYP1B1 molecule as well as its ability to adopt normal conformation. Based on these observations, we hypothesise that CYP1B1 participates in the normal development and function of the eye by metabolising essential molecules that are probably used in a signalling pathway.

3. Mutation spectrum of the CYP1B1 gene in Indian primary congenital glaucoma patients; Aramati Bindu Madhava Reddy, Kiranpreet Kaur, Anil Kumar Mandal; Molecular Vision 2004; 10:696-702

Mutations in CYP1B1 have been associated with PCG with varying frequencies across different ethnic communities and geographical boundaries. Populations with higher rate of inbreeding and consanguinity exhibit a higher frequency of CYP1B1 mutations in PCG as opposed to ethnically diverse populations. Screening a cohort of 64 consecutive PCG cases from different geographical locales of India revealed 37.50% (24/64 cases) mutations in CYP1B1. Of these 24 cases, consanguinity was seen in 16 cases and 3 of them had a positive family history. The involvement of CYP1B1 in PCG was found to be lower (37.50%) in our population than those reported in Saudi Arabian (95.0%) and Slovakian Gypsy populations (100%). This could be due to a higher rate of inbreeding and allelic homogeneity in these populations.

PART II

AIM AND OBJECTIVES OF THE STUDY

OBJECTIVES:

- To do clinical evaluation of primary congenital glaucoma
- Identification and analysis of polymorphism in CYP1B1 gene in patients diagnosed to have PCG.
- Isolation of genomic DNA from clinical blood samples
- Amplification of CYP1B1 gene exon from genomic DNA using Polymerase Chain Reaction
- Sequencing of amplified product and analysis of polymorphic variations

METHODOLOGY:

Patients of age 0 to 10, diagnosed to have Buphthalmos and in whom secondary causes of glaucoma were ruled out are registered for this study. Detailed clinical evaluation was done including measurement of corneal diameters, measurement of intraocular pressure and fundus examination. Blood samples will be collected from patients and their relatives after informed consent. DNA isolated from these samples will be subjected to PCR for amplifying the coding exons of the *CYP1B1* gene using gene-specific oligonucleotide primers. PCR products will be sequenced and analyzed to determine the prevalence of common mutations and establish a genetic basis in understanding the pathology of PCG.

SAMPLE SIZE:

20 cases of PCG

STUDY CENTRE:

Regional Institute of Ophthalmology and Government Ophthalmic Hospital, Chennai

Subject Selection:***Inclusion Criteria:***

Pediatric patients with the following criteria will be included in the study

1. Increased corneal diameter (>12.0 mm),
2. Raised intraocular pressure (>21 mmHg) and/ or presence of Haab's striae,
3. Optic disc changes (where examination was possible). Symptoms of epiphora and photophobia were the additional inclusion factors.
4. Age of onset- from birth to one year
5. Patients previously diagnosed to have Primary Congenital Glaucoma and on treatment will be included.

Exclusion Criteria:

1. Patients with secondary causes of Glaucoma
2. Age of onset after 1 year

MATERIALS AND METHODS OF GENETIC ANALYSIS

Reagents and Chemicals:

- Preparation of 10X TEBbuffer done using Tris – 10.8 g, Boric acid – 5.5g, EDTA – 0.93 g and made up to 100ml using distilled water.
- Reagents for Polymerase Chain Reaction:
 - 10 X Taq DNA buffer compositions -100 mM Tris-HCl (pH 8.3), 500 mM KCl and 15 mM MgCl₂. dNTP's (dATP, dGTP, dCTP, dTTP - 250 μM each)
 - Mutated Forward primer (FP) 5 pM/μl, Reverse primer (RP) 5 pM/μl
 - Taq DNA polymerase (0.6 U/μl), Template DNA (approx 50 – 100 ng) with Sterile distilled water

Primer sequence:

Forward primer sequence for CYP1B1	5'-TCTCCAGAGAGTCAGCTCCG-3'
Reverse primer sequence for CYP1B1	5'-GGGTCGTCGTGGCTGTAG-3'

DNA Isolation from Blood or Body Fluids (Spin Protocol):

Genomic DNA was isolated using Qiagen DNA isolation kit. The manufacturer protocol was followed.

Amplification OF CYP1B1 Gene Using PCR was done.

PCR Reaction Condition:

- Initial denaturation 95°C – 10 mins, Denaturation 95 °C – 1 min
- Annealing 55 °C – 1 min, Extension 72 °C – 1 min
- Final extension 72 °C -10 mins, Final hold 4 °C

Gradient PCR Reaction Condition:

- Initial denaturation 95°C – 10 mins, Denaturation 95 °C – 1 min
- Annealing 54 °C to 62 °C – 1 min, Extension 72 °C – 1 min
- Final extension 72 °C -10 mins, Final hold 4 °C

Agarose Gel Electrophoresis was done. Then the gel is taken when the loading dye reaches the end of the gel. Then the DNA bands are visualized using UV in gel doc.

Large scale amplification PCR was carried out.

Gel Elution of Amplified product:

Amplified gene products were gel purified and elute using Qiagen gel extraction kit as described below

Protocol:

- The DNA fragment from the agarose gel was sliced using clean and sharp scalpel.
- The chopped gel was weighed in a microfuge tube, three volumes of buffer QG were added to one volume of gel (100 mg is approximately to be 100 µl).
- Microfuge tube was kept in preheated dry bath for 10 mins (or until the gel gets completely dissolved). It was vortexed every 2-3 mins to dissolve the gel.
- One volume of isopropanol to the one volume of gel was added to the sample and mix.
- Qiagen column was placed in a provided 2 ml collection tube.
- Transfer 700 µl of mixture into the column and then centrifuged for 2 min at 11,000 rpm. Flow through was discarded and the Qiagen column was placed back into the same tube. The DNA get binds to the column.
- To wash, add 750 µl of PE buffer into the Qiagen column and centrifuged at 11,000 rpm for 1 min. Flow through was discarded and the Qiagen column was placed back into the same tube.

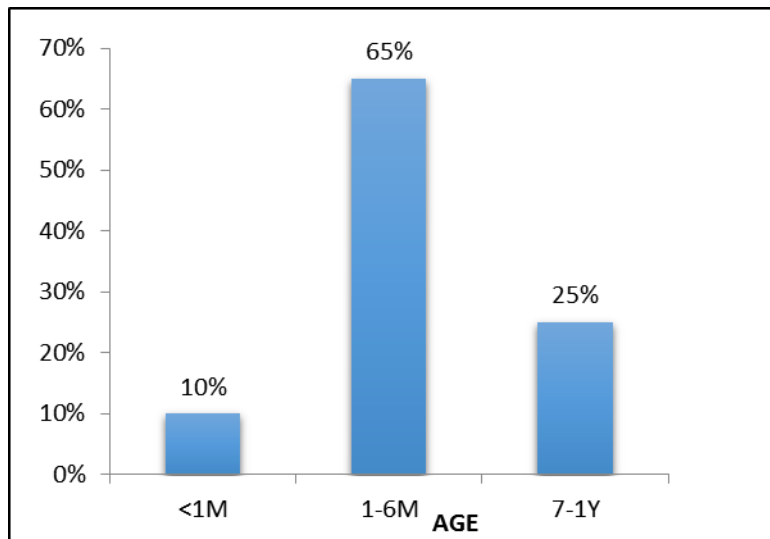
- The Qiagen column was centrifuged again as empty at 11,000 rpm for 2 mins to remove residual of wash buffer.
- Then the column was placed into a clean 1.5 ml micro centrifuge tube.
- The DNA was eluted by adding 50 μ l of EB (elution buffer) and centrifugation of column at 11,000 rpm for 1min.
- Then the purified DNA was analyzed on a 1% agarose gel electrophoresis.

RESULTS AND ANALYSIS OF CLINICAL EVALUATION

TABLE 1: AGE AT PRESENTATION

AGE AT PRESENTATION	n	%
<1M	2	10%
1-6M	13	65%
7-1Y	5	25%

CHART 1: AGE AT PRESENTATION

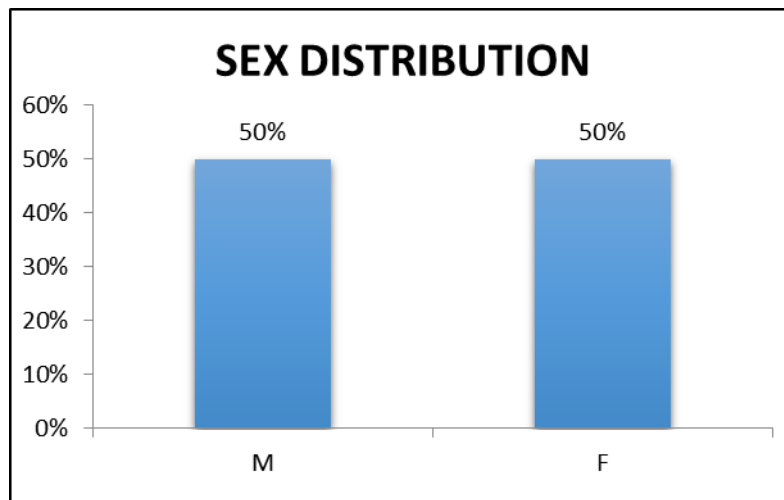


Out of the 20 children who were diagnosed to have Primary Congenital Glaucoma before the age of 1, 10 % of the children presented with symptoms of PCG within 1 month after birth, 65 % of them presented within 1 to 6 months of age and 25 % of them presented after 6 months.

TABLE 2: SEX DISTRIBUTION

SEX DISTRIBUTION	n	%
Male	10	50
Female	10	50

CHART 2: SEX DISTRIBUTION

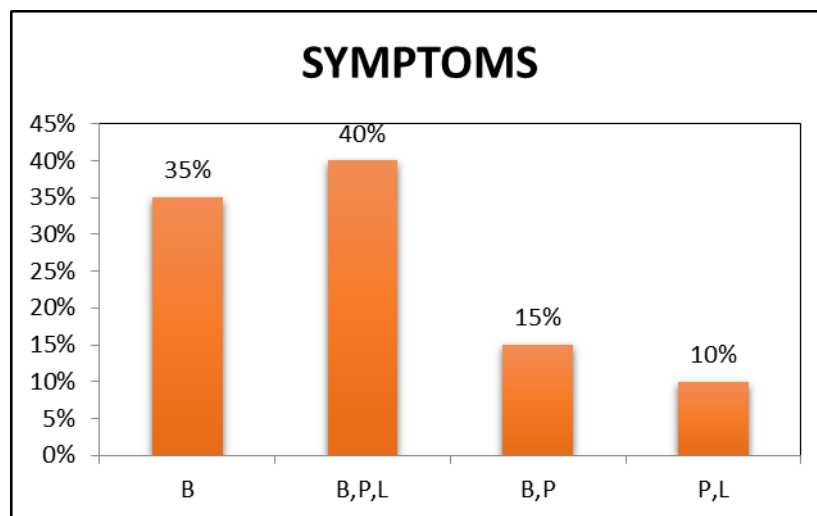


The sex distribution in the subjects enrolled in the study is shown in this chart. 50 % of the children included were males and 50 % of them were females.

TABLE 3: CLINICAL SYMPTOMS

SYMPTOMS	n	%
B	7	35
B,P,L	8	40
B,P	3	15
P,L	2	10

CHART 3: CLINICAL SYMPTOMS

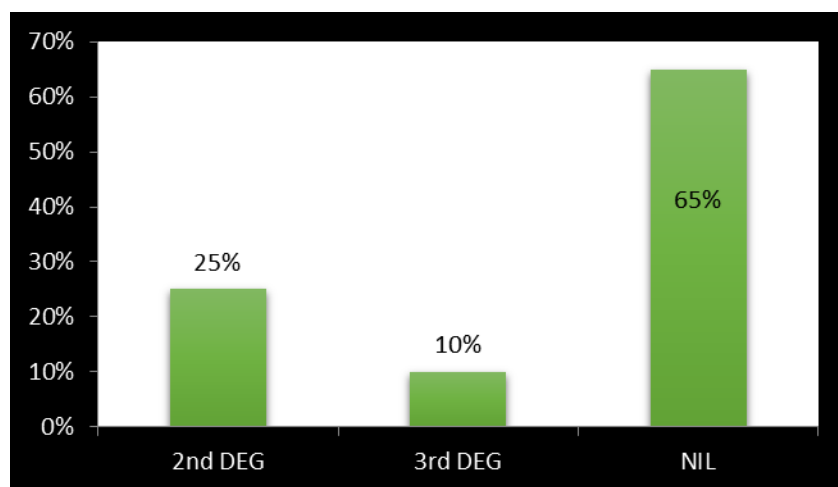


An analysis of the various symptoms with which patients present in congenital glaucoma was done. 40 % of the children were brought with complaints of Buphthalmos (B) which is marked enlargement of eyes, along with photophobia (P) and lacrimation (L). 35 % of the children presented with Buphthalmos only. 15 % of the children were brought with both Buphthalmos and photophobia. 10 % of the children were brought with photophobia and lacrimation, where marked enlargement of eyes was either absent or unnoticed by the parents.

TABLE 4: PROPORTION OF CHILDREN BORN OF CONSANGUINEOUS MARRIAGE

CONSANGUINITY	n	%
2 nd degree	5	25
3 rd degree	2	10
Non consanguineous marriage	13	65

CHART 4: PROPORTION OF CHILDREN BORN OF CONSANGUINEOUS MARRIAGE

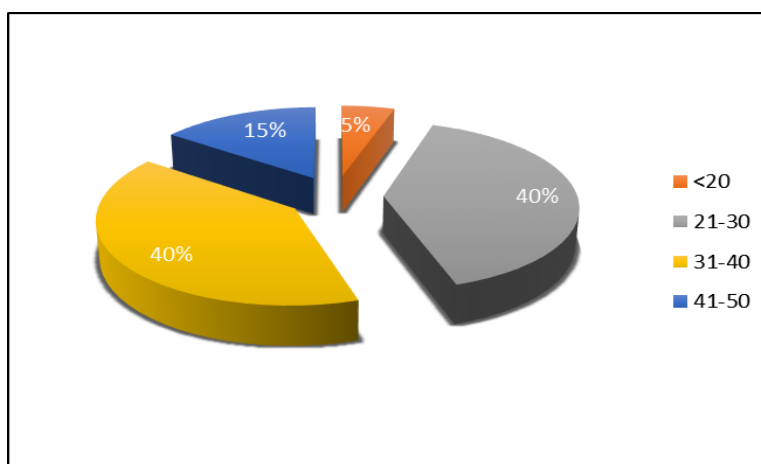


Out of the 20 children, 25 % of them were born of 2nd degree consanguineous marriage, 10 % were born of 3rd degree consanguineous marriage. Remaining 65 % of them were born of non-consanguineous marriage.

TABLE 5: IOP IN MMHG

IOP	n	%
<20	2	5%
21-30	16	40%
31-40	16	40%
41-50	6	15%

CHART 5: IOP IN MMHG

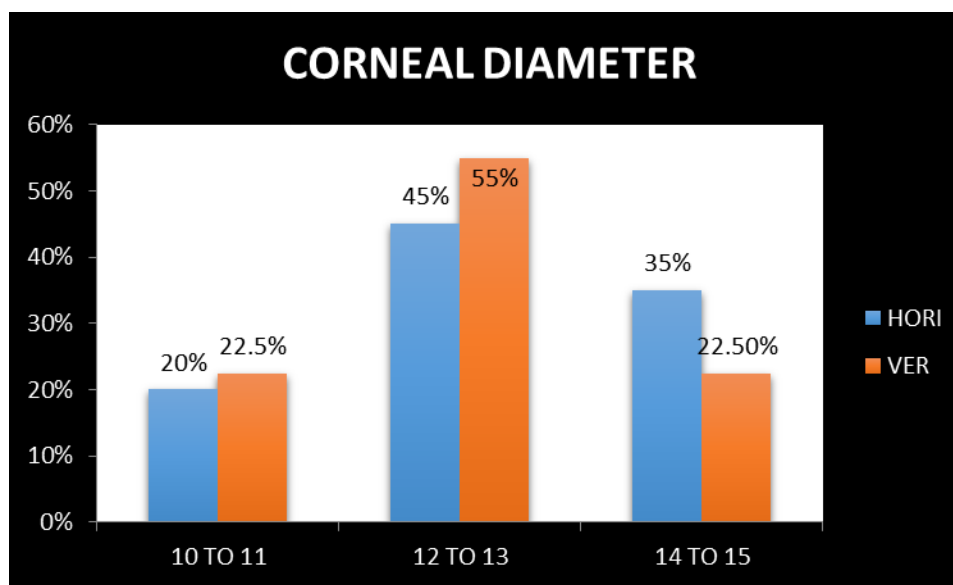


This chart depicts that 40 % of the children in the study group had IOP of 21 to 30 mmHg and 40 % had IOP of 31 to 40 mmHg. 15 % of them had IOP above 40 and 5 % had less than 20mm Hg.

TABLE 6: MEASUREMENT OF CORNEAL DIAMETER

CORNEAL DIAMETER(mm)	HORIZONTAL	VERTICAL
10 TO 11	20%	22.5%
12 TO 13	45%	55%
14 TO 15	35%	22.50%

CHART 6: MEASUREMENT OF CORNEAL DIAMETER



Measurement of corneal diameter in the subjects showed that 55 % of the eyes had vertical diameter of 12 to 13mm, 22.5 % of the eyes had diameter of 14 to 15 mm and 22.5% had diameter of 10 to 11mm. Horizontal diameters were measured to be 10 to 11mm in 20 % 12 to 13 mm in 45% and 14 to 15 mm in 35%.

TABLE 7: PROPORTION OF PATIENTS WITH CORNEAL CLOUDING

CORNEAL CLARITY	n	%
CLEAR	2	5%
MILD HAZE	25	62.5%
SEVERE HAZE	13	32.5%

Only 5 % of the eyes had clear cornea. 62.5 % of eyes had mild haze where fundus could still be visualized. 32.5% had severe haziness where it was not possible to visualize the fundus.

CHART 7: PROPORTION OF PATIENTS WITH CORNEAL CLOUDING

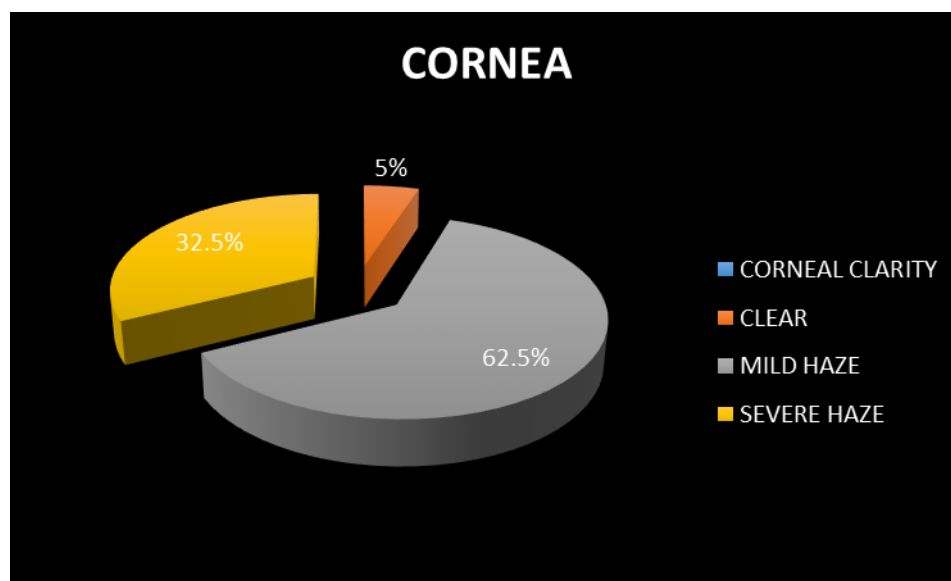
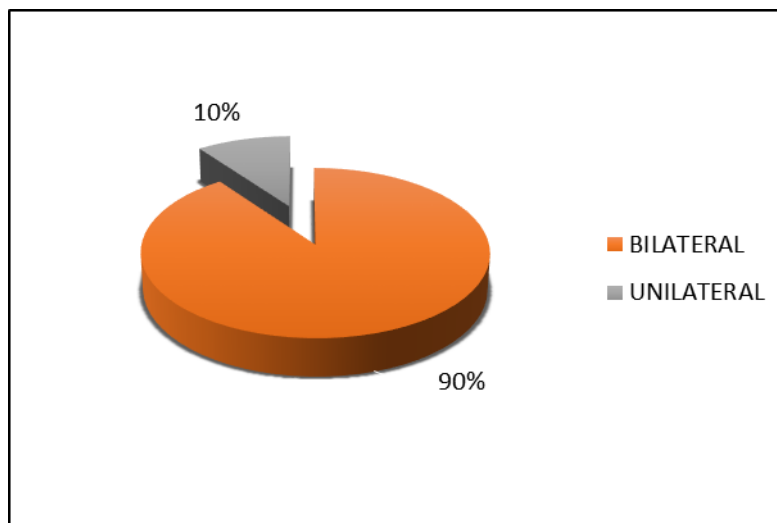


TABLE 8: LATERALITY OF PCG

LATERALITY	n	%
BILATERAL	18	90%
UNILATERAL	2	10%

CHART 8: LATERALITY OF PCG

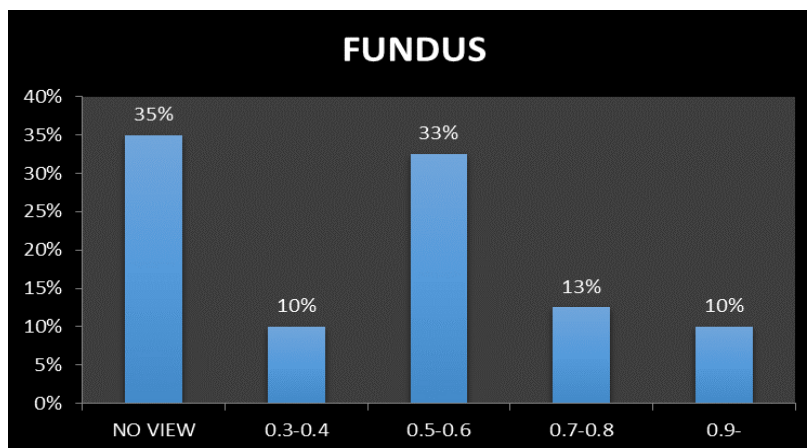


90 % of the children in the study group had bilateral manifestations of PCG. 10 % had unilateral involvement.

TABLE 9: CUP DISC RATIO

FUNDUS	n	%
NO VIEW	14	35%
0.3-0.4	4	10%
0.5-0.6	13	33%
0.7-0.8	5	13%
0.9-	4	10%

CHART 9: CUP DISC RATIO



Fundus view was not possible in 35 % of the eyes due to corneal clouding. 10% of the eyes had CD ratio of 0.3 to 0.4. 33% of the eyes had a CD ratio of 0.5 to 0.6. 13 % had CD ratio of 0.7 to 0.8. 10% of the eyes had 0.9 cupping.

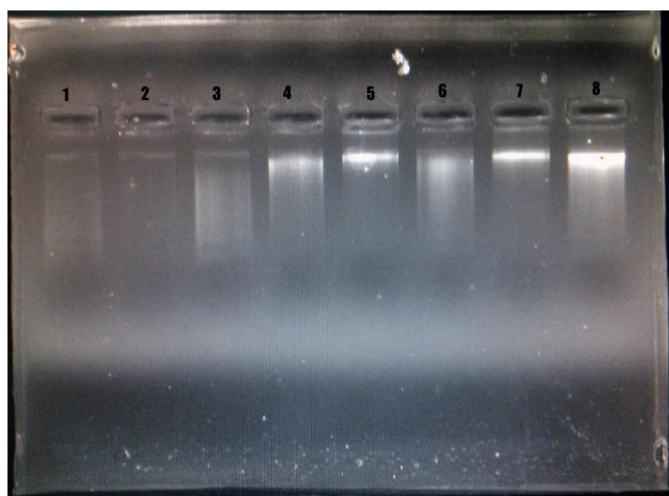
RESULTS OF GENETIC ANALYSIS

DNA was isolated from the patients included in the study by Qiagen DNA isolation kit. PCR amplification was done for the selected regions and the amplified product was found to have a molecular weight of 786 bp of exon 2.

Agarose Gel for Checking the Presence of Genomic DNA from the Collected Samples:

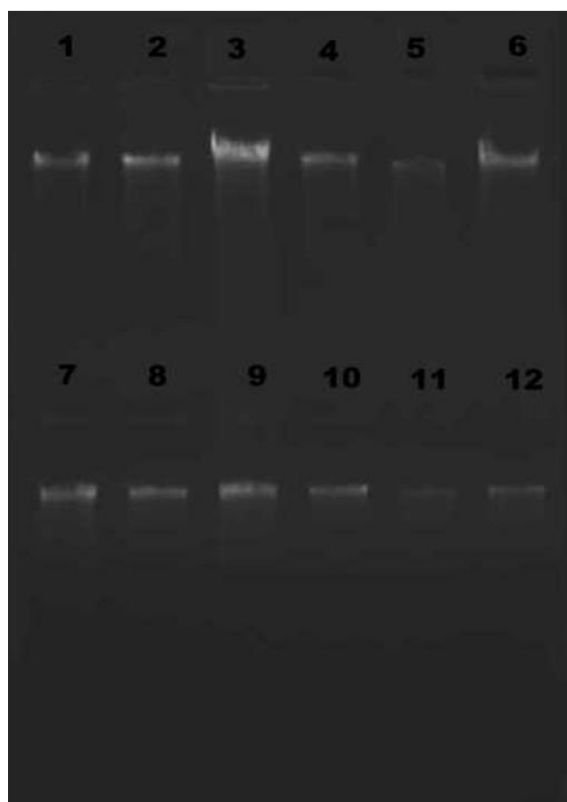
Blood samples were taken from affected patients and their relatives. Genomic DNA was extracted from the collected sample. The presence of isolated genomic DNA was checked in agarose gel. The genomic DNA isolated from the samples were analysed for concentrations as a prerequisite for amplification.

(Fig 12) Agarose Gel for Checking the Presence of Genomic DNA from the First Set of Collected Samples



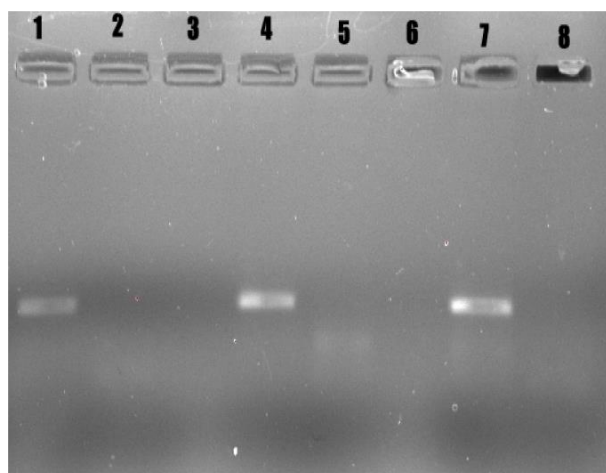
LANE 1, 2 & 3 - sample 1
LANE 4, 5 – sample 2
LANE 6, 7& 8 – sample 3

To confirm the presence and quality of genomic DNA, the isolated genomic DNA were subjected to PCR to amplify the housekeeping gene, GAPDH, using oligonucleotide primers. As expected, the PCR product showed an amplified band between 400 to 500 base pairs which confirmed that the isolated genomic DNA are of good quality and can be subjected to the PCR amplification of Congenital Glaucoma specific genes for polymorphic studies.



LANE	SAMPLE	Conc. ng/ μ l
1	Sample 1	305
2	Sample 2	90.5
3	Sample 3	147.3
4	Sample 4	47.4
5	Sample 5	50
6	Sample 6	34.8
7	Sample 7	54.9
8	Sample 8	61.5
9	Sample 9	63.6
10	Sample 10	100.2
11	Sample 11	52.5
12	Sample 12	48.9

(Fig 13) Comparison with Negative Control



LANE 1 – Sample 1

LANE 2 – NEGATIVE CONTROL FOR sample 1

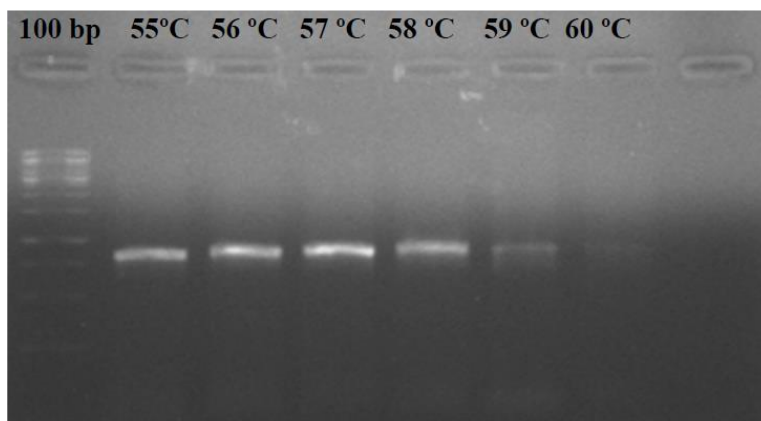
LANE 4 – sample 2

LANE 5 – NEGATIVE CONTROL FOR sample 2

LANE 7 – sample 3

LANE 8 – NEGATIVE CONTROL FOR sample 3

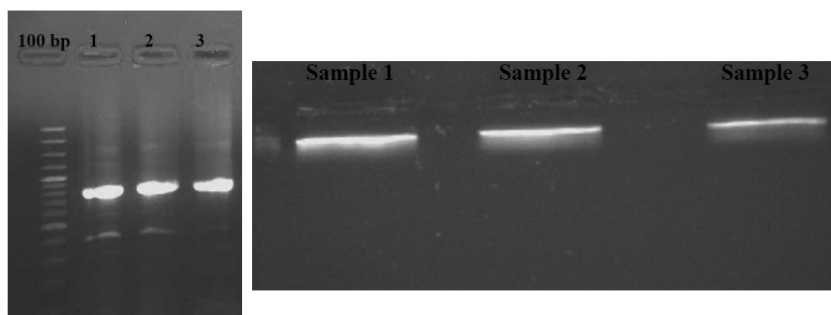
(Fig 14) Gradient PCR for CYP1B1 Gene



As the gene was amplified for varied temperatures, the band that belongs to 57°C is brighter when compared with other temperatures. Due to which 57°C is chosen as the annealing temperature.

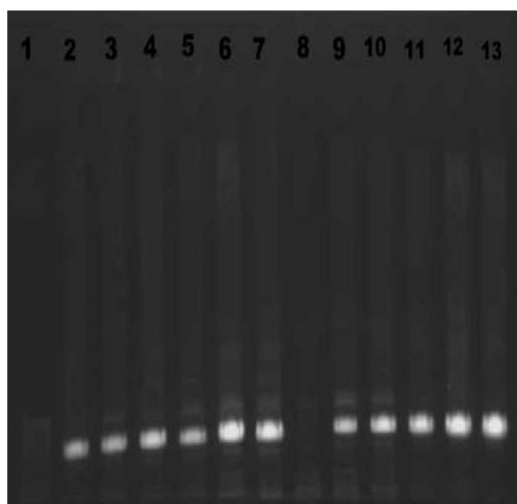
(Fig 15, 16) PCR Amplification of CYP1B1 in three samples

CYP1B1 amplicon (exon) 786 bp



The amplified samples are then gel eluted using Quigenkit and was sequenced.

(Fig 17) PCR Amplification of CYP1B1 in various clinical samples



LANE	SAMPLE	PRIMER
1	100 Base pair ladder	CYP1B1
2	Sample 1	CYP1B1
3	Sample 2	CYP1B1
4	Sample3	CYP1B1
5	Sample4	CYP1B1
6	Sample 5	CYP1B1
7	Sample 6	CYP1B1
8	Sample 7	CYP1B1
9	Sample 8	CYP1B1
10	Sample 9	CYP1B1
11	Sample 10	CYP1B1
12	Sample 11	CYP1B1
13	Sample 12	CYP1B1

Sequence of the CYP1B1 Exon

**TCTCCAGAGAGTCAGCTCCGACCTCTCCACCCAACGGCACTCAGTCCCCAGAGGC
TGGGGTAGGGGCGTGGGGCGCCCGCTCCTGTCTCTGCACCCCTGAGTGTACGCCTT
CTCCTTTCTGTCCCCAGCATGGGCACCAGCCTCAGCCCGAACGACCCTTGGCCGCTA
AACCCGCTGTCCATCCAGCAGACCACGCTCCTGCTACTCCTGTCTGGTGCTGGCCACT
GTGCATGTGGGCCAGCGGCTGCTGAGGCAACGGAGGCGGCAGCTCCGGTCCGCGCC
CCCGGGCCCGTTTGCGTGGCCACTGATCGGAAACGCGGGCGGCGGTGGGCCAGGCGG
CTCACCTCTCGTTCGCTCGCCTGGCGCGGCGCTACGGCGACGTTTTCCAGATCCGCC
TGGGCAGCTGCCCCATAGTGGTGCTGAATGGCGAGCGCGCCATCCACCAGGCCCTG
GTGCAGCAGGGCTCGGCCTTCGCCGACCGGCCGGCCTTCGCCTCCTTCCGTGTGGTG
TCCGGCGGCCCGCAGCATGGCTTTCGGCCACTACTCGGAGCACTGGAAGGTGCAGCG
GCGCGCAGCCACAGCATGATGCGCAACTTCTTCACGCGCCAGCCGCGCAGCCGCC
AAGTCCTCGAGGGCCACGTGCTGAGCGAGGCGCGCGAGCTGGTGGCGCTGCTGGTG
CGCGGCAGCGCGGACGGCGCCTTCCTCGACCCGAGGCCGCTGACCGTCGTGGCCGT
GGCCAACGTCATGAGTGCCGTGTGTTTCGGCTGCCGCTACAGCCACGACGACCC**

Multiple sequence alignment using Clustal W2:

Nucleotide sequence of CYP1B1 forward primer

Sample A-CYP F----AGGCTGGGGTAGGGGCGTGGGGCGCCCGCTCCTG 34-
 Sample C- CYP F ---AGGCTGGGGTAGGGGCGTGGGGCGCCCGCTCCTG 36-
 Healthy Sample -----AGGCTGGGGTAGGGGCGTGGGGCGCCCGCTCCTG 50-
 Sample B- CYP F-----GCTGGGGTAGGGGCGTGGGGCGCCCGCTCCTG 32--

TCTCTGCACCCCTGAGTGTCACGCCTTCTCCTTTCTGTCCCCAGCATGGG 84-
 TCTCTGCACCCCTGAGTGTCACGCCTTCTCCT**C**TCTGTCCCCAGCATGGG 86-
 TCTCTGCACCCCTGAGTGTCACGCCTTCTCCTTTCTGTCCCCAGCATGGG100-
 TCTCTGCACCCCTGAGTGTCACGCCTTCTCCTTTCTGTCCCCAGCATGGG 82-

GGCCAGCGGCTGCTGAGGCAACGGAGGCGGCAGCTCCGGTCCGCGCCCCC 234-
 GGCCAGCGGCTGCTGAGGCAACGGAGGCGGCAGCTCCGGTCCGCGCCCCC 236-
 GGCCAGCGGCTGCTGAGGCAACGGAGGCGGCAGCTCCGGTCCGCGCCCCC 250-
 GGCCAGCGGCTGCTGAGGCAACGGAGGCGGCAGCTC**G**GGTCCGCGCCCCC 232-

CATCCACCAGGCCCTGGTGCAGCAGGGCTCGGCCTTCGCCGACCGGCCGG 434-
 CATCCACCAGGCCCTGGTGCAGCAGGGCTCGGCCTTCGCCGACCGGCCGG 436-
 CATCCACCAGGCCCTGGTGCAGCAGGGCTCGGCCTTCGCCGACCGGCCGG 450-
 CATCCACCAGGCCCTGGTGCAGCAGGGCTCGGCCTTCGCCGACCGGCCG**T** 432-

Common Single Nucleotide Polymorphisms (SNP) are highlighted in red and bold.

Protein sequence CYP1B1 Forward primer

Healthy sample –RLGGRGAPAPVSAPLSVTPSPFCPQHGHQPQPE-50
 Sample A_CYP.F -RLGGRGAPAPVSAPLSVTPSPFCPQHGHQPQPE 33
 Sample B_CYP.F-GVGAWGARSCLCT-----PECHAFSFLSPA W 27
 Sample C_CYP.F-RGWGRGVGRPLLSLHPVSRLLLSVPSMGTSLSPN 34-
 RPLAAKPAVHPADHAPATPVGAGHCACGPAAAEATEAAAPVVRAPGPVCVA 100-
 -RPLAAKPAVHPADHAPATPVGAGHCACGPAAAEATEAAAPVVRAPGPVCVA 83-
 -APASARTTLGRTRCPSSRPRSCYSCRCWPLCMWASGCGNGGGSSGPRPRA 77-
 -DPWPLNPLSIQQTLLLLLSVLATVHVGQRLLRQRRRQLRSAPPGPFAW**P** 84-

 -TDRKRGGGGPGGSPLVRSPGAALRRRFPDPPG--QLPHSGAEWRARHPPG 148
 -TDRKRGGGGPGGSPLVRSPGAALRRRFPDPPG--QLPHSGAEWRARHPPG 131
 -RLRGHSETRRRWARRLTSRSLAWRG-ATATFS--RSAWAAAPWCMAS**A**PS 124
 -LIGNAAAVGQAAHLSFARLARRYGDVVFQIRLGSCPIVVLN**G**ERAIHQ**ALV** 134

 -HAPAAQPPSPRGPRRAERGARAGGAAGARQRGRRLPRPEAADRRGRGQRHE 248
 -HAPAAQPPSPRGPRRAERGARAGGAAGARQRGRRLPRPEAADRRGRGQRHE 231
 -OPTACATSSRASRAAA**K**SSRATCARRASWWRCW**CA**AARTAPSSTRGRPSW 217
 -QPRSRQVLE**EG**HVLSEARELVALL**VRGS**ADGAFDPRPLT**VVAVAN**VMSAV 234

Common Single Nucleotide Polymorphisms (SNP) are highlighted in red and bold.

Common Single Nucleotide Polymorphisms which are suggestive of published CYP1B1 mutations in PCG individuals are found in sample 1 and sample 7 of the patients included in this study group.

DISCUSSION

- In this study, a detailed clinical evaluation of children presenting with features of Congenital Glaucoma was done.
- Out of the 20 children who were diagnosed to have Primary Congenital Glaucoma before the age of 1, 10 % of the children presented with symptoms of PCG within 1 month after birth, 65 % of them presented within 1 to 6 months of age and 25 % of them presented after 6 months. 90% of the children had bilateral involvement.
- An analysis of the various symptoms with which patients present in Congenital Glaucoma was done.
- 40 % of the children were brought with complaints of Buphthalmos (B) which is marked enlargement of eyes, along with photophobia (P) and lacrimation (L).
- 35 % of the children presented with Buphthalmos only.
- 15 % of the children were brought with both Buphthalmos and photophobia.
- 10 % of the children were brought with photophobia and lacrimation, where marked enlargement of eyes was either absent or unnoticed by the parents.
- 40 % of the children in the study group had IOP of 21 to 30 mmHg and 40 % had IOP of 31 to 40 mmHg.
- 15 % of them had IOP above 40 and 5 % had less than 20mm Hg.
- Only 5 % of the eyes had clear cornea. 62.5 % of eyes had mild haze where fundus could still be visualized.
- 32.5% had severe haziness where it was not possible to visualize the fundus.

- This is important in the view of surgical management since Goniotomy, which is a successful initial line of management, can be performed only in patients who have clear cornea to allow adequate visualization of the angle structures.
- Blood samples were collected from patients diagnosed to have Primary Congenital Glaucoma.
- The study population who attend our tertiary centre represents the south Indian population.
- Genomic DNA was isolated using Qiagen kit. The isolated DNA from the samples were checked using agarose gel electrophoresis.
- We used GAPDH primer at annealing temperature 60°C to confirm the presence and quality of genomic DNA.
- Using the primers exon 2 was amplified by PCR technique and was sequenced.
- PCR products were then purified with the Qiagen gel/ PCR purification kit, and sequenced and analyzed for SNPs.
- Referral CYP1B1 gene was obtained from GenBank accession number U56438.
- Multiple Sequence Alignment was done using CLUSTAL W2 to analyse the significance of mutations.
- Then the sequence was analyzed comparing the CYP1B1 gene with the amplified products.
- Presence of Single Nucleotide Polymorphism was identified in two samples.
- The analysis was done by comparing the sequence of earlier reported exon with the amplicon under study obtained by sequencing.

- CYP1B1 mutations in PCG individuals suggest the presence of transition mutations that was analysed by conceptual translation (Bassem A. Bejjani et al, 1998)

CONCLUSION

PCG is one of the common causes of childhood blindness and its genetic etiology has been established. Molecular genetics has greatly enhanced our understanding of the molecular basis of this disorder. The underlying genes and the pathogenic mutations thereof can be identified.

The technological advances in molecular diagnostics and genetics can aid us to characterize pathologic gene changes providing further insight into the molecular pathogenesis of these disorders. In this regard, the incidence of PCG is one in every 10000-15000 live births and is bilateral in up to 80% of cases.

Further, it is interesting to note that most cases are sporadic (90%). However, in the remaining 10% there appears to be a strong familial component. Hence, our study attempted to understand the prevalence of PCG in the South Indian population as limited literature is available and does not cover data on all the reported PCG gene loci.

Even though three different loci have been mapped for PCG, mutations in Cytochrome P450 (CYP1B1; GLC3A) are the most predominant cause of disease and are reported in various ethnic backgrounds. Confirmation of linkage between CYP1B1 and PCG in different populations have verified the GLC3A locus (CYP1B1) as a major cause of PCG accounting for 85%–90% of all familial cases and 27% of sporadic cases.

Moreover, PCG transmission follows an autosomal-recessive inheritance pattern and has both Mendelian and multifactorial genetic-causative traits.

Common Single Nucleotide Polymorphisms which are suggestive of published CYP1B1 mutations in PCG individuals are found in sample 1 and sample 7 of the patients included in this study group. Extensive studies to determine the prevalence of CYP1B1 mutation in Primary Congenital Glaucoma in India, where there are multiple ethnic groups, are yet to be done. Only such large-scale multi-centric studies can establish the prevalence of such genetic mutations, and can aid in the development of genetic markers. Hence, the current study attempts to show some putative mutations in the population included in it.

PCG patients and/or their relatives can be given an option for genetic evaluation in order to understand the disease well from research point of view as well as help the patient and/ or patient's relatives to take appropriate decisions regarding the disease. Molecular diagnostic approaches are likely to improve the diagnostic and management strategies of PCG dramatically over the next few decades.

Genetic testing and molecular diagnostics have many new applications. It helps the clinician, patient and his/her family to take further decisions. Genetic testing aids in understanding the disorder thereby improving medical care, and the future is foreseen to yield continued advances in this direction. In the coming years, genetic counselling will be one of the important areas in PCG patient management.

PART III

BIBLIOGRAPHY

1. Becker-Shaffer's Diagnosis and Therapy of the Glaucomas
2. Parsons' diseases of the eye
3. System of ophthalmology- Sir Stewart Duke Elder - Vol III
4. Shaffer RN, Weiss DI. Congenital and paediatric glaucomas. CV Mosby: St. Louis; 1970.
5. Anderson JR. Hydrophthalmia or congenital glaucoma: its causes, treatment, and outlook. Cambridge University Press: London; 1939.
6. Barkan O. Technique of goniotomy. Arch Ophthalmol 1938; 19:217–221.
7. Burian HM. A case of Marfan's syndrome with bilateral glaucoma. With a description of a new type of operation for developmental glaucoma (trabeculotomy ab externo). Am J Ophthalmol 1960; 50:1187–1192.
8. The Pediatric Glaucomas, Anil K Mandel, Peter A Netlend
9. DeLuise VP, Anderson DR. Primary infantile glaucoma (congenital glaucoma). Surv Ophthalmol 1983; 28:1–19.
10. Hoskins HD Jr, Shaffer RN, Hetherington J. Anatomical classification of the developmental glaucomas. Arch Ophthalmol 1984; 102:1331–1336.
11. Francois J. Congenital glaucoma and its inheritance. Ophthalmologica 1972; 181:61–73.
12. Genicek A, Genicekova A, Ferak V. Population genetical aspects of primary congenital glaucoma. I. Incidence, prevalence, gene frequency, and age of onset. Hum Genet 1982; 61:193–197.
13. Jaffar MS. Care of the infantile glaucoma patient. In: Reineck RD, ed. Ophthalmol Annual. Raven Press: New York; 1988:15.

14. Molecular Vision 2011; 17:2911-2919 Screening of CYP1B1 and LTBP2 genes in Saudi families with primary congenital glaucoma: Genotype-phenotype correlation
15. Dandona L, Williams JD, Williams BC, Rao GN. Population-based assessment of childhood blindness in Southern India. Arch Ophthalmol 1998; 116:545–546.
16. Sarfarazi M, Akarsu AN, Hossain A. Assignment of a locus (GLC3A) for primary congenital glaucoma (buphthalmos) to 2p21 and evidence for genetic heterogeneity. Genomics 1995; 30:171–177.
17. Akarsu AN, Turacli ME, Aktan SG, et al. A second locus (GLC3B) for primary congenital glaucoma (buphthalmos) maps to the 1p36 region. Hum Mol Genet 1996; 5:1199–1203.
18. Sarfarazi M, Stoilov I. Molecular genetics of primary congenital glaucoma. Eye 2000; 14:422–428
19. Anderson DR. The development of the trabecular meshwork and its abnormality in primary infantile glaucoma. Trans Am Ophthalmol Soc 1981; 79:458–485.
20. Worst JGF. The pathogenesis of congenital glaucoma. An embryological and goniosurgical study. Charles C. Thomas: Springfield; 1966.
21. Hansson HA, Jerndal T. Scanning electron microscopic studies on the development of the iridocorneal angle in human eyes. Invest Ophthalmol 1971; 10:252–265
22. Shields MB. Axenfeld–Rieger syndrome. A theory of mechanism and distinctions from the iridocorneal endothelial syndrome. Trans Am Ophthalmol Soc 1983; 81:736–784.
23. Mann I. The development of the human eye, 3rd edn. Cambridge University Press: Cambridge; 1964

24. Allen L, Burian HM, Braley AE. A new concept of the development of the anterior chamber angle. Its relationship to developmental glaucoma and other structural anomalies. *AMA Arch Ophthalmol* 1955; 53:783–798
25. Barkan O. Pathogenesis of congenital glaucoma. Gonioscopic and anatomic observation of the angle of the anterior chamber in the normal eye and in congenital glaucoma. *Am J Ophthalmol* 1955; 40:1–11.
26. Maumenee AE. Further observations on the pathogenesis of congenital glaucoma. *Am J Ophthalmol* 1963; 55:1163–1176.
27. Hoskins HD Jr, Kass MA. *Becker-Shaffer's diagnosis and therapy of the glaucomas*, 6th edn. CV Mosby: St. Louis; 1989.
28. Kwitko ML. The pediatric glaucomas. *Int Ophthalmol Clin* 1981; 21:199–222
29. Scheie HG. Symposium on congenital glaucoma: Diagnosis, clinical course and treatment other than goniotomy. *Trans Am Acad Ophthalmol* 1955; 59: 309
30. Morin J: Primary congenital glaucoma: diagnosis and therapy. In: Cairns J, editor: *Glaucoma*, London, Grune & Stratton, 1986.
31. Waring GO, Laibson PR, Rodriguez M. Clinical and pathological alteration of Descemet's membrane with emphasis on endothelial metaplasia. *Surv Ophthalmol* 1974
32. Hass J. Principles and problems of therapy in congenital glaucoma. *Invest Ophthalmol* 1968; 7:140.
33. Worst JGF. The pathogenesis of congenital glaucoma, an embryological and goniosurgical study. CC Thomas: Springfield; 1966
34. Quigley HA. Childhood glaucoma: Results with trabeculotomy and study of reversible cupping. *Ophthalmology* 1982; 89:219–226.

35. Bailey PL. Timolol and postoperative apnea in neonates and young infants.
Anesthesiology 1984; 61:622
36. Bowman RJ, Cope J, Nischal KK. Ocular and systemic side effects of brimonidine 0.2% eye drops (Alphagan) in children. Eye 2004; 18:24–26
37. . Morgan KS, Black B, Ellis FD, Helveston EM. Treatment of congenital glaucoma. Am J Ophthalmol. 1981;92:799–803
38. The Glaucoma volume 2 Tarek shaarawy, Mark Sherwood
39. Gonioscopy-assisted transluminal trabeculotomy, ab interno trabeculotomy: technique report and preliminary results, Grover DS, Godfrey DG, Smith O, Feuer WJ, Montes de OcaI, Fellman RL, Ophthalmology. 2014 Apr; 121(4):855-61.
40. Mandal AK, Prasad K, Naduvilath TJ. Surgical results and complications of mitomycin C-augmented trabeculectomy in refractory developmental glaucoma. Ophthalmic Surg Lasers.1999; 30:473–80.
41. Bassem A. Bejjani et al, 1998 Hum Mol Genet.

PROFORMA

Name:

Age:

Sex:

IP no:

Address:

Registration Number:

Contact number:

Informer: mother/father/relative/others

Reliability of the Informer:

Presenting complaints:

History of present illness:

Complaints	Duration
Watering	
Inability to see bright light	
Defective vision	
Increased size of the eye balls	

Past history:

H/O treatment for Glaucoma

H/O Ocular surgery

Family history:

H/O similar complaints in the Family

Family Pedigree**Marital history:****(Consanguinity)****Birth history:****GENERAL EXAMINATION:**

Vital data:

Pulse rate:

Blood pressure:

SYSTEMIC EXAMINATION:**OCULAR EXAMINATION**

Parameters	Right eye	Left eye
Visual acuity		
Anterior segment examination with slit lamp		
Corneal diameter		
Fundus examination		
Intra ocular pressure measurement by Icare/Schiotz		
Gonioscopy (if possible)		

INVESTIGATIONS: Blood sample for Genetic Analysis

GENETIC ANALYSIS REPORT:

MASTER CHART

SAMPLE NO	NAME	IP NO	AGE	CURRENT AGE	SEX	SYMPTOMS	SYSTEMIC ILLNESS	FAMILY HISTORY	CONSANGUINITY	RE Vn AT INITIAL PRESENTATION	LE Vn AT INITIAL PRESENTATION	IOP RE	IOP LE	CORNEA DIAMETER RE	CORNEA DIAMETER LE	CORNEA RE	CORNEA LE	FUNDUS RE	FUNDUS LE
1	LATHISH	42387	1M	1Y	M	B,P,L	NIL	NIL	2ND DEG	-	-	45	40	H13 V13	H15 V15	MH	MH	0.4	0.7
2	ILAVARASI	54231	6M	2Y	F	B	NIL	NIL	NIL	F+	F+	45	24	H 14 V 16	H12 V12	SH	MH	NV	0.5
3	SANJAY	87564	10M	2Y	M	B,P,L	NIL	NIL	NIL	F+	F+	24	50	H12 V11	H12.5 V12.5	MH	MH	0.4	0.6
4	DINESH	32876	3M	1Y	M	B	NIL	NIL	NIL	F+	F+	34	30	H12 V13	H13 V13	MH	MH	0.9	0.9
5	NITHYA	87544	4M	3Y	F	B,P,L	NIL	NIL	2ND DEG	F+	F+	45	50	H15 V14	H14 V13	MH, HS	MH, HS	0.7	0.8
6	ROSHINI	68907	20D	1Y	F	B,P	NIL	NIL	NIL	-	-	26	29	H13 V13	H14 V13	SH	SH	NV	NV
7	GOUTHAM	34857	8 M	2Y	M	B	NIL	NIL	NIL	F+	F+	35	24	H13 V13	H14 V13	MH, HS	SH	0.7	NV
8	DINESH	27659	6M	3Y	M	P,L	NIL	NIL	NIL	F+	F+	26	35	H11 V11	H13 V13	CL	SH	0.6	NV
9	UDAY	90754	2M	1Y	M	B,P,L	NIL	NIL	2ND DEG	F+	F+	35	40	H14 V16	H14 V14	SH	SH	NV	0.6
10	VLAYA	33567	6M	1Y	F	B,P,L	NIL	NIL	NIL	F+	F+	35	40	H14 V14	H14 V13	SH	SH	NV	NV
11	SUMITHRA	22470	5D	1Y	F	B,P	NIL	NIL	NIL	-	-	31	37	H11 V11	H11 V11	MH	MH	NV	NV

SAMPLE NUMBER	NAME	IN-PATIENT NUMBER	AGE	CURRENT AGE	SEX	SYMPTOMS	SYSTEMIC ILLNESS	FAMILY HISTORY	CONSANGUINITY	RE Vn AT INITIAL PRESENTATION	LE Vn AT INITIAL PRESENTATION	IOP RE	IOP LE	CORNEA DIAMETER RE	CORNEA DIAMETER LE	CORNEA RE	CORNEA LE	FUNDUS RE	FUNDUS LE
12	SATHYAVANI	45667	9M	1 1/2Y	F	B,P,L	NIL	NIL	NIL	F+	F+	29	20	H13 V13	H10 V10	SH	CL	NV	0.4
13	SHANKARI	88764	3M	10M	F	B	NIL	NIL	2ND DEG	F+	F+	29	29	H12.5 V12	H12 V12	MH, HS	MH, HS	0.5	0.6
14	GANGA	21143	1M	6M	F	P,L	NIL	NIL	2ND DEG	-	-	26	23	H11 V12	H11 V11	MH, HS	MH, HS	0.5	0.5
15	REGINA	77709	3M	8M	F	B	NIL	NIL	3RD DEG	F+	F+	29	10	H14 V13	H10 V10	SH	CLEAR	NV	0.4
16	SURIYA	54336	10M	1 1/2Y	M	B,P,L	NIL	NIL	NIL	F+	F+	21	45	H111 V12	H12 V13	MH, HS	MH, HS	0.6	0.9
17	RAJESWARI	66812	10M	2Y	F	B,P	NIL	NIL	NIL	F+	F+	35	29	H13 V11	H12 V11	MH	MH, HS	0.6	0.9
18	SAARATHI	44214	5M	1Y	M	B	NIL	NIL	NIL	6,36	6,60	30	25	H12 V14	H15 V14	MH, HS	MH, HS	0.5	0.7
19	MUKLAN	77860	2M	4M	M	B	NIL	NIL	3RD DEG	F+	F+	33	36	H13 V13	H13 V13	MH, HS	MH, HS	0.6	0.6
20	MANOJ	22123	2M	6M	M	B,P,L	NIL	NIL	NIL	-	-	32	40	H14 V13.5	H14 V14	SH	SH	NV	NV

KEY TO MASTER CHART

Vn- VISION

IOP- INTRAOCULAR PRESSURE

H- HORIZONTAL

V- VERTICAL

SH- SEVERE HAZE

MH- MILD HAZE

HS- HAAB'S STRIAE

CL- CLEAR

B- BUPHTHALMOS

P- PHOTOPHOBIA

L- LACRIMATION

F+- FIXING THE EYES TO LIGHT

NV- NO VIEW

M- MONTHS

D- DAYS

Y- YEARS

ABBREVIATIONS AND SYMBOLS

PCG- primary congenital glaucoma

CD ratio- cup disc ratio

μl- microliter

bp - Base pairs

μg- microgram

DNA - Deoxyribonucleic acid

mM- millimolar

ml- millilitre

mg- milligram

ng- nanogram

dNTP - Deoxyribonucleoside triphosphate

ddNTP - Dideoxynucleoside triphosphate

rpm- rotation per minute

EDTA - Ethylene diamine tetra acetic acid

KCl – Potassium chloride

kDa - Kilodaltons

NaCl – Sodium chloride

PCR - Polymerase chain reaction

NH₄Cl – Ammonium chloride

RBC - Red blood cell

HCl – Hydro chloric acid

SNP – Single nucleotide polymorphism

EtBr - Ethidium Bromide

UV – Ultra violet