

**DIGITAL DENTAL SPLINTS IN ORTHOGNATHIC
SURGERY AND EVALUATION OF THEIR
ACCURACY OF FIT IN AN ANATOMICALLY
ARTICULATED MODEL**

Dissertation Submitted to
THE TAMILNADU Dr. M.G.R. MEDICAL UNIVERSITY

In partial fulfillment for the Degree of
MASTER OF DENTAL SURGERY



BRANCH III
ORAL AND MAXILLOFACIAL SURGERY
MAY 2018

**THE TAMIL NADU Dr. MGR MEDICAL UNIVERSITY
CHENNAI**

DECLARATION BY THE CANDIDATE

I hereby declare that this dissertation titled “**DIGITAL DENTAL SPLINTS IN ORTHOGNATHIC SURGERY AND EVALUATION OF THEIR ACCURACY OF FIT IN AN ANATOMICALLY ARTICULATED MODEL**” is a bonafide and genuine research work carried out by me under the guidance of **Dr.VEERABAHU.M, M.D.S.,IBOMS.**, Professor and Head, Department of Oral & Maxillofacial Surgery, Ragas Dental College and Hospital, Chennai.

Nambinayaki

Dr.NAMBINAYAKI.E.M

Post Graduate Student,

Department of Oral & Maxillofacial Surgery,

Ragas Dental College and Hospital,

Chennai.

Date: 29.1.2018


Place: Chennai

CERTIFICATE



This is to certify that this dissertation titled "DIGITAL DENTAL SPLINTS IN ORTHOGNATHIC SURGERY AND EVALUATION OF THEIR ACCURACY OF FIT IN AN ANATOMICALLY ARTICULATED MODEL" is a bonafide record of work done by Dr. NAMBINAYAKI.E.M under our guidance and to our satisfaction during her postgraduate study period 2015-2018.

This Dissertation is submitted to THE TAMILNADU Dr. M.G.R. MEDICAL UNIVERSITY, in partial fulfillment for the award of the Degree of MASTER OF DENTAL SURGERY – ORAL AND MAXILLOFACIAL SURGERY, BRANCH III. It has not been submitted (partial or full) for the award of any other degree or diploma.

Head of the Department and Guide:



Dr. VEERABAHU.M, M.D.S.,IBOMS.,
Professor and Head
Department of Oral &
Maxillofacial Surgery,
Ragas Dental College & Hospital,
Chennai.



Dr.N.S.Azhagarasan,M.D.S.,
Principal,
Ragas Dental College & Hospital,
Chennai.

PRINCIPAL
RAGAS DENTAL COLLEGE AND HOSPITAL
UTHANDI, CHENNAI-600 119.

Dr. M. VEERABAHU, MDS,IBOMS
Professor & HOD
Dept of OMFS
RAGAS DENTAL COLLEGE & HOSPITAL
Uthandi, Chennai - 600 119.

THE TAMIL NADU Dr. MGR MEDICAL UNIVERSITY
CHENNAI


PLAGIARISM CERTIFICATE

This is to certify the dissertation titled "DIGITAL DENTAL SPLINTS IN ORTHOGNATHIC SURGERY AND EVALUATION OF THEIR ACCURACY OF FIT IN AN ANATOMICALLY ARTICULATED MODEL" of the candidate Dr. NAMBINAYAKI.E.M for the award of MASTER OF DENTAL SURGERY in BRANCH III - Oral and Maxillofacial Surgery.

On verification with the urkund.com website for the purpose of plagiarism check, the uploaded thesis file from introduction to conclusion contains 6 percentage of plagiarism, as per the report generated and it is enclosed in Annexure - II.

Date: 29.1.2018


Place: Chennai



Dr.NAMBINAYAKI.E.M

Post Graduate Student,
Department of Oral & Maxillofacial Surgery,
Ragas Dental College and Hospital,
Chennai.

Guide sign with seal:



Dr.VEERABAHU.M, M.D.S.,IBOMS.,

Professor and Head
Department of Oral & Maxillofacial Surgery,
Ragas Dental College & Hospital,
Chennai.

Dr. M. VEERABAHU, MDS,IBOMS
Professor & HOD
Dept of OMFS
RAGAS DENTAL COLLEGE & HOSPITAL
Uthandi, Chennai - 600 119.

ACKNOWLEDGEMENT

*I thank **GOD** for His love, grace, mercy and wisdom which formed the foundation of my life and all my work.*

*I wish to thank my father **Mr Essakimuthu N** and my mother **Mrs Karunambikai P** for the sacrifices they made and for giving me a great foundation in my life and for being the most wonderful parents. I thank my brother **Mr Paramasivan E M** for being the pillar of my life and showering me love and encouragement. I sincerely thank my grandparents for believing in me & supporting me unconditionally.*

With deep satisfaction and immense pleasure, I present this work undertaken as a Post Graduate student specializing in Oral and Maxillofacial Surgery at Ragas Dental College and Hospital. I would like to acknowledge my working on this dissertation which has been wonderful and enriching learning experience.

*I convey my heartfelt gratitude and my sincere thanks to my Head of the department and my guide **Professor Dr M Veerabahu MDS IBOMS**, Department of Oral and Maxillofacial Surgery, Ragas Dental College and Hospital, Chennai for his exceptional guidance, tremendous encouragement, well timed suggestions, concern and motivation providing me with his immense patience in brightening years of my postgraduate program. I have been fortunate to study under his guidance and support. I thank you very much sir*

for guiding me in my thesis work and I am indebted towards you forever for all consideration you have shown towards me. Your presence in the department creates an aura which motivates me to reach heights. I would cherish these memories throughout my life.

*I would like to extend my heartfelt gratitude to **Professor Dr N S Azhagarasan**, Principal, Ragas Dental College and Hospital for allowing us to use the scientific literature and research facilities of the college and for providing the platform to meet such wonderful academicians and people.*

*I owe enormous gratitude to **Professor Dr Malini Jayaraj** for her invaluable guidance and support throughout my course. She has always been a source of provoking new thoughts in me. Her loving and caring nature lightened the burden of many hardships.*

*I wish to convey my heartfelt thanks to **Professor Dr B Vikraman**, a great teacher who has always been a source of inspiration. His way of looking at things three dimensionally has always given a touch of perfection. His subtle humour and comments have been thoroughly enjoyed throughout my post graduate life.*

*I would also thank my **Professor Dr J A Nathan** for everlasting inspiration, constant encouragement, constructive criticism and valuable suggestion conferred upon me throughout my postgraduate period.*

*I am greatly indebted to **Dr Radhika Krishnan** Anaesthesiologist, for imparting and sharing her vast experience in the field of medicine. I thank her for her valuable suggestion and constant encouragement through my postgraduate course.*

*I would especially like to thank **Dr Harish K M** for guiding me throughout my Post Graduate course as well as helping me in completing my thesis. I thank you sir for your constant support, patience and all the valuable suggestions and inputs that you gave me without which I would not have been able to finish my thesis on time.*

*I would like to thank **Dr John Nesan (Manager CTARS)**, for his exceptional support in training me and familiarizing me with the modules of MIMICS and inspiring me throughout the thesis and **Dr Kailasham** for familiarizing me the concepts of CBCT.*

*I am grateful and sincerely thankful to **Prof. Dr D. Shankar, Dr Sathya Bama, Dr Saneem and Dr Satish** Readers, for their vehement personal interest, wish and never-ending willingness to render generous help to me throughout my dissertation and post graduate with valuable advice.*

*I thank **Dr Seema Alice Mathew, Dr James Bhagat, Dr Naren Kumar**, Senior lecturers for their guidance, scholarly suggestion and whole-hearted support throughout my postgraduate course.*

*I thank **Dr Pankaj Chaturvedi, Dr Burhan, Dr Hitesh, Dr Hemanth,** Department of Head and Neck Oncology, Tata Memorial Hospital, Mumbai, **Dr Venkatesh, Dr Raghu** Department of surgical oncology, Cancer Institute Adayar, Chennai and **Dr Dhavapalani Alaagappan,** Department of Emergency Medicine, Apollo Hospitals, Greems Road, Chennai, for their vehement, valuable guidance and encouragement during my peripheral postings.*

*I would like to thank **Dr Frits Rangel, Dr Stefaan Berge, Dr Anne Marie Kuijpers Jatman, Dr Thomaas Maal** for inspiring me and giving their valuable advice.*

*I sincerely thank my batch mates, **Dr Sharif, Dr Senthil, Dr Narsimman** and **Dr Sharnu Siviah, Dr Nirmal** for their support, constructive criticism at every step and selfless co - operation during my dissertation. I wish them a successful career ahead.*

*I offer my sincere thanks to my senior's **Dr Nirmal tony, Dr Sriraman, Dr Vivek, Dr Nalini Sailaja, Dr Yasmin,** My Juniors **Dr Manoj kumar, Dr Stephen, Dr Ajith, Dr Alka, Dr Veera Raghavan, Dr Aravindh sai** for their encouragement and support during the course.*

*I sincerely thank **Mr Thavamani,** for helping in editing and printing of my thesis. I would also thank Theatre assistants **Mr Venugopal, Sis.Malathi** OT staffs, **Sis.Deepa, Sis.Laila, Sis. Leema, Sis.Mala** for helping me throughout my post graduate period.*

I would like to dedicate this dissertation to my family and who always wish for me to reach great heights and achieve greater goals in my life.

ABSTRACT

PURPOSE:

The purpose of this prospective clinical study is to evaluate the accuracy of fit of digital dental splints in an anatomically articulated model on which

model surgery is performed. The intermediate 3D printed splints were verified in an anatomical articulator.

MATERIALS AND METHODS:

A total of 4 patients (Table 1,2) who were willing to undergo orthognathic surgery (Graph 2) were included in this study. The methodology of the study were as follows:

A Cone Beam Computed Tomography scan was obtained with fiducial titanium markers of standardized dimensions glued to the attached gingiva (Figure 57) for all patients excluding one patient for whom a medical Computed Tomography scan was taken. The upper and lower impressions were made, and models prepared (Figure 58). These dental casts were scanned with an optical scanner and the digital dental casts were saved as stl files (Figure 56 A, B). The CBCT scans and the digital dental scans were imported into MIMICS software (Version 17.0 Leuven, Belgium). Planned virtual osteotomy was performed virtually on the 3D reconstructed models after accurate superimposition based on the fiducial titanium markers (Figure 30,31). Intermediate splints were virtually designed (Figure 36,37,38), and 3D printed by importing into 3D printer (Inkjet printing) in our study.

RESULTS:

Out of the four patients, one patient with Hemifacial Microsomia had extensive bleeding during a medial cut on the mandibular ramus due to which

the planned mandibular surgery was not performed. One patient was previously treated for temporomandibular joint ankylosis, who had no complications intra-operatively during orthognathic surgery. The fit of the digital dental splint was subjectively superior to the conventional acrylic splints and therefore was clinically more acceptable.

CONCLUSION:

The results of this study indicates that virtual planning and 3D printing of the intermediate splints have the following advantages:

1. An overall decrease in the time required for conventional planning in orthognathic surgery.
2. Aids in better understanding of the existing deformity in all dimensions.
3. Ensures more accuracy in splint fabrication, aiding in superior precision in positioning of the osteotomized segments.
4. Minimizes the errors due to conventional two-dimensional radiographs.
5. The use of fiducial markers in our study makes the superimposition process more accurate and avoids inaccuracies due to superimposition.

KEYWORDS: CONE BEAM COMPUTED TOMOGRAPHY, ORTHOGNATHIC SURGERY, VIRTUAL PLANNING, DIGITAL SPLINTS, FIDUCIAL TITANIUM MARKERS.

CONTENTS

S.NO	TITLE	PAGE NO
1.	INTRODUCTION	1
2.	AIMS AND OBJECTIVES	6
3.	REVIEW OF LITERATURE	7

4.	MATERIALS AND METHODS	29
5.	RESULTS	35
6.	DISCUSSION	42
7.	SUMMARY AND CONCLUSION	60
8.	BIBLIOGRAPHY	63
9.	ANNEXURE	-

LIST OF TABLES

TABLE NO.	TITLE	PAGE NO.
1.	DEMOGRAPHIC DATA	39

2.	SURGICAL PLAN	40

LIST OF GRAPHS

S.NO	GRAPHS	PAGE NO.
1.	GENDER DISTRIBUTION IN OUR STUDY	41

2.	PERECNTAGE DISTRIBUTION OF SINGLE JAW AND BI-JAW SURGERY IN OUR STUDY	41

LIST OF FIGURES

S.NO	PHOTOGRAPHS
1.	PRE-OPERATIVE FRONTAL PHOTOGRAPH AT REST
2.	PRE-OPERATIVE FRONTAL PROFILE – AT SMILE
3.	PRE-OPERATIVE RIGHT OBLIQUE VIEW
4.	PRE-OPERATIVE RIGHT LATERAL VIEW
5.	PRE-OPERATIVE LEFT OBLIQUE VIEW

6.	PRE-OPERATIVE LEFT LATERAL VIEW
7.	PRE-OPERATIVE OCCLUSION-RIGHT
8.	PRE-OPERATIVE OCCLUSION-LEFT
9.	PRE-OPERATIVE OCCLUSION-FRONTAL VIEW
10.	PRE-OPERATIVE MAXILLARY OCCLUSAL VIEW
11.	PRE-OPERATIVE MANDIBULAR OCCLUSAL VIEW
12.A	PRE-OPERATIVE MEASUREMENT OF MAXILLARY CASTS PRIOR-MODEL SURGERY- VERTICAL PLANE
12.B	POST-OPERATIVE MEASUREMENT OF MAXILLARY CAST-VERTICAL PLANE
13.A	PRE-OPERATIVE MEASUREMENT OF MAXILLARY CASTS PRIOR MODEL SURGERY-ANTEROPOSTERIOR PLANE
13.B	POST-OPERATIVE MEASUREMENT OF MAXILLARY CASTS – ANTEROPOSTERIOR PLANE
14.A	PRE-OPERATIVE MEASUREMENT OF MAXILLARY CASTS PRIOR MODEL SURGERY- TRANSVERSE PLANE
14.B	POST-OPERATIVE MEASUREMENT OF MAXILLARY CASTS- TRANSVERSE PLANE
15.	3D RECONSTRUCTED FRONTAL SKULL- PRE-OPERATIVE VIEW
16.	PRE-OPERATIVE 3D RECONSTRUCTED SKULL- RIGHT LATERAL VIEW
17.	PRE-OPERATIVE 3D RECONSTRUCTED SKULL- LEFT LATERAL VIEW

18.	DIGITAL DENTAL MAXILLARY CAST-RIGHT LATERAL VIEW
19.	DIGITAL DENTAL MAXILLARY CAST-LEFT LATERAL VIEW
20.	DIGITAL DENTAL MAXILLARY CAST-FRONTAL VIEW
21.	PRE-OPERATIVE SKULL WITH THE FIDUCIAL MARKERS AFTER SEGMENTING THE SKULL AND MAXILLA
22.	PRE-OPERATIVE SKULL WITH MARKERS- RIGHT LATERAL VIEW
23.	PRE-OPERATIVE SKULL WITH MARKERS- LEFT LATERAL VIEW
24.	SUPERIMPOSITION OF DIGITAL DENTAL CAST AND SKULL BASED ON THE FIDUCIAL MARKERS- FRONTAL VIEW
25.	SUPERIMPOSITION OF DIGITAL DENTAL CASTS AND SKULL- RIGHT LATERAL VIEW
26.	SUPERIMPOSITION OF DIGITAL DENTAL CASTS AND SKULL - LEFT LATERAL VIEW
27.	ANTERIOR MAXILLARY OSTEOTOMY LINES
28.	ANTERIOR MAXILLARY OSTEOTOMY REFERENCE FRAMES AFTER EXTRACTION OF FIRST PREMOLAR
29.	ANTERIOR MAXILLARY OSTEOTOMY 4MM- RIGHT LATERAL VIEW
30.	POST-OPERATIVE SKULL FRONTAL VIEW AFTER ANTERIOR MAXLLARY OSTEOTOMY OF 4MM
31.	LEFORT I MAXILLARY SETUP OSTEOTOMY REFERENCE

	FRAME
32.	LEFORT I MAXILLARY SET-UP 5MM RIGHT LATERAL VIEW
33.	LEFORT I MAXILLARY SET-UP 5MM LEFT LATERAL VIEW
34.	PRE-OPERATIVE SKULL MEASUREMENTS BEFORE LEFORT I OSTEOTOMY MEASURED FROM THE TIP OF CENTRAL INCISOR TO REFERENCE FRAME- 33MM
35.	POST-OPERATIVE MEASUREMENTS AFTER LEFORT I MAXILLARY SET-UP 5MM MEASURED FROM TIP OF CENTRAL INCISOR TO REFERENCE FRAME-28MM
36.	VIRTUAL SPLINT FABRICATION ON POST-OPERATIVE VIRTUAL SKULL-FRONTAL VIEW
37.	VIRTUAL SPLINT RIGHT LATERAL VIEW
38.	VIRTUAL SPLINT LEFT LATERAL VIEW
39.A	INTERMEDIATE SPLINT WITH POST-OPERATIVE MAXILLARY OCCLUSAL IMPRINTS
39.B	INTERMEDIATE SPLINT WITH POST-OPERATIVE MANDIBULAR OCCLUSAL IMPRINTS
40.A.	INTERMEDIATE SPLINT FABRICATED IN CONVENTIONAL SETUP-FRONTAL VIEW
40.B.	INTERMEDIATE SPLINT FABRICATED IN CONVENTIONAL SETUP-RIGHT LATERAL VIEW
40.C.	INTERMEDIATE SPLINT FABRICATED IN CONVENTIONAL SETUP-LEFT LATERAL VIEW
41.A.	INTERMEDIATE SPLINT MANUFACTURED BY 3D PRINTING- FRONTAL VIEW

41.B.	INTERMEDIATE SPLINT MANUFACTURED BY 3D PRINTING-RIGHT LATERAL VIEW
41.C.	INTERMEDIATE SPLINT MANUFACTURED BY 3D PRINTING-LEFT LATERAL VIEW
42.	CONFIRMATION OF THE FACEBOW TRANSFER ON A LATERAL CEPHALOGRAM
43.	PREDICTION TRACING ON LATERAL CEPHALOGRAM
44.	INTRA-OPERATIVE FIT OF THE DIGITAL INTERMEDIATE SPLINT-RIGHT LATERAL VIEW
45.	INTRA-OPERATIVE FIT OF THE DIGITAL INTERMEDIATE SPLINT-LEFT LATERAL VIEW
46.	INTRA-OPERATIVE FIT OF THE DIGITAL INTERMEDIATE SPLINT-FRONTAL VIEW
47.	POST-OPERATIVE FRONTAL VIEW
48.	POST-OPERATIVE RIGHT LATERAL VIEW
49.	POST-OPERATIVE LEFT LATERAL VIEW
50.	POST-OPERATIVE OCCLUSION-RIGHT LATERAL VIEW
51.	POST-OPERATIVE OCCLUSION- LEFT LATERAL VIEW
52.	POST-OPERATIVE OCCLUSION-FRONTAL VIEW
53.	KODAK CARESTREAM CBCT SCANNER
54.	STRATASYS INKJET PRINTER OBJECT 500
55.	HAPTIC DEVICE
56.A.	DIGITAL DENTAL MODELS- MAXILLA
56.B	DIGITAL DENTAL MODELS- MANDIBLE

57.	FIDUCIAL TITANIUM MARKERS GLUED TO THE ATTACHED GINGIVA
58.	IMPRESSIONS OF MAXILLA AND MANDIBLE WITH THE FIDUCIAL MARKERS TRANSFERRED TO THEM

INTRODUCTION

“Smile is a curve that sets everything straight”- for which both the orthodontist and the surgeon strive. An aesthetic smile is a reflection of confidence and inner beauty. Harmony is one of the main objectives in any surgery or orthodontic therapy and this harmony must be maintained in smile.

Various dentofacial abnormalities in the following planes, vertical, transverse and anteroposterior modify the harmony of facial aesthetics of an individual. Obwegeser^[31] quoted that vertical maxillary deficiency can cause a feeling of edentulism for patients, whereas vertical maxillary excess can cause excess gum exposure ^[31]. Orthognathic (Greek word, Ortho: to straighten, gnathos: jaw) surgery, a subset of craniofacial surgery is the art and science of diagnosis, treatment planning and execution of the treatment plan to correct musculoskeletal, dento-osseous, soft tissue deformities of jaws and associated structures. The three important tissue groups in orthognathic surgery include, the facial soft tissue (skin, connective tissues, fat and muscles), facial skeleton, dentition and are referred to as **TRIAD** and this plays a decisive role in planning an orthognathic surgery ^[22]. The history of orthognathic surgery dates back to 1849 when HULLIHEN performed the first orthognathic surgery for a patient with mandibular deformity. It was not until the demonstration of the possibility of repositioning the maxilla in stable position by HUGO L. OBWEGGESER in 1965, the speciality of orthognathic surgery was fully established. Obwegeser in 1970 reported the simultaneous repositioning of maxilla and mandible which marked the beginning of modern era in orthognathic surgery ^[31].

PLANNING IN ORTHOGNATHIC SURGERY

The pre-operative planning must ensure precise diagnosis of underlying dento-skeletal deformity and device a treatment plan which is accurately

reproducible in the operating room. The traditional diagnostic work-up in planning for orthognathic surgery involves the following: -

1. Clinical Examination and photographs
2. Radiologic Investigations and cephalometric analysis
3. Impression making and plaster model preparations
4. Facebow transfer and articulation in patient's occlusion
5. Mock model surgery
6. Manual splint fabrication

SHORTCOMINGS AND CHALLENGES IN CONVENTIONAL ORTHOGNATHIC SURGICAL PLANNING

The challenges faced by a surgeon during the planning process can be classified as: -

1. Challenges in Clinical examination and Diagnosis
2. Challenges in treatment planning
3. Challenges in execution of the planned treatment

PROBLEMS IN CONVENTIONAL ORTHOGNATHIC SURGICAL PLANNING

1. Errors in clinical evaluation
2. Radiographic errors
3. Errors in impression making
4. Errors in face-bow transfer

5. Errors in model surgery
6. Errors in splint fabrication

DIGITAL PLANNING IN ORTHOGNATHIC SURGERY

Surgery is a speciality which is driven by results. Surgeons have turned to technology to improve their outcomes and achieve high quality results. Computer assisted surgery is an umbrella term to describe all forms of surgical planning or execution that includes advanced imaging, various softwares, virtual planning, 3D printing and image guided surgery. Computer assisted surgery of cranio-maxillofacial skeleton exists in two forms namely,

1. Template guided surgery
2. Image guided surgery (Navigational Surgery)

ADVANTAGES OF DIGITAL PLANNING

1. Three-dimensional representation of patient's data exploring the 'ANATOMIC TRUTH'.
2. Minimizing the two-dimensional radiographic errors.
3. Virtual planning eliminates the need for a facebow transfer and manual model surgery in plaster models, thus eliminating the flaws in them.

4. The errors incorporated in manufacturing conventional manual splints are eliminated as the splints can be planned virtually and manufactured by 3D printing.
5. 3D virtual planning is a powerful communication tool.

The image quality obtained by a CBCT is however not sufficient for precise representation of occlusal configuration and intercuspation^{[8], [9], [48], [50]}. With the shift in data type from analog to digital, the dental stone model is replaced by Digital dental models^[32] (Figure 56). By linking these data sets, the 3D patient model, including bony skeleton, dentition and facial soft tissues (untextured) can be created^[32]. In patients with orthodontic brackets or metallic restorations, surface-based image fusion becomes highly inaccurate due to improper visualization of structures^[9]. Several studies have used intra-oral reference devices or bite jigs for the fusion, however these methods are time consuming and most of the bite-jigs cause soft tissue distortion which inhibits reliable judgement of the soft tissues at rest^{[6], [58]}.

To overcome these difficulties, we have incorporated small fiducial titanium markers of standardized dimensions (1*1.5*2mm) that is placed on the attached gingiva of the patient for the image fusion process (Figure 57).

The aim of our study was to evaluate the accuracy of fit of digital dental splints in an anatomically articulated model on which the intended model surgery would be performed. Previous studies compared the digital dental splints with conventional manual splints and considered this comparison as

ground truth, which was not actually correct^[57]. Few studies reported mean errors which may underestimate the magnitude of error^[57]. Therefore, our study is carried out in the intention to compare the accuracy of fit of 3D printed splints in an anatomically articulated model in which planned manual model surgery would be performed.

AIMS AND OBJECTIVES

The aim of this prospective clinical study is to evaluate the accuracy of fit of digital dental splints (intermediate splints) used in orthognathic surgery in anatomically articulated model.

The digital dental splints were evaluated intra-operatively and in anatomically articulated models in which the intended model surgery is performed for accuracy of fit.

REVIEW OF LITERATURE

W.Wayne Babcock (1909)⁵⁵ in their review discussed the historical evolution of orthognathic surgery and the importance of planning in orthognathic surgery. He in this review described the first orthognathic surgery for a patient with congenital deformity under general anaesthesia and introduced the use of plaster casts in orthognathic surgery.

Graham Rabey (1970)¹⁷ in their review discussed the importance of craniofacial morphoanalysis and the present available 3D technology to analyse the craniofacial morphoanalysis.

G N Hounsfield (1973)¹³ reviewed a technique on X-ray transmission through head at multiple angles presented a series of pictures of slices of cranium. He found that the system was 100 times more sensitive than conventional x-rays to an extent that variations in soft tissue of nearly same density can be displayed.

Edward Ellis (1990)¹¹ and coworkers in their review evaluated the accuracy of conventional model surgery in 20 maxillary and mandibular casts in bimaxillary cases. The results of their investigation suggested that maxillary model surgery performed in classic conventional manner was variable, frequently imprecise and in some instances induced extreme errors.

Willam Arnett et al (1993)¹⁴ in their review discussed about the reliance of cephalometric analysis leading to esthetic problems. They focussed only on the anteroposterior dimensions of face whereas a complete analysis required assesment of vertical and transverse planes.

Nattestad.A et al (1994)¹ in their review illustrated that the actual result of orthognathic surgery may be different from the planned result because of the erroneous transition of reference lines and points between model surgery

and operation. The error varied between 3.7 and 3.3 mm for movements of the maxilla from -10 to 10 mm horizontally and vertically. They proposed that the application of current and future computer graphics systems to the planning procedure could be a major advancement.

Polido and co-workers (1991)³⁴ investigated the predictability of maxillary central incisor position in 100 consecutive patients and found an average discrepancy of 2.2mm vertically and 1.8mm horizontally.

Zonneveld et al (1994)¹¹ reviewed existing 3D printing techniques. The best known were milling of polyurethane foam and stereolithography. Surgical simulation consisted of performing the surgery on these accurate models.

Vander Stolen et al (1996)²⁰ in their paper introduced a simulation system developed in a computer aided design (CAD) environment, where in a 3-D mathematical model of the skull was created and possible actions such as osteotomy, bending, rotation, translation and removal were described and stimulated.

E. W. Steinhauser (1996)¹⁰ in his review described the historical development of orthognathic surgery and the most significant authors who has contributed to orthognathic surgery. He also emphasized on the need for a precise planning in orthognathic surgery.

Dieter Dirksen et al (1998)⁸ in their article described about three-dimensional acquisition and visualization of dental arch features from optically digitized models. They identified that the characteristic features like cusp tips can be identified and located semi-automatically from the digital data set and

the results were visualized as interactively controllable 3D computer graphics, which helped to make spatial relations clear.

Quintero JC et al (1999)²³ in their review discussed the evolution of craniofacial imaging in orthodontics and reviewed the limitations of current methods, including the two-dimensional representation of three-dimensional anatomy and associated geometric errors. They found that three-dimensional computed tomography can be considered a partial solution to these limitations, but imaging costs, radiation exposure, and lack of soft tissue representation would make it unacceptable for routine orthodontics for which solution might be achieved through digital processing of contemporary imaging technologies that would extend their capabilities, overcome many of their limitations, and result in an increase in the amount of relevant information obtained. They concluded that these models will be interactive, linked to knowledge databases, and will provide the clinician with answers to pertinent questions. These advances in imaging were likely to enhance the accuracy and reliability of orthodontic diagnosis and treatment planning and would be of importance in both clinical practice and research.

James Xia et al (2001)²¹ in their paper presented a virtual reality workbench for surgeons to perform virtual orthognathic surgical planning and soft tissue predictions in three dimensions in 14 patients. They combined 3D visualization virtual reality, colour video-imaging technique planning and simulation to solve bone-soft-tissue relationship problem and provide the

surgeon with ideal virtual-reality workbench for orthognathic surgical planning and stimulation.

William E.Harrell et al (2002)⁵⁶ in their article discussed the importance of visualizing patients “anatomic truth” using 3D digital modelling and measured treatment outcomes more accurately and to monitor changes over time (fourth dimension).

Meyer et al (2002)⁵² performed a study involving three patients with complex craniofacial malformations who required orbital resection. They confirmed that computer-assisted stimulation was a reliable and useful tool which improved surgical planning and helped to evaluate surgical outcome. They stated that the disadvantage of this technique was high cost and lack of technical personnel.

Delong and coworkers (2003)³⁸ in their study on impact of digital dental models, compared standard measurements from actual object and from stone model to measurements obtained from digitized model on 10 casts which were scanned by Comet 100 optical scanner using Virtual dental patient system. Accuracy \pm precision for the casts and impressions was $0.024 \pm 0.002\text{mm}$ and $0.013 \pm 0.003\text{mm}$, respectively. Their results showed that digital models were clinically acceptable.

Meredith L. Quimby et al (2003)³⁷ in their study determined the accuracy, reproducibility, efficacy and effectiveness of measurements made on computer based digital models and conventional plaster models by comparing

them to a plastic model occlusion. They concluded that measurements made from computer-based models were accurate and reliable with the differences ranging less than 0.5mm compared to conventional plaster models.

Gateno et al (2003)¹⁵ in their study on 7 volunteers compared the precision of computer generated surgical splints and conventional splints by quantifying the airspace between teeth and splint by slicing the impression materials, acrylic and stereolithographic splints cross sectionally. They concluded that the average difference between conventional and stereolithographic splints were 0.24 +/- 0.23-millimetre square. The correlation coefficient (*r*) of the airspace areas between the stereolithographic and conventional acrylic splints was 1.00, and the regression coefficient was 1.03 (*P* less than 0.01). The results indicated that the stereolithographic splints, generated by the authors CAD/CAM technique, had a high degree of accuracy. They further stated that traditional plaster dental model surgery will be replaced by computer-assisted surgical planning.

Gateno et al (2003)¹⁶ in their study developed a technique for creating computerized skull model and evaluated their accuracy by assessing the bone to bone, tooth to tooth and bone to tooth measurements between computerized composite skull and dry skull. Their study showed the feasibility of creating computerized composite skull model and its accuracy. They concluded that the mean difference between computerized composite skull model and dry skull was 0.5 +/- 0.6mm for bone to bone, 0.1 +/- 0.2 mm for tooth to tooth and 0.2 +/- 0.3mm for bone to tooth measurements which was statistically insignificant.

Santoro and coworkers (2003)¹¹ in their study in 76 patients demonstrated significant difference between plaster and digital model measurements with respect to both tooth width and overbite. The results showed a statistically significant difference between the 2 groups for tooth size and overbite, with the digital measurements smaller than the manual measurements. However, the magnitude of these differences ranged from 0.16mm to 0.49mm (p value 0.02) and can be considered clinically not relevant.

Emeka Nkenke et al (2004)⁹ in their study determined the limits of accuracy of fusion of optical three-dimensional (3D) imaging and computed tomography (CT) with and without metal artefacts in an experimental setting and showed the application of this hybrid system in 3D orthognathic surgery simulation. They found that mean distance between the corresponding data points of CT and optical 3D surface images of dental arches was 0.1262 +/- 0.0301mm and 0.2671 +/- 0.0580mm, respectively, for the plaster casts without and with metal restorations which was statistically significant. The mean difference for the patient case was 0.66 +/- 0.49mm and 0.56 +/- 0.48 mm for mandible and maxilla, respectively, calculated between CT and optical surface data. They concluded that the accuracy of the fusion of 3D CT surface data and optical 3D imaging was significantly reduced by metal artefacts.

Mathew et al (2004)¹⁹ in their review emphasized on advent of digital dental models and their advantages. They also emphasized on the abilities of

the viewing software and the basic requirements needed to utilize digital models.

Kostas Tsiklakis et al (2005)⁵⁰ in their article measured the absorbed dose of CBCT and interpreted the total effective dose in a CBCT. They concluded that the use of CBCT for maxillofacial imaging results in reduced absorbed and effective dose. The absorbed dose of bone marrow of mandible was found to be 1.67mGy and effective dose was 0.035mSv in non-shielding technique and absorbed dose of 1.64mGy in bone marrow of mandible and effective dose of 0.035mSv in shielding technique.

Filip Schutyser and co-workers (2005)⁴⁰ in their study on 7 patients with amalgam fillings introduced a double scan technique for visualization of dental occlusion and a technique for the fusion of both the scans using spherical gutta percha markers incorporated to a splint generated by plaster models. They concluded that the mean registration error was 0.16mm which was statistically insignificant (p value<0.02).

Swennen et al (2005)⁴⁴ in their review compared the advantages and disadvantages of craniofacial Cone beam computed tomography to a conventional multi-slice computed tomography and the potentials of cone beam computed tomography. They concluded that CBCT, 3D cephalometry would enable craniofacial patient care due to reduced patient radiation exposure, accessibility, and favourable cost benefit analysis.

Vannier et al (2003)⁵⁴ in their study stated that improvements in CBCT reconstruction algorithm and post-processing will provide benefits for future craniofacial imaging. They concluded that when new developments in synthesis and optimization of CBCT reconstruction algorithms allowed exploring fully the area detectors in CBCT, this would provide important benefits in craniofacial imaging in the future.

Swennen et al (2006)⁴⁵ in their study on 10 dry adult human cadavers evaluated the accuracy of automatic rigid registration using new 3D splint and double CT scan procedures to obtain accurate anatomic virtual augmented model of skull. They found out that the overall mean registration error was 0.1355 +/- 0.0323mm which was statistically insignificant and concluded that combination of new 3D splint with double CT scan procedure gave an accurate anatomic 3D virtual augmented model of skull with detailed dental surface.

Uechi and co-workers (2006)⁵³ in their study in 2 patients with severe skeletal deformities established a novel method for simulating orthognathic surgery in 3-dimensional (3D) space. In their study the virtual skull (VS) was fused with dental optical surface scans occluded in pre-operative and post-operative positions (VD1 and VD2). They found that the registration error was less than 0.4mm which was statistically insignificant in both patients and concluded that simulation system could be used to precisely realize the pre-surgical and postsurgical occlusal relationships and craniofacial morphology of

a patient with severe skeletal deformities, and to quantitatively describe the movement of a given anatomical point of bony segments.

Tsuji.M and co-workers (2006)⁵¹ in their study evaluated a system that uses cephalograms instead of CT scans to create images. The system used a dental cast to register the operation field to a pair of frontal and lateral cephalograms. The cast is transformed to 3D data with a laser scanner and a programme that worked on a personal computer. 3D data describing the dental cast, cephalograms and the oral and maxillofacial region of the patient were integrated with specialized software. The optical tracking system for navigation used CCD's and LED's. They found that errors occurring when a dental cast was transformed to 3D data ranged from 0.08 to 0.21mm. They concluded that this surgical navigation system provides sufficient accuracy for highly precise surgery.

Claudio Marchetti et al (2006)²⁵ in their study in 25 patients with facial malformations provided a virtual surgery (VISU) tool for accurately planning the aesthetic impact of hard and soft tissue movements in dento-skeletal malocclusions. They compared the postoperative 3-D CT and facial outcomes with the simulations. They concluded that in 80% of the cases studied, the simulation-predicted changes, when compared with the clinical outcomes, were within the tolerance level (2 mm) established by maxillo-facial surgeons.

Swennen et al (2007)⁴⁶ in their study in 10 patients scheduled for orthognathic surgery introduced and evaluated the use of a wax bite wafer in

combination with double CT scan procedure to augment 3D virtual skull with detailed dental surface. They concluded that the error was 0.17 ± 0.07 .

Mehmet Emin Mavili and co-workers (2007)²⁷ in their prospective trial in 12 patients assessed the usefulness of stereolithographic models in orthognathic surgery. In their study alveolar arches of the maxilla and mandible of the models were replaced with orthodontic dental cast models. The relation between proximal and distal mandibular segments after bilateral sagittal split osteotomies were evaluated on models preoperatively. The same bony relation was observed both in preoperative models and in the surgical field in all patients. They concluded that studying preoperative planned movements of osteotomized bone segments and observing relations of osteotomized segments of mandible and maxilla in orthognathic surgery increased the intraoperative accuracy.

Noguchi et al (2009)²⁹ in their study evaluated a method for simulating the movement of teeth, jaw and face caused by orthognathic surgery. The teeth and facial data were obtained by a laser scanner and the data for the patient's mandible were reconstructed and integrated according to 3D cephalometry using a projection-matching technique. The mandibular form was simulated by transforming a generic model to match the patient's cephalometric data. They concluded that this system permits analysis of bone movement at each individual part, while also helping in the choice of optimal osteotomy design considering the influences on facial soft-tissue form.

Plooj et al (2008)³³ in their article in 15 patients evaluated the accuracy of three different image matching procedures. The textured skin surface (3D photograph) and untextured skin surface (CBCT) were matched by two observers using three different methods to determine the accuracy of registration. They found out that the registration errors were relatively large at the lateral neck, mouth and around the eyes with 90% of errors within range of +/- 1.5mm. They concluded that the 3D data set provides an accurate and photorealistic digital 3D representation of a patient's face.

Metzger and co-workers (2008)²⁸ in their article presented a technique for manufacturing splints for orthognathic surgery using a 3D printer. They advocated that to reduce artefacts, plaster models were scanned either simultaneously with the patient during the 3D data acquisition or separately using a surface scanner. The CT data and the dental scan data were combined and the planned reposition was performed virtually using surface registration. They found out that setting a virtual splint between the tooth rows made it possible to encode the repositioning. After performing a boolean operation, tooth impressions are subtracted from the virtual splint. The "definitive" splint was then printed out by a 3D printer. They concluded that this technique combines the advantages of conventional plaster models, precise virtual 3D planning, and the possibility of transforming the acquired information into a dental splint.

Swennen et al (2009)⁴⁶ in their study on 10 patients undergoing orthognathic surgery presented a new approach to acquire a three-dimensional

virtual skull model appropriate for orthognathic surgery planning without the use of plaster dental models and without deformation of the facial soft-tissue mask using a triple CBCT scan procedure. In their study, the patient was scanned vertically with a wax bite wafer in place (CBCT scan N-1) first. After this step, a limited dose scan of the patient with a Triple Tray Alginate impression in place was carried out (CBCT scan N- 2). Finally, a high-resolution scan of the Triple Tray Alginate impression was done (CBCT scan N-3). The accuracy of registration was measured on a synthetic skull and showed to be highly accurate. A volume overlaps of 98.1% was found for registered impression scan N-1. The mean distance between registered impression scan N-1 and registered impression scan N-2 was 0.08 +/- 0.03mm (range, 0.04 +/- 0.11 mm). They concluded that this method was appropriate and valid for 3-D virtual orthognathic surgery planning in the clinical routine.

Greenhill et al (2009)¹² in their study evaluated the advantages of tissue adhesives for wound closure and establish the incidence of hypertrophic and keloid scars after the use of N-butyl-2-cyanoacrylate tissue adhesive. They concluded that the incidence of hypertrophic and keloid scars was 8 and 9, respectively. The technique was simple and safe, and the incidence of hypertrophic and keloid scars was within the accepted range for sutures.

Swennen et al (2009)⁴⁷ in their report presented an integrated 3-dimensional (3D) virtual approach toward cone-beam computed tomography-based treatment planning of orthognathic surgery in the clinical routine. They described the different stages of the workflow process for routine 3D virtual

treatment planning of orthognathic surgery and discussed potential benefits and actual limits of an integrated 3D virtual approach for the treatment of the patient with a maxillofacial deformity.

Dan Grauer et al (2009)¹⁸ in their study have assessed the visualization of CBCT images in orthodontics, measurement in CBCT images, creation of 2-dimensional radiographs from DICOM (Digital imaging and communication in medicine) files, segmentation engines and multi-modal images, registration and superimposition of 3-dimensional images. They concluded that this paradigm shift has paved way towards 3D diagnosis, treatment planning and computer aided design.

Choi et al (2009)⁷ in their article presented a patient who underwent virtual model surgery using combined data from 3D CT and 3D virtual dental casts. They concluded that the errors with 3D virtual model surgery (0.00-0.35) were less than manual model surgery (0.00-0.94) and the time taken for the entire procedure was recorded to be less than 50minutes including scanning upper, lower casts, fabrication of 3D virtual models, superimposition of 3D virtual models and CT data and 3D virtual model surgery and printing the surgical wafers.

Stefaan.J.Berge et al (2010)⁴⁹ in their review on 15 articles described the 3D digital image fusion models of two or more different imaging techniques for orthodontics and orthognathic surgery. They concluded that image fusion and 3D virtual head are accurate and realistic tools for documentation, analysis

and treatment planning and long term follow up which provided accurate and realistic prediction model.

Sean P. Edwards (2010)⁴¹ in his review elaborates the various applications of computer aided surgical technology and emphasized on incorporating it into traditional diagnostics and treatment planning.

Scott Tucker and coworkers (2010)⁴³ in their study on 20 patients determined whether the virtual surgery performed on 3D models constructed from cone-beam computed tomography (CBCT) would correctly simulate the actual surgical outcome and validated the ability of this emerging technology to recreate the orthognathic surgery hard tissue movements in 3 translational and 3 rotational planes of space. They inferred that there was no statistically significant difference between the simulated and the actual surgical models and concluded that virtual surgical methods were reliably reproduced which has the potential to increase predictability in the operating room.

Richmond and Popat (2010)³⁶ in their work familiarized the technique for creating a virtual 3D patient, outlining the advantages and disadvantages of the software and concluding on the feasibility of its routine use in clinical practice.

J.C. Barbenel and co-workers (2010)⁵ in their study on 5 orthognathic procedures emphasized on the flaws of conventional orthognathic surgical planning. A mathematical analysis showed that the misalignment of the

maxillary model introduces errors in the wafers, which may lead to the incorrect surgical positioning of the maxilla. They concluded that existing methods for prediction planning of the surgical correction of dentofacial deformities using dental models and available articulators were inaccurate.

Stefaan J. Berge et al (2011)³⁹ in their systematic review of literature concluded that the image fusion and 3D virtual head are accurate and realistic tools for documentation, analysis and treatment planning and long term follow up which provides an accurate prediction model.

Bong Chul Kim et al (2011)²⁴ in their study on 55 orthognathic patients requiring maxillary orthognathic surgery presented their clinical experience regarding the production and accuracy of digitally printed wafers for maxillary movement during the bimaxillary orthognathic surgery. They found out that digital model surgery involved a mean error of 0.00-0.09 mm which was statistically insignificant and concluded that the rapid-prototyped interocclusal wafer produced with the aid of digital model surgery can be an alternative procedure for maxillary orthognathic surgery.

Samir Aboul-Hosn Centenero et al (2011)⁶ in their study in 16 patients undergoing orthognathic surgery determined the advantages of 3D planning in predicting postoperative results and manufacturing surgical splints using CAD/CAM (Computer Aided Design/Computer Aided Manufacturing) technology in orthognathic surgery. Conventional preoperative treatment plan was devised for each patient, and surgical splints were manufactured. These

splints were used as study controls. In the operating room, both types of surgical splints were compared and the degree of similarity in results obtained in three planes was calculated. Three months after surgery a second set of 3D images were obtained and used to obtain linear and angular measurements on screen. The maxillary osteotomy line was taken as the point of reference. The level of concordance was used to compare the surgical splints. Three months after surgery a second set of 3D image were obtained and used to obtain linear and angular measurements on screen. Using the intraclass correlation coefficient the postoperative measurements were compared with the measurements obtained when predicting postoperative results. The results obtained showed that a high degree of correlation in 15 of the 16 cases. A high coefficient of correlation was obtained in most of predictions of results in hard tissue, although less precise results were obtained in measurements in soft tissue in the labial area. They concluded that software program used in the study is reliable for 3D planning and for the manufacture of surgical splints using CAD/CAM technology and also advocated that further progress in the development of technologies for the acquisition of 3D images, new versions of software programs, and further studies of objective data are necessary to increase precision in computerised 3D planning.

Frits.A.Rangel et al (2012)³⁹ in their study described a method for the fusion of cone beam computed tomographic scans and digital dental casts. They also emphasized on the advantages of cone beam computed tomography and

concluded that integration of cone beam computed tomographic scans and digital dental models overcomes problems such as increased radiation exposure, distortion of soft tissues due to bite jigs and time consuming digital data handling process.

Olszewski (2012)³⁰ in his systematic review emphasized on the various applications of surgical engineering in craniomaxillofacial surgery. His results showed that surgical engineering plays an important role in the development and improvement of cranio-maxillofacial surgery. Some technologies, such as computer-assisted surgery, image-guided navigation, and three-dimensional rapid prototyping models, have reached maturity and allow for multiple clinical applications, while augmented reality, robotics, and endoscopy still need to be improved.

Zinser et al (2012)⁵⁸ in their study demonstrated the feasibility and validity of virtual planning protocol with a patented 3-surgical splint technique for orthognathic surgery in 8 patients with class 3 mal-occlusion treated with bimaxillary osteotomies. The virtual plan was compared with the postoperative surgical result using image fusion of CT/CBCT dataset by analysis of measurements between hard and soft tissue landmarks relative to reference planes. The virtual planning approach showed clinically acceptable precision for the position of the maxilla (<0.23 mm) and condyle (<0.19 mm), marginal precision for the mandible (<0.33 mm), and low precision for the soft tissue (<2.52 mm). They concluded that virtual diagnosis, planning, and use of a

patented CAD/CAM surgical splint technique provides a reliable method that may offer an alternate approach to the use of arbitrary splints and 2-dimensional planning.

Polley et al (2012)³⁵ in their study introduced the concept of “occlusal-based orthognathic positioning system” (OPS) to be used during orthognathic surgery. This consisted of intraoperative occlusal-based devices that transfer virtual surgical planning to the operating field for repositioning of the osteotomized dentoskeletal segments which used detachable guides connected to an occlusal splint. An initial drilling guide was used to establish stable references or landmarks. After mobilizing dental segment final positioning guide was used to transfer the skeletal segment according to virtual surgical planning. The guides were virtually designed and printed. They concluded that orthognathic positioning system has the possibility to eliminate the inaccuracies commonly associated with traditional orthognathic surgery planning and to simplify the execution by eliminating surgical steps such as intraoperative measuring, determining the condylar position, the use of bulky intermediate splints, and the use of intermaxillary wire fixation. This also allowed precise translation of the virtual plan to the operating field, bridging the gap between virtual and actual surgery.

Gateno and coworkers (2013)¹⁶ in their multicentre study on 65 patients assessed the accuracy of a computer-aided surgical simulation (CASS) protocol for orthognathic surgery. For genioplasty, 1 centre used computer-

generated chin templates to reposition the chin segment for patients with asymmetry alone. Standard intraoperative measurements were used without the chin templates for the remaining patients. The primary outcome measurements were the linear and angular differences for the maxilla, mandible, and chin when the planned and postoperative models were registered at the cranium. The secondary outcome measurements were the maxillary dental midline difference between the planned and postoperative positions and the linear and angular differences of the chin segment between the groups with and without the use of the template. The latter were measured when the planned and postoperative models were registered at the mandibular body. Statistical analyses were performed, and the accuracy was reported using root mean square deviation (RMSD) and the Bland-Altman method for assessing measurement agreement. They concluded that in the primary outcome measurements, there was no statistically significant difference among the 3 centers for the maxilla and mandible. The largest RMSDs were 1.0mm and 1.5° for the maxilla and 1.1mm and 1.8° for mandible. For the chin, there was a statistically significant difference between the groups with and without the use of chin template. The chin template group showed excellent accuracy, with the largest positional RMSD of 1.0mm and the largest orientation RMSD of 2.2°. They concluded that using computer-aided surgical simulation protocol, the computerized plan can be transferred accurately and consistently to the patient to position the maxilla and mandible at the time of surgery.

Ayoub et al (2013)⁴ in their study in 6 human cadavers and two adult humans introduced a method of producing composite model consisting of a three-dimensional printed mandible bearing plaster teeth. The distorted teeth of the printed models were removed and replaced by the plaster casts of the teeth using a simple transfer jig. The scans of the dry mandibles and the composite models were superimposed and the magnitude of the discrepancies at six points on the dentition and six on the mandible were obtained and the error was found to be 0.35mm. It was concluded that the errors of the method were small enough to be clinically significant.

Ayoub et al (2014)⁴³ in their study assessed the accuracy of rapid prototyping of virtual wafers derived from laser scanned dental models using CAD/CAM software in 10 orthognathic patients. Upper and lower plaster models, the articulated models, and the conventional wafers and rapid prototyped models were scanned. The absolute mean error of the rapid prototype wafer when aligned with the dental models was 0.94(0.09) mm. The absolute distance of the 2 models articulated by conventional and rapid prototype wafers ranged from 0.04 - 1.73mm. The rapid prototype wafers were able to orientate the upper and lower dental models with an absolute mean error of 0.94 (0.09) mm, but it ranged from 0.04-1.73mm.

Jyothikiran et al (2014)¹⁵ in their review presented an overview of the currently used imaging methods along with those of the past and a look at the innovations in craniofacial imaging. The development of an interactive 3D

digital model of a patient's anatomy would greatly improve our ability to determine different treatment options, to monitor changes over time (the fourth dimension), to predict and display final treatment results, and to measure treatment outcomes more accurately.

X.Lin et al (2015)⁵⁷ in their study investigated the accuracy of point based superimposition of digital dental model into 3-dimensional computed tomographic skull (CT) with intact dentition. They concluded that clinically acceptable accuracy was achieved using direct point-based method to superimpose digital dental model on to a 3D skull using Bland-Altman analysis.

Shashank Uniyal et al (2015)⁴² in their case report on three patients emphasized the workflow in planning a patient for orthognathic surgery and the importance of three-dimensional model surgery using modified Eastman's technique. They concluded that canted occlusal planes and edentulous spaces require 3D control during planning and surgery.

E.Shaheen et al (2016)²² in their study on 20 patients undergoing orthognathic surgery validated the accuracy of 3D printed final occlusal splints by comparing them to the conventional splints (manufactured by conventional setup) by distance measurements. They found that the mean absolute distance error was 0.4mm (standard deviation 0.17mm) which is clinically acceptable and concluded that their protocol could be used to produce accurate 3D final occlusal splints with acceptable clinical outcomes.

MATERIALS AND METHODOLOGY

DATA COLLECTION

The study was conducted in the department of Oral & Maxillofacial Surgery, Ragas Dental College and Hospital, Chennai, TamilNadu on four patients who required surgical correction of their jaws to improve function and aesthetics, after obtaining clearance from the institutional review board ethical committee.

INCLUSION CRITERIA

1. Patients who were planned to undergo Orthognathic surgery involving three-dimensional repositioning of maxilla.
2. Patients who were planned to undergo Orthognathic surgery involving three-dimensional repositioning of mandible.

EXCLUSION CRITERIA

1. Patients medically unfit for surgery
2. Patients not willing for surgery
3. Patients not willing to be a part of study

STUDY DESIGN - Prospective study.

INFORMED CONSENT

All patients included for the study were explained completely about the procedure in their own native language and informed consent was obtained from all of them in written format.

ARMAMENTARIUM

1. Titanium markers of standardized dimensions (1*2*1.5mm)
2. Tissue adhesive (N-butyl,2-cyanoacrylate glue)
3. Plastic orthodontic impression trays
4. Alginate impression material
5. Standardized CBCT scanning protocol
6. Optical scanner

CBCT SCANNING PROTOCOL:

A CBCT scan was taken for patients included in the study in natural head position with the Frankfort plane parallel to the floor. (Figure 53).

OPTICAL SCANNER

The model plaster casts were scanned with a resolution of 20 microns to visualize the 3D models via volume rendering (Figure 56 A, B).

SOFTWARES USED

The components in our study included different software with each software being used for different steps in the course of the study.

1. **MIMICS: MATERIALISE INTERACTIVE MEDICAL IMAGE CONTROL SYSTEM**

Mimics was used to convert the DICOM data from CBCT into a three-dimensional object. (Leuven, Belgium)

2. **HAPTICS:**

This device was used to create virtual osteotomies by virtual tactile perception, (3D SYSTEMS, U.S.A) (Figure 55)

3. **3-MATIC:**

This software was used to store and save the planned virtual surgery as STL files. (Leuven, Belgium)

HARDWARE REQUIREMENTS:

Minimum system requirements

- Windows XP (x64 edition is needed for Mimics 64-bit version)
- 2GB RAM
- 2GB available hard drive space
- Graphics card with 256 MB RAM
- DirectX 9.0

Recommended system requirements

- Windows 7 x64 editions
- 4GB RAM
- 8GB free hard disk space
- Graphics card supporting 512 MB RAM
- Direct X 9.0 or higher

DATA ACQUISITION

All the images obtained were saved and stored as DICOM (Digital imaging and communication in medicine and imported into MIMICS SOFTWARE (LEUVEN, BELGIUM). The patient's dental casts were also imported into MIMICS. Using mathematical algorithms, the DICOM data were converted into 3D images.

DATA RECONSTRUCTION

The data imported is reconstructed by image thresholding into a virtual 3D object commonly called SMART MODEL or an INTERACTIVE MODEL (Figure 15,16,17).

3D PRINTING

The wafers in their finalized virtual plan is saved as. stl files and imported to the 3D printer (Inkjet printing) for obtaining the rapid prototyped model (Figure 54).

METHODOLOGY

In patients planned for orthognathic surgery, small rectangular fiducial (1*2*1.5mm) titanium markers (Robison's Mill, Avadi, Chennai, Tamilnadu) were glued to the gingiva using tissue adhesive True Seal Derma bond (N-butyl-2-cyanoacrylate). The markers were placed on attached gingiva, 2 to 3 mm from the cervical margin, at the level of the dental midline, the canine, and the first molar and patient was instructed to wait for five minutes to ensure that the adhesive dried completely (Figure 57). After the adhesive dried, the patients underwent routine scan using a standardized CBCT scanning protocol. After the scan was completed, impressions were taken using plastic impression trays and alginate. Immediately after ensuring set of the impression material, the impressions were removed from the mouth with the markers embedded in it (Figure 58). Markers which remained attached to the gingiva were replaced in the marker spot in the impression using their imprints as guide. Some tissue

adhesive remained on the gingiva of the patient which dissolved within an hour and did not give any discomfort to the patient. Plaster models were prepared immediately from the impressions. The dental casts were scanned using an optical scanner with a resolution of 20 microns, to visualize the dentition accurately (Figure 56 A, B). The scans of the patient's head and of the impressions were exported as DICOM (Digital Imaging and Communications in Medicine) datasets and imported into viewing software. From the DICOM images of the patient's head, 3D reconstructions were made by thresholding. A grey value of 276 is set as the threshold value for segmentation of bony structures and a grey value of 3500 was set for the fiducial titanium markers and they were extracted separately. The final 3D reconstruction is the "3D MODEL" (Figure 15). A grey value of -300 was set for the DICOM data of the plaster models and the markers in the model were segmented with a grey value of 3500. This 3D reconstruction of the 3D MODEL and the DIGITAL DENTAL MODEL were fused by:

1. DICOM data of patient's head and the plaster models were imported into MIMICS software and markers extracted (Figure 21).
2. Using mathematical algorithms, the two models were fused by point based superimposition with titanium markers as reference (Figure 24,25,26).
3. The gingiva of digital dental model was removed, and the teeth from the patients scan data was removed.

4. Thus, the digital dentition and the patients CBCT scan is viewed as a single image.

This data is saved as .stl file and imported to HAPTICS for virtual osteotomy (Table 2). The reference lines were marked, and the planned virtual osteotomy done with virtual tactile perception in haptic device (Figure 55). The final virtual model is saved in 3-Matic software and the intermediate surgical wafers were virtually manufactured in this software. The intermediate occlusal splint is saved as .stl files and imported into a 3D printer for printing the occlusal splints.

CASE 1:

Fig.1. PRE-OPERATIVE FRONTAL PHOTOGRAPH AT REST



Fig.2. PRE-OPERATIVE FRONTAL PROFILE – AT SMILE



Fig.3. PRE-OPERATIVE RIGHT OBLIQUE VIEW

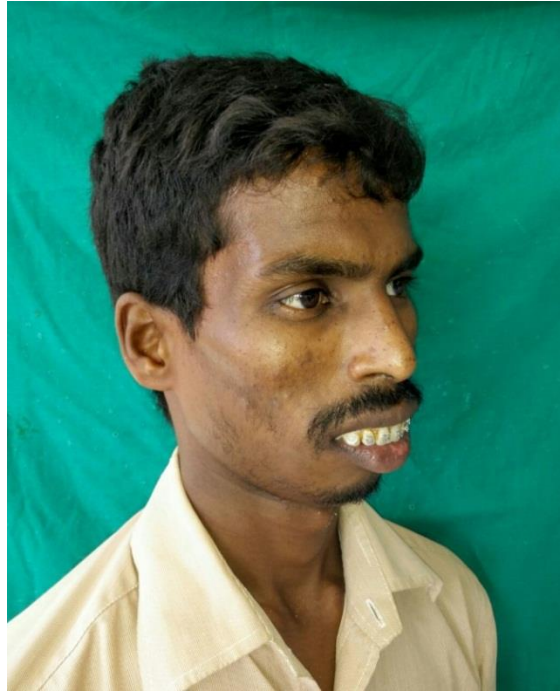


Fig.4. PRE-OPERATIVE RIGHT LATERAL VIEW

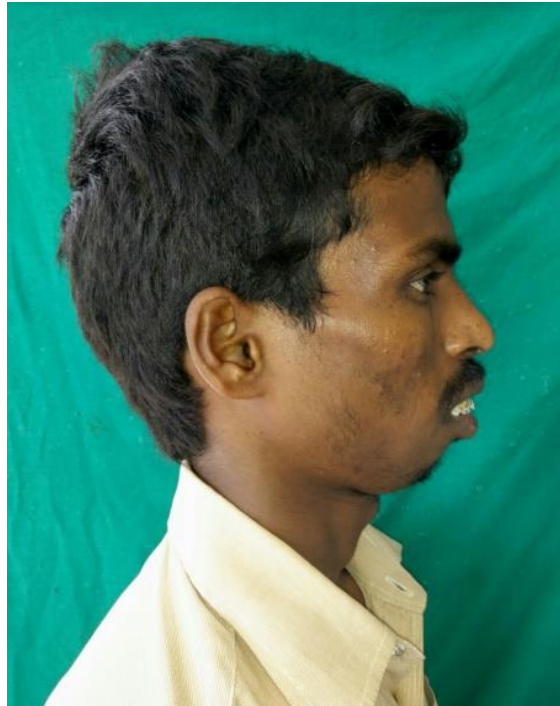

Fig.5. PRE-OPERATIVE LEFT OBLIQUE VIEW

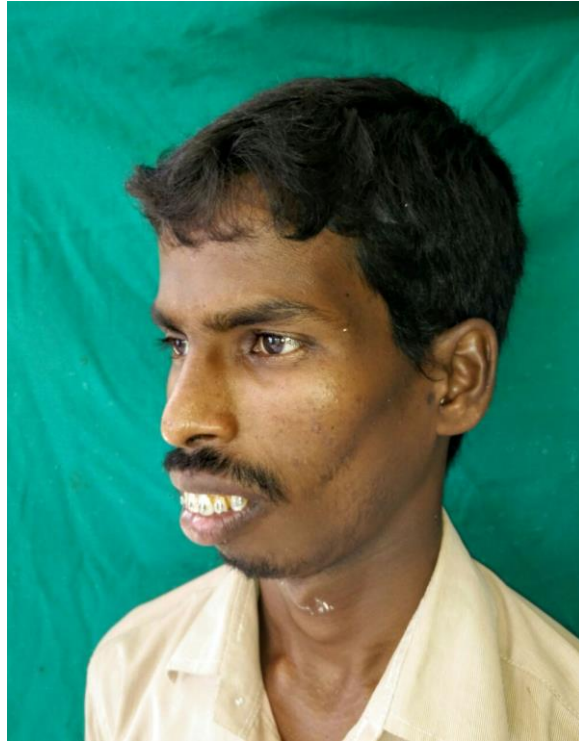
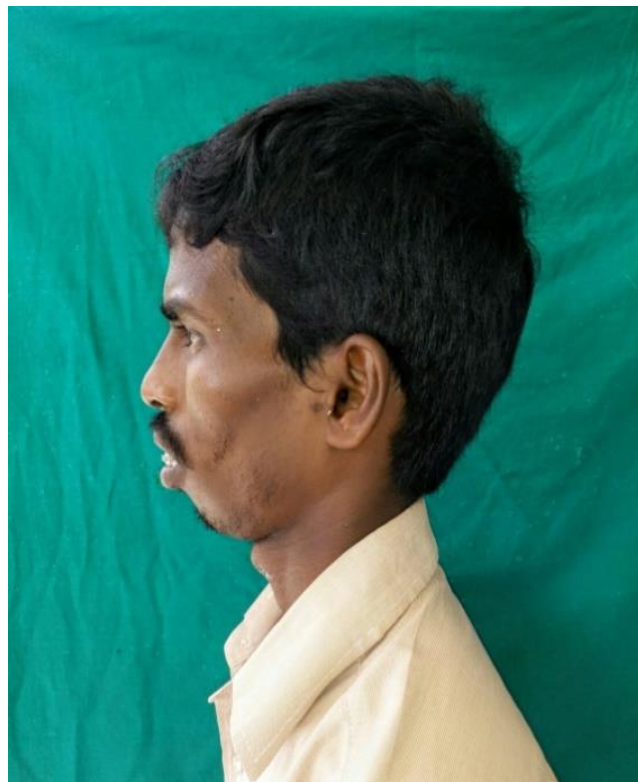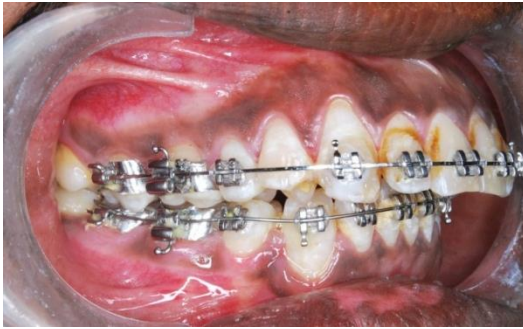


Fig.6. PRE-OPERATIVE LEFT LATERAL VIEW



**Fig.7.PRE-OPERATIVE OCCLUSION
-RIGHT**



**Fig.8.PRE-OPERATIVE
OCCLUSION-LEFT**

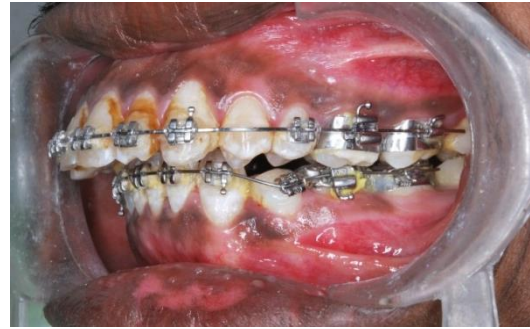

Fig.9. PRE-OPERATIVE FRONTAL OCCLUSAL VIEW

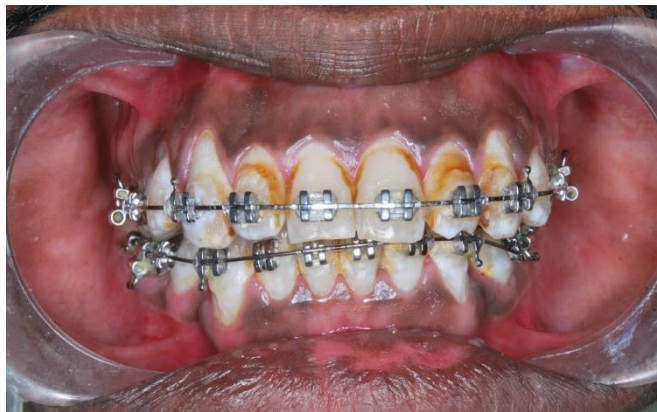

Fig.10. PRE-OPERATIVE MAXILLARY OCCLUSAL VIEW

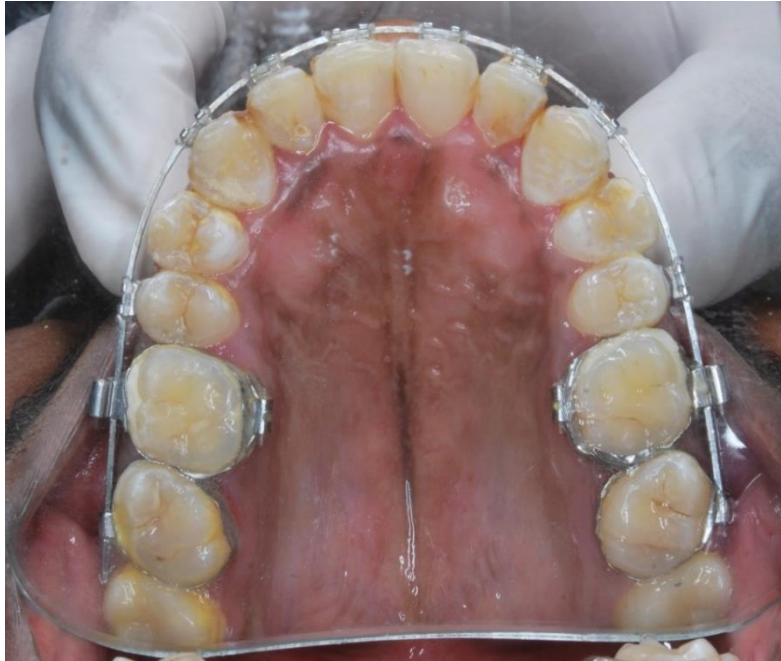
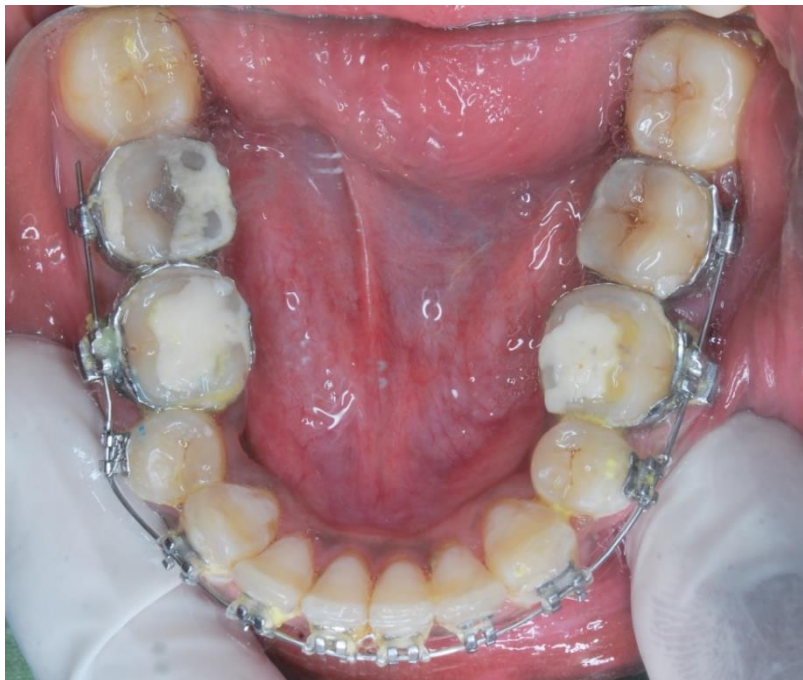

Fig.11. PRE-OPERATIVE MANDIBULAR OCCLUSAL VIEW




**TREATMENT PLAN: LEFORT I OSTEOTOMY AND
MAXILLARY SETUP 5MM, ANTERIOR MAXILLARY
OSTEOTOMY 4MM**


**Fig.12. A. PRE-OPERATIVE MEASUREMENT OF MAXILLARY
CASTS PRIOR-MODEL SURGERY- VERTICAL PLANE**




**Fig.12. B. POST-OPERATIVE MEASUREMENT OF MAXILLARY
CAST-VERTICAL PLANE**




**Fig.13. A. PRE-OPERATIVE MEASUREMENT OF MAXILLARY
CASTS PRIOR MODEL SURGERY-
ANTEROPOSTERIOR PLANE**



**Fig.13. B. POST-OPERATIVE MEASUREMENT OF MAXILLARY
CASTS – ANTEROPOSTERIOR PLANE**



**Fig.14. A. PRE-OPERATIVE MEASUREMENT OF MAXILLARY
CASTS PRIOR MODEL SURGERY- TRANSVERSE
PLANE**



**Fig.14. B. POST-OPERATIVE MEASUREMENT OF MAXILLARY
CASTS- TRANSVERSE PLANE**




Fig.15. 3D RECONSTRUCTED FRONTAL SKULL - PRE-OPERATIVE

VIEW

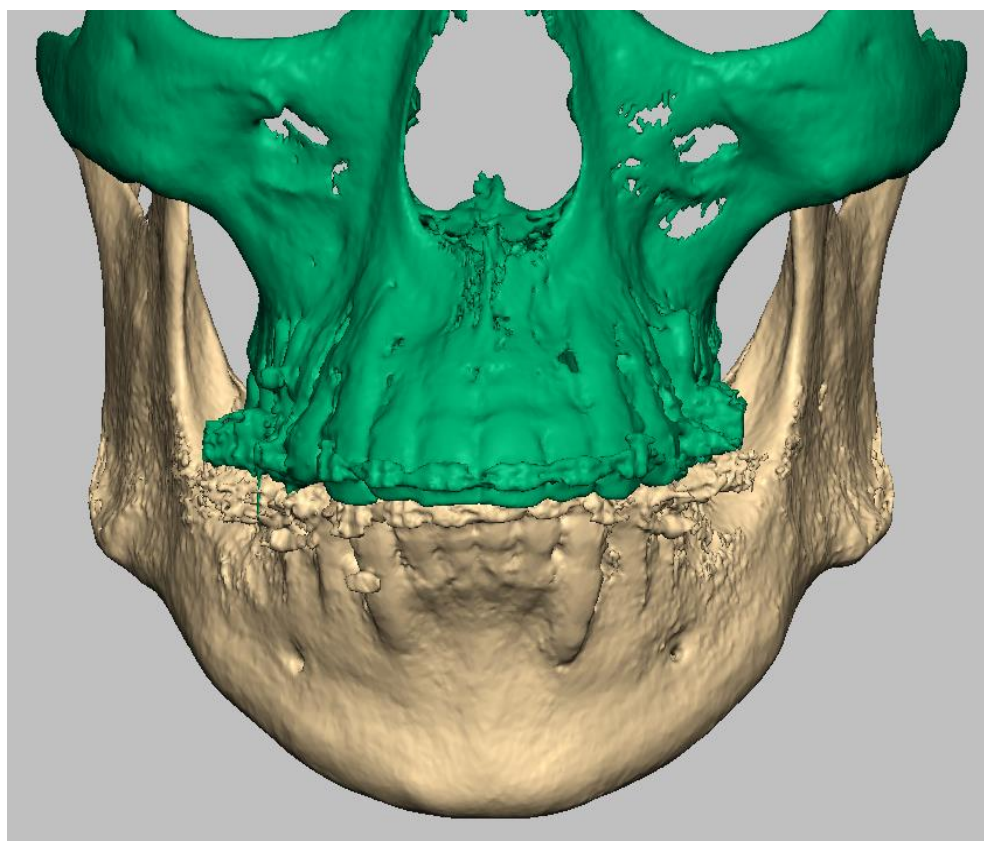


Fig.16. PRE-OPERATIVE 3D RECONSTRUCTED SKULL- RIGHT

LATERAL VIEW

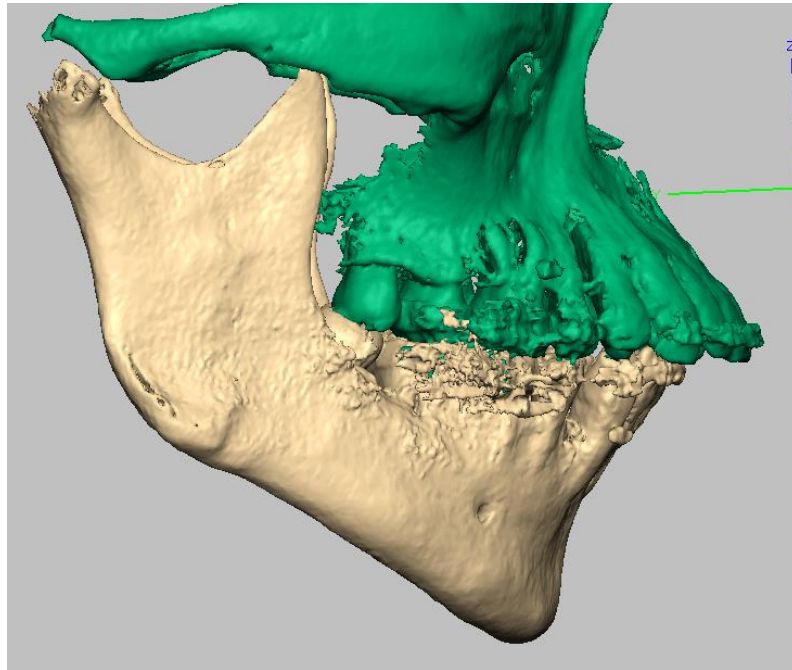
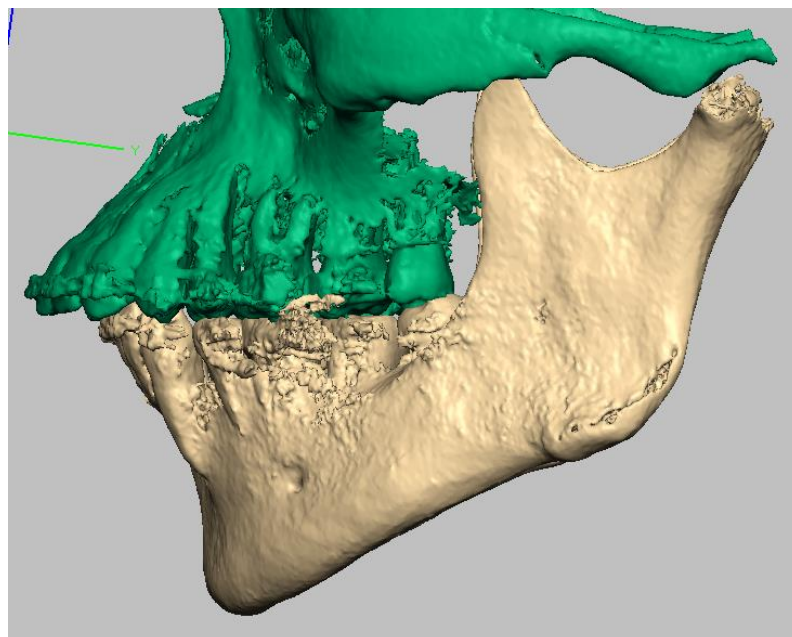



Fig.17. PRE-OPERATIVE 3D RECONSTRUCTED SKULL- LEFT

LATERAL VIEW



**Fig.18. DIGITAL MAXILLARY CAST
RIGHT LATERAL VIEW**



**Fig.19. DIGITAL DENTAL
MAXILLARY CAST-LEFT
LATERAL VIEW**

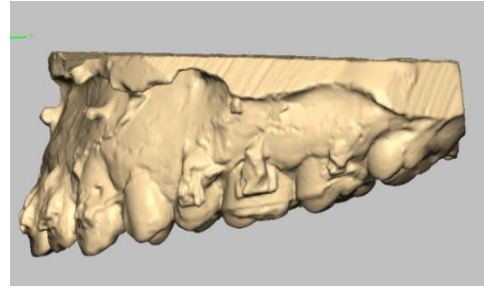
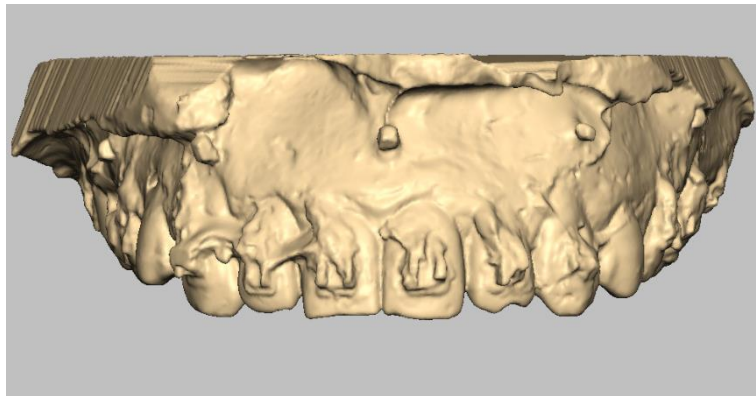


Fig.20. DIGITAL DENTAL CAST- MAXILLA



**Fig.21. PRE-OPERATIVE SKULL WITH THE FIDUCIAL MARKERS
AFTER SEGMENTING THE SKULL AND MAXILLA**

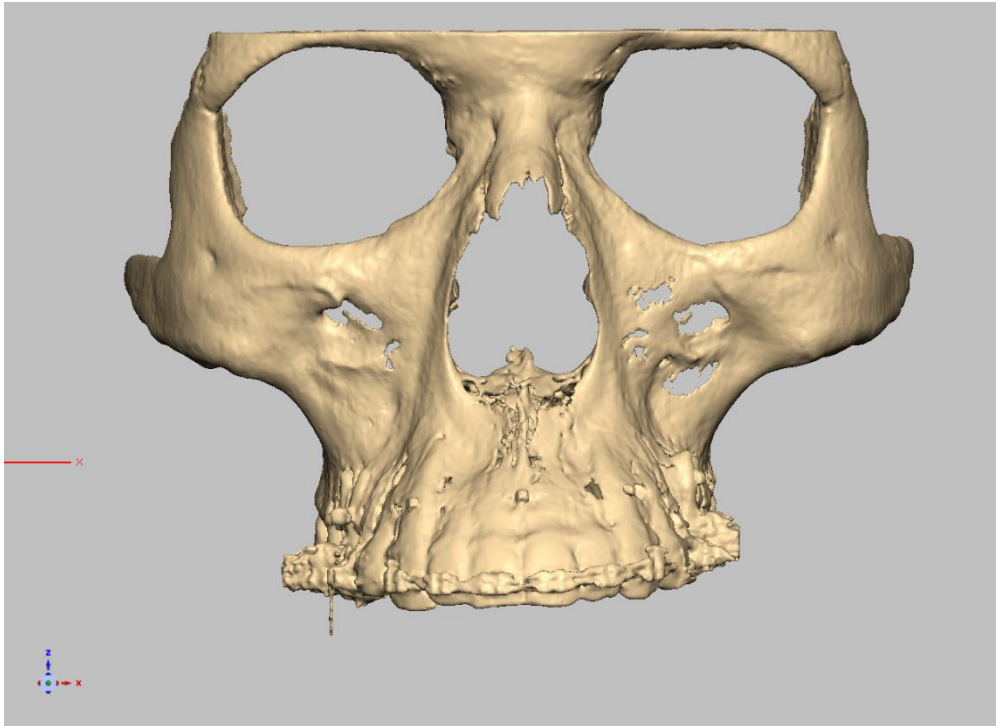


Fig.22. PRE-OPERATIVE SKULL WITH MARKERS- RIGHT

LATERAL VIEW

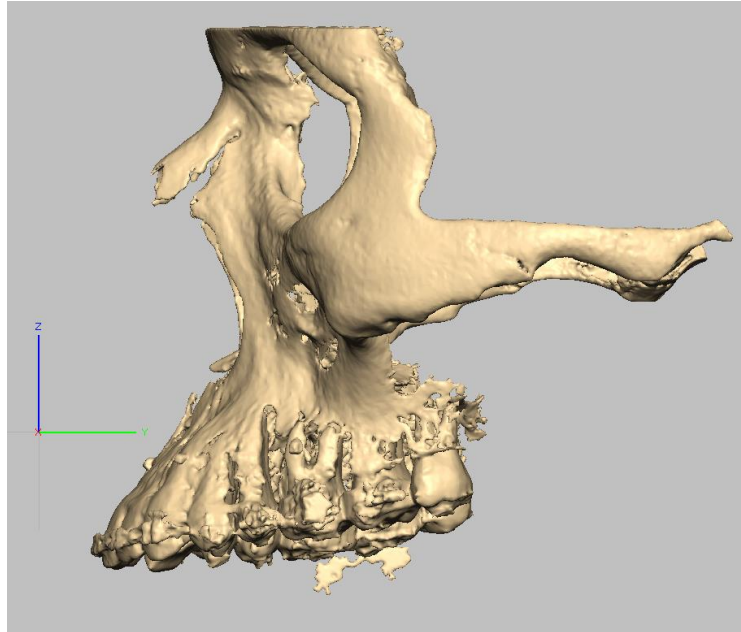
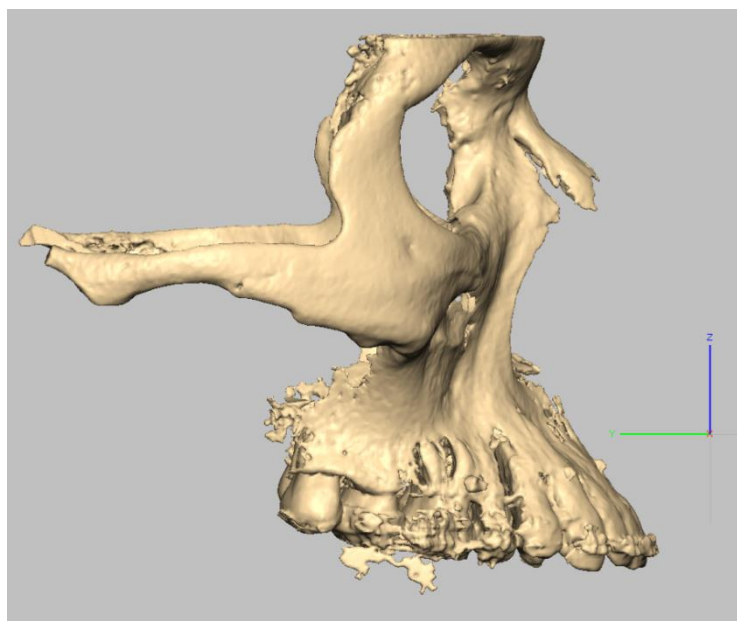
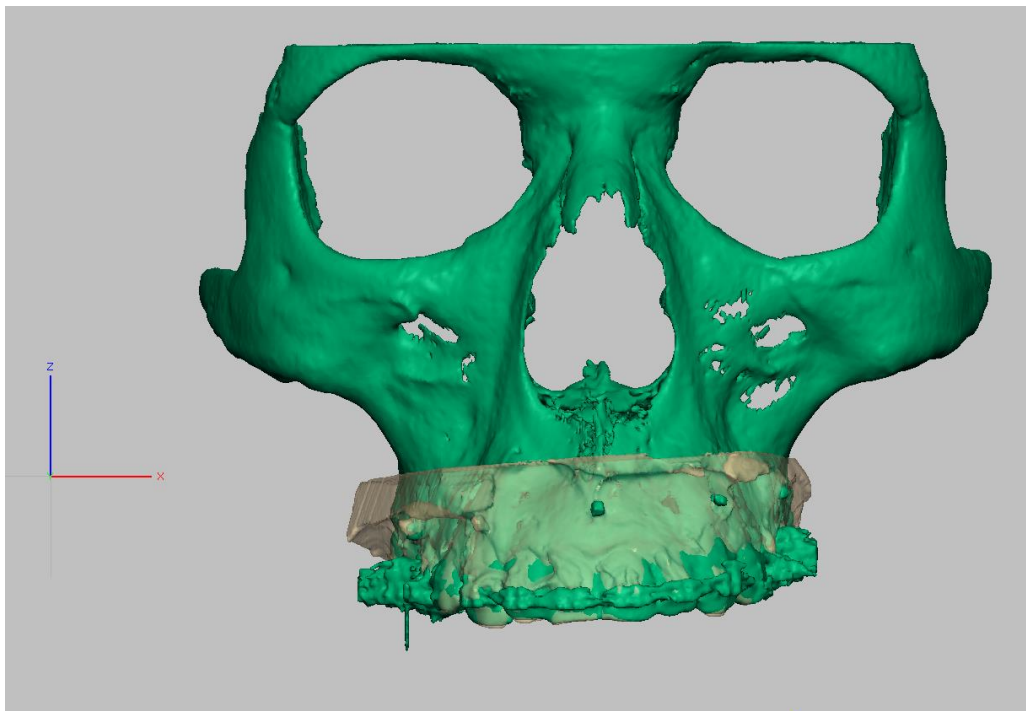


Fig.23. PRE-OPERATIVE SKULL WITH MARKERS- LEFT


LATERAL VIEW



**Fig.24. SUPERIMPOSITION OF DIGITAL DENTAL CAST AND
SKULL BASED ON THE FIDUCIAL MARKERS-FRONTAL
VIEW**



**Fig.25. SUPERIMPOSITION OF DIGITAL DENTAL CASTS AND
SKULL- RIGHT LATERAL VIEW**



**Fig.26. SUPERIMPOSITION OF DIGITAL DENTAL CASTS AND
SKULL - LEFT LATERAL VIEW**

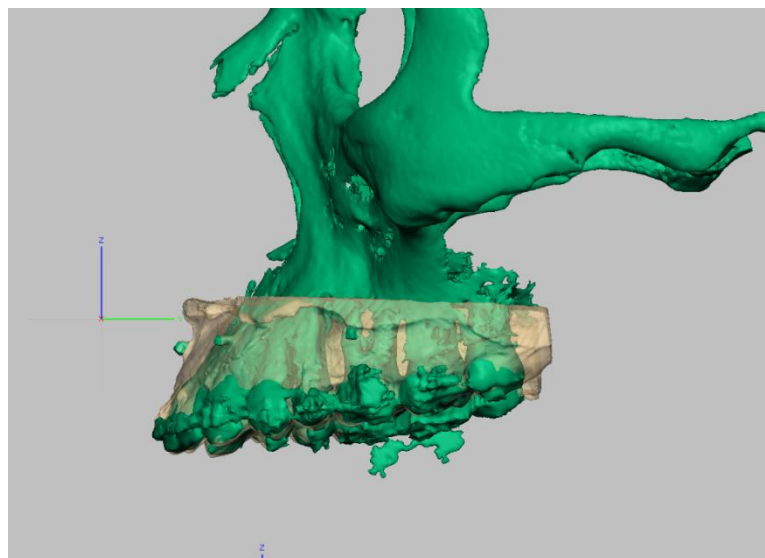
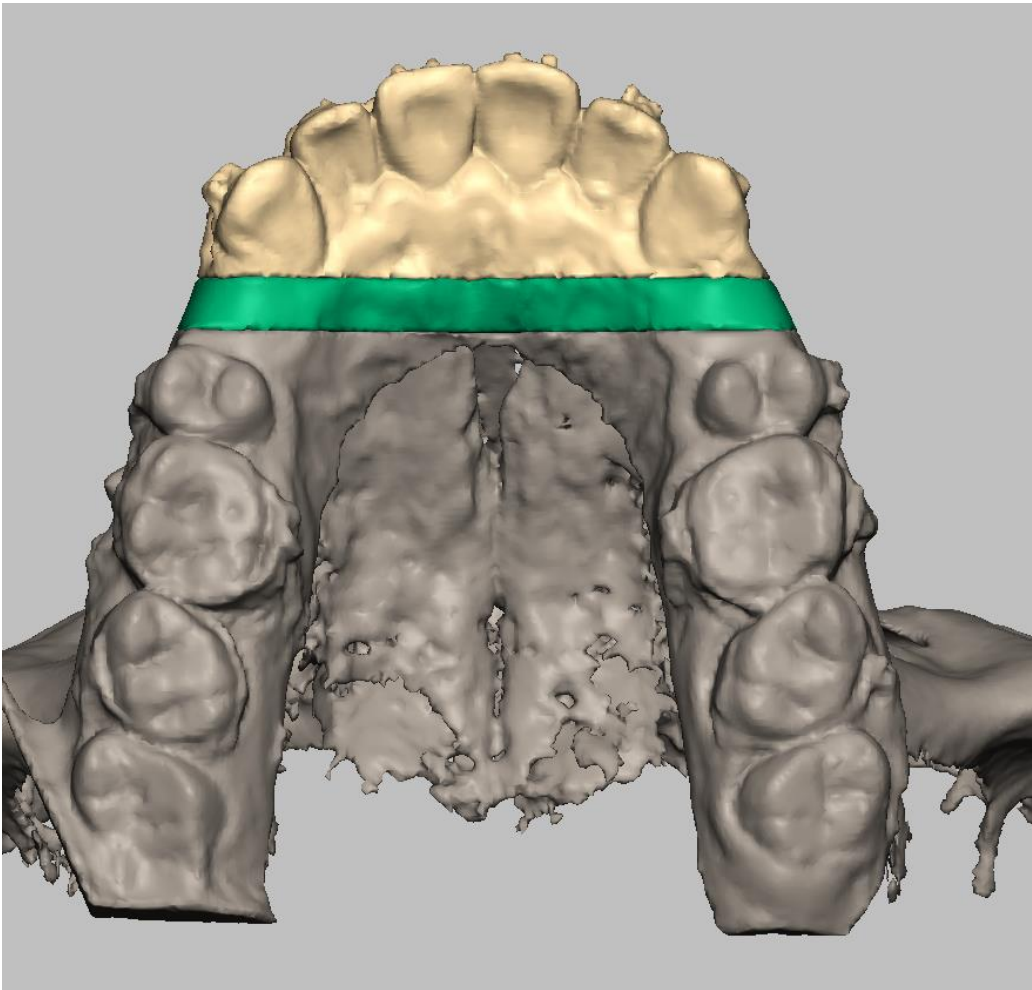
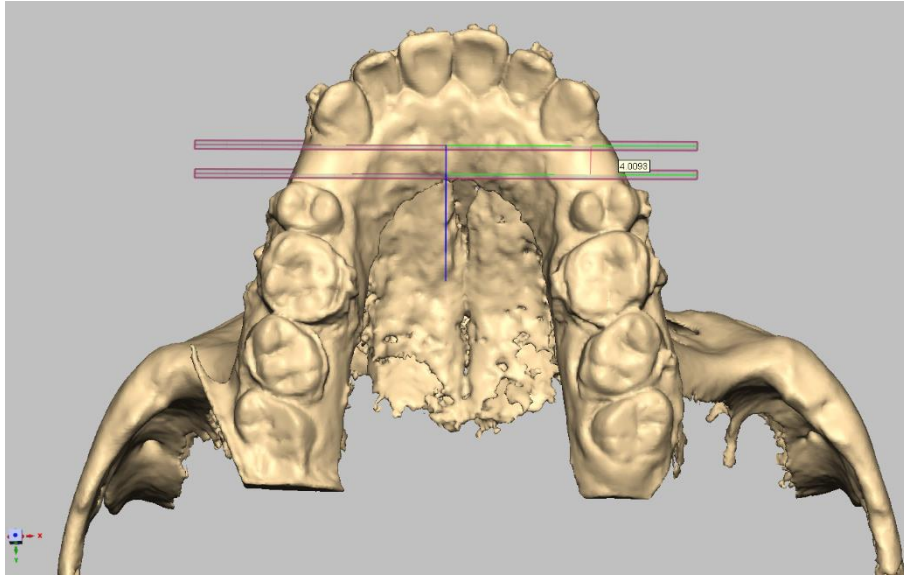


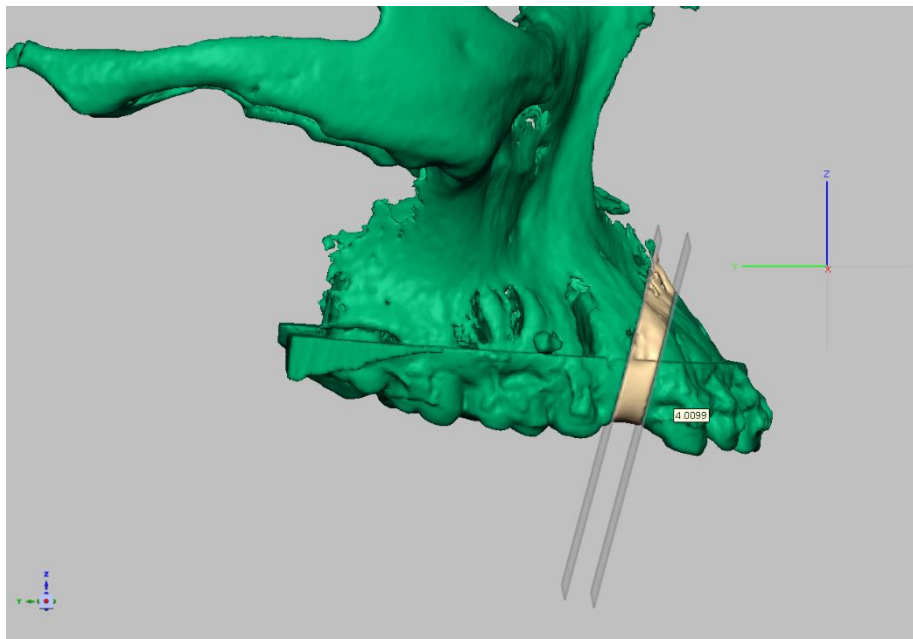
Fig.27. ANTERIOR MAXILLARY OSTEOTOMY LINES



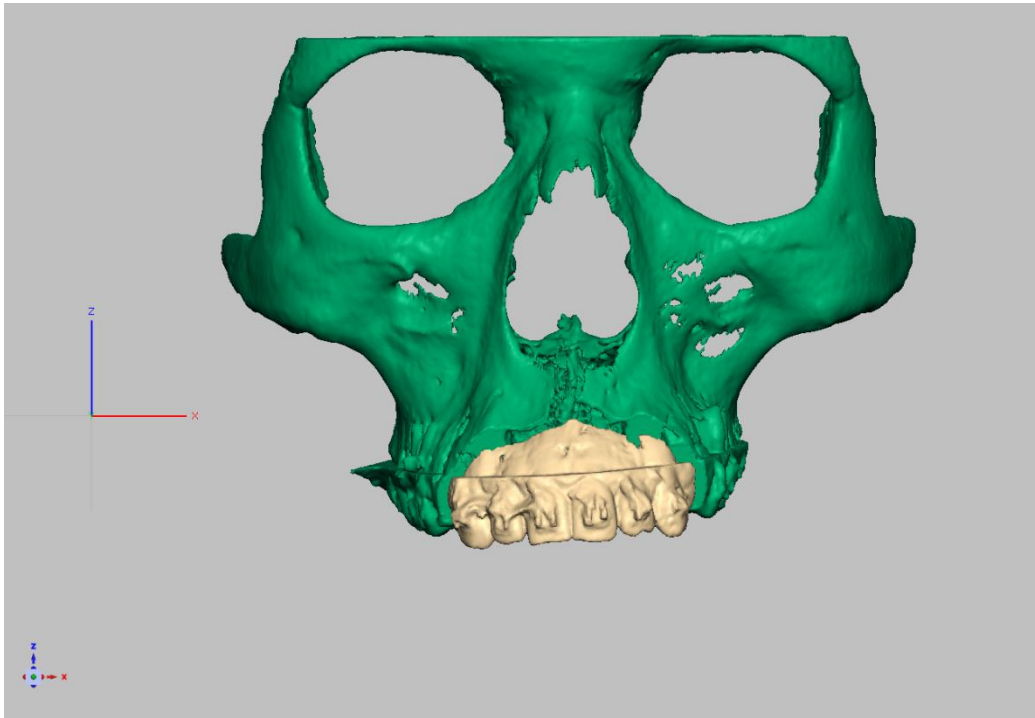
**Fig.28. ANTERIOR MAXILLARY OSTEOTOMY REFERENCE
FRAMES AFTER EXTRACTION OF FIRST PREMOLAR**



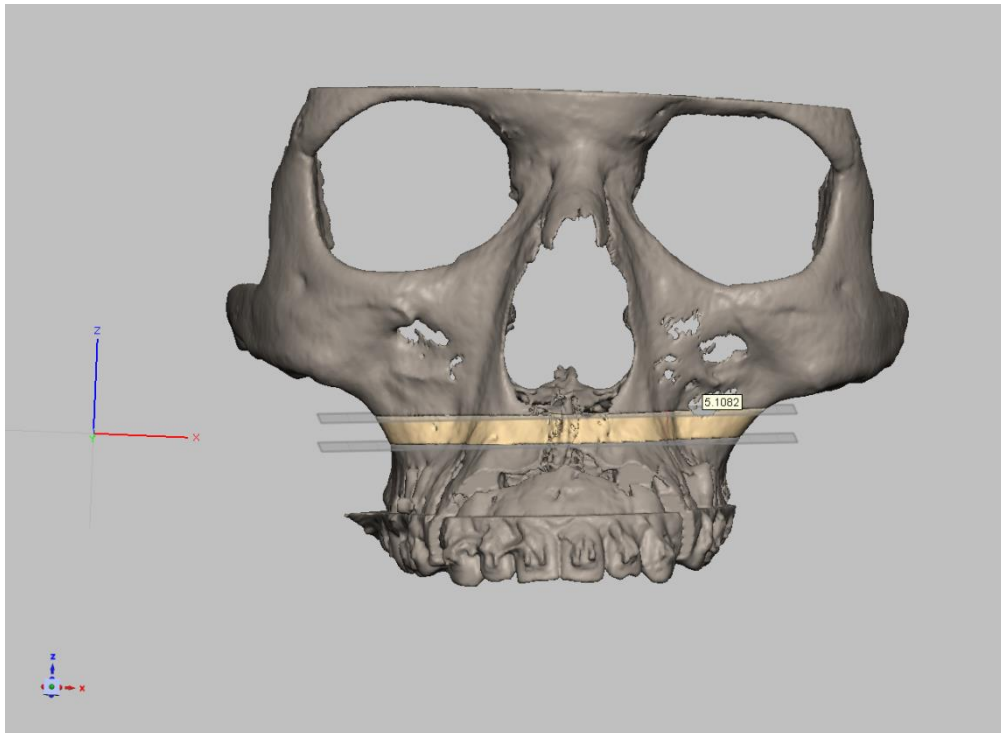
**Fig.29. ANTERIOR MAXILLARY OSTEOTOMY 4MM- RIGHT
LATERAL VIEW**



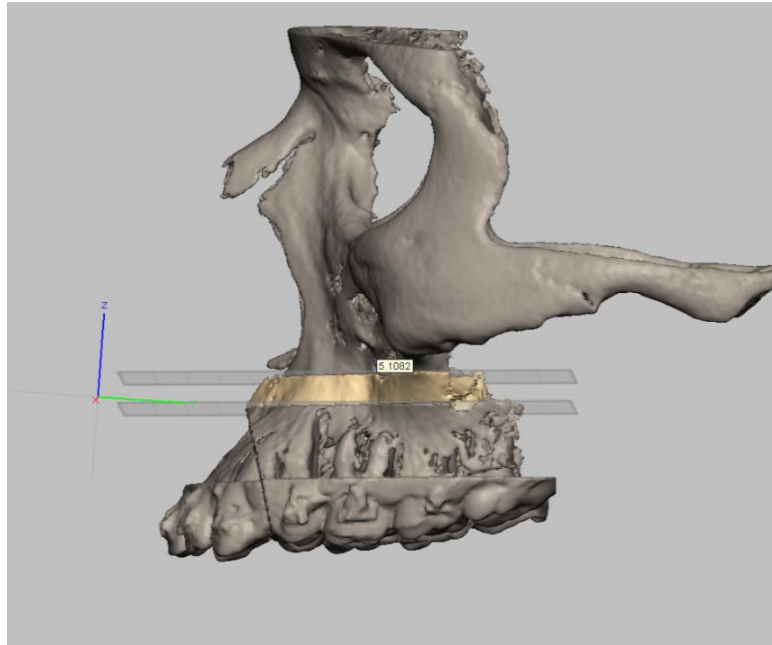
**Fig.30. POST-OPERATIVE SKULL FRONTAL VIEW AFTER
ANTERIOR MAXLLARY OSTEOTOMY OF 4MM**



**Fig.31. LEFORT I MAXILLARY SETUP OSTEOTOMY REFERENCE
FRAME**



**Fig.32. LEFORT I MAXILLARY SET-UP 5MM RIGHT
LATERAL VIEW**



**Fig.33. LEFORT I MAXILLARY SET-UP 5MM LEFT
LATERAL VIEW**

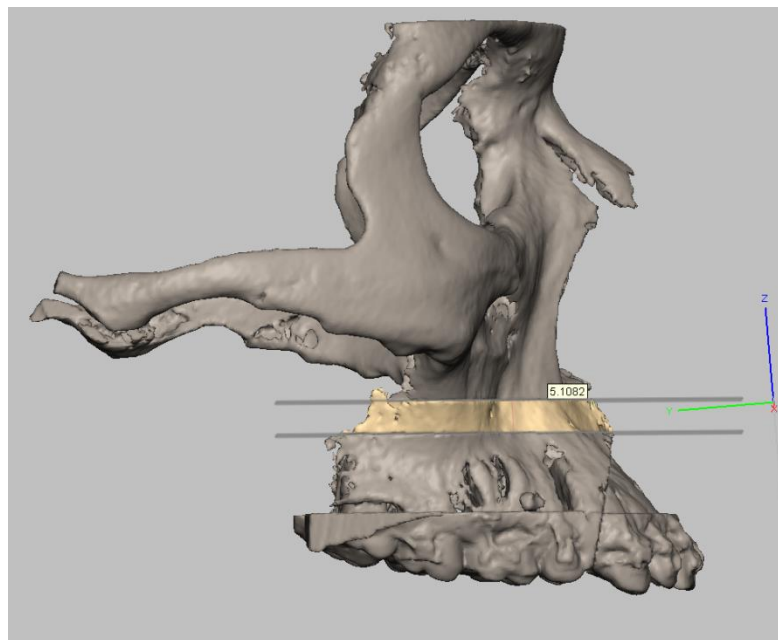


Fig.34. PRE-OPERATIVE SKULL MEASUREMENTS BEFORE LEFORT I OSTEOTOMY MEASURED FROM THE TIP OF CENTRAL INCISOR TO REFERENCE FRAME- 33MM

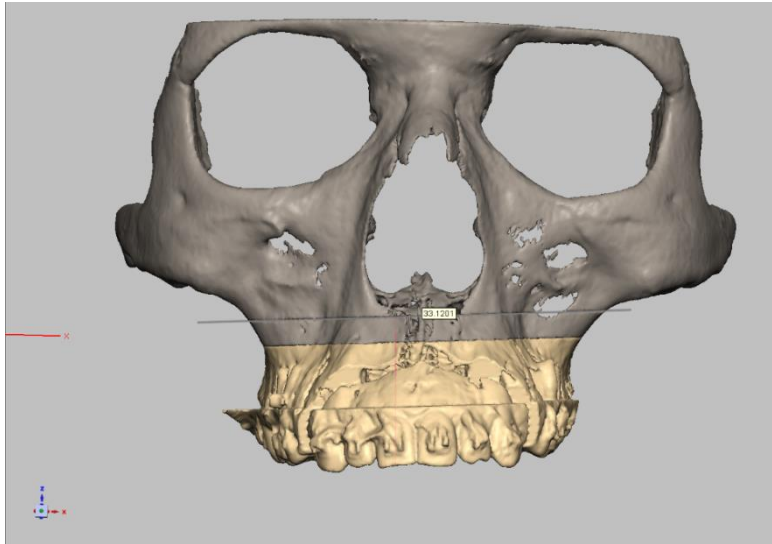
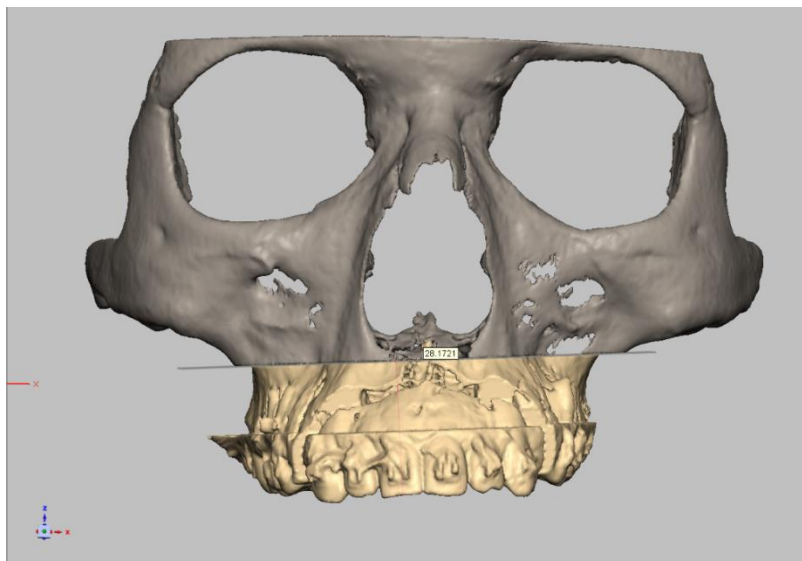


Fig.35. POST-OPERATIVE MEASUREMENTS AFTER LEFORT I MAXILLARY SET-UP 5MM MEASURED FROM TIP OF CENTRAL INCISOR TO REFERENCE FRAME-28MM



**Fig.36. VIRTUAL SPLINT FABRICATION ON POST-OPERATIVE
VIRTUAL SKULL-FRONTAL VIEW**

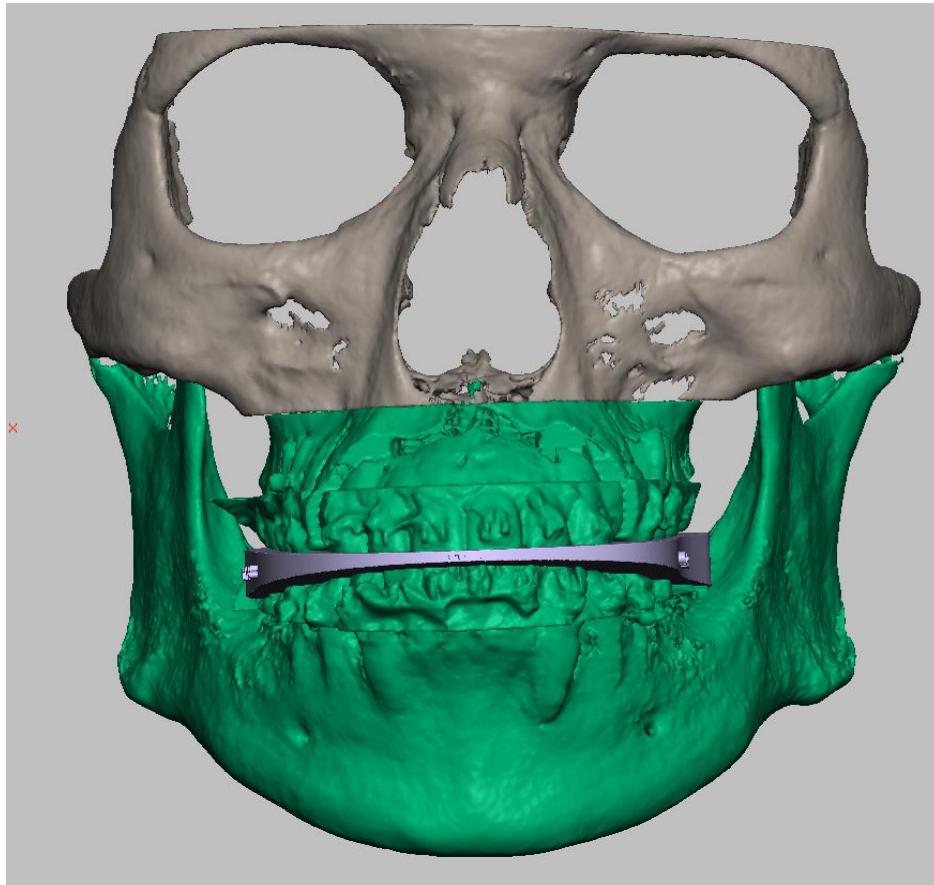


Fig.37.VIRTUAL SPLINT RIGHT LATERAL VIEW

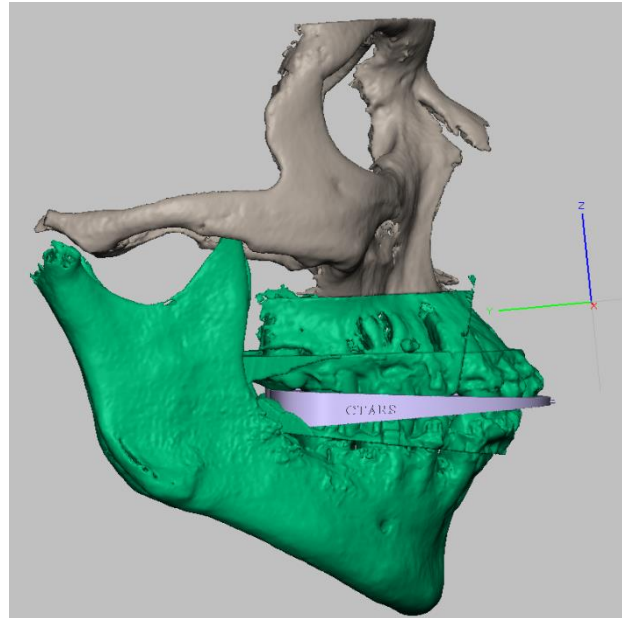
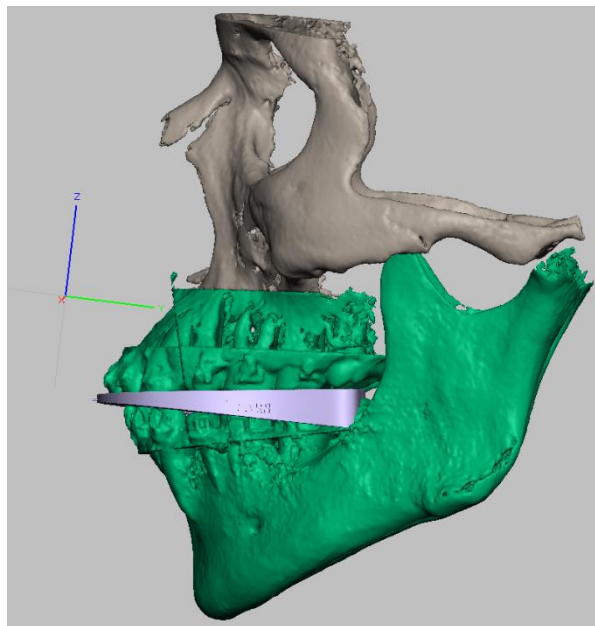
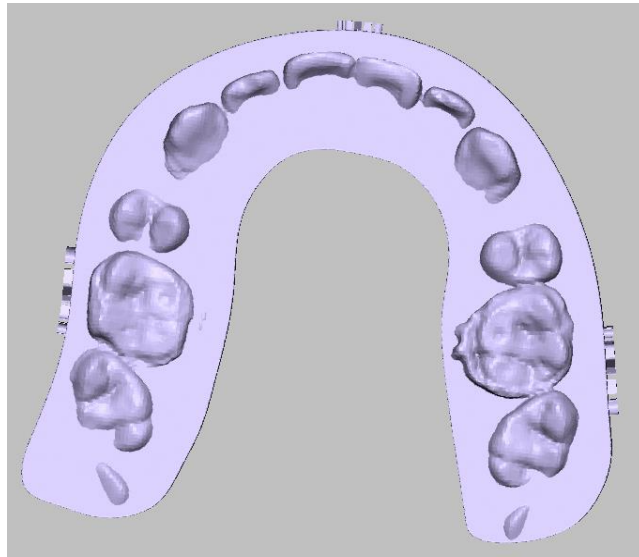


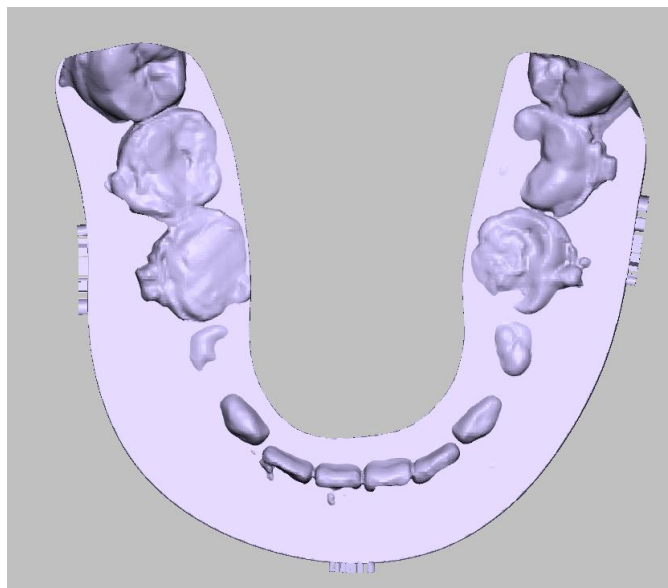Fig.38.VIRTUAL SPLINT LEFT LATERAL VIEW



**Fig.39.A INTERMEDIATE SPLINT WITH POST-OPERATIVE
MAXILLARY OCCLUSAL IMPRINTS**



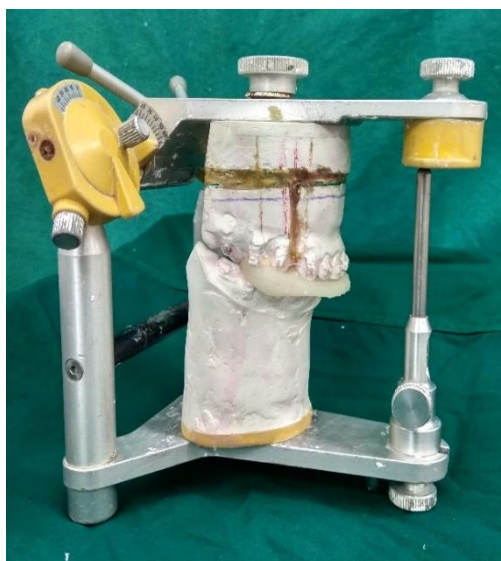**Fig.39.B INTERMEDIATE SPLINT WITH POST-OPERATIVE
MANDIBULAR OCCLUSAL IMPRINTS**



**Fig.40. A. INTERMEDIATE SPLINT FABRICATED IN
CONVENTIONAL SETUP-FRONTAL VIEW**



**Fig.40. B. INTERMEDIATE SPLINT FABRICATED IN
CONVENTIONAL SETUP-RIGHT LATERAL
VIEW**



**Fig.40. C. INTERMEDIATE SPLINT FABRICATED IN
CONVENTIONAL SETUP-LEFT LATERAL
VIEW**



**Fig 41.A. INTERMEDIATE SPLINT MANUFACTURED BY 3D
PRINTING-FRONTAL VIEW**



**Fig 41.B. INTERMEDIATE SPLINT MANUFACTURED BY 3D
PRINTING-RIGHT LATERAL VIEW**



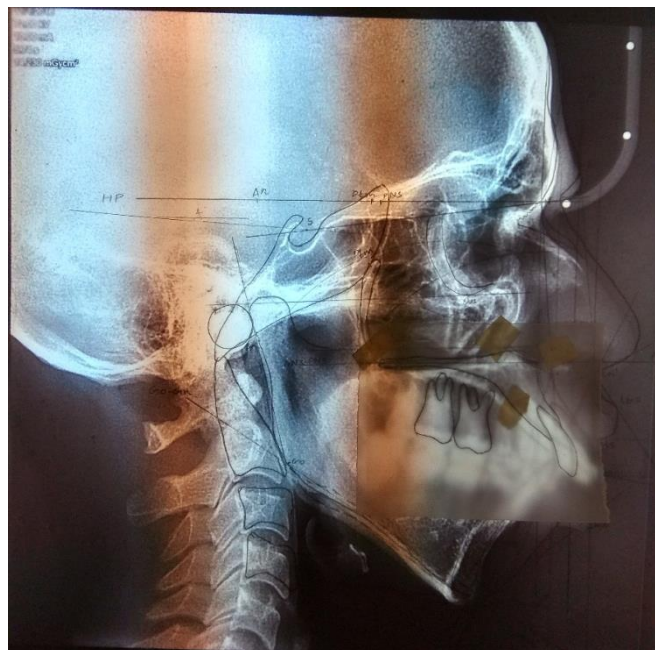
**Fig 41.C. INTERMEDIATE SPLINT MANUFACTURED BY 3D
PRINTING-LEFT LATERAL VIEW**



Fig.42. CONFIRMATION OF THE FACEBOW TRANSFER ON A LATERAL CEPHALOGRAM

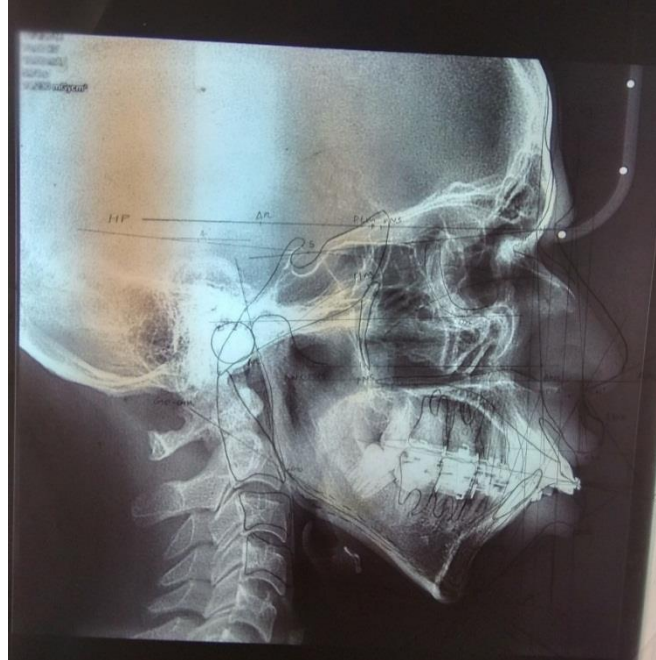

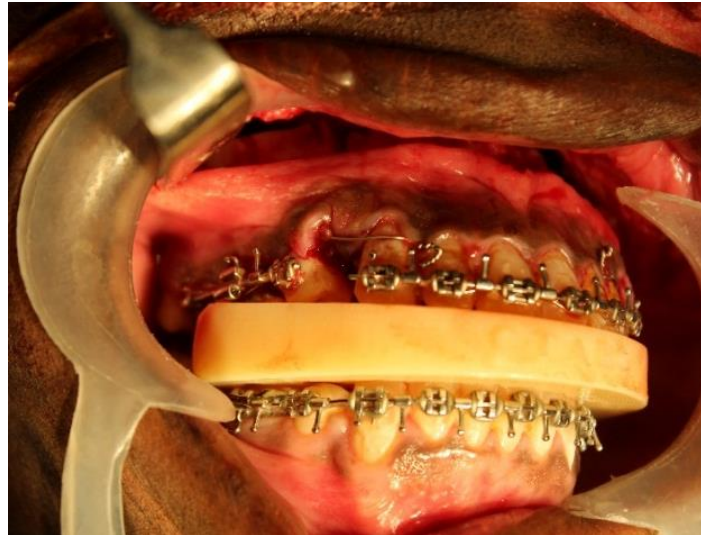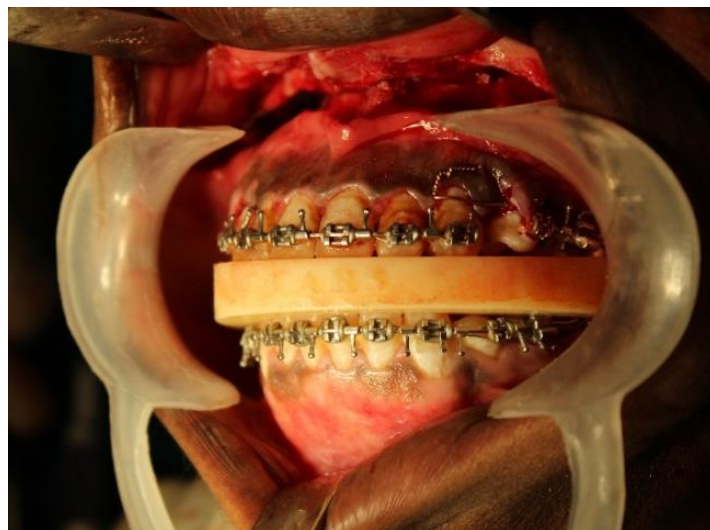
Fig.43. PREDICTION TRACING ON LATERAL CEPHALOGRAM



**Fig.44. INTRA-OPERATIVE FIT OF THE DIGITAL INTERMEDIATE
SPLINT-RIGHT LATERAL VIEW**



**Fig.45. INTRA-OPERATIVE FIT OF THE DIGITAL INTERMEDIATE
SPLINT-LEFT LATERAL VIEW**



**Fig.46. INTRA-OPERATIVE FIT OF THE DIGITAL
INTERMEDIATE SPLINT-FRONTAL VIEW**

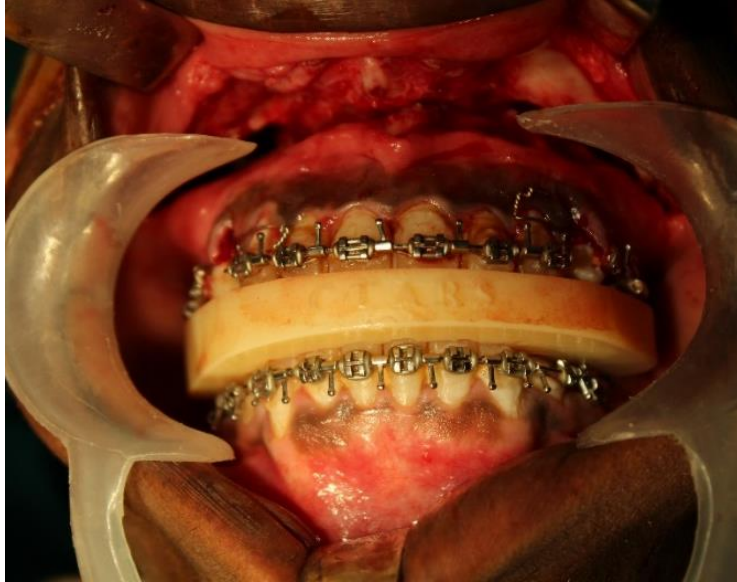


Fig.47. POST-OPERATIVE FRONTAL VIEW



Fig. 48. POST-OPERATIVE RIGHT LATERAL VIEW



Fig. 49. POST-OPERATIVE LEFT LATERAL VIEW

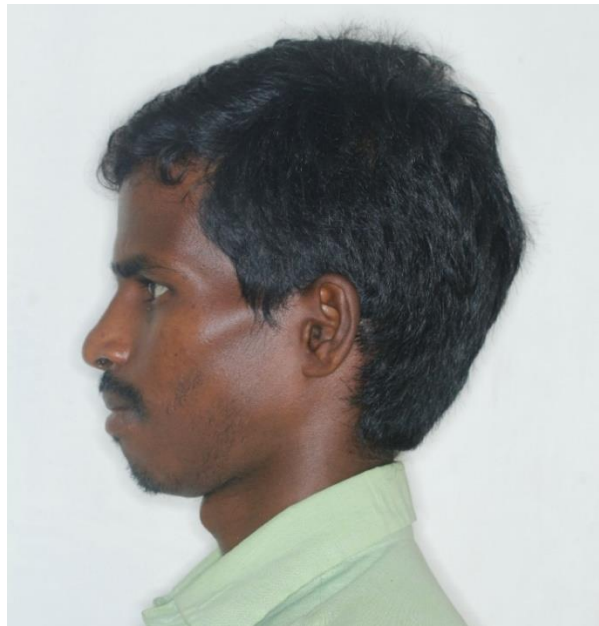

Fig. 50. POST-OPERATIVE OCCLUSION-RIGHT LATERAL VIEW

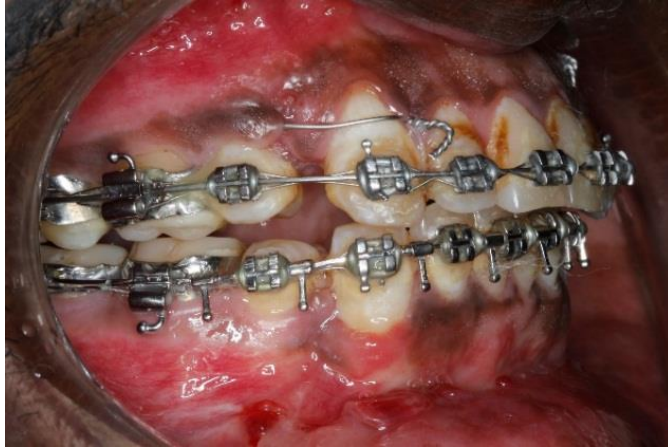


Fig. 51. POST-OPERATIVE OCCLUSION- LEFT LATERAL VIEW

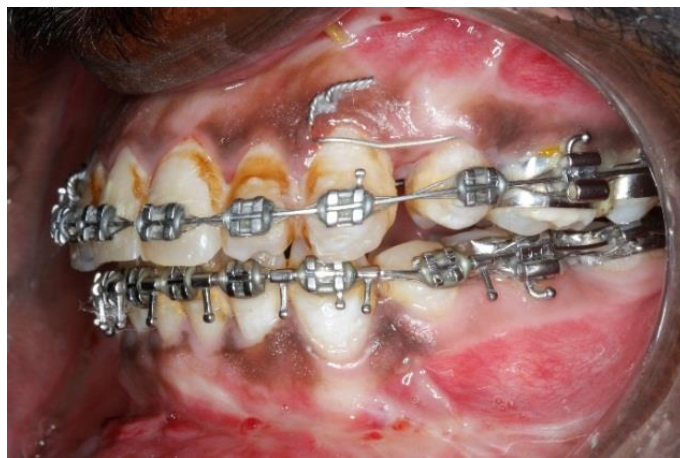

Fig. 52. POST-OPERATIVE OCCLUSION-FRONTAL VIEW

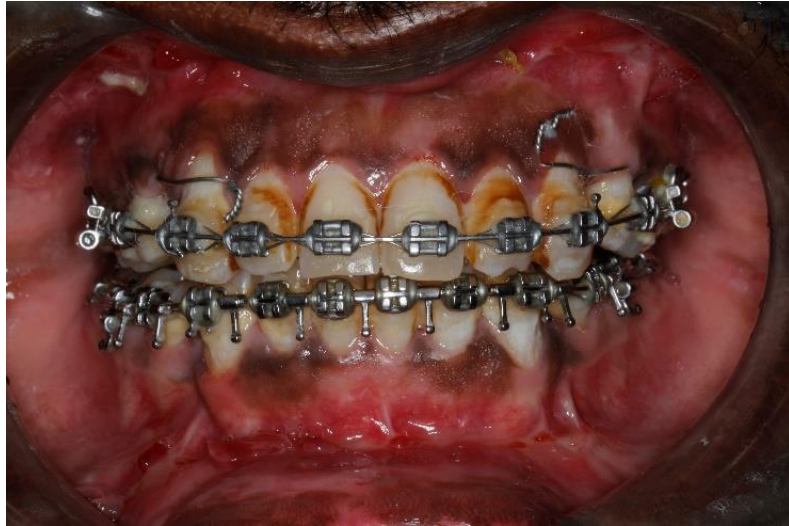

Fig. 53. KODAK CARESTREAM CBCT SCANNER

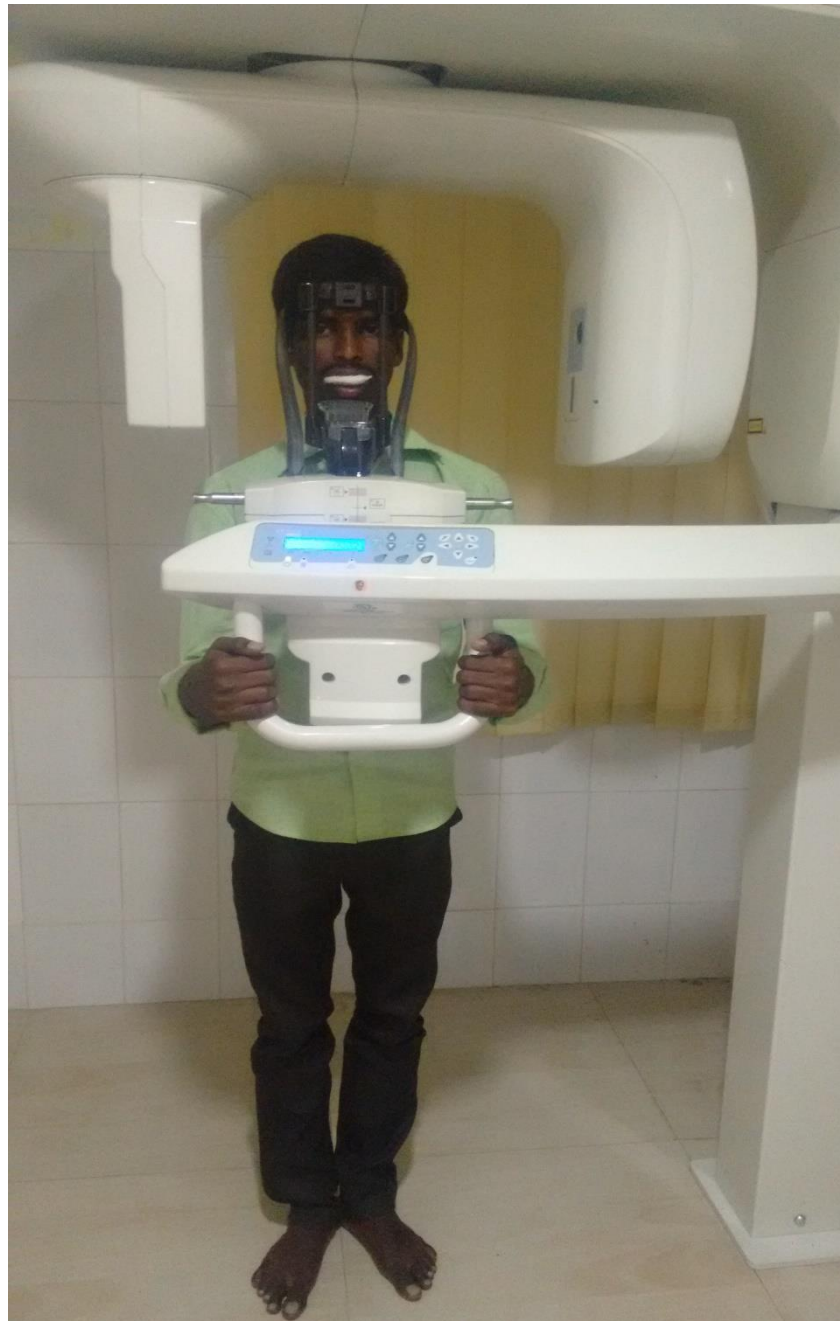

Fig. 54. STRATASYS INKJET PRINTER OBJECT 500



Fig. 55. HAPTIC DEVICE



Fig. 56.A. DIGITAL DENTAL MODELS- MAXILLA

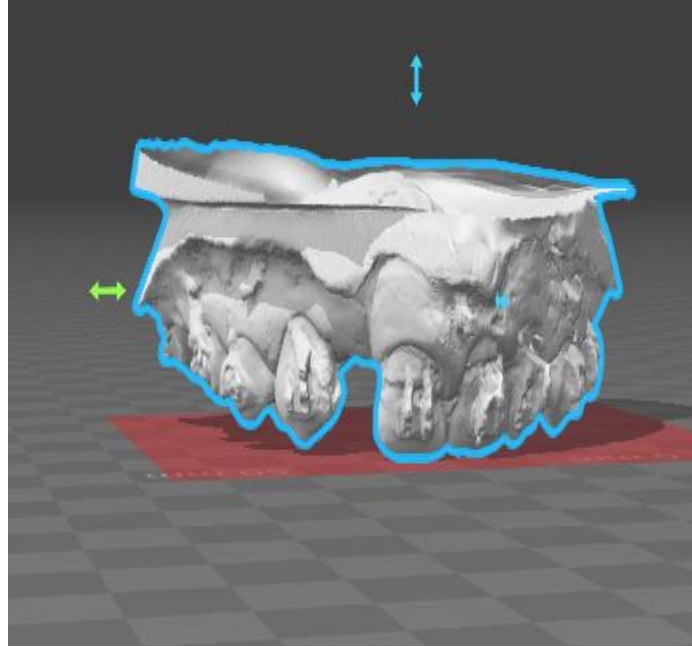


Fig. 56.B. DIGITAL DENTAL MODELS- MANDIBLE




Fig.57. FIDUCIAL TITANIUM MARKERS GLUED TO THE ATTACHED GINGIVA

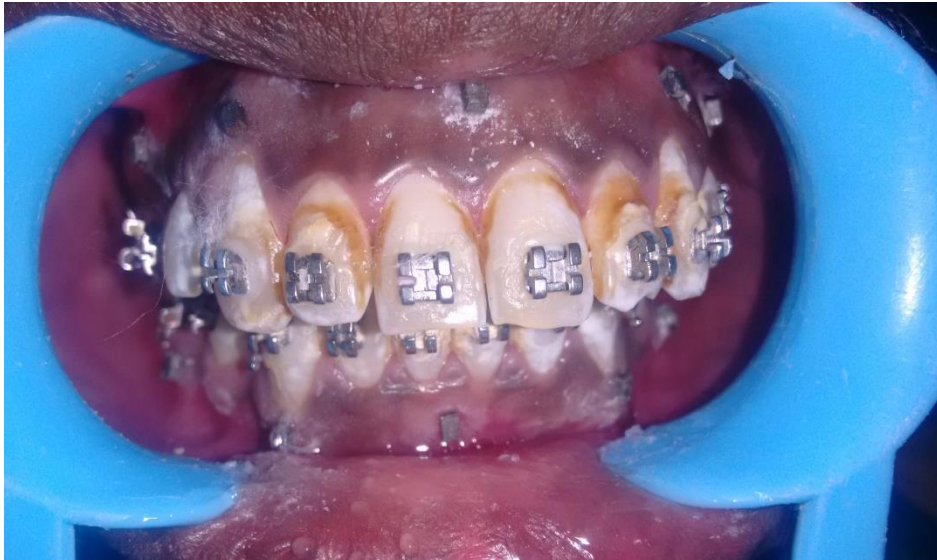
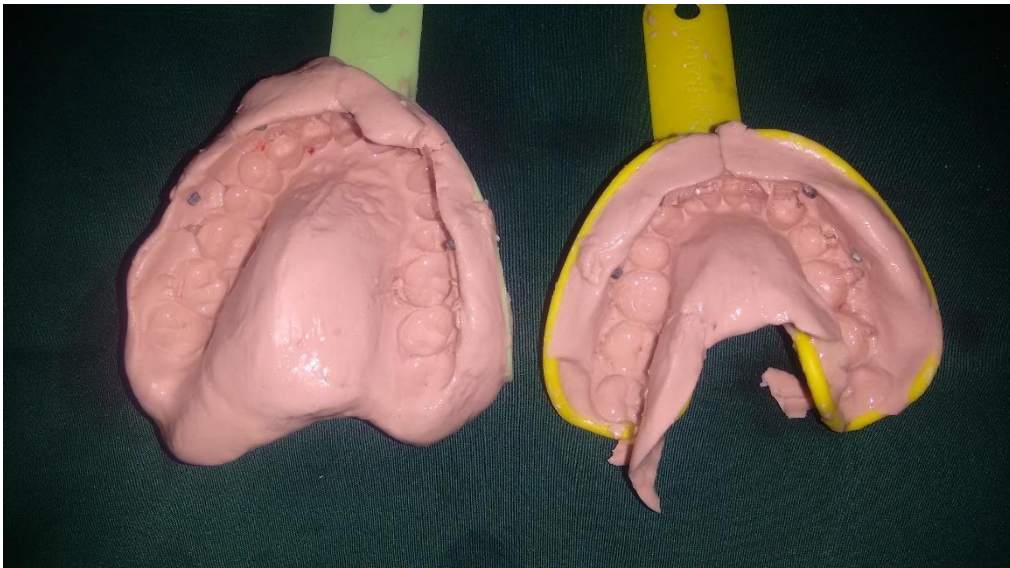
Fig.58. IMPRESSIONS OF MAXILLA AND MANDIBLE WITH THE FIDUCIAL MARKERS TRANSFERRED TO THEM



RESULTS

The present prospective, clinical study was conducted to evaluate the accuracy of fit of digital dental splints (intermediate splints) in an anatomically articulated model on which model surgery had been performed. This study was undertaken on 4 patients (Table 2) who reported to the Outpatient Department, Department of Oral and Maxillofacial surgery, Ragas Dental College, Uthandi, Chennai for aesthetic and functional correction of face. The mean age of all patients was 24 (Table 1) and the male to female ratio was 1:1 (Graph 1). None of our patients were medically compromised.

In our study two planning methods were used for each patient. A digital virtual planning and a conventional model planning. Two splints were fabricated, one being 3D printed from digital virtual planning (Figure 41) and the second one being manually made (Figure 40) from acrylic (acrylic splint) from conventional model planning. A CBCT with standardized protocol was taken for all our patients (Figure 53), with the fiducial markers glued in the attached gingiva (Figure 57), except for one patient for whom medical computed tomographic scan was taken. All our patients underwent planned surgical procedure under general anaesthesia (Table 2). All the patients in our study were followed up for a period of 6 months.

The fit of the digital and conventional splints was verified in an anatomically articulated model subjectively (Figure 40,41). The digital splints

were clinically acceptable and superior to the conventional acrylic splints. (Figure 40,41,44,45,46).

The total time needed for placement of the markers in the mouth was approximately 10 minutes. Impression making, including replacement of the markers into the impression, took approximately 5 minutes. The total time needed to produce the fusion model in the computer was approximately 30 minutes.

PATIENT 1:

The DICOM data from the cone beam computed tomographic scans showed scatter at both occlusal and gingival levels during 3D reconstruction in MIMICS due to which the fiducial markers were difficult to segment separately, which led to difficulties in superimposition. Due to these difficulties, the superimposition was made by taking three reference frames for superimposition rather than the fiducial markers. The planned surgery was performed intra-operatively without any complications.

PATIENT 2:

The DICOM data of this patient also showed scatter during 3D reconstruction in MIMICS. To avoid this the grey value for reconstruction were lowered according to the recommendations of KODAK CS 3D CBCT machine and reconstructions were made. By this method the fiducial titanium markers were separately segmented by assigning a separate grey value to these markers

and the superimposition of the digital dental scans and cone beam computed tomographic scans were made based on these fiducial markers. However, the scatter at the occlusal level which was due to metallic brackets were not eliminated. Intra-operatively, this patient with hemifacial microsomia had extensive bleeding after performing the medial cut in the mandibular ramus during Bilateral Sagittal Split Ramus Osteotomy after finishing the Lefort 1 maxillary osteotomy and plating. Due to this the planned mandibular osteotomy was not performed. The bleeding however was controlled by placing bone wax and suturing was done. There was no post-operative bleeding or complications.

PATIENT 3:

In this patient the scatter in the occlusal level was avoided by placing small rolled cotton balls over the metallic brackets. By placing cotton rolls and reducing the grey value for segmentation during reconstruction, both occlusal and gingival level scatter were removed.

Intra-operatively the planned osteotomy was performed without any complications.

PATIENT 4:

In this patient the superimposition was not marker based, a medical Computed Tomography scan was taken for this patient with bilateral temporomandibular joint ankylosis. Intra-operatively no complications were encountered.

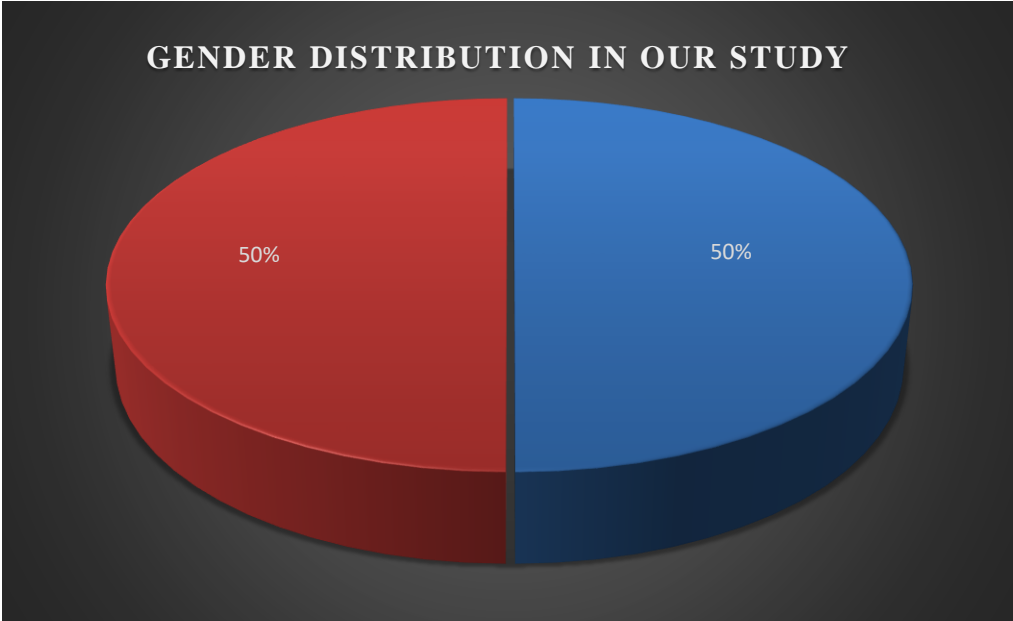
TABLE 1: DEMOGRAPHIC DATA

S.NO	AGE/SEX
1.	22/Female
2.	19/Male
3.	24/Male
4.	19/Female

TABLE 2: PLANNED SURGICAL MOVEMENTS

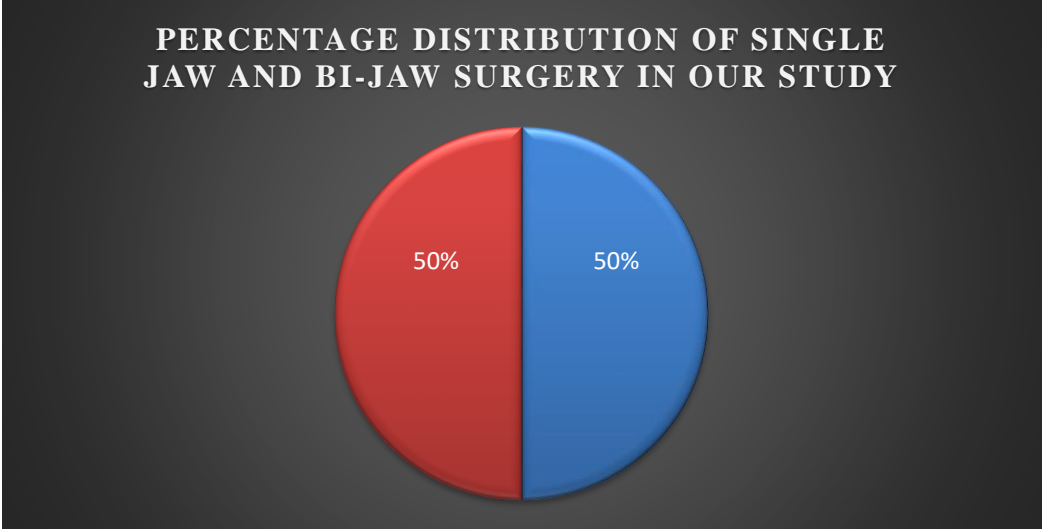
S.NO	AGE/SEX	TREATMENT PLAN
1.	22/F	LEFORT I OSTEOTOMY AND MAXILLARY SETUP -5mm BILATERAL SAGITTAL SPILT RAMUS OSTEOTOMY INTO OCCLUSION
2.	19/M	LEFORT I OSTEOTOMY AND MAXILLARY ADVANCEMENT 4mm, MAXILLARY MIDLINE CORRECTION TOWARDS RIGHT SIDE BY 2mm BILATERAL SAGITTAL SPLIT RAMUS OSTEOTOMY INTO OCCLUSION
3.	24/M	LEFORT I OSTEOTOMY AND MAXILLARY SETUP 5mm, ANTERIOR MAXILLARY OSTEOTOMY 4mm ADVANCEMENT GENIOPLASTY
4.	19/F	LEFORT I OSTEOTOMY AND MAXILLARY SETBACK 2mm BILATERAL SAGITTAL SPLIT OSTEOTOMY 8mm

GRAPH 1: GENDER DISTRIBUTION IN OUR STUDY



50%-MALES, 50%-FEMALES

**GRAPH 2: PERCENTAGE DISTRIBUTION OF SINGLE JAW AND BI-JAW SURGERY IN OUR STUDY
(50%-SINGLE JAW, 50%-BI-JAW SURGERY)**



DISCUSSION

Orthognathic surgery, a subset of cranio-maxillofacial surgery is a speciality which requires extensive pre-operative planning to obtain facial, skeletal and dental harmony. The development of this speciality traces its roots back to 1906 when the first surgery to correct a prognathic mandible was performed on a medical student by plastic surgeon Vilray Blair^[10]. Obwegeser's introduction of the sagittal split osteotomy in the 1950s^[31] and Bell's research on the vasculature of the maxilla in LeFort I osteotomy lead to the modern era in orthognathic surgery. Single jaw surgeries, however yielded predicted results without extensive planning. Bimaxillary surgery was more difficult to predict than single jaw surgery which was due to its greater complexity. The traditional diagnostic work up in planning orthognathic surgery includes clinical examination, photographs, radiologic investigations and cephalometric analysis, impression making, plaster model preparations, facebow transfer and articulating in patient's occlusion, mock model surgery and manual splint fabrication. The goal of this work-up was to accurately reproduce the relationship of the maxilla, mandible and the associated dentition upon which model surgery would be performed eventually and surgical splints which were necessary for the positioning of maxilla and mandible would be fabricated. This technique, however, requires extensive time and has the potential to have inaccuracies amplified during the process. With the advent of virtual

orthognathic surgery, the flaws in the conventional orthognathic planning have been rectified easily. [15], [23], [28], [37], [44]. Our study emphasises on virtual planning in orthognathic surgery and 3D printing the intermediate splints; highlighting on the fusion of CBCT scans with digital dental scans. It is impossible to extract dentition from CBCT scans due to scattering and noise produced by metallic brackets at the occlusal level [40], [50], therefore in our study we used dental scans [8], [9], [32], [38] to replace dentition in the CBCT scans. Titanium markers of standard dimensions (1*1.5*2mm) (Robinson's Mill, Avadi, Chennai, TamilNadu) were glued to the attached gingiva, 2-3mm above the gingival margin as this region is not influenced by scatter at the level of occlusal plane. These markers showed scatter after normal 3D reconstruction, therefore they were segmented separately with a grey value of 3500 which resulted in extraction of the markers alone without any scatter. This method of integration avoids the use of external bite jigs which causes soft tissue distortion or the need for a double CBCT scan procedure. The markers were glued to the gingiva using Truseal Dermabond (N-butyl-2-cyanoacrylate glue) which was approved for clinical use since 1996^[12]. In 2 patients, these markers were loose after contact with saliva and tongue, therefore patients were instructed not to touch these markers. Not all markers remained embedded in the impression, after the alginate impression was removed from the patient's mouth, however the imprints of these markers were identified easily on the impression and they were replaced accurately by the titanium markers using their imprints as guide.

CONVENTIONAL ORTHOGNATHIC SURGICAL PLANNING & ITS INHERENT ERRORS

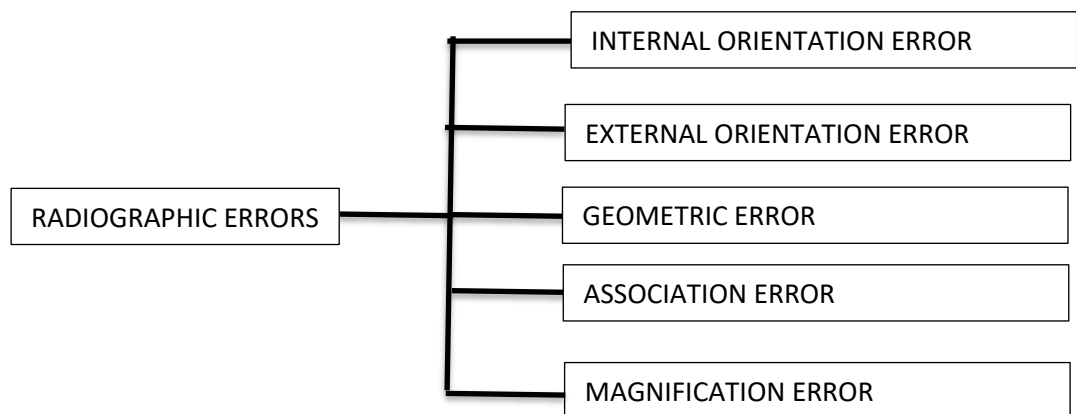
1. ERRORS IN CLINICAL ASSESMENT:

The clinical assessment of face is the most valuable diagnostic procedure. This aesthetic evaluation is performed in natural head position with lips relaxed and teeth in centric occlusion. An error may be incorporated if this examination is not done in the above-mentioned position, which can influence the treatment planning.

In our study all the patients were systematically examined in natural head position (i.e., Frankfort's line and interpupillary line parallel to the floor), with relaxed lips and in centric occlusion. (Figure53).

2. RADIOGRAPHIC ERRORS

Conventional X-rays are two-dimensional representation of three-dimensional data and may have incorporated errors such as ^[23]



INTERNAL ORIENTATION ERROR

Internal orientation error is the error which occurs due to differences in 3D relationships of patient relative to the central x-ray beam and the imaging device and can be reduced only when the patient's position is consistent and specific. ^[23] To avoid this the patients were instructed not to swallow saliva or move as this would affect the postural head position.

EXTERNAL ORIENTATION ERROR

External orientation error is the error which occurs due to inaccuracies in three-dimensional orientation of imaging device, patient stabilizing device and image recording device and can be reduced only when the distance between x-ray source and cephalostat is 60 inches. In our study, the above-mentioned distance was standardized.

GEOMETRIC ERROR/MAGNIFICATION ERROR

Geometric error is the error due to projection distance between imaging device, recording device and the patient. Objects far from film are magnified more than objects closer to it. The lateral cephalogram has an inherent magnification error of 6-7% ^[23]. Thus, cephalometric landmarks are not stable and their location in a lateral cephalogram is not standard due to the associated errors in superimposition and magnification especially in patients with facial asymmetry.

In our study a Cone Beam Computed Tomographic scan was used, which had reduced absorbed and effective dose compared with the conventional CT's overcoming the flaws in conventional two-dimensional radiographs. ^[13]

[18], [21], [23], [48]. The absorbed dose of bone marrow of mandible was found to be 1.67mGy and effective dose was 0.035mSv in non-shielding technique and absorbed dose of 1.64mGy in bone marrow of mandible and effective dose of 0.035mSv in shielding technique. [50]

3. ERRORS IN IMPRESSION MAKING

In patients with orthodontic brackets and wires, impression making process is quite often tedious and alginate undergoes dimensional distortions leading to changes in the plaster models and poor surface details.

With the introduction of intra-oral scanning and digital dental models, the need for an impression making process is eliminated. [8], [22], [32], [37], [38], [56] (Figure 56 A,B)

4. ERRORS IN FACE-BOW TRANSFER

Articulators are based on the principle that condyles rotate around a hinge axis, but research conclude that they rotate around a single point [11]. They are however unable to simulate the combined rotational and translation of condyles during their movements. Zizelmann^[14] in their study concluded that the traditional use of face-bow devices showed inaccuracies in model mounting as well as in assignment of anatomic reference planes. Errors at this stage lead to inaccuracies in splint fabrication, which results in unplanned surgical movements [1]. In our study facebow transfer in the conventional setup was verified in the lateral cephalogram by measuring the distance from

the canine tip and the mesiobuccal cusp tip of the first molar to the base of the mounting plate in the articulator and marking these in the lateral cephalogram as arcs and connecting the them. These arcs when transferred to the horizontal plane must make an angle of 0 ± 4 degrees. In our study the angulation was 2 ± 1 degrees. (Fig.42)

The need for a facebow transfer is eliminated in virtual planning in orthognathic surgery since the relationship of maxilla, mandible to the cranial base is exactly established in CBCT scans ^[46].

5. ERRORS IN MODEL SURGERY

Manual model surgery is a laboratory-based procedure that is time consuming. Literature concludes that model surgery contains potential errors such as marking the reference lines, sectioning the casts, repositioning the maxilla in three planes and measuring the surgical movement of these segments ^[1]. These methods can be accompanied with inaccuracies such as 3D movement in space, repeated measurements and the proficiency of individuals performing the procedure.

Simulating the planned surgery on plaster models is difficult owing to the lack of correlation between cephalometric analysis and the performed plaster model surgery. Rotational and translational movements of plaster models are not controlled during manual model surgery which gets incorporated into the splint. ^[28] The innovations in software and technology makes 3D translational and rotational

movement of digital model surgery easy to stimulate. [24], [35], [58] In our study, model surgery was performed in MIMICS (version 17.0 Belgium, Leuven) and the osteotomy was saved in 3-matic. (Materialize 3-matic, Leuven, Belgium)

6. ERRORS IN SPLINT FABRICATION

Conventional orthognathic splints are manufactured using acrylic, which may be subjected to deformational changes owing to polymerization shrinkage leading to errors that gets transferred to the operating room. [1], [11]

In our study the 3D splints were fabricated by importing the STL files into a 3D printer (Inkjet printing technology, Stratasys, Figure 54). These splints are manufactured by photopolymer which is more dimensionally stable than conventional acrylic [43].

PHOTOPOLYMER PROPERTIES- VEROWHITE (Biocompatible MED610 and MED620)

These materials are tested for

- 1.Cytotoxicity
- 2.Genotoxicity
- 3.Delayed type Hypersensitivity
- 4.Irritation
- 5.USP plastic class VI

Tensile strength: 50-65 MPa

Flexural strength: 75-110 MPa

Youngs modulus: 2.8GPa

Elongation at failure: 6.2%

Izod Impact Notched: 20-30 J/m

Heat deflection temperature: 58.4 degrees Celsius

These materials are approved for skin contact up to 30 days and mucosal contact of 24 hours.

Gateno et al in his study of comparing the conventional and the stereolithographic wafers concluded that the 3D printed splints had more accuracy. ^{[15], [44]}

DIGITAL PLANNING IN ORTHOGNATHIC SURGERY

The introduction of cone beam computed tomographic scans has led to advances in 3D imaging and virtual surgical planning in orthognathic surgery. Computer assisted surgery includes all forms of surgical planning and execution that includes advanced imaging, software analysis, virtual planning, 3D printing and image guided surgery. Computer assisted surgery of cranio-maxillofacial skeleton exists in two forms.

1. Template guided surgery
2. Image guided surgery (Navigational)

Template based surgery is a more familiar paradigm for craniomaxillofacial surgeons. These templates can be 3D printed wafers, stereolithographic models and custom-made plates and screws which transfer

the treatment plan from the virtual environment to the operating room. The improvement in computer aided surgery is a result of increased availability of low radiation imaging technology and powerful commercially available software packages that allows visualizing and stimulating operations. Using 3D digital datasets, surgery can be made more predictable, reducing the operating time in operation theatre. Digital models can be prepared by Intra-oral scanning or scanning the plaster casts which can then be matched to the CBCT of the patient for a composite skull model with better accuracy.

WORKFLOW IN DIGITAL PLANNING IN OUR STUDY

1. DATA ACQUISITION

The DICOM (Digital imaging and communication in medicine) data sets are acquired from CBCT scans in all the patients and imported into Materialize software.(MIMICS version 17.0 Belgium). CBCT scans were obtained from Kodak Carestream 9300 machine (Figure 53).

Specifications

Sensor type: TFT

Focal spot size: 0.7mm

Scan mode: continuous and pulse

CBCT scanning time: 12-28 seconds (+/- 10%)

Voxel shape: isotropic

Reconstruction time: Less than 2 minutes based on the recommended computer system configuration requirements

Tube voltage: 60-90kV

Tube current: 2-15mA

Input voltage (AC): 220/230/240 V, 50/60 Hz

Weight: 160 kgs (353 lb), with cephalometric module: 199 kg (438 lb)

Footprint: 120 x 160 cm (45.5 x 62.8 inches), with cephalometric module: 215 x 160 cm (84.6 x 62.8 inches)

2. DATA RECONSTRUCTION

The data imported was reconstructed by thresholding, segmenting and assigning grey values to both bone and soft tissues before thresholding. The planned osteotomy and splints were performed virtually in Materialize software and Haptics. They were saved in 3-matic software.

3. 3D PRINTING

The intermediate splints were virtually fabricated and were saved as .stl files and imported into a 3D printer (Stratasys- Inkjet printing), this is one of the techniques of additive manufacturing called material extruding/jetting that jets a liquid from the print head (nozzle) which is solidified by UV light and with microscopic layer resolution and accuracy down to 0.1mm and can print up to 14mm/h.

DIGITAL IMAGING

In the quest for the “ANATOMIC TRUTH”, Cone beam computed tomography scan has always been a boon to the surgeons. This is a medical imaging system introduced in 1990 which uses a cone shaped x-ray beam centered on a two-dimensional detector. Scanning in vertical natural seated position, low cost, low radiation dose and accessibility makes it a keystone in planning orthognathic surgery virtually. The various imaging techniques are:-

1. HARD TISSUE IMAGING TECHNIQUES

Multislice computed tomography

Cone beam computed tomography

Magnetic resonance imaging

2. SOFT TISSUE IMAGING TECHNIQUES

3D ultrasonography

3D surface laser scanning

3D stereophotogrammetry

Magnetic resonance imaging

SOFTWARES

The software enables the surgeon to interact with the 3D images more precisely. The data can be stored and transferred as DICOM (Digital imaging and communication in medicine) datasets which facilitates easy data handling process. However a single software cannot stimulate all the purpose of virtual planning such as marking osteotomy lines, 3D cephalometry, 3D virtual planning, prediction of post-operative outcomes and construction of the virtual

splint and saving all this data. Therefore the identification of a more demanding software with all the stimulations is still under research. These softwares can be as follows: -

1. Open source
2. Bundled viewer
3. Third party softwares.

In our study third-party software was used, MIMICS (Version 17.0 Belgium) for 3D reconstructions and planning the osteotomies, Haptics (GeoMagic U.S.A.) for virtual tactile perception during creating the osteotomy lines and 3-Matic software (Materialize 3-matic, Leuven, Belgium) to save all the planned data.

DIGITAL DENTAL MODELS

The image quality obtained by a CBCT is however not sufficient for precise presentation of occlusal configuration and intercuspation ^{[23], [29], [32], [44]}. This is due to fact that teeth have different compositions from bone, which affects the deflection of x-rays during radiographic capture of face and due to streak artefacts produced from orthodontic brackets and metallic restorations. Thus, the elimination of these scatter would enable better visualization of dentition and jaws which would influence planning and quality of treatment. With the shift in data type from analog to digital, the dental stone model is replaced by Digital dental models (Figure 56 A, B). By linking these data sets,

a 3D patient model, including bony skeleton, dentition and facial soft tissues (untextured) can be created [22], [29], [44], [49], [51], [53]. The patient's dentition can be digitized by four imaging techniques namely:

1. Digitization of plaster cast with CBCT scanner, laser scanner or moire topography
2. A digital data set reconstructed by CBCT
3. CT or laser scanned impression
4. Intra-oral scanning and obtaining digital impressions.

Digitization of plaster casts can be done with CBCT scanner, laser scanner or moire topography. This was done after making the impressions and scanning the casts. The plaster models were optically scanned. This can be stored (<1MB) and peer-viewed multiple times. In this technique although artefacts were reduced, it was mandatory to fabricate the casts.

The second method included a CBCT scan of the patient and using the DICOM images to render a 3D volume of the dentition. Dental imaging derived from CT data have important disadvantages such as metal restorations, brackets which generated streak artefacts. Therefore, this method was not suitable for capturing the dentition for planning orthodontic therapy and orthognathic surgery.

The third method was to scan the dental impression of the dental arches with a CBCT scanner. Without the need for a plaster cast, a digital dental model

with the correct relationship between the upper and lower arch was reconstructed from the CBCT data.

The fourth method was taking a digital impression with intra-oral scanning devices. With this, the 3D data of the dentition were directly captured without the need for impression material or pouring the plaster cast.

In our study the plaster dental models were scanned and digital models were obtained. These digital dental casts can be stored on any storage device (<1MB) and viewed at multiple locations (peer view communication).

FUSION OF DIGITAL DATASETS

Image fusion is the process of converting two or more different coordinates into a single data set. The fusion of data sets can be done by either of these methods.

1. Surface based registration
2. Point based registration
3. Voxel based registration

IMAGE FUSION CHALLENGES

The patients in our study had orthodontic brackets and metallic restorations due to which surface-based image fusion was unreliable due to improper visualization of structures. Several studies have used intra-oral reference devices or bite jigs for the fusion, however these methods are time

consuming and most of the bite-jigs cause soft tissue distortion which inhibits reliable judgement of the soft tissues at rest.

Gateno and associates^[16] developed a technique of fusion using a bite jig with fiducial markers attached to it. The patient wore the bite jig when the CBCT scan was made, after which the bite jig was scanned together with the impressions. After data processing, the fiducial markers were visualized on both the CBCT scan and the scan of the bite jig with the impressions. Both datasets were surface matched, using the fiducial markers as reference points. The disadvantage of this method is that the fiducial markers are positioned outside the mouth and produce distortion of the soft tissues which prevents reliable judgement of the patient's soft tissue anatomy.

Swennen et al^[32] developed a triple scan method, using an impression tray in which both the upper and lower jaws are registered. CBCT scan with a large field of view was made of the patient at rest. Next, a low-resolution CBCT scan with a small field of view was made, with the impression tray placed in the mouth. Finally, the impression tray was scanned separately with high-resolution. Impression scan was registered into the CBCT scan of the patient using voxel based registration, using the impression tray in the low-resolution scan as reference. The major disadvantage of this technique was that:

1. Two CBCT scans of the patient were required, necessitating increased radiation exposure.

2. The digital data handling processes was time consuming.

To overcome these difficulties, we have incorporated small fiducial titanium markers of standard dimensions 1*1.5*2cm (Robinsons Mill, Avadi, Chennai, TamilNadu) that is placed on the attached gingiva using tissue adhesive (True seal Dermabond, N-butyl-2-cyanoacrylate glue)^[12] for point-based image fusion process. The markers were segmented separately with a grey value of 3500 in both the CBCT scans and in the digital dental models and fused by point based image fusion. The aim of our study was to evaluate the accuracy of fit of digital dental splints (intermediate splints) in an anatomically articulated model. Previous studies compared the digital dental splints with conventional manual splints and considered that as ground truth, which was actually not correct ^[57]. Few studies reported mean errors which may underestimate the magnitude of error ^[57]. Therefore, our study was carried out in the intention to compare the fit of 3D printed splints on an anatomically articulated model on which planned model surgery was performed.

The final splints were not printed in our study. This is due to the lack of collision detection property in the commercially available software packages. Collision detection is one of the software property in which contact between two virtual objects (teeth and cast) prevents them passing through each other, preventing the inaccuracies in splint. This is an essential property in developing final occlusion and this property is poorly developed in the current software packages. As a result, the fabrication of surgical splints in final occlusion is not

advised^[49]. The benefits of this technology could be realized in the intermediate splints. Our study uses the intermediate splints for evaluation in an anatomical articulator. Most of the surgeons refer to tactile feedback that comes from hand articulating stone models to get a sense of perfect occlusion in manual model surgery setup, which becomes difficult in virtual planning due to lack of collision detection and for this reason the final orthognathic splints were not 3D printed and evaluated.

Herman F Sailer^[49] in their study on 8 patients undergoing bimaxillary orthognathic surgery concluded that the highest precision for the wafers was observed in patients with CAD/CAM splints (<0.23 mm; $P > .05$) followed by surgical "waferless" navigation (<0.61 mm, $P < .05$) and classic intermaxillary occlusal splints (<1.1 mm; $P < .05$). Only the innovative CAD/CAM splints kept the condyles in their central position in the temporomandibular joint. They concluded that CAD/CAM splints and surgical navigation provide a reliable, innovative, and precise approach for the transfer of virtual orthognathic planning.

In our study, two planning methods were used for each patient, digital virtual planning and conventional model planning. Two intermediate splints were manufactured for every patient, Conventional Acrylic Intermediate splint and Digital 3D printed intermediate splint. The fit of the digital splint was verified on the articulator in which conventional model surgery was performed and we found that the fit of the digital splints was superior than that of

conventional acrylic splints thus overcoming the flaws in conventional manual model surgery.

SUMMARY AND CONCLUSION

In this era of evidence-based dentistry, pre-surgical planning is essential for predictable result of orthognathic surgery. In this prospective clinical study, we presented orthognathic surgical planning by both conventional setup and digital setup for each patient (Table 2) and evaluated the accuracy of fit of the Digital Intermediate Splint in an anatomically articulated model on which manual mock model surgery had been performed (Figure 40,41). The results of our study indicate that although the learning curve for virtual technology was high, the use of 3D planning and 3D printing aids in achieving better understanding and appreciation of the patient's three-dimensional anatomy and thus formulating an accurate treatment plan. A major paradigm shift from routine planning to 3D virtual planning would take time until these advanced techniques becomes easily accessible, user friendly and affordable at a relatively low cost. Previous researchers have compared the digital splints to the conventional splints which is not considered the ground truth for comparison. In our study the digital splints were evaluated by verifying their accuracy of fit in an anatomically articulated model in which intended model surgery was performed. In our study fiducial titanium markers were used for the reference points for superimposition. The advantages of using intra-oral fiducial markers were:

1. No soft tissue distortion due to external bite jigs as in other studies was noted.

2. No need for a triple scan technique as in previous studies, thus prevented the amount of radiation exposure.

These fiducial markers of standardized dimensions were glued to the attached gingiva in the dental midline, canine and first molar regions (5 markers in each arch). They were glued to the attached gingiva as this wouldn't interfere with the scatter at the occlusal level due to the metallic brackets. The CBCT scans and digital dental models were superimposed based on these fiducial markers. The accuracy of superimposition of the two data sets was objectively evaluated by observing the distance between the corresponding markers in CBCT scans and dental scans after superimposition. An accurate match ensured that the corresponding markers were perfectly matched without any distance in between them.

ADVANTAGES OF OUR STUDY

1. Intra-oral fiducial titanium markers were used rather than external reference frame or the use of a triple scan.
2. Digital dental scanning of the casts to avoid the distorted teeth in a CBCT scan.
3. The use of a CBCT in our study reduces the radiation exposure compared to a conventional medical CT.
4. Comparison of the intermediate digital splint in an anatomical articulator rather comparing with a conventional splint.

5. Both Conventional and Digital planning methodology was used for each patient, so that the comparison of digital and conventional splints in an anatomically articulated model would be more reliable.
6. The total time required for virtual planning was less than an hour.

DISADVANTAGES OF OUR STUDY:

1. Although 3D planning and 3D printing aids the surgeon, it requires high technical support and trained personnel.
2. Longer learning curve.
3. Cost and availability of virtual planning and 3D printing.
4. Smaller sample size.

CONCLUSION:

The fit of the digital dental splints (intermediate splints) was subjectively more superior to the conventional splints intra-operatively and in an anatomically articulated model. However, the application of Digital Splints in routine orthognathic surgical planning will take longer time as the use of virtual planning and 3D printing technology is limited due to its affordability. Further, the employment of this technology in larger scale will eventually make this more affordable. Henceforth, there will be an era in the future, when the entire orthognathic surgical planning would be planned and executed with high precision and reliability using 3D planning and printing technology.

BIBLIOGRAPHY

1. **A, Nattestad, P. Vedtofte.** Pitfalls in orthognathic model surgery. The significance of using different reference lines and points during model surgery and operation. September 1994. *Int. J. Oral Maxillofac. Surg*, 23:11-15
2. **A. B. Strong, S. Lobregt and F. W. Zonneveld.** Applications of three-dimensional display techniques in medical imaging. May 1990. *Journal of Biomedical Engineering* 12(3): 233-238
3. **ApproaShaheen E, Sun Y, Jacobs R,** Three-dimensional printed final occlusal template for orthognathic surgery: design and validation. *International Journal of Oral & Maxillofacial Surgery*, 2016. (2): 1-5
4. **Ayoub AF, Rehab M, O'Neil M, Khambay B, Ju X, Barbenel J, .** A novel approach for planning orthognathic surgery: The integration of dental casts into three-dimensional printed mandibular models. *International journal of oral and maxillofacial surgery* 2014;43(4): 454-459.
5. **Barbenel JC, Paul PE, Khambay BS,** Errors in orthognathic surgery planning: the effect of inaccurate study model orientation. *Int J Oral Maxillofac Surg* 2010; 39:1103–8.
6. **Cevidanes LH, Bailey LJ, Tucker SF, Styner MA, Mol A, Phillips CL, Proffit WR, Turvey T.** Three-dimensional cone-beam computed

tomography for assessment of mandibular changes after orthognathic surgery. *Am J Orthod Dentofacial Orthop* 2007; 131: 44–50

7. **Choi JY, Song KG, Baek SH.** Virtual model surgery and wafer fabrication for orthognathic surgery. *Int J Oral Maxillofac Surg* 2009; 38:1306Y1310.
8. **Dieter Dirksen, Steffen Diederichs, Christoph Runte, Gert von Bally, Friedhelm Bollrann.** Three-Dimensional Acquisition and Visualization of Dental Arch Features from Optically Digitized Models. *Journal of Orofacial Orthopedics* 1998 60(9) 152-159
9. **E Nkenke, S Zachow, M Benz, T Maier, K Veit, M Kramer¹, S Benz¹, G Hausler, F Wilhelm Neukam and M Lell,** Fusion of computed tomography data and optical 3D images of the dentition for streak artefact correction in the simulation of orthognathic surgery. *Dentomaxillofacial Radiology* (2004) 33, 226–232
10. **E. W. Steinhauser.** Historical development of orthognathic surgery. *Journal of Cranio-Maxillofacial Surgery* (1996) 24, 195-204.
11. **Edward Ellis III** Accuracy of Model Surgery: Evaluation of an Old Technique and Introduction of a New One. 1990 *J Oral Maxillofac Surgery* 1161-1167.
12. **G. A. Greenhill and B. O'Regan,** “Incidence of hypertrophic and keloid scars after N-butyl 2-cyanoacrylate tissue adhesive had been used to close parotidectomy wounds: a prospective study of 100

consecutive patients,” *British Journal of Oral and Maxillofacial Surgery*, vol. 47, no. 4, pp. 290–293, 2009.

13. **G.N.Hounsfield**. Computerized transverse axial scanning (tomography): Part I. Description of the system 1973, *British Journal of Radiology*, 46, 1016-1022.
14. **G.William Arnett, Robert T.Bergman**. Facial keys to orthodontic diagnosis and treatment planning Part 1, April 1993 *American Journal of Orthodontics and Dentofacial Orthopedics*.103 (4) 299-312.
15. **Gateno J, Xia J, Teichgraeber JF**, The precision of computer-generated surgical splints. *J Oral Maxillofac Surg* 61:814-817, 2003
16. **Gateno J, Xia J, Teichgraeber JF**: A new technique for the creation of a computerized composite skull model. *J Oral Maxillofac Surg* 61:222-227, 2003
17. **Graham Rabey**. Craniofacial Morpho analysis, Section of Odontology Royal Society of Medicine. 1971 February64(2):103-111.
18. **Grauer D, Cevidanes LS, Proffit WR**. Working with DICOM craniofacial images. *Am J Orthod Dentofacial Orthop*. 2009; 136:460–470.
19. **Hsu SS, Gateno J, Bell RB**, Accuracy of a computer-aided surgical simulation protocol for orthognathic surgery: a prospective multicenter study. *J Oral Maxillofac Surg* 2013; 71:128–42
20. **J. Vander Sloten, K. Degryse, R. Gobin, G. Van der Perret, M. Y. Mommaerts**. Interactive simulation of cranial surgery in a computer

aided design environment. May 1996 Journal of Cranio-Maxillofacial Surgery 24, 122-129.

21. **James Xia, Member, IEEE, Horace H. S. Ip, Member, IEEE, Nabil Samman, Helena T. F. Wong, Jaime Gateno, Dongfeng Wang, Richie W. K. Yeung, Christy S. B. Kot, and Henk Tideman.** Three-Dimensional Virtual-Reality Surgical Planning and Soft-Tissue Prediction for Orthognathic Surgery. June 2001 IEE Transactions on information technology in biomedicine, VOL. 5, NO. 2: 97-106
22. **Joanneke M. Plooij, Thomas J. J. Maal, Piet Haers, Wilfred A. Borstlap, Anne Marie Kuijpers-Jagtman, Stefaan J. Berge´.** Digital three-dimensional image fusion processes for planning and evaluating orthodontics and orthognathic surgery. A systematic review. Int. J. Oral Maxillofac. Surg. 2011; 40: 341–352
23. **Juan Carlos Quintero, Andrew Trosien, David Hatcher, Sunil Kapila.** Craniofacial Imaging in Orthodontics: Historical perspective, cuurent status, and future developments. November 1999 The Angle Orthodontist 69(6): 491-505
24. **Kim BC, Lee CE, Park W,** Clinical experiences of digital model surgery and the rapid-prototyped wafer for maxillary orthognathic surgery. Oral Surg Oral Med Oral Pathol Oral Radiol Endod 2011; 111:278–285

25. **Marchetti C, Bianchi A, Bassi M**, Mathematical modelling and numerical simulation in maxillo-facial virtual surgery (VISU). *J Craniofac Surg* 17:661, 2006
26. **Margherita Sano, Scott Galkin, Monica Teredesai, Olivier F. Nicolay, and Thomas J. Cangialosi**, Comparison of measurements made on digital and plaster models, July 2003 *American J Orthodontics and Dentofacial Orthop* 2003;124:101-5
27. **Mavili ME, Canter HI, SaglamAydinatay B, Kamaci S, Kocadereli I**. Use of three-dimensional medical modelling methods for precise planning of orthognathic surgery. *J Craniofac Surg* 2007: 18: 740–747
28. **Metzger MC, Hohlweg-Majert B, Schwarz U, Teschner M, Hammer B, Schmelzeisen R**. Manufacturing splints for orthognathic surgery using a three-dimensional printer. *Oral Surg Oral Med Oral Pathol Oral Radiol Endod* 2008;105(2):e1-7
29. **Noguchi N, Tsuji M, Shigematsu M, Goto M**. An orthognathic simulation system integrating teeth, jaw and face data using 3D cephalometry. *Int J Oral Maxillofac Surg* 2007: 36: 640–645
30. **Olszewski R**. Surgical engineering in cranio-maxillofacial surgery: a literature review. *J Healthc Eng* 3(1):53–86
31. **Obwegeger (Hugo L. Obwegeser)**. Orthognathic Surgery and a tale of how three procedures came to be: A letter to the next generation of surgeons, *Clinics of Plastic Surgery* 34 (2007) 331-355

32. **Peluso MJ, Josell SD, Levine SW, Lorei BJ.** Digital models: an introduction. *Semin Orthod* 2004; 10: 226–238
33. **Plooij JM, Swennen GR, Rangel FA, Maal TJ, Schutyser FA, Bronkhorst EM, Kuijpers-Jagtman AM, Berge SJ.** Evaluation of reproducibility and reliability of 3D soft tissue analysis using 3D stereophotogrammetry. *Int J Oral Maxillofac Surg* 2009; 38: 267– 273.
34. **Polido WD, Ellis E III, Sinn DP.** An assessment of the predictability of maxillary repositioning. *Int J Oral Maxillofac Surg.* 1991; 20:349– 352.
35. **Polley JW, Figueroa AA:** Orthognathic positioning system: Intraoperative system to transfer virtual surgical plan to operating field during orthognathic surgery. *J Oral Maxillofac Surg* 71: 911, 2013
36. **Popat H, Richmond S, Drage NA.** New developments in: three-dimensional planning for orthognathic surgery. *J Orthod* 2010; 37: 62– 71.
37. **Quimby ML, Vig KW, Rashid RG, Firestone AR.** The accuracy and reliability of measurements made on computer-based digital models. *Angle Orthod* 2004; 74:298-303
38. **R. DeLong1, M. Heinzen1, J.S. Hodges, C.-C. Ko1, and W.H. Douglas.** Accuracy of a System for Creating 3D Computer Models of Dental Arches, 2003, *J Dent Res* 82(6):438-442, 2003

39. **Rangel FA, Maal TJ, Berge SJ, Kuijpers-Jagtman AM.** 2012. Integration of digital dental casts in cone-beam computed tomography scans. *ISRN Dent* 2012:949086.
40. **Schutyser F, Swennen G, Suetens P:** Robust visualization of the dental occlusion by a double scan procedure: Lecture notes in computer science. *Med Imag Computer Assist Interven* 3749:368-374, 2005
41. **Sean.P. Edawards,** Computer assisted Craniomaxillofacial Surgery, *Oral Maxillofacial Surg Clin N Am*, February 2010 22(1):117-134
42. **Shashank Uniyal, Somil Chhag, S Anilkumar, N Jayakumar, Marut Patel, A** Systematic approach for Splint Fabrication in Orthognathic Surgery: Case Series *IJSS Case Reports & Reviews* July 2015 Vol 2 (2): 5-9
43. **Shqaidef A, Ayoub AF, Khambay BS:** How accurate are rapid prototyped (RP) final orthognathic surgical wafers? A pilot study. *Brtish J Oral Maxillofac Surg* 52: 609-614, 2014.
44. **Swennen GR, Barth EL, Eulzer C, Schutyser F.** The use of a new 3D splint and double CT scan procedure to obtain an accurate anatomic virtual augmented model of the skull. *Int J Oral Maxillofac Surg* 2007: 36: 146– 152
45. **Swennen GR, Mollemans W, De Clercq C, Abeloos J, Lamoral P, Lippens F, Neyt N, Casselman J, Schutyser F.** A cone-beam computed tomography triple scan procedure to obtain a three-

- dimensional augmented virtual skull model appropriate for orthognathic surgery planning. *J Craniofac Surg* 2009; 20: 297–307.
46. **Swennen GR, Mollemans W, Schutyser F.** Three-dimensional treatment planning of orthognathic surgery in the era of virtual imaging. *J Oral Maxillofac Surg* 2009; 67: 2080–2092.
47. **Swennen GR, Mommaerts MY, Abeloos J, De Clercq C, Lamoral P, Neyt N, Casselman J, Schutyser F.** The use of a wax bite wafer and a double computed tomography scan procedure to obtain a three-dimensional augmented virtual skull model. *J Craniofac Surg* 2007; 18: 533–539
48. **Swennen GRJ, Schutyser F.** Three-dimensional cephalometry: spiral multislice vs cone-beam computed tomography. *Am J Orthod Dentofacial Orthop* 2006; 130: 410–416.
49. **Thomas J.J. Maal, Bram van Loon, Joanneke M. Plooij, Frits Rangel, Anke M. Ettema, Wilfred A. Borstlap, and Stefaan J. Bergé,** Registration of 3-Dimensional Facial Photographs for Clinical Use. *J Oral Maxillofac Surg* 2010.
50. **Tsiklakis K, Donta C, Gavala S, Karayianni K, Kamenopoulou V, Hourdakis CJ.** Dose reduction in maxillofacial imaging using low dose cone beam CT. *Eur J Radiol* 2005; 56:413-7
51. **Tsuji M, Noguchi N, Shigematsu M, Yamashita Y, Ihara K, Shikimori M, Goto M.** A new navigation system based on

cephalograms and dental casts for oral and maxillofacial surgery. *Int J Oral Maxillofac Surg* 2006; 35: 828– 836

52. **U. Meyer, T. Stamm, N. Meier, U. Joos** First experience with a public domain computer-aided surgical system *British Journal of Oral and Maxillofacial Surgery* 2002, 40, 96–104.
53. **Uechi J, Okayama M, Shibata T, Muguruma T, Hayashi K, Endo K, Mizoguchi I.** A novel method for the 3- dimensional simulation of orthognathic surgery by using a multimodal imagefusion technique. *Am J Orthod Dentofac Orthop* 2006; 130: 786–798.
54. **Vannier MW.** Craniofacial computed tomography scanning: technology, applications and future trends. *Orthod Craniofac Res* 2003; 6 (1):23–30 discussion 179–182
55. **W.Wayne Babcock M.D.** The surgical treatment of certain deformities of jaw associated with malocclusion of the teeth. *JAMA* September 11 1909; LIII (11):833-839.
56. **William E. Harrell, David C. Hatcher, and Raymond L. Bolt.** In search of anatomic truth: 3-dimensional digital modelling and the future of orthodontics. 2001, *American Journal of Orthodontics and Dentofacial Orthopedics* 122(3): 325-330
57. **X. Lin, T. Chen, J. Liu, T. Jiang, Shen c,** Point-based superimposition of a digital dental model on to a three-dimensional computed tomographic skull: an accuracy study in vitro *British Journal of Oral and Maxillofacial Surgery* 53 (2015) 28–33

58. **Zinser MJ, Mischkowski RA, Dreiseidler T:** Computer assisted orthognathic surgery: Waferless maxillary positioning, versatility and accuracy of an image guided visualization display. *Br J Oral Maxillofac Surg*,52(2) 2013 223-228.

ANNEXURE -I



RAGAS DENTAL COLLEGE & HOSPITAL

(Unit of Ragas Educational Society)

Recognized by the Dental Council of India, New Delhi

Affiliated to The Tamilnadu Dr. M.G.R. Medical University, Chennai

2/102, East Coast Road, Uthandi, Chennai - 600 119. INDIA

Tele : (044) 24530002, 24530003 - 06. Principal (Dir) 24530001 Fax : (044) 24530009


TO WHOMSOEVER IT MAY CONCERN

Date: 19.01.2018

Place: Chennai

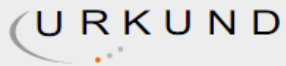
From,
The Institutional Review Board,
Ragas Dental College and Hospital,
Uthandi,
Chennai – 600 119.

The dissertation topic titled “**DIGITAL DENTAL SPLINTS IN ORTHOGNATHIC SURGERY AND EVALUATION OF THEIR ACCURACY OF FIT IN AN ANATOMICALLY ARTICULATED MODEL**” submitted by **Dr. NAMBINAYAKI.E.M.**, has been approved by the Institutional Review Board of Ragas Dental College and Hospital.


Dr. N.S. Azhagarasan M.D.S,
Member secretary,
Institution Ethics Board,
Ragas Dental College & Hospital
Uthandi,
Chennai – 600 119.



ANNEXURE – II



Urkund Analysis Result

Analysed Document: Nambinayaki Thesis.docx (D34900668)
Submitted: 1/22/2018 6:44:00 AM
Submitted By: vidhyadr19@gmail.com
Significance: 6 %

Sources included in the report:

Thesis final.docx (D30174265)
racha.doc (D21903679)
FULL THESIS NEW1.docx (D32422012)
<https://www.sciencedirect.com/science/article/pii/S1079210407006208>
<https://link.springer.com/article/10.1186/s13005-015-0082-9>
http://www.scielo.br/scielo.php?script=sci_arttext&pid=S2176-94512016000100089
<https://link.springer.com/article/10.1007/s11548-017-1585-6>
<https://link.springer.com/article/10.1007/s00266-017-0914-z>

Instances where selected sources appear:

42