

DISSERTATION

Submitted in partial fulfillment of requirements of

A CLINICAL STUDY ON ROLE OF ENDONASAL DACRYOCYSTORHINOSTOMY IN THE TREATMENT OF ACUTE DACRYOCYSTITIS AND ITS OUTCOME

M.S. OPHTHALMOLOGY

BRANCH - III

REGIONAL INSTITUTE OF OPHTHALMOLOGY

MADRAS MEDICAL COLLEGE

CHENNAI- 600 003



THE TAMILNADU

DR. M.G.R. MEDICAL UNIVERSITY

CHENNAI

APRIL 2015

CERTIFICATE

This is to certify that this dissertation entitled “**A CLINICAL STUDY ON ROLE OF ENDONASAL DACRYOCYSTORHINOSTOMY IN THE TREATMENT OF ACUTE DACRYOCYSTITIS AND ITS OUTCOME**” is a bonafide record of the research work done by **Dr. M.UMA MAHESWARI**, post graduate in Regional Institute of Ophthalmology and Government Ophthalmic Hospital, Madras Medical College and Government General Hospital, Chennai-03, in partial fulfillment of the regulations laid down by The Tamil Nadu Dr. M.G.R. Medical University for the award of M.S. Ophthalmology Branch III, under my guidance and supervision during the academic years 2012-2015.

Dr. M.SUBHASHINI, MS., DO.
Chief – Orbit & Oculo Plasty
Services RIO-GOH
Egmore, Chennai – 08

**Dr.K.NAMITHA BHUVANESWARI,
MS., DO.**
Director and Superintendent
RIO – GOH
Egmore, Chennai – 08

Dr. R.VIMALA, M.D.
Dean,
Madras Medical College.
and Government General Hospital
Chennai –03

ACKNOWLEDGEMENT

I express my sincere thanks and gratitude to **Prof. Dr. R. Vimala, M.D.** Dean, Madras Medical College and Government General Hospital for permitting me to conduct this study.

I express my sincere gratitude to **Prof. Dr. K. Namitha Bhuvaneswari, M.S., D.O.**, Director and Superintendent, Regional Institute of Ophthalmology and Government Ophthalmic Hospital, Madras Medical College, Chennai for her valuable advice in preparing this dissertation.

I am extremely grateful to **Prof. Dr. M.Subhashini, M.S., D.O.**, my Unit Chief and my guide for her valuable guidance and constant support at every stage throughout the period of this study.

I am very grateful to my Assistant Professors **Dr.P.Ashok Kumar, M.S.**, and **Dr. K.Vasumathi, M.S.**, for their valuable guidance and support not only during the study but also throughout my course in all aspects.

I wish to express my sincere thanks to all the professors, assistant professors and all my colleagues who had helped me in bringing out this study.

Finally, I am indebted to all the patients for their sincere co-operation for the completion of this study.

My heartfelt gratitude goes to my alma mater, Regional Institute of Ophthalmology, Egmore, Chennai-8 from where I learnt the art and science of ophthalmology.

Last, but not the least, to my husband **Dr.Damodar**, and to my daughter **Nila** for their utmost co-operation all through my study.

Turnitin Document Viewer - Google Chrome

https://www.turnitin.com/dv?o=456212167&u=1031766887&s=&student_user=1&lang=en_us

The Tamil Nadu Dr.M.G.R.Medical... TNMGRMU EXAMINATIONS - DUE 15-A

Originality GradMark PeerMark

A CLINICAL STUDY ON ROLE OF ENDONASAL DACRYOCYSTORHINOSTOMY IN

BY 221213012 M. S OPTHALMOLOGY DR.M UMA MAHESHWARI

turnitin 14% --
SIMILAR OUT OF 0


Dissertation

Submitted in partial fulfillment of requirements of

A CLINICAL STUDY ON ROLE OF ENDONASAL DACRYOCYSTORHINOSTOMY IN THE TREATMENT OF ACUTE DACRYOCYSTITIS AND ITS OUTCOME

M.S. OPTHALMOLOGY
BRANCH - III

REGIONAL INSTITUTE OF OPTHALMOLOGY
MADRAS MEDICAL COLLEGE
CHENNAI- 600 005



THE TAMILNADU
DR. M.G.R. MEDICAL UNIVERSITY
CHENNAI
APRIL 2015

No Service Currently Active

PAGE: 1 OF 84

03:48 PM
26-09-2014




Digital Receipt

This receipt acknowledges that Turnitin received your paper. Below you will find the receipt information regarding your submission.

The first page of your submissions is displayed below.

Submission author: 221213012 . M. S Ophthalmology Dr..
Assignment title: TNMGRMU EXAMINATIONS
Submission title: A CLINICAL STUDY ON ROLE OF E..
File name: my_thesis.rtf
File size: 15.38M
Page count: 84
Word count: 7,177
Character count: 39,250
Submission date: 26-Sep-2014 03:38PM
Submission ID: 456212167



DECLARATION BY THE CANDIDATE

I hereby declare that this dissertation entitled " **A CLINICAL STUDY ON ROLE OF ENDONASAL DACRYOCYSTORHINOSTOMY IN THE TREATMENT OF ACUTE DACRYOCYSTITIS AND ITS OUTCOME** " is a bonafide and genuine research work carried out by me under the guidance of **Prof.Dr.M.SUBHASHINI MS., DO.**

PLACE:

DATE:

Dr.M. UMAMAHESWARI

CONTENTS

SL. NO.	TITLE	PAGE NO.
PART 1		
1	INTRODUCTION	1
2	ANATOMY OF THE LACRIMAL SYSTEM	4
3	PHYSIOLOGY OF THE LACRIMAL SYSTEM	12
4	OBSTRUCTION OF THE LACRIMAL SAC AND DUCT	15
5	PATHOLOGY OF LACRIMAL PASSAGE OBSTRUCTION	17
6	BACTERIOLOGY OF DACRYOCYSTITIS	19
7	ACUTE DACRYOCYSTITIS	20
8	EPIPHORA	22
9	CLINICAL APPROACH TO A PATIENT WITH WATERING	24
10	CLINICAL DIAGNOSTIC TESTS – SECRETORY FUNCTION	31
11	EXCRETORY FUNCTION	33
12	IMAGING STUDIES	36
13	APPROACH TO A PATIENT WITH ACUTE DACRYOCYSTITIS	38
14	RECENT ADVANCES IN LACRIMAL SURGERY	43
15	ENDONASAL DACRYOCYSTORHINOSTOMY	44

PART 2

1.	AIM OF THE STUDY	63
2.	MATERIALS AND METHODS	64
3.	ENDONASAL DACRYOCYSTORHINOSTOMY	67
4.	OBSERVATION AND ANALYSIS	70
5.	DISCUSSION AND RESULTS	88
6.	REVIEW OF LITERATURE	91
7.	CONCLUSION	94

PART 3

PROFORMA

MASTER CHART

KEY TO MASTER CHART

BIBLIOGRAPHY

ABBREVIATIONS

1. DCR- Dacryocystorhinostomy
2. CSF- Cerebro spinal fluid
3. NLD-Naso lacrimal duct
4. DCG- Dacryocystography
5. CNLDO-Congenital nasolacrimal duct obstruction
6. PANDO-Primary acquired naso lacrimal duct obstruction
7. SANDO-Secondary acquired naso lacrimal duct obstruction
8. MPL-Medial palpabrel ligament
9. POD- Post operative day
- 10.PNS – Para nasal sinuses

INTRODUCTION

Field of lacrimal surgery is not an exception for the well known fact that there has always been the need for change since time immemorial. Acute dacryocystitis which was once managed best conservatively has now become one of the indications for endonasal DCR.

In the era of conservative management the morbidity is high because of lacrimal abscess, fistula, etc. All these morbidities are alleviated by endonasal DCR.

It has also got advantages of excellent visualisation of nasal cavity, lack of external scar, less postoperative pain, etc. afore mentioned factors improve the success rate in surgery as well as shorten the patient stay in the hospital.

The only disadvantage as on date being the prolonged learning curve of the surgeon.

With the advent of newer endoscopic techniques and camera a great revolution has happened in the field of endonasal DCR.

In 1904 Addeo Toti's first performed traditional external dacryocystorhinostomy by using skin incision.

In 1921 Dupuy Dutemps first used mucosal flaps in external DCR.

In 1893 caldwell first described endonasal approach in lacrimal surgery.

In 1910 West attempted endonasal approach to make a communication between the lacrimal sac and the nose. In 1917 West modified Caldwell technique by using a window resection over the lacrimal sac area.

In 1912 polyak, and in 1925 Kofler and Lester Jones performed dacryostomy. In 1990, Massaro, Gonnering and Haeris introduced argon laser DCR which simplified surgical techniques.

Patients' demand for less invasive and scarring surgery has renewed interest in endonasal DCR. Results are improving with modern endoscopes microsurgical instruments and lasers with a similar success rate to conventional external DCR.

This study goes on discussing about endonasal DCR in acute dacryocystitis.




FIG. 1 DUPUY DUTEMPS

EMBRYOLOGY

During the sixth gestational week the maxillary and the naso lacrimal processes meet to form the naso optic fissure. The lacrimal drainage system arises in the naso optic fissure from a thickened cord of surface ectoderm which detaches from the surface and moves deep into the fissure. At 3- 4 months of gestation, the cord canalizes to form the entire lacrimal drainage system. The most inferior portion of the NLD is the most frequent site of incomplete canalization which leads to chronic infection and needs a bypass procedure to overcome the obstruction.

The lacrimal system that secretes and drains the tears into the nasal cavity consists of the lacrimal gland, and upper and lower lacrimal pathway.

Upper lacrimal pathway: Puncta and Canaliculi.

Lower lacrimal pathway: Lacrimal sac and Naso lacrimal duct

LACRIMAL GLAND:

The lacrimal gland lies in the lacrimal fossa situated in the supero temporal part of the orbit, formed by the orbital part of frontal bone. This gland is divided into two parts by lateral part of the levator aponeurosis

into superior orbital and inferior palpebral part .Several other tiny lacrimal glands (glands of Krause and Glands of Wolfring) are located in the superior orbital fornix also secrete additional serous tear fluid.

LACRIMAL PUNCTA:

These are two in number, rounded or oval in shape situated one each on upper and lower eyelid at the junction of ciliary and lacrimal portion of the lid margin. Each of the punctum is situated upon a slight elevation called, lacrimal papilla .The upper and lower punctum lies about 6mm and 6.5mm lateral to the medial canthus respectively. Hence when the eyes are closed, the puncta do not overlap each other. The upper punctum is directed downwards and backwards. The lower punctum is directed upwards and backwards. Normally the puncta are not visible, unless the lids are everted.

LACRIMAL CANALICULI

The superior and inferior canaliculi have two parts, vertical (2mm) and horizontal (8mm) each 0.5mm in diameter. Both canaliculi open into the common canaliculus which is 3-5mm long and then empty into the lacrimal sac. Sinus of Maier is the dilated part of common canaliculus before it enters the lacrimal sac.

Valve of Rosenmuller is a small mucosal flap lies at the junction of common canaliculus and lacrimal sac, which prevents reflex of tears into the canaliculi. The lacrimal portion of the Horner's muscle surround the canaliculi, which forms the constrictor muscle of lacrimal punctum.

LACRIMAL SAC:

The lacrimal sac lies in the lacrimal fossa located in the medial orbital wall in its anterior part. The lacrimal bone and the frontal process of the maxilla forms the lacrimal fossa. The lacrimal sac is bounded by the anterior and posterior lacrimal crests.

The lacrimal fascia encloses the lacrimal sac, which is a part of periorbita. Vertical suture line between the frontal process of the maxilla and the lacrimal bone is medial to the middle of the floor of the fossa. In dacryocystorhinostomy operation, the first bony opening is made along this suture line.

Dimensions of the sac: when distended, the sac is about 12-15mm in length. 5-6mm in breadth with a volume of 20c.mm.

Parts:

Lacrimal sac has got 3 parts

Fundus-portion of the sac above the opening of canaliculi (3-5mm).

Body- middle part of the sac (10-12mm)

Neck-lower narrow small part which is continuous with the nasolacrimal duct.

There is a vascular plexus lies between posterior surface of the sac and posterior lacrimal fascia. Injury to this plexus during sac surgery leads to troublesome bleeding. Medial palpebral ligament lies close to the sac in its anterior part, which has to be divided near its attachment for the complete mobilization of the sac. Angular vein crosses over the medial palpebral ligament around 8mm from the inner canthus.

NASOLACRIMAL DUCT:

The lacrimal sac continues as the nasolacrimal duct and opens into the inferior meatus of the nose. It is about 12-24mm in length and 3mm in diameter. Direction is downwards, backwards and laterally. The narrowest part is its upper end. NLD consists of two parts, an intraosseus

part (12.5mm) lies in the bony nasolacrimal canal formed antero laterally by the maxilla and postero medially by the lacrimal bone and inferior nasal concha.

Intra meatal portion of the NLD lies in the lateral wall of the nose within the mucous membranes. The NLD opens in the inferior meatus at a depth of 30-40mm from the anterior nares.

Hassner's valve, a mucosal flap forming the medial wall of the membranous duct, prevents reflex into the lacrimal drainage system.

THE LATERAL NASAL WALL:

The lateral nasal wall is formed by the nasal turbinates, which are bony and are lined by mucosa. It has three turbinates and meatus lies beneath each turbinate. The turbinates appear as scrolls of bone, delicately covered by ciliated columnar epithelium. Commonly a prominence is seen at the attachment of the middle, which is known as agger nasi cells, that overlie the lacrimal sac, separated by a thin layer of bone.

The inferior meatus is present between the inferior turbinate and the lateral wall. The naso lacrimal duct opens in the anterior part of inferior meatus.

The middle meatus lies between the middle turbinate and the lateral nasal wall. Anterior group drains the frontal sinus, maxillary sinus, anterior ethmoidal sinus. The middle meatus hosts the following structures from anterior to posterior.

1. Agger nasi
2. Uncinate process
3. Hiatus semilunaris
4. Bulla ethmoidalis
5. Sinus lateralis
6. Posterior fontanellae.

The nasolacrimal duct opens in the inferior meatus

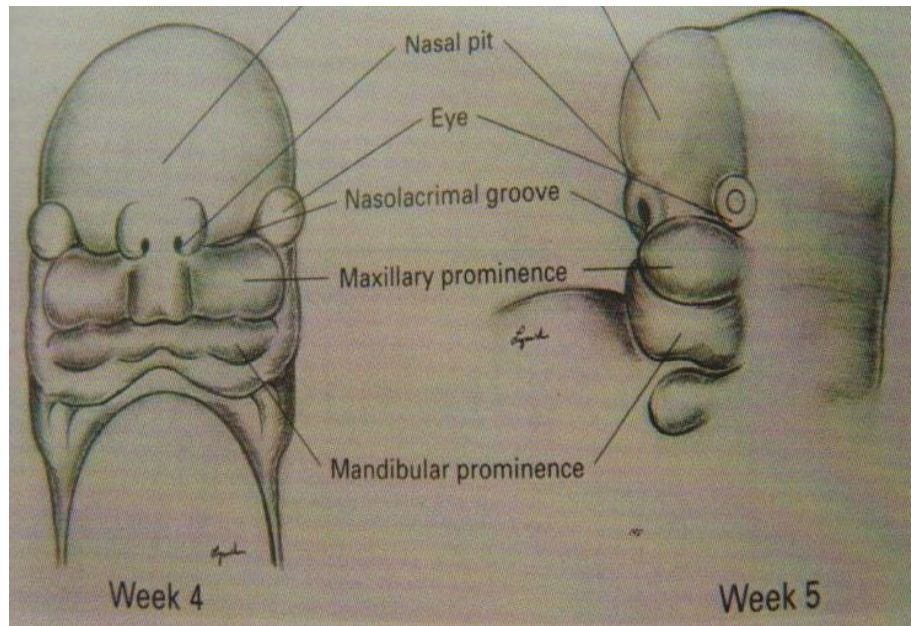


FIG. 2 : DEVELOPMENT OF THE LACRIMAL SYSTEM

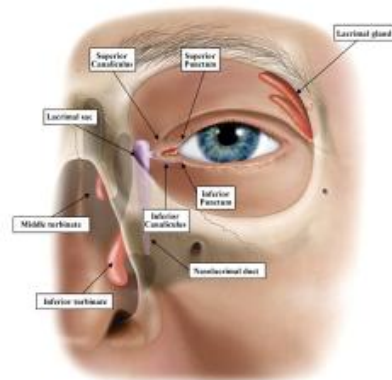


FIG. 3 : ANATOMY OF THE LACRIMAL SYSTEM

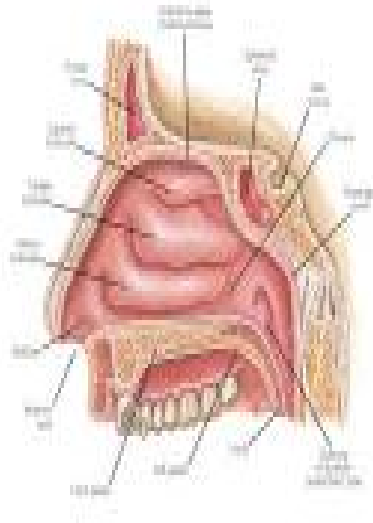


FIG.4 : ANATOMY OF THE LATERAL NASAL WALL

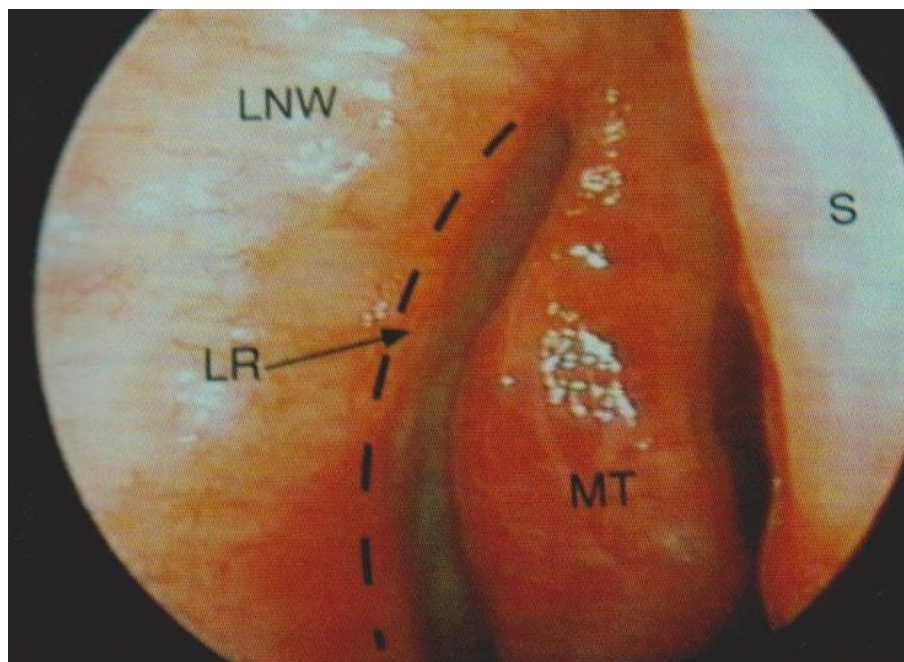


FIG.5 : ENDOSCOPIC ANATOMY OF THE NOSE-SAC AREA

INNERVATION OF THE LACRIMAL GLAND:

The sensory nerve supply for the lacrimal gland comes from the lacrimal nerve. Nervus intermedius (Nerve of Wrisberg) is the parasympathetic secretomotor nerve. The parasympathetic fibres from lateral and posterior roots of the facial nerve course to the lacrimal gland via the greater superficial petrosal nerve, with which it synapses in the sphenopalatine ganglion. The superior cervical sympathetic ganglion supplies the sympathetic fibres and follow the blood vessels course to the gland.

TEAR SECRETION:

The tear film which moistens the conjunctiva and the cornea is made up of three layers. An outer oily lipid layer, which stabilizes the tear film and prevents rapid desiccation. A watery layer, which keeps the cornea clean and smooth for maintenance of optical transparency. The inner mucin layer which also stabilizes the tear film.

The outer oily layer (0.5 mic m thickness) is secreted by the meibomian glands, sebaceous glands and the sweat glands of the margin of the eyelid. The middle aqueous layer (8-10 mic m thickness) is secreted by the lacrimal gland and the accessory lacrimal glands. The

inner mucin layer (0.8 mic m thickness) is secreted by the goblet cells of the conjunctiva and the lacrimal gland.

Lysozyme, beta lysine, lactoferrin and immunoglobulin A are tear specific proteins are responsible for the tear fluid antimicrobial properties. The normal pH of human tear ranges from 6.5 to 7.6.

TEAR ELIMINATION:

Most of the secreted tear is drained by the lacrimal pump mechanism (75%) and the remaining is done by evaporation (25%) according to Rosengren-Doane lacrimal pump theory tear film is spread over the cornea by the act of blinking and tears are moved towards the puncta.

The horizontal part of the canaliculi is encircled by the pretarsal orbicularis muscle. When the muscle contracts, ampulla is closed and the tears are drained through the canaliculi into the sac. The posterior insertion of the orbicularis in a fascia around the NLD pulls the lateral wall of the sac laterally and creates the negative pressure drawing the tears from the common canaliculus. When the eye opens the sac collapses and the tears are driven into the NLD by gravity.

The lacrimal drainage system comprises a canalicular pumping mechanism and lacrimal sac syphoning mechanism

Epiphora occurs in the facial nerve paralysis due to weakening of the orbicularis oculi muscle. The muscle fibres gets attached to the upper part of the sac.

When the muscle contracts upper part of the sac distends and lower part is constricted. The tears are aspirated into the sac and pushed down into the NLD. In facial paralysis weakness of orbicularis oculi causes epiphora.

OBSTRUCTIONS OF THE LACRIMAL SAC AND DUCT

TYPES OF OBSTRUCTIONS

1. Congenital NLD obstruction (CNLDO)
2. Primary NLD obstruction (PANDO)
3. Secondary NLD obstruction (SANDO)

Congenital NLD obstruction (CNLDO)

Commonest cause of epiphora in children due to an imperforate membrane of Hasner's valve or stenosis of opening from narrowed NLD or hypertrophied inferior nasal turbinate

ACQUIRED OBSTRUCTIONS

Primary NLD obstruction (PANDO)

Described by Lindberg in 1986. Most common cause of epiphora in adults. Chronic mucosal thickening with progressive fibrosis leading to narrowing of the NLD along with increased venous stasis within the venous sinusoids in and around the NLD

Secondary NLD obstruction (SANDO)

Described by Bartley in 1992. Causes are

Inflammation: sarcoidosis, Wegener's granulomatosis

Infections :bacterial etiology

Traumatic: mid facial fractures, rhinoplasty

Neoplasm: lacrimal sac tumours

PATHOLOGY OF LACRIMAL PASSAGE OBSTRUCTION

DACRYOCYSTITIS:

Inflammation of the lacrimal sac, blockage of the NLD is the leading cause for dacryocystitis. It can be acute, chronic, or congenital.

ACUTE DACRYOCYSTITIS:

Sudden onset of infection of the lacrimal sac.

CHRONIC DACRYOCYSTITIS:

Long standing or recurrent infections of the sac.

CONGENITAL DACRYOCYSTITIS:

Seen in infants due to poorly developed naso lacrimal duct.

AGE:

This disease is more common in adults over the middle age. Less common in children and adolescents. People in their fifth decade and in old age are frequently affected.

SEX RATIO:

Congenital dacryocystitis affects both sexes equally. In adults, females are more commonly affected than males. The female: male ratio is around 80:20(Duke Elder 1974). This is attributed to the narrow lumen of bony canal in females.

RACIAL VARIATION:

Negroes are less commonly affected than whites due to their short and wide NLD and large ostium in this race.

ETIOLOGY:

Blockage of NLD is the basic cause for dacryocystitis. It may occur due to spread of infection from the mucosal lining of the nose and the sinuses and from conjunctival diseases. Inflammation of the lacrimal sac is possible if there is stasis of the contents of sac. The NLD has numerous folds and valves in the mucosal lining which swells up, leads to stasis of fluid and hamper its smooth drainage.

BACTERIOLOGY OF DACRYOCYSTITIS:

The most common aerobic organism associated with dacryocystitis is Staph. Epidermidis. Staph.aureus, streptococcus,pneumococcus and pseudomonas are also isolated.

In adults, the most common anaerobic organism isolated include peptostreptococcus, propionibacterium etc.

Gram negative bacteria have been seen more commonly in patients with profuse purulent discharge is E.Coli.

Fungi is involved very rarely. Most common fungal isolates are aspergillus, mucor and penicillium.

ACUTE DACRYOCYSTITIS

SYMPTOMS:

Patients presents with redness, swelling or watering from the eye.

Oedema of the lids and cellulitis may be present which may involve the cheek with pain radiating to the surrounding areas such as maxilla, nose, orbit.

Epiphora is present and a mass noted inferior to the medial canthal tendon. This leads to the formation of abscess which may burst leading to the fistula formation. The fistula is located just below the MPL.

In severe cases there is erythema over the skin, it looks friable. The condition may subside with conservative treatment.

However it can get worse leading to the extravasation of pus into the skin and surrounding area. This leads to the abscess formation. Lacrimal abscess thus formed may burst leading to the fistula formation. The fistula is located just below the medial palpabrel ligament.

DIAGNOSIS:

Diagnosis of acute dacryocystitis is by clinical symptoms and signs.

Fever may or may not be present.

Probing and syringing is deferred in acute dacryocystitis.

CT and MRI are required only in complicated cases.

COMPLICATIONS OF ACUTE DACRYOCYSTITIS:

- Conjunctiva- chemosis, redness, and conjunctivitis
- Cornea- superficial ulcers
- Pre septal cellulitis is more common. Due to the spread of infection from the ruptured sac and bacterial over growth into the surrounding tissues
- Orbital cellulitis is rare

EPIPHORA

Watering from the eye is a common symptom in cases of lacrimal sac disorders. Epiphora may be due to

A. PUNCTAL OBSTRUCTION/ CANALICULAR

OBSTRUCTION:

B. LACRIMAL SAC OBSTRUCTION

C. NASO LACRIMAL DUCT OBSTRUCTION:

A. PUNCTAL OBSTRUCTION/ CANALICULAR

OBSTRUCTION:

- Congenital- atresia , absence
- Traumatic-chemical, mechanical, irradiation
- Infective- viral
- Cicatrising- Steven-Johnson syndrome

B. LACRIMAL SAC OBSTRUCTION

- Traumatic- nasal and orbital surgeries, Le Fort 2 fractures
- Infections - acute, chronic, recurrent dacryocystitis
- Tumours - squamous cell carcinoma, inverted papilloma

C. NASO LACRIMAL DUCT OBSTRUCTION:

- Congenital- Atresia, absence, lack of canalization
- Traumatic- surgeries of nose, facial fractures, probing
- Nasal pathology- antral carcinomas, polyps, inferior turbinate hypertrophy
- Idiopathic involutional stenosis of old age- commonest cause
- Pseudo NLD obstruction- secondary to nasal allergy, allergic rhinitis.

CLINICAL APPROACH TO A PATIENT WITH WATERING

1. HISTORY:

Time and age onset

- First few weeks of life- congenital NLD obstruction
- Young age group- trauma, viral infection
- Middle age- dacryoliths (intermittent) , infections
- Old age- infections, idiopathic involutional NLD obstruction.

2. DURATION:

- Acute
- Chronic
- Subacute

3. FREQUENCY:

- Constant
- Intermittent (dacryoliths)

4. PRESENCE OF PRECIPITATING OR AGGRAVATING FACTORS:

➤ Cold weather

➤ Sunlight

➤ Wind

5. HEAD ACHE:

➤ Glaucoma

➤ Iritis

➤ Refractive errors

6. LATERALITY:

➤ Unilateral

➤ Bilateral

7. PAIN:

➤ Inflammation

8. SWELLING IN THE SAC REGION:

➤ Acute /chronic dacryocystitis

➤ Mucoceles

➤ Tumours

9. REGURGITATION ON PRESSURE OVER SAC REGION:

- Lower lacrimal system obstruction

10. DIFFICULTY IN READING:

- Due to the increase in the tear lake

PAST HISTORY:

- Similar complaints in the past denotes recurrent dacryocystitis, lacrimal abscess, fistula
- H/O associated injuries / trauma
- Mid facial fractures, surgeries of eye or nose
- Previous H/O eye disease or prolonged use of topical medications
- Associated systemic medical illness
- Bell's palsy, cerebro vascular accidents
- H/O treatment with chemotherapy or radiotherapy.

PHYSICAL EXAMINATION:

INSPECTION:

Detailed ocular examination

LIDS:

Coloboma, blepharitis, excoriation of skin of lids- dermatitis, ectropion, entropion, trichiasis, punctual eversion, widening of palpebral fissure, senile skin laxity

Skin over the sac region:

- Swelling
- Fistula
- Redness
- Scars

Increased tear meniscus

Regurgitation on pressure over sac region

ASSESSMENT OF LID LAXITY:

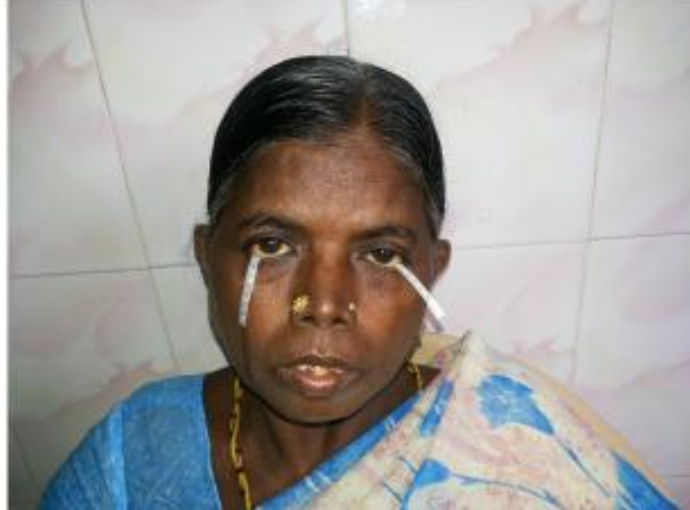

FIG.6 : SCHIRMER S TEST

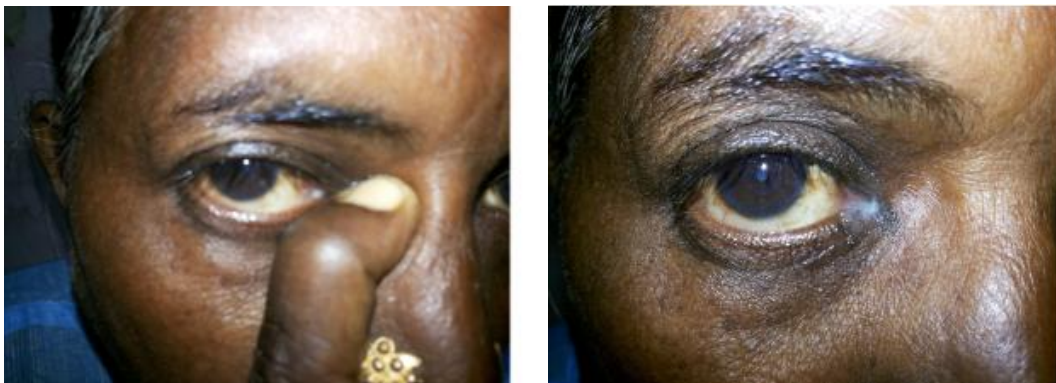

FIG.7 : ROPLAS POSITIVE

SNAP BACK TEST:

The lower lid is pulled away from the globe. If it is retracted > 6mm or does not snap back to its original position quickly indicates lid laxity.

MEDIAL CANTHON TENDON LAXITY:

The lower lid is pulled laterally and the displacement of the lower punctum from its position is measured along the horizontal axis (normal upto 2-3 mm).

SLIT LAMP EXAMINATION:

- Lid margin
- Conjunctiva
- Cornea
- Anterior chamber are evaluated thoroughly

DIAGNOSTIC NASAL ENDOSCOPY:

This is important to assess the mucosal status of nose and to assess the presence of any pathology (deviated nasal septum, polyp, atrophic rhinitis) which may be responsible for intranasal obstruction of NLD.

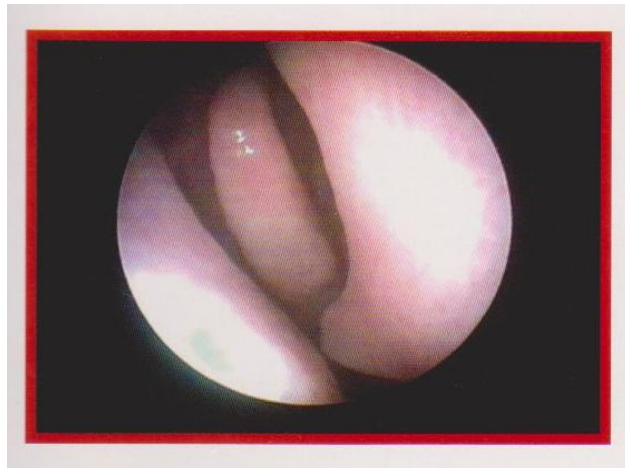


FIG. 8 : SEPTAL DEVIATION

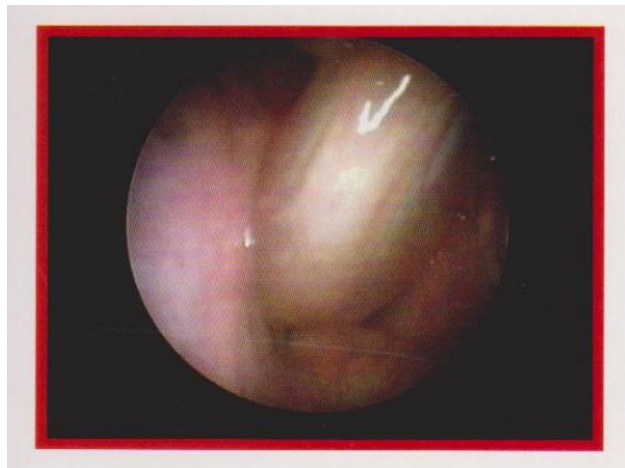

FIG. 9 : MASS FLOOR OF THE NOSE

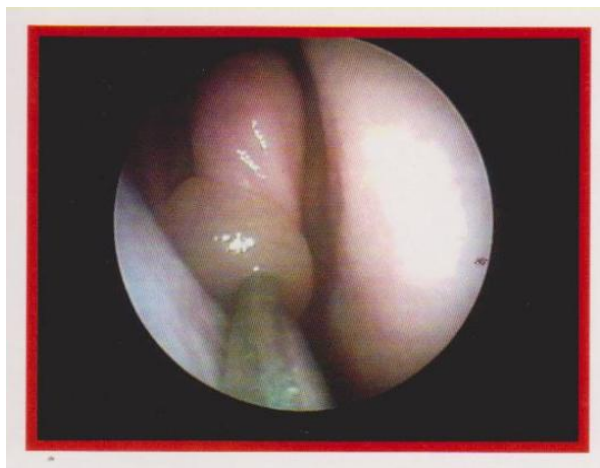

FIG.10 : ETHMOIDAL POLYP

CLINICAL DIAGNOSTIC TESTS

SECRETORY FUNCTION:

1. SCHIRMER'S TEST:

The amount of wetting by using a whatmann filter paper strip over five minutes- helps us to assess the tear production

In normal non anaesthetised eyes

- <40 years - 15mm
- > 40 years - 10mm

In normal anaesthetised eyes

- < 40 years - 10mm
- > 40 years -5mm

TEAR FILM BREAK UP TIME (BUT)

This is defined as the interval between a complete blink and the appearance of the first randomly distributed dry spot is detected under slit-lamp examination under cobalt blue illumination, after instillation of 2% fluorescein in conjunctival sac. Normally BUT is 15-35 seconds. If it is less than 10 seconds, indicates mucin deficiency, which spreads the tears

ROSE BENGAL TEST:

1% rose bengal stain is instilled into the conjunctival sac, which stains the abnormal epithelial debris, mucin in the conjunctiva in the interpalapabrel area, denotes indirectly the tear secretion

EXCRETORY FUNCTION

1. DIAGNOSTIC PROBING AND LACRIMAL SYRINGING

This was advocated by Dominique Anel in 1703. Under topical surface anaesthesia the lower lid punctum is dilated with Nettleship's dilator. The lacrimal irrigation cannula (23-g) is attached with a syringe is directed first 2mm vertically , rotated to 90 degree and redirected horizontally 8mm and advanced further into the canaliculus to the medical wall of the lacrimal sac fossa.

If 'HARD STOP' is noted, it implies, the canaliculus is patent the probable obstruction lies in the lacrimal sac or NLD.

If a 'SOFT STOP' is noted denotes canalicular obstruction. Clear water or saline is irrigated gently through the lacrimal cannula. If the fluid passes into the nose or throat without reflux from the opposite canaliculus the lacrimal system is patent. If fluid passes into the nose with some resistance, with reflux occurred through opposite cannaliculus. Then the system is anatomically patent, but partial occlusion may be present. If no fluid passes into the nose with complete regurgitation through either of the punctum, indicates complete NLD obstruction in the involved eye.

FLUORESCESIN DYE DISAPPEARANCE TEST:**GRADING SCALE:**

- 0-no fluorescein noted in the conjunctival sac
- 1-fluorescein in the marginal tear strip persists
- 2-more fluorescein persists between 1-3
- 3-wide, brightly fluorescing tear strip noted

Grade 0-1 - Normal

 2-3 – Abnormal

JONES FLUORESCIN DYE TEST:

This test is done to assess whether the lacrimal drainage system is fully patent or not. If obstructed the site of block is assessed

JONES 1 TEST:

2% Fluorescein dye is instilled in the patient's conjunctival sac. A cotton tipped swab is placed in the nose below the inferior turbinate. If the dye is found on the cotton bud, the test is positive - indicates a patent system and normal physiologic function.

Negative test indicates:

The test could be

1. False negative
2. Physiological dysfunction
3. Anatomical obstruction

Hence Jones 2 test is recommended

JONES 2 TEST:

After Jones 1 test, the lacrimal drainage system is irrigated. Then a transcanalicular irrigation with saline is done and the patient is requested to expel the collected fluid from the throat. Presence of dye indicates partial block at lower sac level or NLD. Presence of saline indicates - punctal or canalicular level of obstruction.

HORNBLASS SACCHARINE TEST:

This is a simple and effective test used in children.

Saccharine drops are instilled in one eye. chloramphenicol eye drops are instilled in other eye. Few minutes later, Ability to detect the sweet taste in one eye and the bitter taste in the other eye denotes a patent lacrimal system

IMAGING STUDIES

Following options are available

- Conventional dacryocystography
- Computed tomographic dacryocystography
- Magnetic resonance imaging with dye injection or instillation
- Scintigraphy

DACRYOCYSTOGRAPHY

This test involves injection of radio opaque fluid into the lower or upper canaliculus and taking magnified images.

Bilateral simultaneous DCG gives relatively more functional information whereas Digital subtraction DCR gives a high quality image.

Modified DCG includes radiological subtraction techniques and macrography (image size is increased)

DCG - Contraindicated in acute dacryostitis, Mucoceles.

NUCLEAR LACRIMAL SCINTIGRAPHY:

This technique uses radio tracer technetium 99. A minute dose of 5-10 mega becquels eye is used. The recording of tracer activity is done at intervals by using Gamma camera.

COMPUTED TOMOGRAPHY:

High resolution CT in axial and coronal plane is used in suspected cases of tumours in the sac region, failed DCR and Mid facial trauma.

ULTRASONOGRAPHY:

Useful in cases of common canalicular obstruction, where DCR cannot be demonstrated.

ULTRASOUND BIOMICROSCOPY

Resolution of the sub surface structures upto 4mm helps us to visualise the canaliculus

APPROACH TO THE PATIENT WITH ACUTE DACRYO CYSTITIS

HISTORY

SYMPTOMS:

Epiphora, swelling in the medial canthus, discharge (purulent or mucoid) epistaxis (nasal, sinus, lacrimal sac tumours)

PAST HISTORY:

- Previous surgery (DCR/sinus surgery) medications used
- Previous H/O radio therapy
- H/O trauma to its midface.

CLINICAL EVALUATION:

MUCOID OR PURULANT EYE DISCHARGE

Overflow of tears/ Mass over the sac area

REGURGITATION TEST- ROPLAS test. Mucoid reflux with lacrimal passage indicates lacrimal system obstruction.

SLIT LAMP EXAMINATION:

- For assessment of tear meniscus height,
- Stenosis or pouting of punctum
- Canaliculitis
- Expression of concretions from the punctum

INVESTIGATION:

LABORATORY INVESTIGATIONS:

Lacrimal discharge for gram and giemsa stain / culture and sensitivity KOH- stain - for fungal infection.

Anti neutrophilic cytoplasmic antibodies - Wegener's granulomatosis

IMAGING STUDIES:

- Dacryocystography- to assess the level of anatomical block.
- Dacryoscintigraphy - to assess the functional level of block
- CT - in trauma and sinus involvement

DIAGNOSTIC NASAL ENDOSCOPY:

- To rule out nasal pathology.

OTHER TESTS:

- Schirmer s test

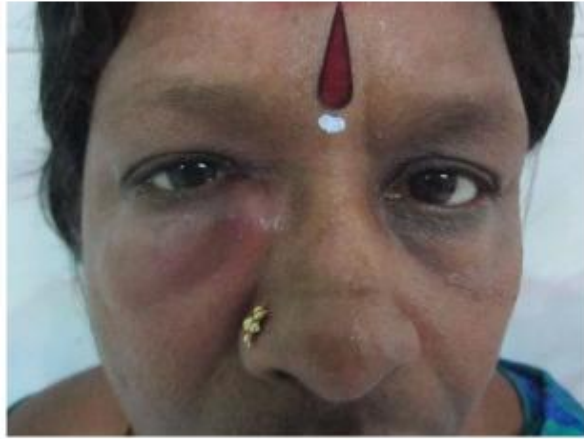TREATMENT:

Treatment of acute dacryocystitis is essentially surgical. However, prior to surgical approach, broad spectrum systemic antibiotic therapy is useful in sub-acute and acute dacryocystitis followed by DCR 2-3 days later. Hot fomentation is also useful.

The success rates of surgery is around 85-90% in endonasal DCR



FIG. 11 : ACUTE DACRYOCYSTITIS



**FIG.12 : ACUTE DACRYOCYSTITIS WITH
PRE SEPTAL CELLULITIS**

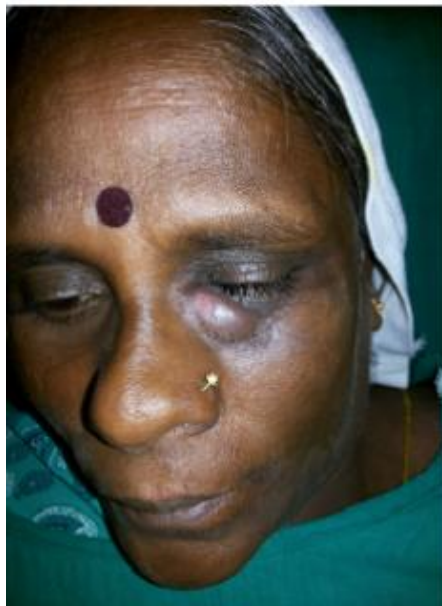

FIG. 13 : ACUTE DACRYOCYSTITIS WITH ABSCESS

RECENT ADVANCES IN LACRIMAL SURGERY

1. Balloon catheter dilatation of the lacrimal passage.

Dacryocystography is a nonsurgical treatment performed under topical anaesthesia as an outpatient procedure.

This is recommended in cases of congenital NLD obstruction and in adult with NLD obstruction.

2. Role of canalicular endoscopes are available is a noninvasive can directly localize the site and type of obstruction.

3. Stenting of NLD

It is most effective in children with NLD obstruction, who are not responding to probing and syringing.

ENDONASAL DACRYOCYSTORRHINOSTOMY

INTRODUCTION:

Pioneered by Caldwell in 1893, Rice- who modified the external DCR to endonasal DCR by using instruments endoscopically to create the ostium.

(FESS) functional endoscopic sinus surgery by Messerklinger, devised his own technique brought this technique into light.

INDICATIONS FOR FESS IN OPHTHALMOLOGY

- Acute dacryocystitis
- Chronic dacryocystitis
- Enophthalmos - for medial wall decompression
- Tumours of orbit for biopsy and excision
- Orbital floor fracture- diagnostic
- Inflammatory- extra periosteal abscess
- Optic nerve injury- for optic nerve sheath fenestration.

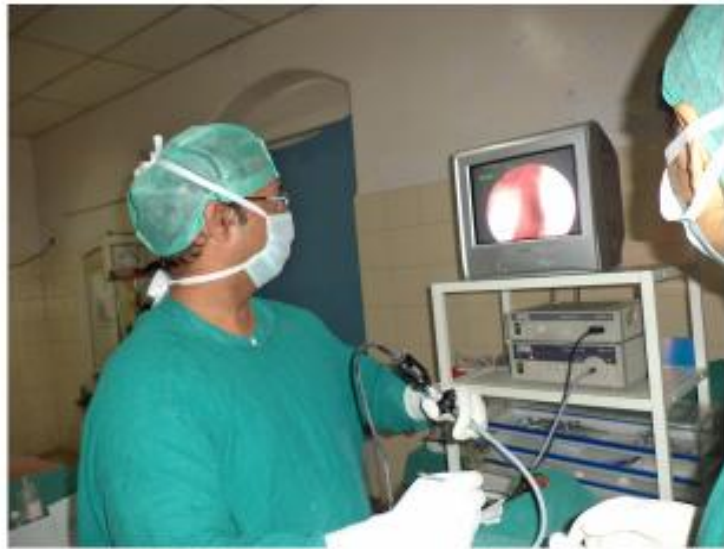

FIG.14: ENDONASAL DACRYOCYSTORHINOSTOMY

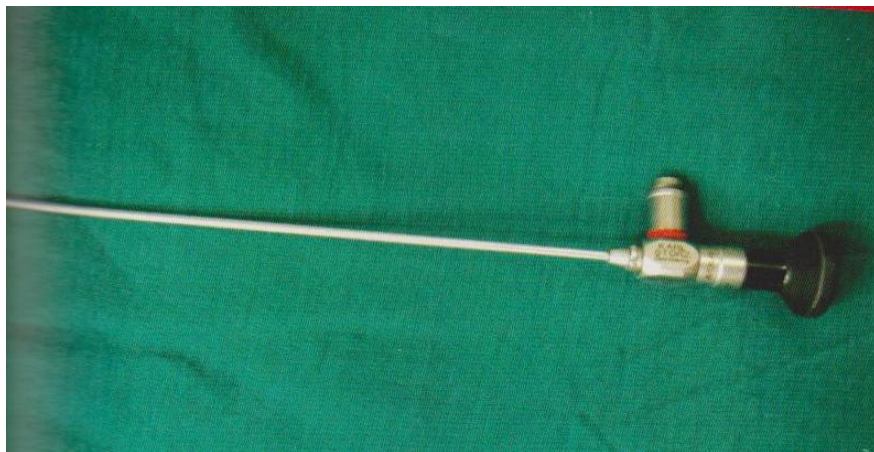


FIG. 15: 30° NASAL ENDOSCOPE



FIG. 16 : FORMALIN CHAMBER

INDICATIONS FOR ENDONASAL DCR:

Lacrimal drainage system obstruction at the level of the sac or distal sac

- Acute or chronic dacryocystitis
- Mucocele
- Failed external DCR

CONTRA INDICATIONS:

- Acute sinusitis
- Nasal polyposis
- -Obstruction of the lacrimal canaliculus

INSTRUMENTATION AND TECHNIQUES:

The instruments used are

- Telescopes (Hopkin's rigid endoscope) 0 degree and 30 degree 4 mm size
- Telescope handles
- Suction tips- straight and curved
- Freer periosteal elevator
- Cold light fountain and fibre optic cable

- Sickle knife.
- Forceps- Blakesely- straight -upturned 90 and 40 degree
- Video adapter with camera
- T.V monitor
- Anti fog solution
- Bipolar cautery
- Long curved needle-26G, 1.5 inch with 1 ml syringe
- Kerrison s bone punch forceps
- Malleable probe and suction tips of different angles
- Ball probe
- Fess scissors

SURICAL TECHNIQUE:

This procedure is done with the surgeon standing on the right side of the patient. Patient lying in a supine position. The scope is dipped into an antifog solution (savlon) So that it prevents fogging by forming a thin film of solution over the lens.

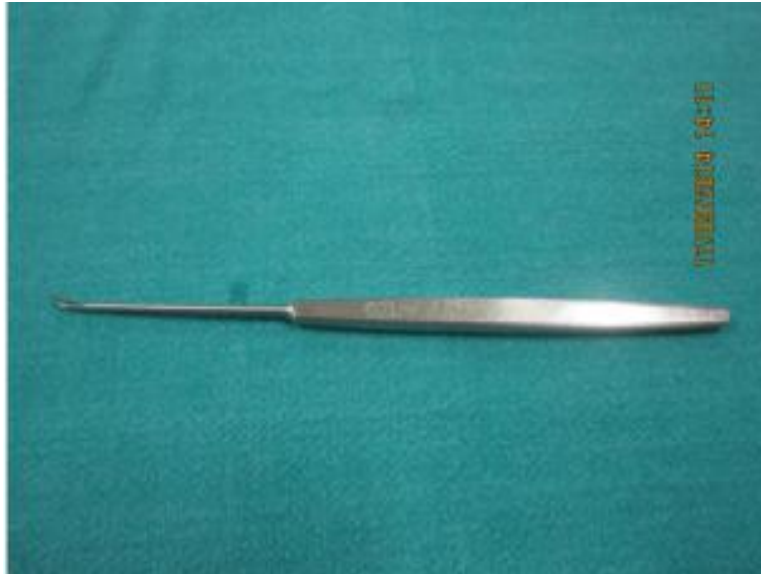

FIG. 17 SICKLE KNIFE

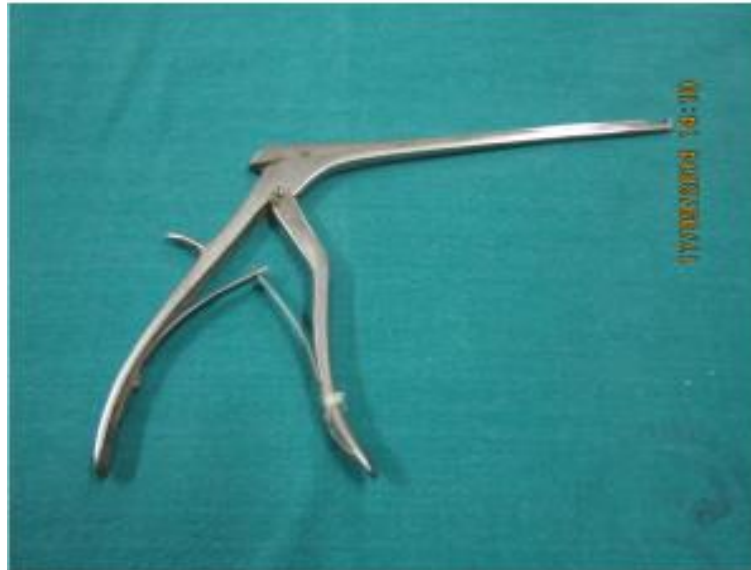

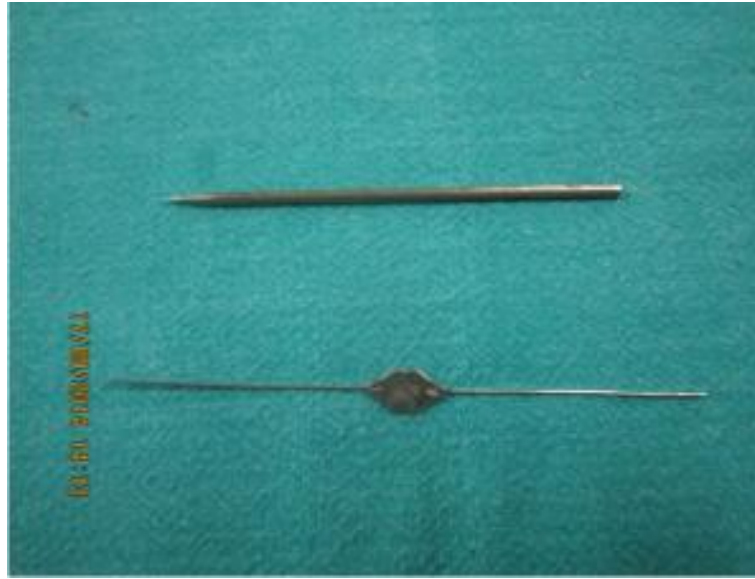
FIG. 18 KERRISON BONE PUNCH

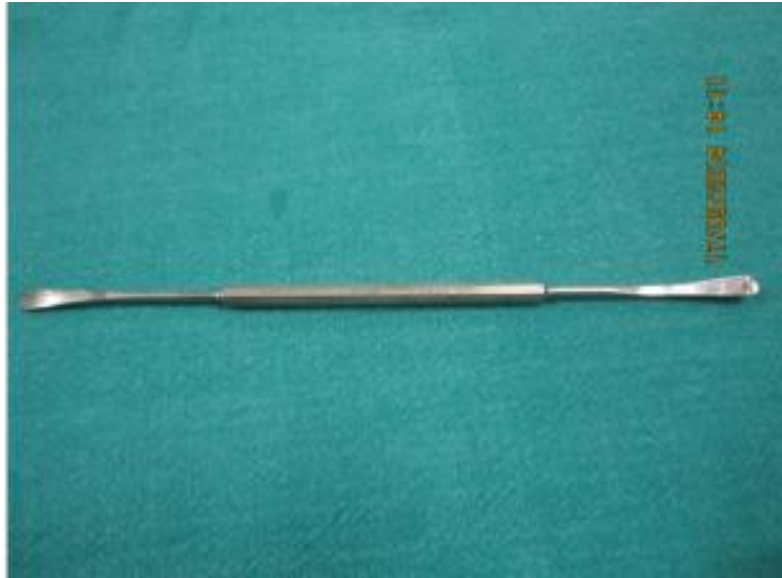

FIG. 19 : PERIOSTEAL ELEVATOR

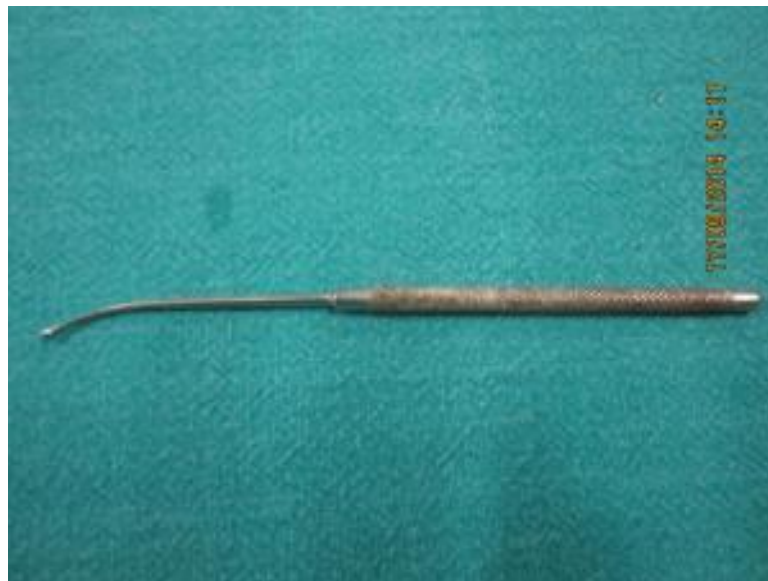

FIG. 20 : BALL PROBE



**FIG. 21 : NETTLESHIP PUNCTUM DILATOR,
BOWMAN'S PROBE**

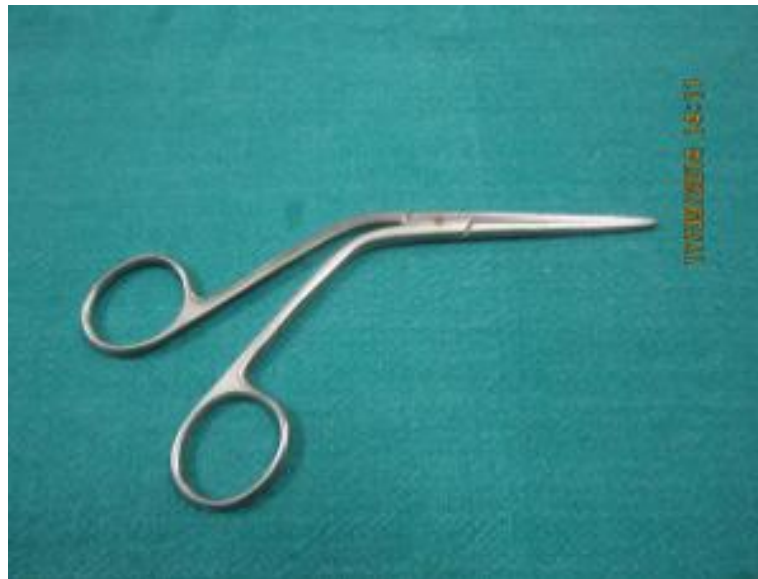

FIG. 22 : SINUS FORCEPS

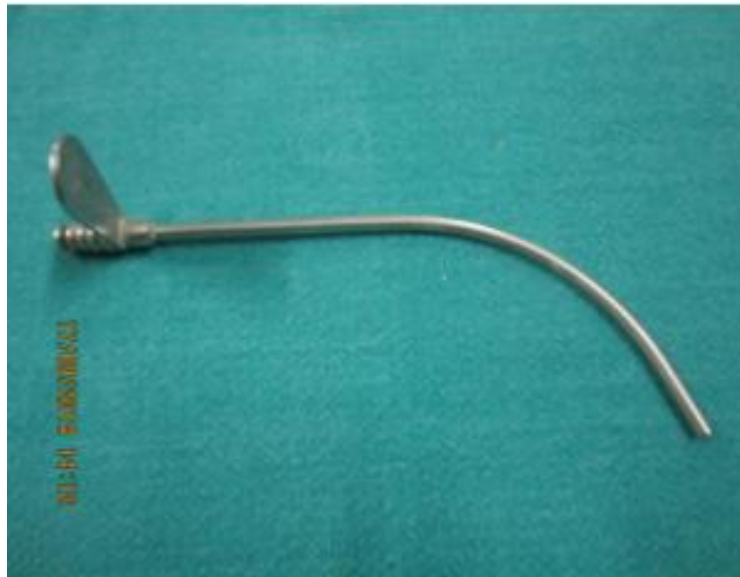

FIG. 23 : SUCTION CANNULA

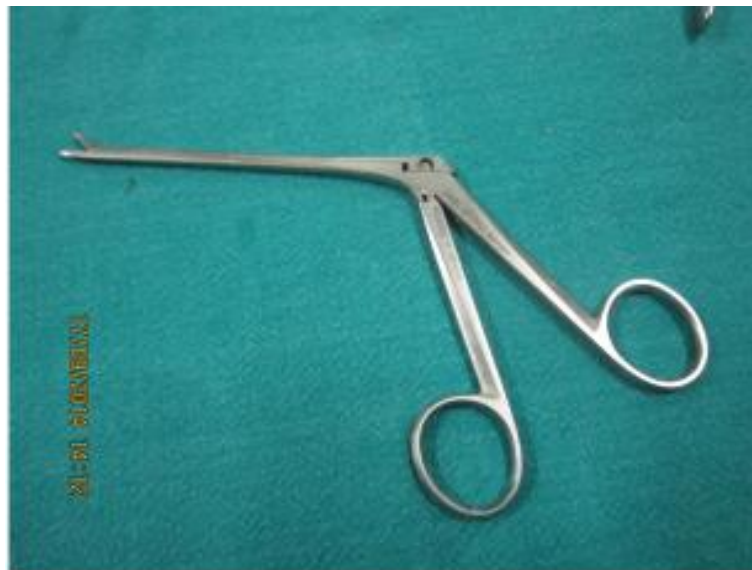

FIG. 24 : MUCOSAL FORCEPS

DIAGNOSTIC NASAL ENDOSCOPY

A pack of 4% lignocaine and oxymetazoline hydrochloride soaked cotton pads are kept in the nose for a period of 5-10 minutes before the procedure.

The endoscopy is passed through the floor of the nose, viewing the inferior turbinate nasal septum upto the middle turbinate. After reaching the choana, the orifice of eustachian tube, Fossa of Rosenmuller and the nasopharynx are visualised as a small punctate or slit like opening at the junction of anterior one-third and middle thirds of inferior turbinate.

The scope is passed along the middle meatus. The uncinate process is identified by a shallow groove lies behind the lacrimal crest. The free edge is visualised behind the bony prominence lies the Bulla ethmoidalis. Sulcus semilunaris lies between these two structures which contains the infundibulum in the anterior part and the ethmoidal and maxillary sinus openings.

ANAESTHESIA:

Pre-operative packing of 4% lignocaine 10ml with one ml of adrenalline soaked cotton pledgets in the agger nasi area, middle Meatus,

middle and inferior turbinate, inferior meatus area for 15-30 minutes. This is followed by infiltration of 2% lignocaine with 1:100000 adrenaline just anterior to the attachment of middle meatus in agger nasi area, just in front of the uncinat process.

PROCEDURE:

Nasal mucosa incised at or just posterior to the nasal ridge after marking the area with ball probe and using sickle knife and flap of mucoperiosteum is raised over the maxillary and lacrimal bone. The location of lacrimal sac is ascertained by passing a Bowman's probe through the lower punctum.

The thin bone over the lacrimal sac is removed by using Kerrisons bone punch. Once the medial wall of the sac is exposed it is incised in the vertical aspect by using sickle knife and removed completely with Blakesley wilde forceps. Stenting by using silicon tube may be done. In the medial wall of the sac is removed widely followed by meticulous nasal irrigation and cleaning is done to prevent re-stenosis of the sac.

POST OPERATIVE CARE:

Syringing with antibiotic steroid eye drops

Oxymetazoline nasal drops four times a day for two to three weeks

Endoscopic cleaning of the crusts in the nasal area after a week can be performed

ADVANTAGES:

- The primary advantage is ability to identify the abnormal intranasal anatomy and can be corrected at the same time
- No scar, no cut, less morbidity
- Less bleeding, less cumbersome
- Shortens the hospital stay
- Bilateral DCR can be done in the same sitting as an outpatient procedure under local anaesthesia. Since there is no patching of the eye is required
- Postoperative adhesions are less.
- Adjacent structures are well preserved
- Revision surgery is easy

- Lacrimal abscess in acute phase can be operated by endoscopic approach.
- Incision and drainage of the abscess is required for external DCR
- After 7-10 days period, after complete healing only, patient can be operated as the skin is friable and unhealthy and skin flaps are difficult to suture. Endoscopic DCR takes care of all the complications in one sitting
- All the disadvantages of external DCR are the advantages of endonasal DCR
 - Error in location of ostium
 - Error in bone removal
 - Common canalicular obstruction
 - Scarring at the rhinostomy site
 - intervening of ethmoidal cells
 - Enlarged middle turbinate
 - Deviated nasal septum



FIG.25 : POST ENDONASAL DCR

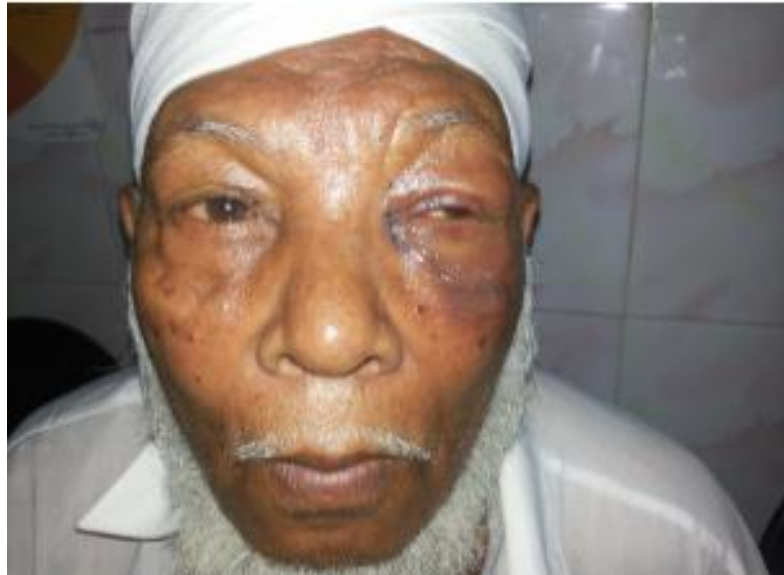

FIG. 26 : POST EXTERNAL DCR

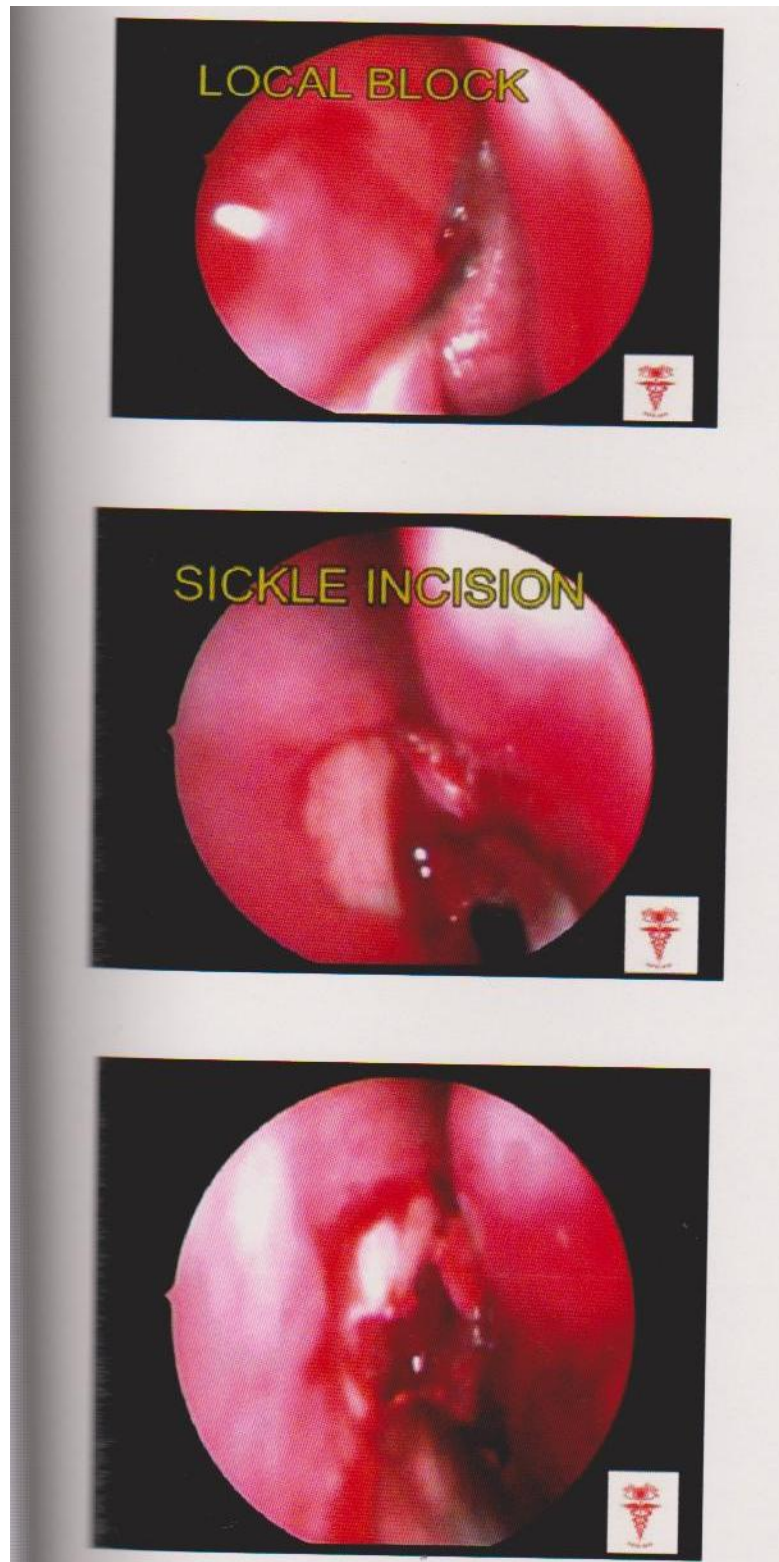


FIG. 27 : ENDONASAL DCR

DISADVANTAGES:

- Since the lacrimal sac and the nasal mucosal flaps are not sutured inside the nose due to technical difficulty
- External DCR is responsible for better results.
- Long standing lacrimal sac fistula needs fistulectomy, which can be managed along with external DCR
- Endo nasal DCR needs expert surgical skills and instrumentation is necessary

COMPLICATIONS OF ENDONASAL DCR:**BLEEDING:**

- Due to accidental damage to intra orbital vessels
- Common in Previous H/O surgery
- Uncontrolled hypertension patient
- Patients on anticoagulants
- Undetected bleeding disorders
- Infected nasal mucosa with narrow and compromised anatomy
- Difficulty in locating the sac for various reasons can cause mucosal damage and laceration leading to bleeding.

BLINDNESS:

Extremely rare. Orbital haemorrhage may occur due to injury to anterior ethmoidal artery or orbital vessels leads to proptosis and compressive optic neuropathy. Immediate treatment is by lateral Canthotomy.

INJURY TO LAMINA POPYRACEA

Lamina papyracea is the orbital plate of the ethmoid bone and form the medial wall of orbit. If damage occurs, fat prolapse into the nose is seen. Lid edema and peri orbital ecchymosis indicate entry into the orbit

FALSE PASSAGE:

Surgical failure indicates obstruction of the rhinostomy ostium by granulation tissue or due to synechiae in the early postoperative period.

CSF LEAK:

Occurs through the fractured ethmoid. The bony removal or the forceful correction of septum may fracture the perpendicular plate of ethmoid and leads to CSF leak.

SUMP SYNDROME:

Collection of pus in the remnants of the sac after surgery. It may regurgitate on pressure. The cause is the inadequate bone removal from the lower part of the sac and its junction with the NLD. This can give rise to recurrent infections of the lacrimal sac giving rise to the same symptoms as were present before surgery.

CORNEAL ABRASION

Occur due to prolonged exposure of the cornea during the surgery

SYNAECHIAE FORMATION

Synaechiae may form at different sites between the middle turbinate and the lateral wall, between the septum and the lateral wall of the nose.

FAILURE OF ENDONASAL DCR

Immediate failure occurs where syringing was not patent on the first postoperative day

Early or Immediate failure is due to the technical failure. Due to inadequate bone removal, faulty identification of lacrimal sac, Inability to open the sac, too small opening of the sac

INTERMEDIATE FAILURE:

Where the ostium closes after 4-6 weeks of surgery

LATE CASES:

Where the ostium closes after six weeks. Invariably there is a systemic cause or a nasal disease causing the recurrence of symptoms in such cases.

AIM OF THE STUDY

To determine the role of the endonasal Dacryocystorhinostomy in the treatment of acute dacryocystitis and to assess the success rate of the procedure.

MATERIALS AND METHODS

A prospective study was carried out on 30 patients at Orbit and Oculoplasty clinic, RIO-GOH, Chennai during the period of from October 2013 to August 2014.

SELECTION CRITERIA

30 patients who presented with acute dacryocystitis were included in this study. Out of 30 patients 26 were female patients and 4 were male patients.

They were in the age group of 20-58 years and there was no history of major systemic illness like diabetes or hypertension among them . All the patients underwent primary endonasal DCR.

INCLUSION CRITERIA

All the cases of acute Dacryocystitis with abscess with established nasolacrimal duct obstruction were included in the study.

EXCLUSION CRITERIA

- Cases with canalicular and punctal obstruction.
- Cases with ectropion or entropion.
- Cases with noticeable lower lid laxity.
- Cases of congenital malformations of lacrimal apparatus and craniofacial anomalies
- Cases of tumours of the lacrimal apparatus and nasal cavity.
- Cases with lacrimal fistulae and chronic dacryocystitis
- All recurrent cases due to failed external dacryocystorhinostomy.
- Cases with deviated nasal septum on the same side.

CLINICAL EVALUATION

History and detailed ocular examination was carried out in all cases

Since the **Regurgitation test** and the **Lacrimal syringing** is contra indicated in cases of acute dacryocystitis, It was not performed.

Assessment of the medial canthal area was done for swelling, inflammation and fistula

Slit lamp examination was done to assess the anterior segment

Schirmer's test was done to rule out dry eye

Diagnostic nasal endoscopy was done to rule out nasal pathology

INVESTIGATIONS

BLOOD:

- Bleeding time
- Clotting time
- Blood sugar
- Hemogram

URINE:

- Albumin
- Sugar and deposits

XRAY PARANASAL SINUSES

To rule out deviated nasal septum.

BLOOD PRESSURE EXAMINATION

SURGICAL DETAILS AND POST OPERATIVE MANAGEMENT

ANAESTHESIA

Endonasal dacryocystorhinostomy is performed under local anaesthesia.

Nasal mucosal preparation is done by using nasal packs soaked with 2% lignocaine and 1:100000 adrenaline.

Additional infiltration of the lateral nasal wall was done with a solution of 2% lignocaine and 1:100000 adrenaline.

ENDONASAL DCR

The patient is placed in a supine position with the head elevated 15 degrees. The shrinkage of the nasal mucosa with the above packing is noticed.

A 4 mm diameter, zero or thirty degree endoscope is used. Using a sickle knife, a vertical mucosal incision is made 8 mm anterior from the attachment of uncinat process at the lateral nasal wall and it is extended

from just above the anterior attachment of the middle turbinate to the attachment of the inferior turbinate.

The mucosal flap is elevated backwards off the maxillary bone and removed with cutting forceps. Bone covering the lacrimal sac is then gently removed with bone punch until the sac is widely exposed to the level of the fundus. . A metallic lacrimal probe is passed through inferior canaliculi and gently pushed medially to tent the lumen of the sac and to facilitate the incision on the sac.

After identifying the lumen, a vertical incision is made with a sickle knife and extended to the fundus of the sac. An anteriorly based lacrimal sac flap is created, everted and adjusted to accurately oppose the nasal mucosa to maintain the patency.

The patency of the ostium is checked by injecting fluorescein dye through the lower punctum or by passing a Bowman's lacrimal probe through the lower punctum.

Post operatively all the patients are treated with systemic antibiotics, antiinflammatory drugs, antibiotic eye drops and nasal decongestant drops.

VERBAL PAIN AND EDEMA SCORE (0-3)

The patients were examined for post operative comfort level on the first postoperative day on the basis of the following score.

- Score 0-nil pain, no edema
- Score 1-Mild pain and edema
- Score 2-Moderate pain and edema
- Score 3- Severe pain and edema

FOLLOW UP

- Every patient was followed up for every 1 week for 1 month,
- Every month for next three months and
- Every three months for the subsequent six months.

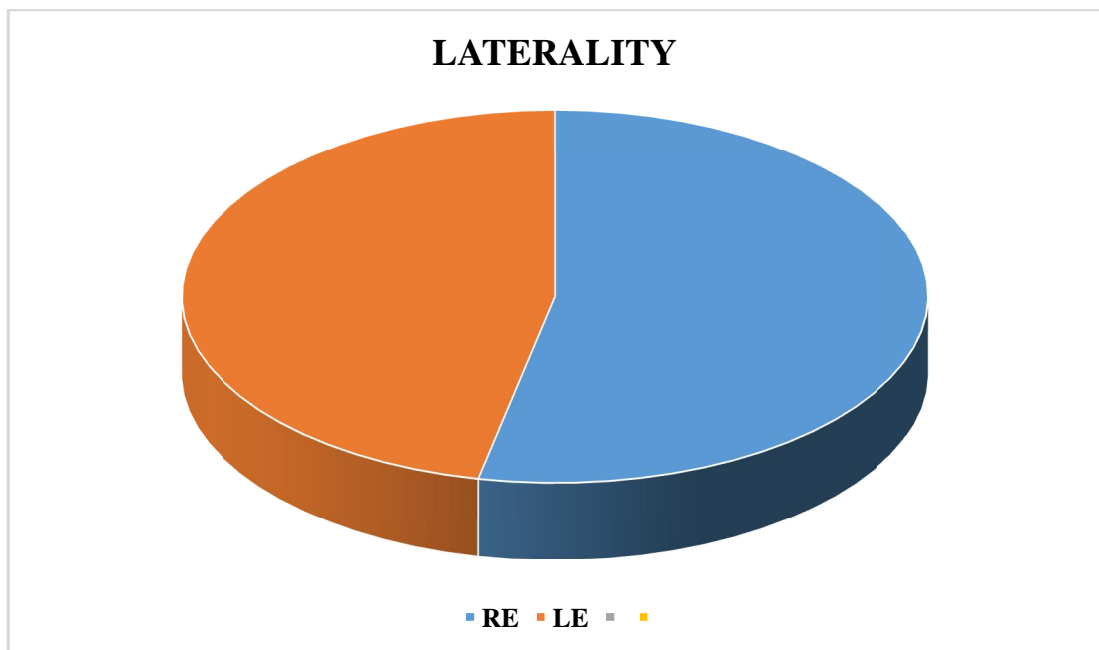
At each visit the status of the nasolacrimal duct is assessed by syringing and the patency is checked. Both anatomical patency of the NLD and symptomatic relief of the patient constitute the successful outcome of the surgery.

OBSERVATION AND ANALYSIS

- 30 patients were included in this study
- 26 patients were females and 4 were males
- Age of the patients ranged from 20-60 years
- All patients were presented with complaints of pain, watering, discharge, swelling in lacrimal sac region. In addition to the above complaints, 5 patients presented with pre septal cellulitis and 7 patients presented with lacrimal abscess.

LATERALITY

LATERALITY	PRESENTATION	PERCENTAGE
RIGHT EYE	16	53.3
LEFT EYE	14	46.6
TOTAL	30	100

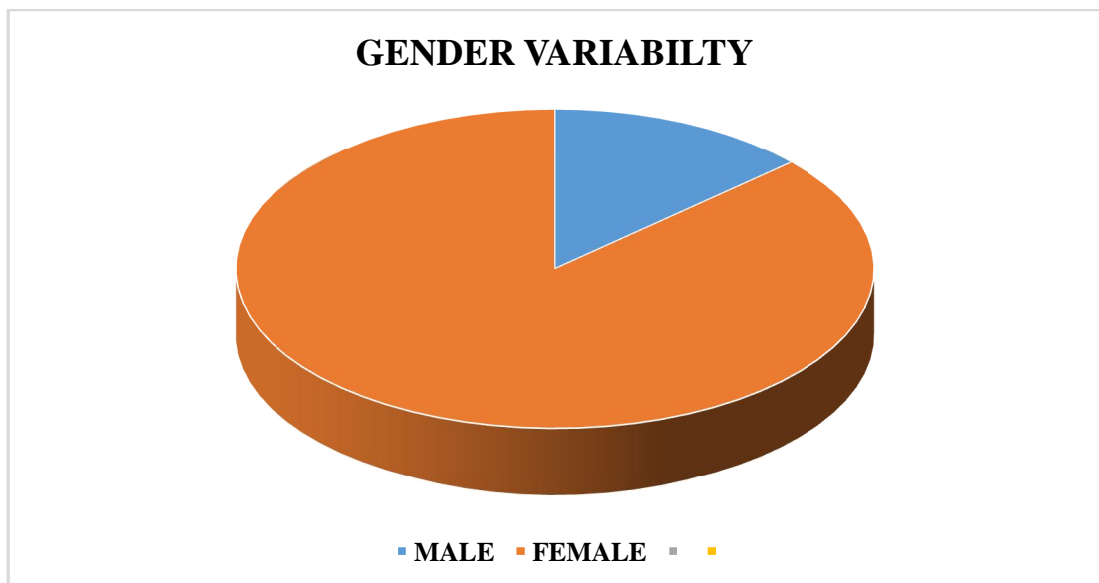


In our study, acute dacryocystitis is found to be common in the right eye.

There is no predilection towards laterality is noted.

GENDER VARIABILITY

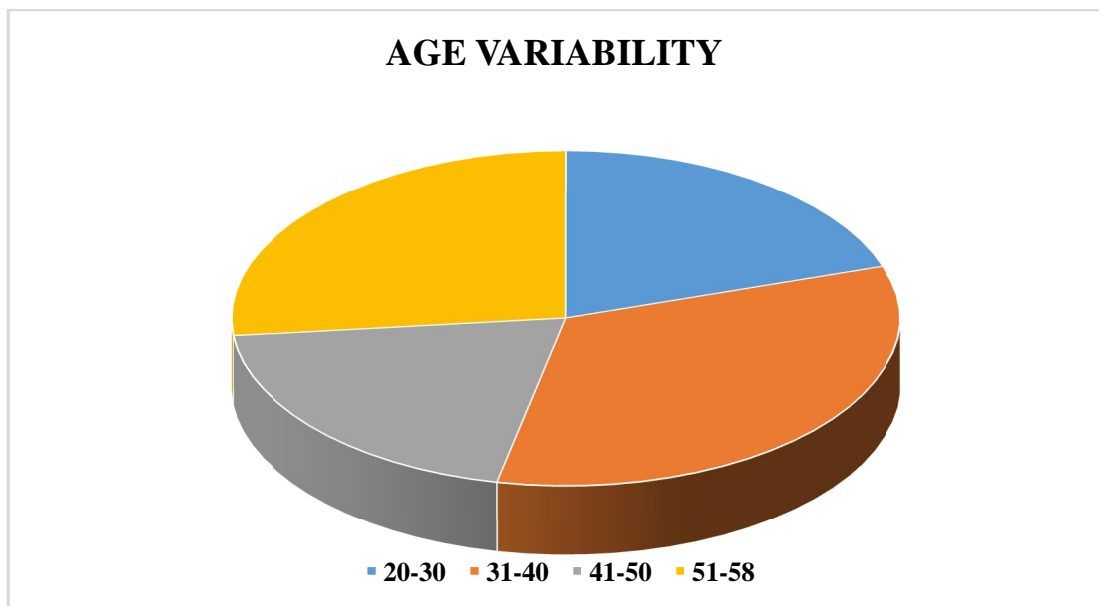
GENDER	NO OF CASES	PERCENTAGE
MALE	4	13.3
FEMALE	26	86.7
TOTAL	30	100



Acute dacryocystitis is common among female population. This is because of the narrow lumen in the bony canal in the females (Meller 1929). This correlates with the incidence given by Duke Elder (1974) that Female: male ratio is around 80:20 in dacryocystitis

AGE VARIABILITY

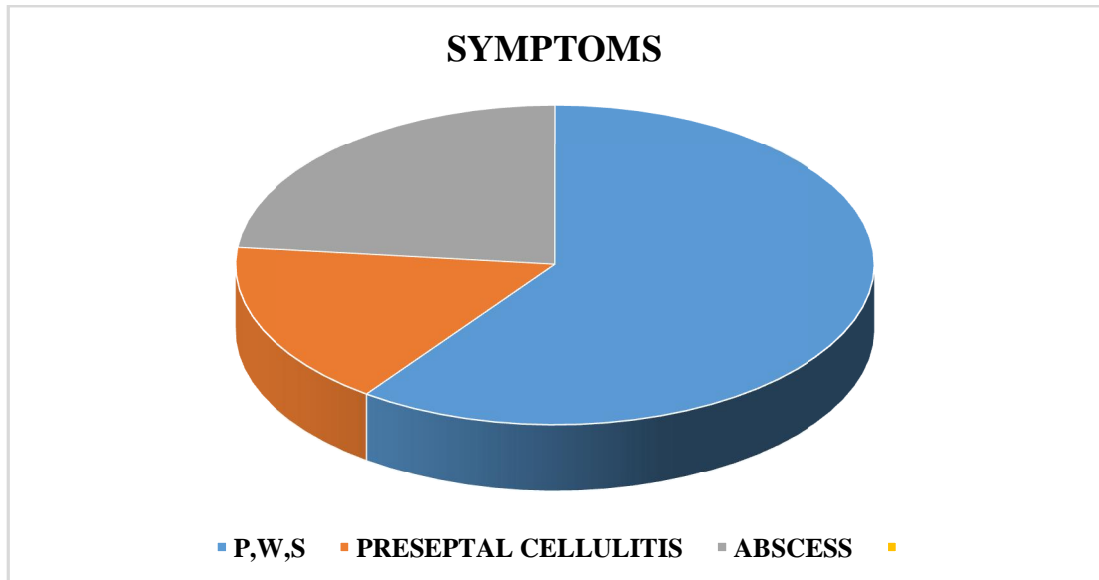
AGE IN YEARS	NO OF CASES	PERCENTAGE
20-30	6	20
31-40	8	26.7
41-50	6	20
51-58	10	33.3
TOTAL	30	100



Acute dacryocystitis was found to be common in the fifth decade in this study.

PRESENTING SYMPTOMS

SYMPTOMS	NO OF CASES	PERCENTAGE
PAIN, SWELLING, WATERING	18	60
PRESEPTAL CELLULITIS	5	16.7
LACRIMAL ABSCESS	7	23.3
TOTAL	30	100



In this study it was found to be Pain, Swelling in lacrimal sac area, Watering and Discharge were present in all the cases

Preseptal cellulitis was present in 5 cases

Lacrimal abscess in 7 cases

FOLLOW UP

All the patients who underwent endonasal DCR were examined with naso lacrimal duct syringing on the first postoperative day and at the end of first week.

In our study two patients were presented with simple regurgitation through opposite punctum. They were treated with meticulous antibiotic steroid syringing on alternate days. Their ducts became patent by the end of first week.

At the end of first month two patients were found have blocked ducts. So the success rate of this procedure at the end of the first month was around 93.3%

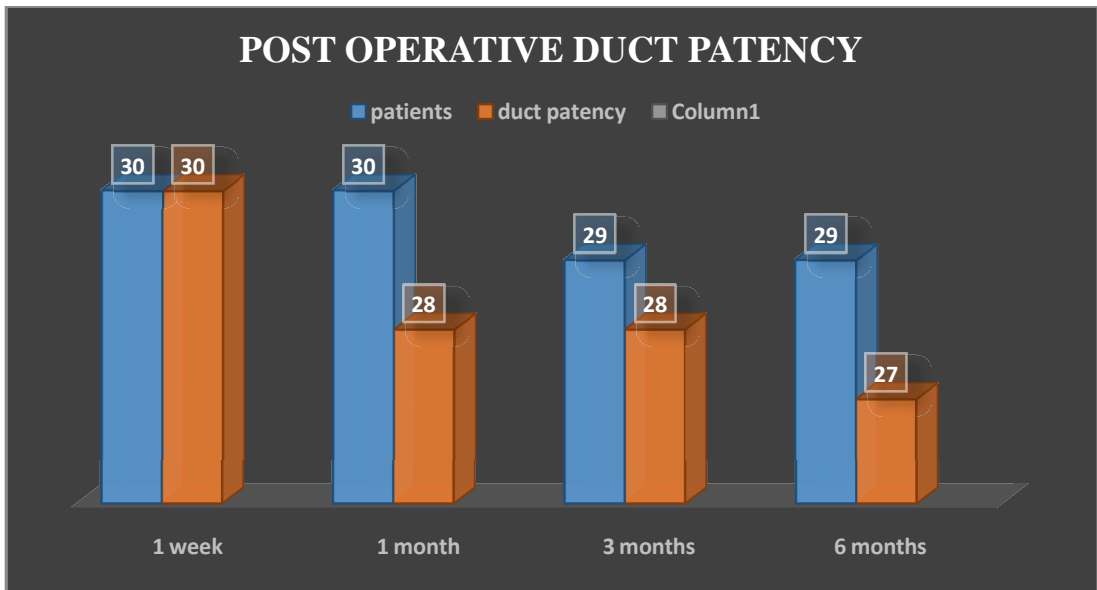
The two patients with blocked ducts were taken up for diagnostic revision endonasal DCR and the mucosal flaps and the closure of the ostium were revised.

At the end of third month, one patient was lost for follow up and one had blocked duct.

At the end of six months one patient did not come for follow up and two patients had blocked ducts. The success rate of this study is around 90% at the end of six months. Both the patients with blocked ducts had fibrous adhesions and subjected for revision surgery after releasing the fibrous adhesions.

POST OPERATIVE DUCT PATENCY

FOLLOW-UP PERIOD	NO OF CASES WITH PATENT DUCT	PERCENTAGE
END OF 1 WEEK	30	100%
END OF 1 MONTH	28	93.3%
END OF 3 MONTHS	28	93.3%
END OF 6 MONTHS	27	90%



At the end of the first week all cases had patent ducts

At the end of first month 2 patients had blocked ducts

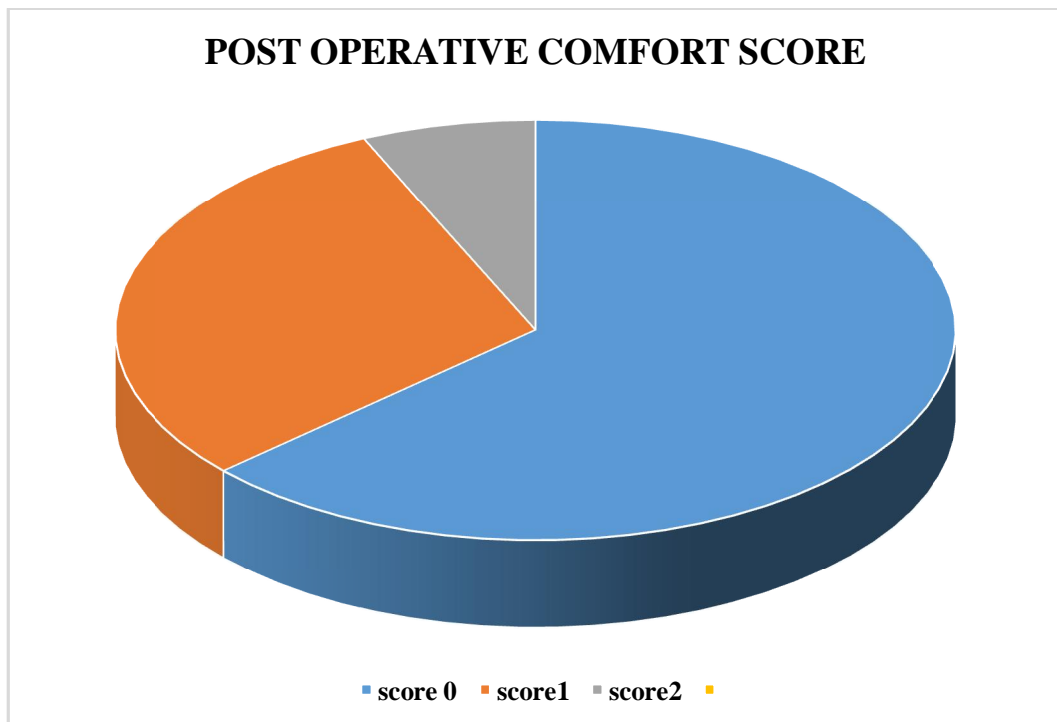
At the end of third month 1 patient had blocked duct and 1 did not come for follow up

At the end of 6 months 2 patients had blocked ducts and 1 did not come for follow up.

The success rate of this procedure is 90% at the end of six months.

POST OPERATIVE COMFORT SCORE

SCORES	NO OF CASES	PERCENTAGE
SCORE 0	19	63.3
SCORE 1	9	30
SCORE 2	2	6.7
TOTAL	30	100



Out of 30 patients

19 patients had no pain and edema

9 patients suffered from mild pain and edema

2 patients had moderate pain and edema.

In this study it is found to be most of the patients were symptom free in the postoperative period.

COMPLICATIONS
INTRA OPERATIVE COMPLICATIONS

HAEMORRAHGE	2 (6.7%)
INJURY TO THE ORBIT AND PERI ORBITA	NIL
CSF LEAK	NIL

Two patients with intra operative bleeding were managed by applying pressure and packing cotton pledgets soaked with vaso constrictive agents like adrenaline

IMMEDIATE POST OPERATIVE COMPLICATIONS

LOCAL INFECTIONS	NIL
EPISTAXIS	1(3.3%)
SUBCUTANEOUS EMPHYSEMA	NIL
CSF LEAK	NIL

One patient suffered from epistaxis and was managed with adrenaline nasal packs.

LATE POST OPERATIVE COMPLICATIONS

CLOSURE OF THE OSTIUM	2 (6.7%)
SCARRING	NIL
SUMP SYNDROME	NIL
CANALICULAR STENOSIS	NIL

Patients who presented with late closure of the ostium were subjected for revision surgery after releasing the adhesions.

DISCUSSION AND RESULTS

Acute dacryocystitis is more common on the right side

Acute dacryocystitis is more common among females. This is because of the narrow lumen in the bony canal which leads to partial or complete closure of the NLD. Acute dacryocystitis is more common in 5th decade.

Acute dacryocystitis presents with complaints of pain, watering, discharge, swelling in the lacrimal sac region and occasionally with pre septal cellulitis and lacrimal abscess.

ROPLAS test and lacrimal syringing are contra indicated in the acute phase of the disease. The diagnosis is made exclusively on clinical signs and symptoms.

The conventional treatment for a case of acute dacryocystitis includes warm compresses, use of systemic antibiotic therapy, percutaneous route of drainage of the abscess and plan for external DCR after complete resolution of infection.

This however may result in formation of cutaneous fistula formation, risk of incidence of recurrent infection before external DCR, prolong the illness and intake of antibiotic therapy.

The procedure of external DCR is contraindicated in acute dacryocystitis. Because it spreads the infection via the tissue planes, exacerbates inflammation and causes septicemia. An endonasal approach reduces these complications since the lacrimal sac abscess is approached via the noninfected and less inflamed tissue areas.

Endonasal drainage of the abscess causes rapid resolution of symptoms and signs.

If the acute dacryocystitis is left unattended it may lead to the formation of lacrimal abscess which may burst open and leads to the formation of lacrimal fistula. These complications can be avoided by timely intervention by endonasal DCR.

Endonasal DCR is associated with less intra operative and early postoperative complications like injury to neighbouring structures.

Endonasal DCR is associated with less postoperative pain, edema, bleeding and cosmetically well acceptable since there is no external scar.

The average time taken for the procedure is ranged from 45 to 60 minutes.

In spite of the expert surgical skills, steep learning curve and expensive instrumentation required, this produces effective results in acute dacryocystitis. The success of the surgery is determined by NLD patency and symptomatic relief of the patient.

REVIEW OF LITERATURE

Acute dacryocystitis with abscess - Endonasal DCR-the primary treatment of choice by Sudhir N Naik et al has proven primary endonasal DCR is a highly successful procedure for acute dacryocystitis with abscess preventing recurrence also relieves the pre-existing symptoms like epiphora.

He also emphasises that neo-ostium cicatrization and closure is considered as a major factor for surgical failure of this procedure. Wide neo-ostium, mucosal flaps, sac marsupialisation with primary healing and silicon tube stenting improves success in surgical outcome. He also gives a success rate of 89.53% without stenting and 89.39% with stents.

This study correlates with our study in the success rate since our study has a success rate of 90%

Endoscopic DCR in acute dacryocystitis by S N Madge Et al performed endonasal DCR early in acute dacryocystitis led to rapid resolution of the condition and associated with subsequent anatomical and functional success in 94.4% of cases.

Endonasal DCR versus external DCR in acute dacryocystitis a comparative analysis by Rinki saha et al proves that endonasal DCR is the treatment of choice in acute dacryocystitis. It concluded endoscopic DCR is a safe, minimally invasive, day-care technique with a good aesthetic result.

Effect of endonasal DCR on acute dacryocystitis as a primary treatment by Lee JB et al proves that endonasal DCR helps in rapid resolution of the patient symptoms with minimal or no pain, bleeding, edema and no scar.

In our study also nasolacrimal duct was patent the postoperative comfort level on day 1 describes score 0 in 19 patients (63.3%) denotes no pain and edema indicating rapid resolution of symptoms in all the patients.

Primary treatment of acute dacryocystitis by endonasal DCR with silicone intubation guided by a soft probe Wencan wu et al emphasises that external DCR along with silicone stenting helps in prevention of failure rate of this procedure and this study has a success rate of 90%.

The above study correlates with the success outcome of our study.

S Morgan et al emphasises laser assisted endonasal DCR by using Holmium YAG laser in cases of acute dacryocystitis proves success rate in the procedure.

CONCLUSION

Endonasal dacryocystorhinostomy is proved to be the treatment of choice in cases of acute dacryocystitis, compared to previous conventional external DCR.

Endonasal DCR is a real boon in this world of upcoming cosmetic surgeries. As capsule endoscopies in gastroenterology and micro incision phacoemulsification in cataract surgery, endonasal DCR is now dominating the field of lacrimal surgery.

It gives less pain, edema, bleeding, fistula formation.

Being aesthetically more acceptable it causes no scar, no adhesions.

It lessens the hospital stay, and provides an additional economic benefits for the patient by avoiding readmission for external DCR and prevents fistula formation.

The overall success rate of this procedure in this study is 90%.

PROFORMA

1. SERIAL NO OP/IP NO
2. NAME AND ADDRESS
3. AGE/SEX
4. OCCUPATION
5. D. O.A
6. D .O. S
7. D .O. D
8. PRESENTING COMPLAINTS AND DURATION
 - PAIN
 - WATERING
 - DISCHARGE
 - SWELLING
 - OTHERS -H/O IRRITATION, REDNESS
9. PAST HISTORY
 - H/O SIMILAR EPISODES IN THE PAST
 - NASAL PROBLEMS
 - SURGERY/TRAUMA
 - DRUG ALLERGY
 - BLEEDING DISORDERS/ANTI COAGULANTS USE
 - SYSTEMIC DISEASES

EXAMINATION

NASAL

- TUMOURS
- POLYP
- HYPERTROPHIED TURBINATE
- DEVIATED NASAL SEPTUM

OCULAR EXAMINATION

- LID ABNORMALITIES
- EPIPHORA/ DISCHARGE
- SWELLING IN THE SAC REGION

SKIN OVER THE SWELLING

WARMTH

TENDERNESS

FISTULA

CLINICAL DIAGNOSIS

INVESTIGATIONS

BLOOD

HB, TC, DC, ESR, BT, CT

RBS

URINE

ALBUMIN/ SUGAR/ DEPOSITS

X RAY PARA NASAL SINUSES

DIAGNOSTIC NASAL ENDOSCOPY

BLOOD PRESSURE EXAMINATION

SURGERY

ENDONASAL DACRYOCYSTORHINOSTOMY

ANAESTHESIA

LOCAL

COMPLICATIONS

INTRA OPERATIVE/ POST OPERATIVE

POST OPERATIVE FOLLOW UP

PAIN AND EDEMA ON DAY 1

PATENCY OF THE NLD

DAY 1

1 WEEK

1 MONTH

3 MONTHS

6 MONTHS

OUTCOME

SL NO	NAME	AGE	SEX	OCCU	IP/OP NO	C/O	LATERALITY	D O S	COMP	FOLLOW UP					POST OPERATIVE COMFORT LEVEL ON DAY 1				RESULTS
										DUCT PATENCY					SCORE 0	1	2	3	
										DAY 1	1 WEEK	1 MONTH	3 MONTHS	6 MONTHS					
1	INDIRA	27	FE	HW	3961	P, S, W	RE	2.10.13	-	+	+	+	+	+	+				S
2	RANI	45	FE	HW	84721	P, S, W	RE	2.10.13	-	+	+	+	+	+	+				S
3	KALA	28	FE	C	15206	P,S,W,C	LE	9.10.13	-	+	+	+	+	+	+				S
4	KRISHNAN	37	M	C	49326	P, S, W	RE	9.10.13	-	+	+	+	+	+	+		+		S
5	GOMATHI	45	FE	C	494910	P, S, W	LE	23.10.13	E	+	+	+	+	+	+				S
6	GANDHIMATHI	51	FE	HW	16722	P, S, W,A	RE	23.10.13	-	+	+	+	+	+	+				S
7	PARVATHI	54	FE	HW	15708	P,S,W	RE	30.10.13	-	+	+	+	+	+	+		+		S
8	GOWRI	48	FE	C	494918	P,S,W,C	LE	6.11.13	-	+	+	B	B	B		+			F
9	SUMATHI	53	FE	HW	17456	P,S,W	LE	6.11.13	H	+	+	+	+	+	+				S
10	PANDIAMMAL	35	FE	C	13229	P,S,W	RE	13.11.13	-	+	+	+	+	+	+				S
11	KARUNA	29	FE	C	494591	P,S,W,A	LE	27.11.13	-	+	+	+	+	+	+				S
12	SARASWATHI	44	FE	C	15473	P,S,W	RE	27.11.13	-	+	+	+	L	L	+				L
13	POONGAVANAM	41	FE	HW	9915	P,S,W	RE	14.12.13	-	+	+	+	+	+	+				S
14	SELVARANI	39	FE	HW	60669	P,S,W,C	RE	14.12.13	-	+	+	+	+	+	+		+		S
15	SAKUNTALA	53	FE	HW	13524	P,S,W	RE	18.12.13	O C	+	+	+	+	B		+			F
16	VIMALA	45	FE	HW	496917	P,V,W,A	LE	15.1.14	-	+	+	+	+	+	+				S
17	MOORTHY	55	M	C	29729	P,S,W	LE	22.1.14	-	+	+	+	+	+	+		+		S
18	VALLIAMMAL	57	FE	HW	3879	P,S,W	RE	22.1.14	O C	+	+	+	B	+	+				S
19	PENCILLAMMA	38	FE	C	84774	P,P,W,C	RE	3.2.14	-	+	+	+	+	+	+			+	S
20	KRISHNAVENI	34	FE	C	30354	P,K,W,A	LE	12.2.14	-	+	+	+	+	+	+				S
21	CHANDRAN	54	M	C	27388	P,S,W	RE	12.2.14	-	+	+	+	+	+	+				S
22	KANNIAMMAL	28	FE	HW	62634	P,S,W	LE	26.2.14	-	+	+	+	+	+	+		+		S
23	DHANALAKSHMI	34	FE	HW	29742	P,S,W,A	RE	5.3.14	-	+	+	+	+	+	+			+	S
24	BHUVANESWARI	56	FE	HW	33851	P,B,W,C	RE	5.3.14	H	+	+	+	+	+	+				S
25	SELVARAJ	52	M	C	34923	P,S,W	LE	12.3.14	-	+	+	+	+	+	+				S
26	SEETHA	27	FE	C	28564	P,S,W,A	RE	26.3.14	-	+	+	+	+	+	+		+		S
27	KANNAMMAL	53	FE	HW	31236	P,S,W	LE	26.3.14	-	+	+	+	+	+	+				S
28	BABY	29	FE	C	35595	P,S,W,A	LE	1.4.14	-	+	+	+	+	+	+		+		S
29	MUNIAMMAL	37	FE	C	42836	P,S,W	LE	3.4.14	-	+	+	+	+	+	+				S
30	MUTHULAKSHMI	39	FE	HW	24975	P,S,W	LE	3.4.14	-	+	+	+	+	+	+				S

KEY WORDS TO MASTER CHART

1.	SL.NO	-	SERIAL NUMBER
2.	M/F	-	MALE/ FEMALE
3.	OCCU	-	OCCUPATION
4.	HW	-	HOUSE WIFE
5.	CO	-	COOLY
6.	IP/OP	-	INPATIENT/ OUTPATIENT
7.	R/L	-	RIGHT/ LEFT
8.	RE	-	RIGHT EYE
9.	LE	-	LEFT EYE
10.	W	-	WATERING
11.	D	-	DISCHARGE
12.	S	-	SWELLING
13.	A	-	ABSCESS
14.	CE	-	CELLULITIS
15.	B	-	BLEEDING
16.	E	-	EPISTAXIS
17.	D O S	-	DATE OF SURGERY
18.	COMP	-	COMPLICATIONS
19.	H	-	HAEMORRHAGE
20.	OC	-	CLOSURE OF OSTIUM
21.	D	-	DROP OUT
22.	F	-	FAILURE
23.	S	-	SUCCESS
24.	B	-	BLOCK

BIBLIOGRAPHY

TEXT BOOKS

1. Wolff's Anatomy of the eye and orbit, J.Bron, 8thedition,1997, 72-84.
2. System of Ophthalmology- Sir Stewart Duke Elder- Vol 13, Ocular Adnexa, Part 2, 675-693.
3. Albert&Jakobiec's Principles and Practice of Ophthalmology, 2nd edition, Volume4, Lids and Orbit, 3550-3564.
4. Parsons Diseases of the Eye- 19thedition, 496-504.
5. Roper Hall, M J Stallard'sEye Surgery- 7th edition.
6. American Academy of Ophthalmology, 2012-2013-Orbit, Eyelids, and Lacrimal System, Section 7,249-277.
7. Smith's Ophthalmic Plastic and Reconstructive Surgery, 2nd edition, 1998,13-25.
8. Endoscopic Sinus Surgery- Levine and May.
9. Colour Atlas of Lacrimal Surgery- Jane Olver- 2002,29-144
10. Endoscopic Sinus Surgery- Stammburger

11. Ophthalmology- Myron Yanoff, Jay S.Duker 2 nd edition, 2004, 761-767
12. A Handbook of Endoscopic Sinus Surgery- Dr Ravi Ramalingam, KKR ENT Hospital.
13. Atlas of Lacrimal Surgery, R K Weber, 2007, 15-61, 87-105.
14. Kanski JackJ, 7 th Edition, 65-77.
15. Dutta L C, Modern Ophthalmology, 3rd edition, Vol 2, 708-728
16. Peymen, Sanders and Goldberg- Principles and Practice of Ophthalmology, Vol 3, 1987,2273-2290 Endoscopic Sinus Surgery.
17. Wormald, Peter John, Endoscopic Sinus Surgery- Anatomy, 3 Dimensional Reconstruction and Surgical Technique, 2nd edition, 143-153.
18. DipakRanjanNayak, Manipal Manual of Endoscopic Sinus Surgery, 1st edition,2008,43-50,68-71,109-112.
19. Anatomical Principles Of Endoscopic Sinus Surgery, A Step By Step Approach, RenukaBradoo, 1st edition,2005, 59-83.
20. Carlos Yanez, Endoscopic Sinus Surgery, A Comprehensive Atlas, 2003, 114-117.

JOURNALS

21. Cahill KV, Burns JA, management of acute dacryocystitis in adults, *ophthal plastic reconstruction surg* 1993;9:38-41
22. Massaro BM, Gonnering RS, Harris GJ. Endonasal laser dacryocystorhinostomy. A new approach to naso lacrimal duct obstruction. *AM J Ophthalmol* 1993;116; 1-10
23. Lee Ts, Woog JJ. Endonasal dacryocystorhinostomy in the Primary treatment of Acute dacryocystitis with abscess formation. *Ophthalplastreconstsurg* 2001;17; 180-83
24. Duggal P, Mahindroo NK, Chauhan A. Primary endoscopic dacryocystorhinostomy as treatment for acute dacryocystitis with abscess formation. *Am J Otolaryngology Head neck med surg* 2008;29;177-79
25. Hartikainen J, Gremman R, Puukka P, Seppa H. Prospective randomized comparison of external DCR and endonasal DCR. *Ophthalmology* 1998;105; 1106-13.
26. Primary endoscopic dacryocystorhinostomy as treatment for acute dacryocystitis with abscess formation Prahald Duggal, M S(ENT) Narinder K. Mahindroo, M S(ENT), Anil Chauhan, M S (Ophthalmology)
27. Shigeta K, Takegoshi H, Kikuchi S. Sex and age differences in the bony nasolacrimal canal. *Arch Ophthalmol* 2007; **125**:1677–81.

28. Woog JJ. The incidence of symptomatic acquired lacrimal outflow obstruction among residents of Olmsted County, Minnesota, 1976–2000 (an American Ophthalmological Society thesis). *Trans Am Ophthalmol Soc* 2007; **105**: 649–66.
29. Traquair H. Chronic dacryocystitis: its causation and treatment. *Arch Ophthalmol* 1941; **26**: 165–80.
30. Woog JJ, Kennedy RH, Custer PL, Kaltreider SA, Meyer DR, Camara JG. Endonasaldacryocystorhinostomy: a report by the American Academy of Ophthalmology. *Ophthalmology* 2001; **108**: 2369–77.
31. Watkins LM, Janfaza P, Rubin PAD. Evolution of endonasaldacryocystorhinostomy. *Surv Ophthalmol* 2003; **48**: 73–84.
32. Dolman PJ. Comparison of external dacryocystorhinostomy with nonlaser endonasaldacryocystorhinostomy. *Ophthalmology* 2003; **110**: 78–84.
33. Hartikainen J, Antila J, Varpula M, Puukka P, Seppä H, Grenman R. Prospective randomized comparison of endonasal endoscopic dacryocystorhinostomy and external dacryocystorhinostomy. *Laryngoscope* 1998; **108**: 1861–6.
34. Verma A, Khabori MA, Zutshi R. Endonasal carbon-dioxide laser assisted dacryocystorhinostomy versus external dacryocystorhinostomy. *Indian J Otolaryngol Head Neck Surg* 2006; **58**: 9–14.

35. Ben Simon GJ, Joseph J, Lee S, Schwarcz RM, McCann JD, Goldberg RA. External versus endoscopic dacryocystorhinostomy for acquired nasolacrimal duct obstruction in a tertiary referral center. *Ophthalmology* 2005; **112**: 1463–8.
36. Yigit O, Samancioglu M, Taskin U, Ceylan S, Eltutar K, Yener M. External and endoscopic dacryocystorhinostomy in chronic dacryocystitis: comparison of results. *Eur Arch Otorhinolaryngol* 2007; **264**: 879–85.
37. Tsirbas A, Davis G, Wormald PJ. Revision dacryocystorhinostomy: a comparison of endoscopic and external techniques. *Am J Rhinol* 2005; **19**: 322–Higgins JPT, Green S. *Cochrane Handbook for Systematic Reviews of Interventions* Version 5.0.1. 2008.
38. Hartikainen J, Grenman R, Puukka P, Seppä H. Prospective randomized comparison of external dacryocystorhinostomy and endonasal laser dacryocystorhinostomy. *Ophthalmology* 1998; **105**: 1106–13.
39. Lester SE, Robson AK, Bearn M. Endoscopic ‘cold steel’ versus laser dacryocystorhinostomy: completing the audit cycle. *J LaryngolOtol* 2007; **122**: 924–7.
40. Mirza A, Al-Barmani A, Douglas SA, Bearn MA, Robson AK. A retrospective comparison of endonasal KTP laser dacryocystorhinostomy versus external dacryocystorhinostomy. *ClinOtolaryngol Allied Sci* 2002; **27**: 347–51.

41. Watts P, Ram AR, Nair R, Williams H. Comparison of external dacryocystorhinostomy and 5-fluorouracil augmented endonasal laser dacryocystorhinostomy. a retrospective review. *Indian J Ophthalmol* 2001; **49**: 169–72.
42. Ibrahim HA, Batterbury M, Banhegyi G, McGalliard J. Endonasal laser dacryocystorhinostomy and external dacryocystorhinostomy outcome profile in a general ophthalmic service unit: a comparative retrospective study. *Ophthalmic Surg Lasers* 2001; **32**: 220–7.
43. Ajalloueyan M, Fartookzadeh M, Parhizgar H. Use of laser for dacryocystorhinostomy. *Arch Otolaryngol Head Neck Surg* 2007; **133**: 340–3. Malhotra R, Wright M, Olver JM. A consideration of the time taken to do dacryocystorhinostomy (DCR) surgery. *Eye* 2003; **17**:691–6.
44. Maini S, Raghava N, Youngs R *et al.* Endoscopic endonasal laser versus endonasal surgical dacryocystorhinostomy for epiphora due to nasolacrimal duct obstruction: prospective, randomised, controlled trial. *J LaryngolOtol* 2007; **121**: 1170–6.
45. Anari S, Ainsworth G, Robson AK. Cost-efficiency of endoscopic and external dacryocystorhinostomy. *J LaryngolOtol* 2008; **122**:476–9
46. Sharma B. Non endoscopic endonasaldacryocystorhinostomy versus external dacryocystorhinostomy. *Kathmandu Univ Med J*2008; **6**: 437–42.

47. Cokkeser Y, Evereklioglu C, Er H. Comparative external versus endoscopic dacryocystorhinostomy: results in 115 patients (130 eyes). *Otolaryngol Head Neck Surg* 2000; **123**: 488–91.
48. Leong SC, Karkos PD, Burgess P, Halliwell M, Hampal SA. Comparison of outcomes between nonlaser endoscopic endonasal and external dacryocystorhinostomy: single-center experience and a review of British trends. [CrossRef](#), [PubMed](#) *Am J Otolaryngol* 2010; **31**
49. Tsirbas A, Davis G, Wormald PJ. Mechanical endonasaldacryocystorhinostomy versus external dacryocystorhinostomy. *Ophthalmic Plast Reconstr Surg* 2004; **20**: 50