

**“STRAIN USG ELASTOGRAPHY WITH GRAY  
SCALE AND COLOUR DOPPLER IMAGING OF  
THYROID NODULES –EFFICACY COMPARED  
WITH FNAC ”**

*Dissertation submitted to*

**THE TAMIL NADU DR.M.G.R.MEDICAL UNIVERISTY  
CHENNAI**

*In Partial Fulfillment of the Regulations  
for the Award of the degree*

**M.D. DEGREE EXAMINATION  
BRANCH VIII RADIODIAGNOSIS**

**MADRAS MEDICAL COLLEGE  
&  
RAJIV GANDHI GOVERNMENT GENERAL HOSPITAL,  
CHENNAI -600 003.**



**THE TAMIL NADU DR.M.G.R.MEDICAL UNIVERISTY  
CHENNAI -600 003. TAMIL NADU**

**APRIL-2018**

## **BONAFIDE CERTIFICATE**

Certified that this dissertation is the bonafide work of DR.A.KARPAGAVALLI on **“STRAIN USG ELASTOGRAPHY WITH GRAY SCALE AND COLOUR DOPPLER IMAGING OF THYROID NODULES – EFFICACY COMPARED WITH FNAC”** during her MD(RADIODIAGNOSIS) in Barnard Institute of Radiology in the academic year of 2015-2018 at the Madras Medical College and Rajiv Gandhi Government General Hospital, Chennai-600003.

**PROF.DR.N.KAILASANATHAN, MD, DMRD**  
FORMER DIRECTOR AND PROFESSOR,  
Department of Radiodiagnosis,  
Barnard institute of Radiology,  
Rajiv Gandhi Government General Hospital,  
Madras Medical College,  
Chennai -600003.

**PROF.DR.RAVI MD, DMRD**  
Director,  
Barnard Institute of Radiology,  
Madras Medical College &  
Rajiv Gandhi Government  
General Hospital,  
Chennai – 600 003.

**PROF.DR.R.NARAYANABABU, MD., D.Ch.,**  
Dean  
Madras Medical College &  
Rajiv Gandhi Government General Hospital,  
Chennai – 600 003.

## **DECLARATION**

I, certainly declare that this dissertation titled “**STRAIN USG ELASTOGRAPHY WITH GRAY SCALE AND COLOUR DOPPLER IMAGING OF THYROID NODULES – EFFICACY COMPARED WITH FNAC**” represent a genuine work of mine. The contribution of any supervisors to the research are consistant with normal supervisory practice, and are acknowledged.

I, also affirm that this bonafide work or part of this work was not submitted by me or any others for any award, degree or diploma to any other university board, neither in India or abroad. This is submitted to The Tamil Nadu Dr.MGR Medical University, Chennai in partial fulfilment of the rules and regulation for the award of Master of Radiodiagnosis Branch VIII.

**DR.KARPAGAVALLI .A**

Date :  
Place: Chennai

## **ACKNOWLEDGEMENT**

I would like to express my deep sense of gratitude to **PROF.DR.R.NARAYANA BABU, MD., D.Ch.**, Dean, Madras Medical College & Rajiv Gandhi Government General Hospital Chennai, for giving me permission to conduct the study in this institution.

With extreme gratefulness, I express my indebtedness to **PROF.DR.RAVI, MD.,DMRD**, Director, Barnard Institute of radiology, MMC & RGGGH, for allowing me to undertake this study on “**STRAIN USG ELASTOGRAPHY WITH GRAY SCALE AND COLOUR DOPPLER IMAGING OF THYROID NODULES – EFFICACY COMPARED WITH FNAC**”

I would like to express my deep gratitude and respect to my guide **FORMER PROF.DR.N .KAILASANATHAN, MD, D.M.R.D** whose advice and insight was invaluable to me. This work would not have been possible without his guidance, support and encouragement.

I was able to carry out my study to my fullest satisfaction, thanks to guidance, encouragement, motivation and constant supervision extended to me, by my beloved Head of the Department **PROF.DR. MALATHI, MD., DMRD** .Hence my profuse thanks are due for her.

My sincere thanks to **Prof.Dr.S.Kalpana,MD.,DNB** for her practical comments and guidance especially at the inception of the study and I also wish to thank **Prof.Dr.S.Babu Peter,MD.,DNB** for his valuable support through out the study.

I am also extremely indebted to **Prof.Dr.D.Ramesh MD** for his valuable suggestions.

I am extremely thankful to my Associate Professor **Dr.GangaDevi MD.,DMRD.,FRCR** for her invaluable contribution ,personal attention, constructive criticism she has made during my study.

I am bound by ties of gratitude to my respected Associate Professors, **Dr.Manimekala MD.,DNB** and **Dr.KasiVisalakshi,MD** and Assistant professors **Dr.K.Geetha MD, Dr.J.Chezhan MD, Dr.G.Geetha MD , Dr.S.Iyengaran, Dr.Mohideen Ashraf MD, Dr.Saranya DMRD , Dr.Balan DMRD, DR.Dheeba MD, Dr.Karthick MD** in general, for placing and guiding me on the right track from the very beginning of my career in Radiodiagnosis till this day.

I am fortunate to have my postgraduate colleagues **Dr.Elavazhagan, Dr.Kanmani kiruba, Dr.Sakthivel raja** and **Dr.Swarnalakshmi** for their valuable suggestions, relentless help for shouldering my responsibilities. Simply words cannot express its depth

for their unseen contributions. My lovable thanks to my family for their moral support.

I would be failing in my duty if I don't place on record my sincere thanks to those patients who inspite of their sufferings extended their fullest co-operation.

**DR.KARPAGAVALLI. A**

## INDEX

<b>SL.NO</b>	<b>CONTENTS</b>	<b>PAGE</b>
1	INTRODUCTION	1
2	ANATOMY AND EMBRYOLOGY	3
3	APPROACH TO THYROID LESIONS	13
4	DIFFUSE THYROID LESIONS	14
5	NODULAR THYROID LESIONS	19
6	EVALUATION OF THYROID NODULES BY USG	35
7	THYROID SONOELASTOGRAPHY	48
8	AIMS AND OBJECTIVES	55
9	MATERIALS AND METHODS	56
10	REPRESENTATIVE CASES	59
11	STATISTICAL ANALYSIS	64
12	RESULTS &DISCUSSION	78
13	CONCLUSION	84
14	BIBLOGRAPHY	
16	ANNXEURE PROFORMA, ABBREVIATION, MASTER CHART ETHICAL COMMITTEE CERTIFICATE PLAGIARISM CERTIFICATE PLAGIARISM DIGITAL RECEIPT	

## **PLAGIARISM CERTIFICATE**

This is to certify that this dissertation work titled “STRAIN USG ELASTOGRAPHY WITH GRAY SCALE AND COLOUR DOPPLER IMAGING OF THYROID NODULES –EFFICACY COMPARED WITH FNAC” of the candidate Dr.A.KARPAGAVALLI with Registration Number 201518002 for the award of M.D RADIODIAGNOSIS. I personally verified the urkund.com website for plagiarism check. I found that the uploaded file containing from introduction to conclusion pages shows a result of 1% plagiarism in this dissertation.

**Guide and supervisor sign with seal**



## INTRODUCTION

Thyroid nodules are very commonly observed on thyroid ultrasonography . Conventional US has been widely used to determine which nodules should be biopsied.

Although conventional US can provide meaningful information in thyroid nodule diagnosis, there has been considerable variation in diagnostic performances.

According to the AmericanThyroidAssociation guidelines, no single US feature or combination of features is adequately sensitive or specific to identify all malignant nodules [9]. For this reason, fine needle aspiration cytology (FNAC) is required for the nodules with suspicious ultrasound signs . However, FNAC has inherent limitations due to indeterminate and nondiagnostic results

On physical examination, a hard or firm nature is associated with thyroid malignancy. But, palpation is very subjective and limited in patients with multinodular goiter or small deep-seated nodules. As a consequence, a significant number of patients eventually receive unnecessary thyroid surgery.

Therefore, improvement and refinement of noninvasive methods to depict malignancy are needed.In this context, US

elastography (USE) has recently been introduced in the clinical workup of thyroid nodules.

USE is a US-based technique to assess the biomechanical properties of tissue in the clinical setting . Meanwhile, US-based elastography can provide an objective evaluation of tissue stiffness. There are two kinds of elastography (strain and shear wave elastography) that are currently used in clinical practice. Among these types of USE, strain USE was the first to be introduced into commercially available systems.

Although many reports have compared conventional US with elastography, in clinical practice, the final decision or diagnosis is usually based on a combination of conventional US and elastography.

## **EMBRYOLOGY**

Thyroid is a butterfly-shaped gland situated in the neck deep to the strap muscle. It develops as an evagination of the primitive foregut at the level of foramen cecum in the base of tongue.

Endodermal cells at the floor of the primitive foregut start to thicken and form the median primordium(bud) of the thyroid, which descends anterior to the structures forming the larynx. An epithelium-lined thyroglossal duct connects the foramen cecum and the median primordium .

The cells from the median primordium become thyroid hormone producing follicular cells. The paired lateral primordium(bud)s develop from the fourth pharyngeal pouches and fuse the median primordium , forming ultimobranchial bodies. The neuroectodermal lateral primordium (ultimobranchial bodies) provide the parafollicular C cells producing calcitonin.

### **ANATOMY:<sup>1,2</sup>**

The bilateral thyroid lobe is connected with each other by the midline isthmus.

A pyramidal lobe can arise from the isthmus in 50% of patients. The pyramidal lobe can extend up to the level of the hyoid bone.

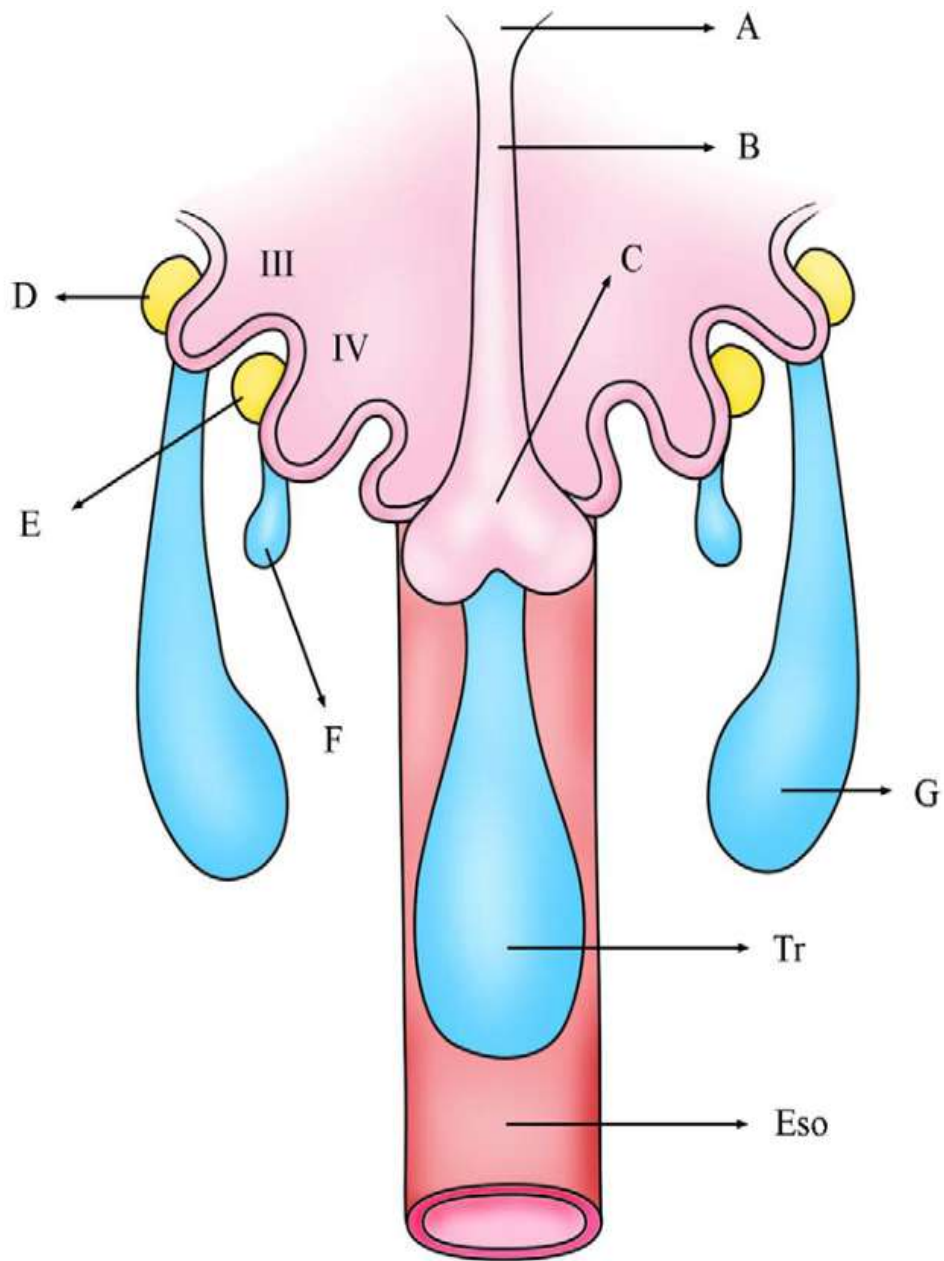


FIG 1. Early development of thyroid gland. The epithelium lined median primordium (c) fuse with the neuroectodermal lateral primordium (ultimobranchial bodies, F), form the thyroid gland. The ultimobranchial bodies provide the parafollicular c cells producing calcitonin.

Notes: III, third branchial pouch; four branchial pouch;A, foramen caecum; B thyroglossal duct; C ,median thyroid;D,inferior parathyroid; E, superior parathyroid ;F,ultimobranchial body; G,thymus; Tr,trachea; Eso,esophagus

### **RELATIONS:**

The thyroid gland is anterior to the prevertebral and paraspinal musculature and deep to the sternothyroid and sternohyoid muscles.

### **ARTERIAL SUPPLY:**

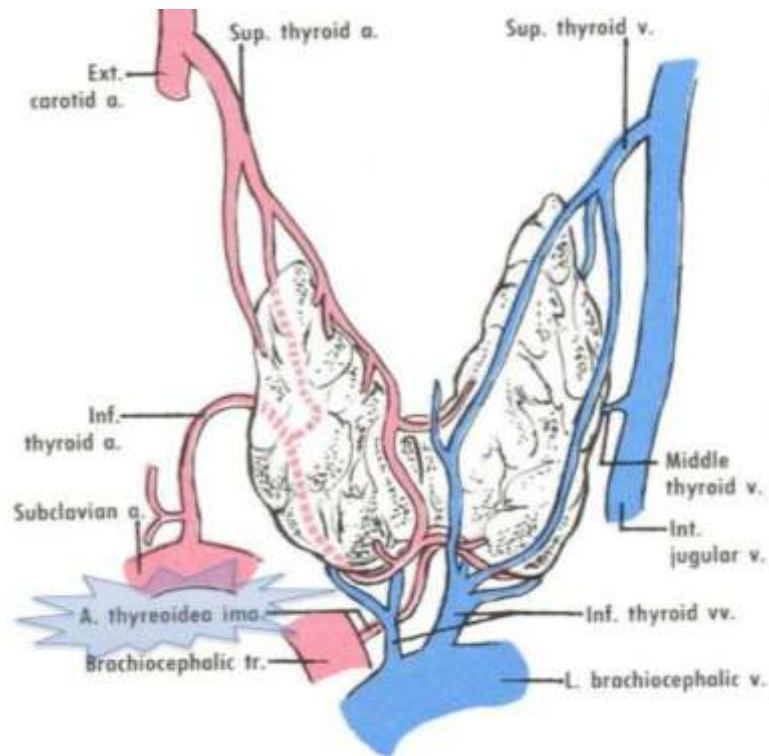
The thyroid gland has a rich blood supply, derived from the superior, inferior, and the small inferior ima arteries that often directly originate from the aortic arch.

### **VENOUS DRAINAGE:**

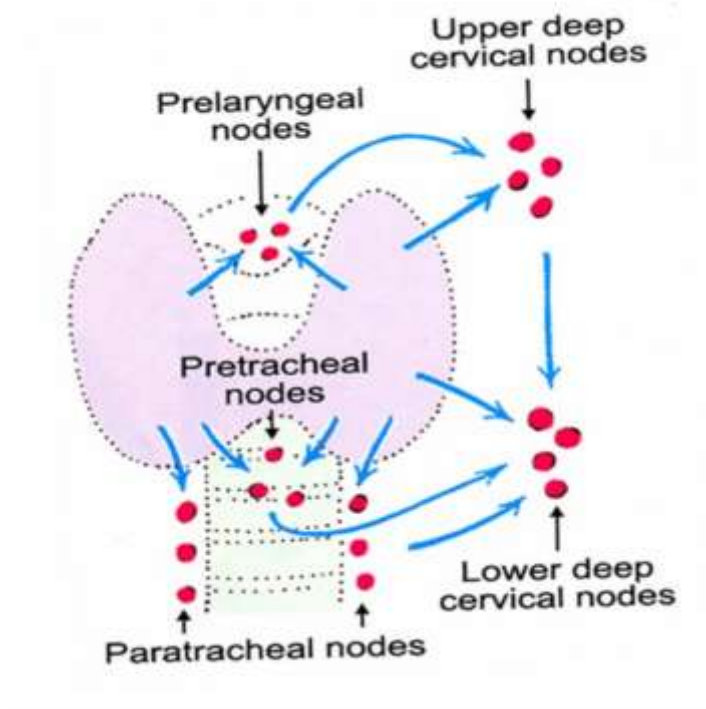
Venous drainage is via multiple surface veins draining into the superior, middle, and inferior thyroid veins.

### **PHYSIOLOGY:**

Thyroid gland produces 2 types of thyroid hormones: thyroxine (T4) and triiodothyronine (T3), which are iodinated derivatives of tyrosine. The primary internal regulation of thyroid activity is through the anterior pituitary gland secreting thyroid-stimulating hormone by way of thyrotropin-releasing hormone released by the hypothalamus. Most circulating thyroid hormones are bound to plasma proteins; the most important and dominant of which is thyroglobulin (Tg).

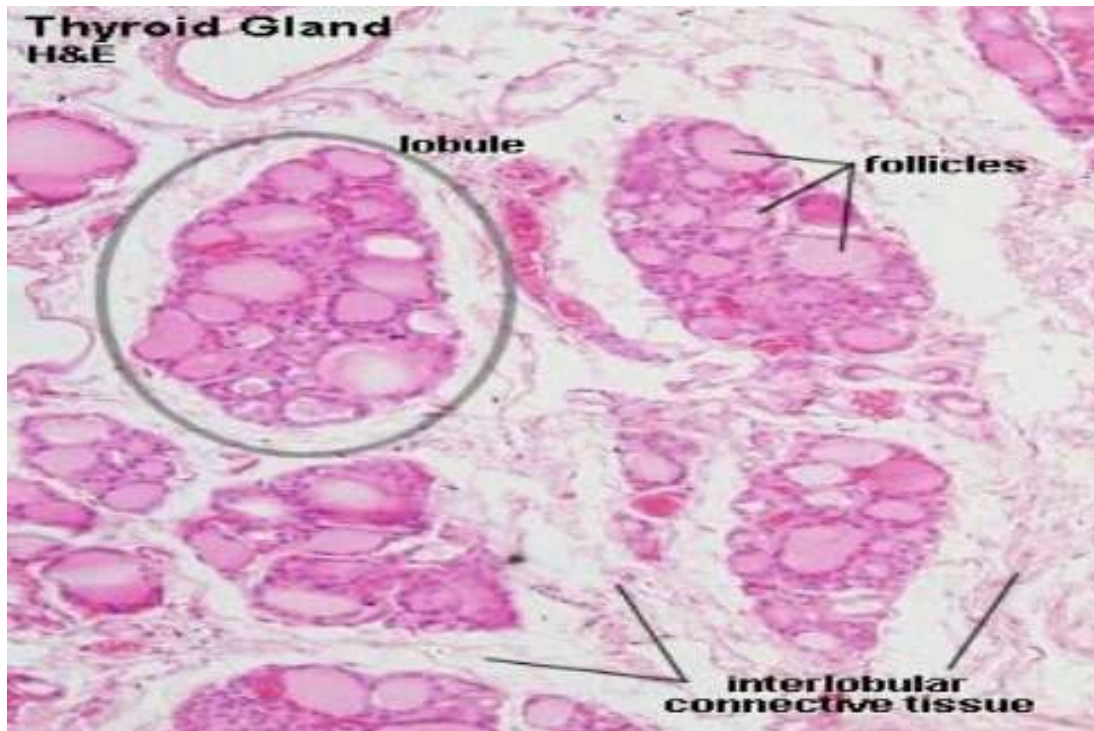


***Fig -2: Thyroid gland is highly vascular . It is supplied by superior and inferior thyroid arteries .It is drained via superior ,middle and inferior thyroid veins .***



***Fig-3: Lymphatic drainage of thyroid***

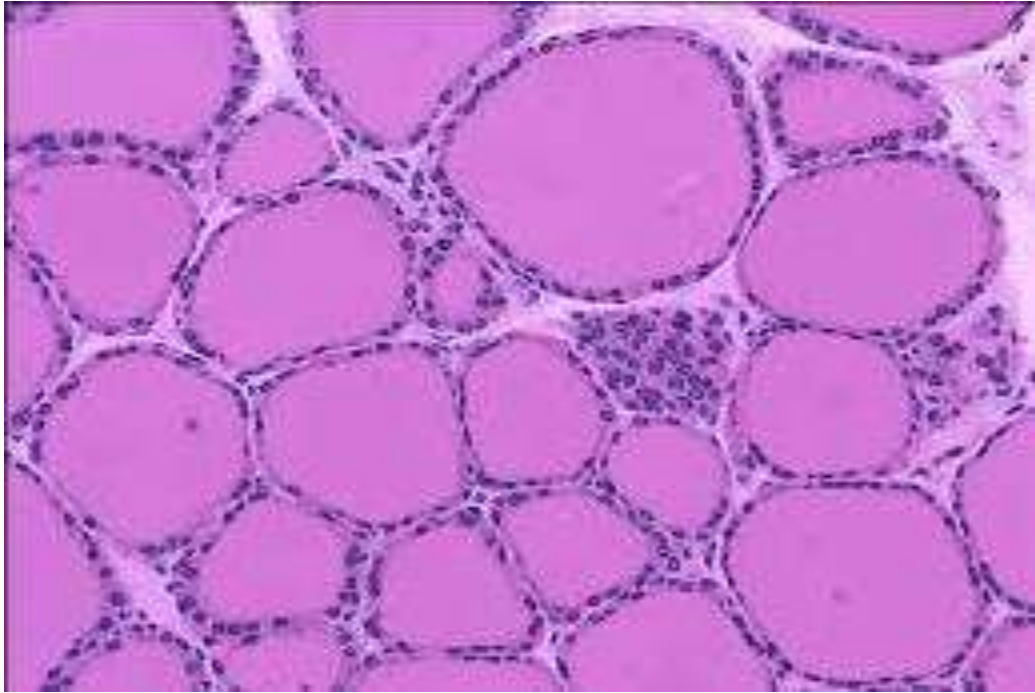
# HISTOLOGY



*FIG.7.Lobule of thyroid*

## DISTINGUISHING FEATURES OF THYROID

- ❖ Follicle is a structural unit.
- ❖ Follicle contains follicular epithelial cells and parafollicular cells.
- ❖ Follicle shows follicular cavity in which contains gel-like colloid.
- ❖ Inter-follicular spaces are filled by reticular connective tissue and blood vessels.

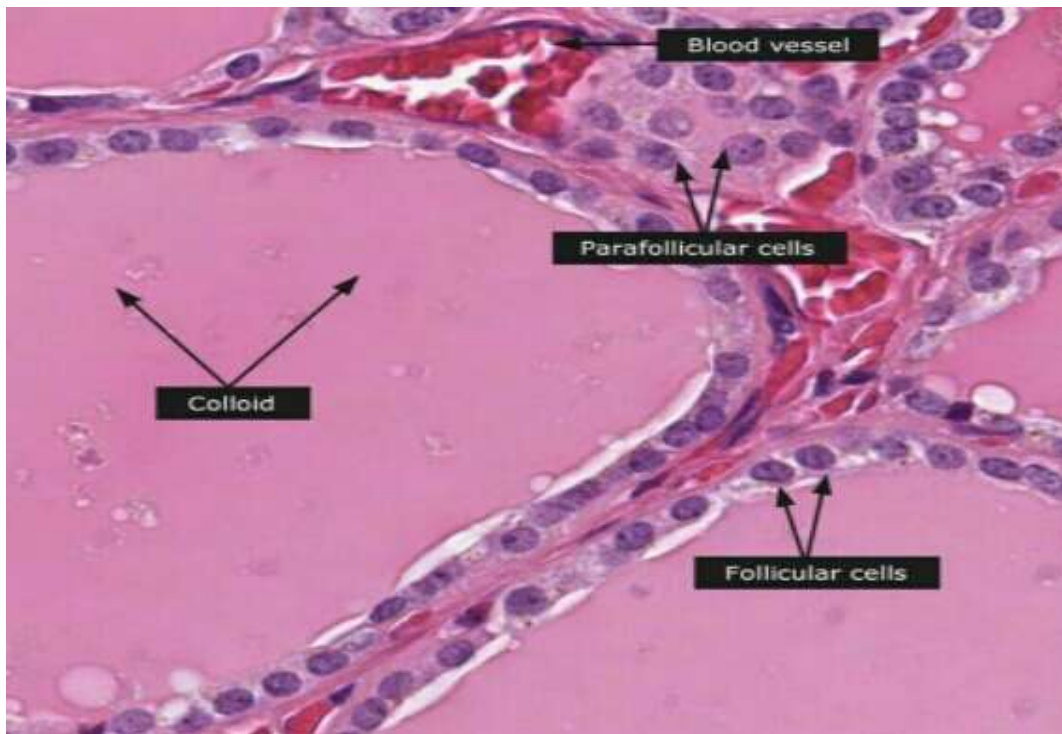


*FIG.8: follicles and Colloid of thyroid gland*

## **COLLOID**

- ❖ Cavity of thyroid follicle is filled with semi –fluid or gel like substance, called thyroid colloid
- ❖ the endocrine secretion of epithelia cells and composed of nucleoproteins, thyroglobulin and proteolytic enzymes.
- ❖ Among the endocrine glands, thyroid is unique because it utilizes an inorganic element iodine for the synthesis of its hormone.



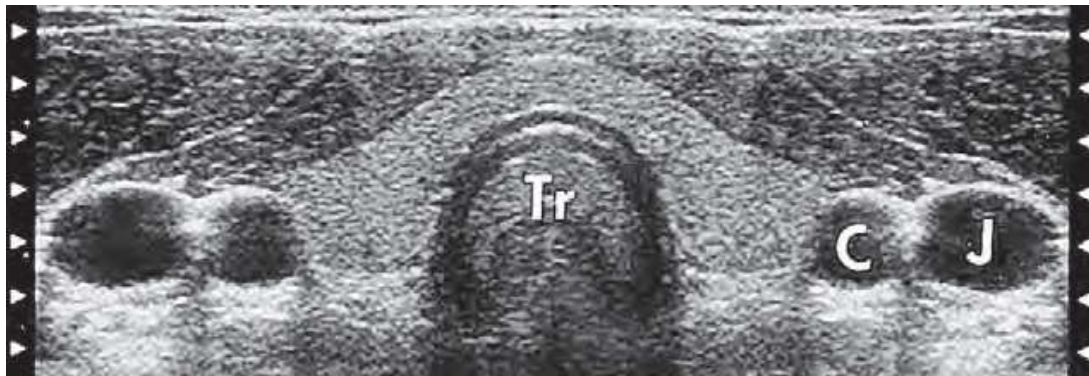


***FIG. 9: Follicular cells of thyroid gland***

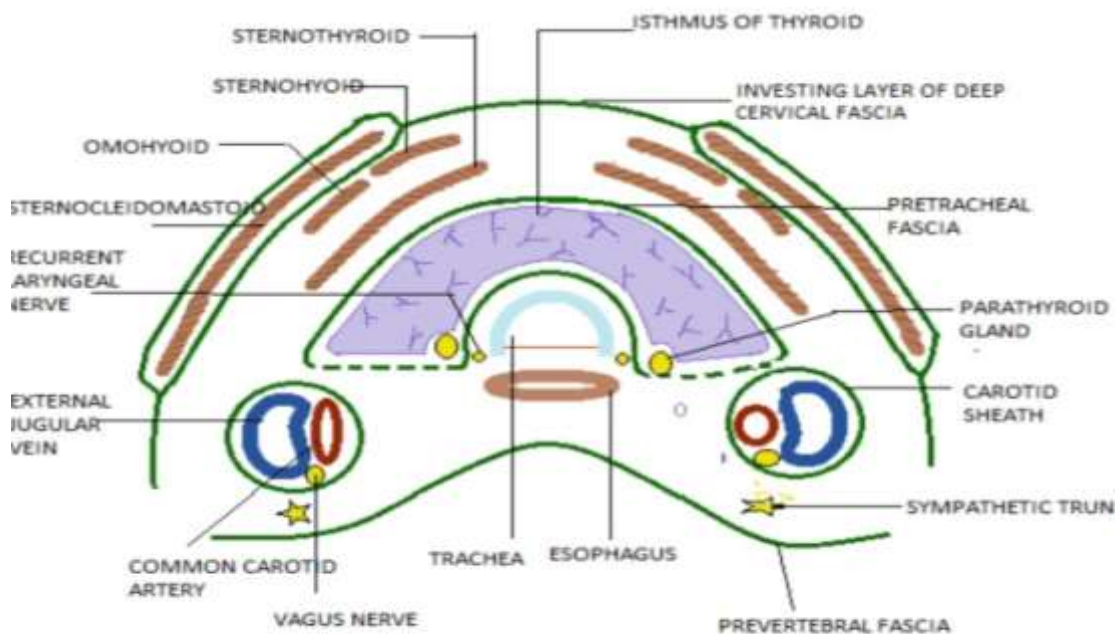
## **FOLLICULAR CELLS**

- ❖ These are cuboidal epithelial cells with their basal ends resting on basement membrane.
- ❖ These cells show the changes in shape depending on state of gland.
- ❖ When the gland is inactive, cells exhibit squamous structure and columnar when hyperactive.
- ❖ The follicular cells show central or basal round nucleus with one or more eccentric nuclei.
- ❖ The apical tips of cells extend microvilli in the cavity.

## CROSS SECTIONAL ANATOMY<sup>3</sup>



*FIG 10, Transverse sonogram made with 7.5-MHz linear array transducer Tr, tracheal air shadow; C, common carotid artery; J, jugular vein.*



*FIG .7, Relations of thyroid gland*

## IMAGING MODALITIES

Imaging modalities for the thyroid gland include cross-sectional imaging techniques, such as ultrasound (US), computed tomography (CT), magnetic resonance imaging (MRI), or positron emission tomography (PET) and nuclear scintigraphy .

Ultrasound is the most frequently performed examination for thyroid lesions . US plays a pivotal role in the diagnosis and management of benign and malignant thyroid nodules.

US allows characterization of thyroid nodules, detection of cervical lymphadenopathy, and guidance for FNA as well as percutaneous intervention, such as ethanol, radio frequency, or laser ablation.

American Thyroid Association recommended in the revised guidelines on 2009 that thyroid US should be performed in patients with palpable or incidental thyroid nodules on CT, MRI, or 18fluorodeoxyglucose (FDG)-PET scan.

### **THYROID USG TECHNIQUE :**

Thyroid US should be performed with high-frequency linear probes ranging from 7 to 12 MHz.

Patients are in supine position with hyperextension of the neck. Scanning field includes the central neck from the lower border of the mandible to the sternal notch and the bilateral cervical nodal chains and the supraclavicular area, to detect accompanying nodal metastasis from thyroid cancer.

The thyroid gland should be evaluated in both transverse and longitudinal scans for each individual lobe and isthmic lobe separately. US features, such as contents, margins, shapes, macro-or

microcalcifications, and echogenicity in combination, are used to assess the malignant potential of each lesion. When a thyroid nodule is detected by US, the size in its maximum dimension should be recorded for the management and follow-up reference. Although malignancy risk becomes 4 times higher in the nodules equal to or 4 cm than that of smaller ones, size is not an independent predictor for malignancy. Smaller nodules could have as much risk of malignancy as larger nodules.

### **COMPUTED TOMOGRAPHY/ MAGNETIC RESONANCE IMAGING:**

CT and MR imaging provide important information about the extension of thyroid disease into adjacent structures, including the trachea and larynx, esophagus, and great vessels.

CT or MRI has a complimentary role with US in preoperative staging and postoperative surveillance of thyroid cancer, and evaluation of mediastinal goiter or ectopic thyroid. CT is also helpful in the evaluation of nodal status of thyroid cancer, especially in US-inaccessible area (retropharyngeal space or mediastinum). MRI is preferred to CT in the evaluation of the extent of thyroid neoplasm due to superior soft-tissue contrast. MR does not require iodinated contrast agent, which is advantageous for patients planned for radioactive iodine (RAI) imaging or therapy.

## **APPROACH TO THYROID LESIONS:<sup>4</sup>**

Thyroid lesions are classified into diffuse and nodular thyroid lesions.

Several thyroid diseases are characterized by diffuse rather than focal involvement.

This usually results in generalized enlargement of the gland (**goiter**) and no palpable nodules. Specific conditions that produce such diffuse enlargement include chronic autoimmune lymphocytic thyroiditis (Hashimoto's thyroiditis), colloid or adenomatous goiter, and Graves' disease.

These conditions are usually diagnosed on the basis of clinical and laboratory findings and occasionally by FNA biopsy. Sonography is seldom indicated. However, high-resolution sonography can be helpful when the underlying diffuse disease causes **asymmetrical** thyroid enlargement, which suggests a mass in the larger lobe. The sonographic finding of generalized parenchymal abnormality may alert the clinician to consider diffuse thyroid disease as the underlying cause. FNA, with sonographic guidance if necessary, can be performed if a nodule is detected.

## **DIFFUSE THYROID LESIONS – SONOGRAPHIC EVALUATION**

Recognition of diffuse thyroid enlargement on sonography can often be facilitated by noting the thickness of the isthmus, normally a thin bridge of tissue measuring only a few millimeters in AP dimension. With diffuse thyroid enlargement, the isthmus may be up to 1 cm or more in thickness.

### **DIFFUSE THYROID DISEASES:<sup>39,40</sup>**

Acute suppurative thyroiditis

Subacute granulomatous thyroiditis

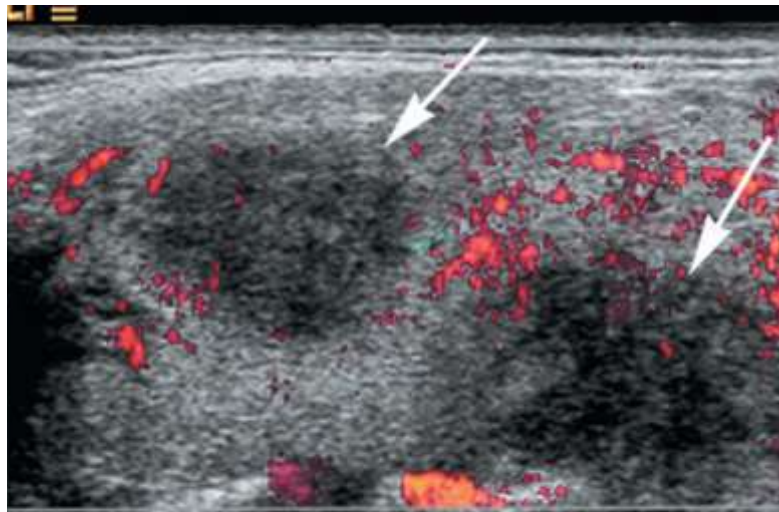
Hashimoto's thyroiditis (chronic lymphocytic thyroiditis)

Adenomatous or colloid goiter

Painless (silent) thyroiditis

**Acute suppurative thyroiditis** is a rare inflammatory disease usually caused by bacterial infection and affecting children. Sonography can be useful in select patients to detect the development of a frank thyroid abscess. The infection usually begins in the perithyroidal soft tissues. On ultrasound images, an abscess is seen as a poorly defined, hypoechoic heterogeneous mass with internal debris, with or without septa and gas. Adjacent inflammatory nodes are often present.

**Subacute granulomatous thyroiditis or de Quervain's disease,**<sup>40,41</sup> is a spontaneously remitting inflammatory disease probably caused by viral infection. Sonographically, the gland may appear enlarged and hypoechoic, with normal or decreased vascularity caused by diffuse edema of the gland, or the process may appear as focal hypoechoic regions. Although usually not necessary, sonography can be used to assess evolution of de Quervain's disease after medical therapy.

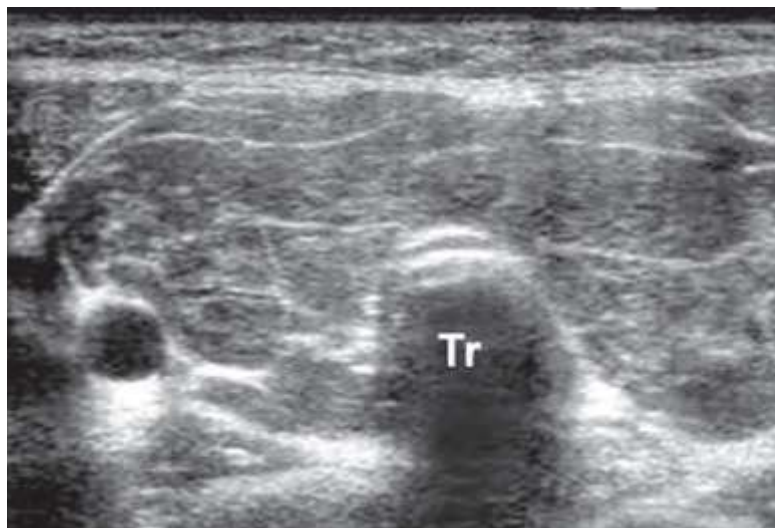

**Fig 11. Focal areas of subacute thyroiditis.** Longitudinal power Doppler image of the thyroid gland shows two poorly defined hypoechoic areas(*arrow*) caused by subacute thyroiditis .

The most common type of thyroiditis is **chronic autoimmune lymphocytic thyroiditis, or Hashimoto's thyroiditis.** It typically occurs as a painless, diffuse enlargement of the thyroid gland in a young or middle-aged woman, often associated with hypothyroidism. The

typical sonographic appearance of Hashimoto's thyroiditis is diffuse, coarsened, parenchymal echotexture, generally more hypoechoic than a normal thyroid.

In most cases the gland is enlarged. Multiple, discrete **hypoechoic micronodules** from 1 to 6 mm in diameter are strongly suggestive of chronic thyroiditis; this appearance has been called **micronodulation**<sup>43</sup>. Micronodulation is a highly sensitive sign of chronic thyroiditis. Micronodules represent lobules of thyroid parenchyma that have been infiltrated by lymphocytes and plasma cells.



*Fig 12. Hashimoto's thyroiditis: coarse septations.*

These lobules are surrounded by multiple linear echogenic fibrous septations. These fibrotic septations may give the parenchyma a “pseudolobulated” appearance. Both benign and malignant thyroid nodules may coexist with chronic lymphocytic thyroiditis, and FNA is often necessary to establish the final diagnosis.. As with other



autoimmune disorders, there is an increased risk of malignancy, with a B-cell malignant lymphoma most often arising within the gland.

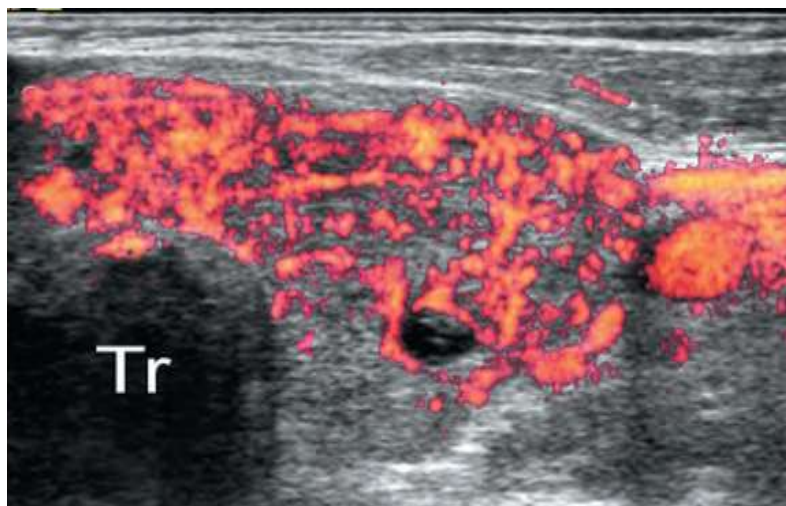
Although the appearance of diffuse parenchymal inhomogeneity and micronodularity is typical of Hashimoto's thyroiditis, other diffuse thyroid diseases, most frequently **multinodular** or **adenomatous goiter**, may have a similar sonographic appearance.<sup>44</sup> Most patients with adenomatous goiter have multiple discrete nodules separated by otherwise normal-appearing thyroid parenchyma. Others have enlargement with rounding of the poles of the gland, diffuse parenchymal inhomogeneity, and no recognizable normal tissue. Adenomatous goiter affects women three times more often than men.

**Graves' disease**<sup>45</sup> is a common diffuse abnormality of the thyroid gland and is usually biochemically characterized by hyperfunction (thyrotoxicosis). The echotexture may be more inhomogeneous than in diffuse goiter, mainly because of numerous large, intraparenchymal vessels. Further, especially in young patients, the parenchyma may be diffusely hypoechoic because of the extensive lymphocytic infiltration or the predominantly cellular content of the parenchyma, which becomes almost devoid of colloid substance. Color Doppler sonography often demonstrates a hypervascular pattern referred to as the **thyroid inferno**. Spectral Doppler will often demonstrate peak systolic velocities exceeding 70 cm/sec, which is the highest velocity found in thyroid diseases. A significant decrease in

flow velocities in the superior and inferior thyroid arteries after medical treatment has been reported.

The rarest type of inflammatory thyroid disease is **invasive fibrous thyroiditis**, also called **Riedel's struma**. This disease primarily affects women and often progresses to complete destruction of the gland.

Some cases may be associated with mediastinal or retroperitoneal fibrosis or sclerosing cholangitis. The primary reason for sonography is to check for extrathyroid extension of the inflammatory process, with encasement of the adjacent vessels. Such information can be particularly useful in surgical planning. Open biopsy is generally required to distinguish this condition from anaplastic thyroid carcinoma. The sonographic findings in these two diseases may be identical.



*Fig 13. Transverse color Doppler image of the left lobe shows increased vascularity, indicating an acute stage of the Graves' disease process; Tr, trachea*

## **NODULAR THYROID LESIONS :**

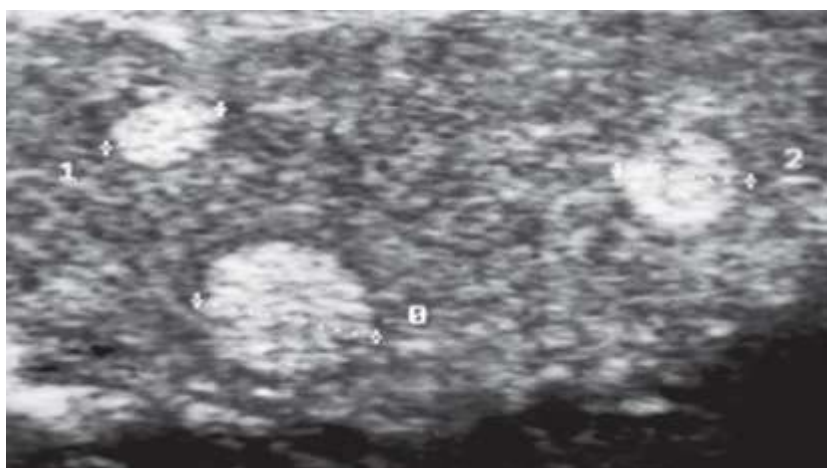
Many thyroid diseases can present clinically with one or more thyroid nodules. Such nodules represent common and controversial clinical problems. women affected more frequently than men. Exposure to ionizing radiation increases the incidence of benign and malignant nodules, with 20% to 30% of a radiationexposed population having palpable thyroid disease. Although nodular thyroid disease is relatively common, thyroid cancer is rare and accounts for less than 1% of all malignant neoplasms. The majority of thyroid nodules are benign. The clinical challenge is to distinguish the few clinically significant malignant nodules from the many benign nodules and thus identify patients who need surgical excision. This task is complicated because nodular disease of the thyroid gland often is clinically occult (<10-15 mm), although it can be readily detected by high-resolution sonography.

## **HYPERPLASIA AND GOITER:**

Approximately 80% of nodular thyroid disease is caused by **hyperplasia**<sup>5,6</sup> of the gland and occurs in up to 5% of any population. Its etiology includes **iodine deficiency** (endemic), **disorders of hormonogenesis** (hereditary familial forms), and **poor utilization of iodine** as a result of medication. When hyperplasia leads to an overall increase in size or volume of the gland, the term **goiter** is used. The peak age of patients with goiter is 35 to 50 years, and women are affected three times more often than men<sup>7</sup>.

Sonographically, most hyperplastic or adenomatous nodules are **isoechoic** compared to normal thyroid tissue, but may become **hyperechoic** because of the numerous interfaces between cells and colloid substance<sup>8</sup>. Less frequently, a hypoechoic spongelike or **honeycomb** pattern is seen. When the nodule is isoechoic or hyperechoic, a thin peripheral **hypoechoic halo** is typically seen, most likely caused by perinodular blood vessels and mild edema or compression of the adjacent normal parenchyma. Perinodular blood vessels are typically detected by color Doppler sonogram<sup>9,10</sup>.

Histologically, the initial stage is cellular hyperplasia of the thyroid acini, followed by micronodule and macronodule formation, often indistinguishable from normal thyroid parenchyma, even at histology. Hyperplastic nodules often undergo liquefactive degeneration with the accumulation of blood, serous fluid, and colloid substance<sup>11</sup>.



*Fig 14. Three hyperechoic nodules, typical of hyperplasia.*

Pathologically, they are often referred to as **hyperplastic**, **adenomatous**, or **colloid** nodules. Many (if not all) cystic thyroid lesions are hyperplastic nodules that have undergone extensive liquefactive degeneration. Pathologically, true epithelial-lined cysts of the thyroid gland are rare.

In the course of this cystic degenerative process, **calcification**, which is often coarse and perinodular, may occur. Hyperplastic nodule function may have decreased, may have remained normal, or may have increased (toxic nodules).

**Hyperfunctioning** (autonomous) nodules often exhibit an abundant perinodular and intranodular vascularity; however, because of the hypervascular pattern shown in most solid thyroid nodules on high-sensitivity Doppler systems, this feature does not allow detection of hyperfunctioning nodules within multinodular goiters with sonography.<sup>9,10</sup>

The degenerative changes of goitrous nodules correspond to their sonographic appearances. Purely anechoic areas are caused by **serous or colloid fluid**. Echogenic fluid or moving fluid-fluid levels correspond to **hemorrhage**.<sup>11</sup> Bright echogenic foci with **comet-tail artifacts** are likely caused by **microcrystals** or aggregates of colloid substance, which may also move slowly, like snowflakes, within the fluid collection.

**Thin, intracystic septations** probably correspond to attenuated strands of thyroid tissue and appear completely avascular on color Doppler ultrasound. These degenerative processes may also lead to the formation of calcifications, which may be either **thin, peripheral shells** (“eggshell”) or **coarse, highly reflective foci** with associated acoustic shadows, scattered throughout the gland.

## **ADENOMA<sup>1</sup>**

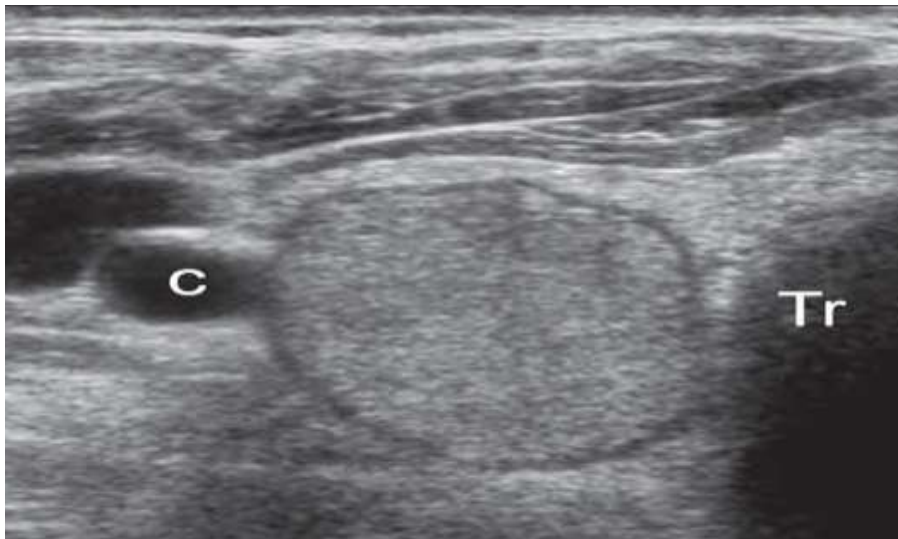Adenomas represent only 5% to 10% of all nodular disease of the thyroid and are seven times more common in women than men. Most result in no thyroid dysfunction.

Most adenomas are solitary, but may also develop as part of a multinodular process. The **benign follicular adenoma** is a true thyroid neoplasm, characterized by compression of adjacent tissues and fibrous encapsulation.

Various subtypes of follicular adenoma include the **fetal adenoma, Hürthle cell adenoma, and embryonal adenoma**, each distinguished according to the type of cell proliferation. The cytologic features of follicular adenomas are generally indistinguishable from those of follicular carcinoma.

Vascular and capsular invasion are the hallmarks of **follicular carcinoma**, identified by histologic rather than cytologic analysis. Therefore, such tumors are usually surgically removed.

Sonographically, adenomas are usually solid masses that may be hyperechoic, isoechoic, or hypoechoic. They often have a thick, smooth peripheral hypoechoic halo resulting from the fibrous capsule and blood vessels, which can be readily seen by color Doppler imaging. Often, vessels pass from the periphery to the central regions of the nodule, sometimes creating a “spoke and wheel” appearance. This vascular pattern is usually seen in both hyperfunctioning and poorly functioning adenomas and thus does not allow the detection of hyperfunctioning lesions.



*Fig 15. homogeneous, hypoechoic, round to oval masses with a surrounding thin halo, the capsule of the adenoma; Tr, tracheal air shadow; C, carotid artery.*

### **CARCINOMA:**

Most **primary thyroid cancers** are of epithelial origin and are derived from follicular or parafollicular cells. Malignant thyroid tumors

of mesenchymal origin are exceedingly rare, as are metastases to the thyroid.

Most thyroid cancers are well differentiated, and papillary carcinoma (including so-called mixed papillary and follicular carcinoma) accounts for 75% to 90% of all cases. In contrast, medullary, follicular, and anaplastic carcinomas (combined) represent only 10% to 25% of all thyroid carcinomas.

### **PAPILLARY CARCINOMA OF THYROID:**

Although it can occur in patients of any age, prevalence of papillary thyroid carcinoma peaks in both the third and the seventh decade of life.<sup>12</sup> Women are affected more often than men. On microscopic examination, the tumor is multicentric within the thyroid gland in at least 20% of cases<sup>14</sup>. Round, laminated calcifications (**psammoma bodies**) in the cytoplasm of papillary cancer cells are seen in approximately 35% of patients. The major route of spread of papillary carcinoma is through the lymphatics to nearby cervical lymph nodes.

In fact, a patient with papillary thyroid cancer may present with enlarged cervical nodes and a palpably normal thyroid gland.<sup>17</sup> Interestingly, the presence of nodal metastasis in the neck generally does not appear to worsen the prognosis for this malignancy. Distant metastases are very rare (2%-3%) and occur mostly in the mediastinum



and lung . After 20 years, the cumulative mortality from papillary thyroid cancer is typically only 4% to 8%.

*Sonographic characteristics of papillary carcinoma are relatively distinctive, as follows ;*

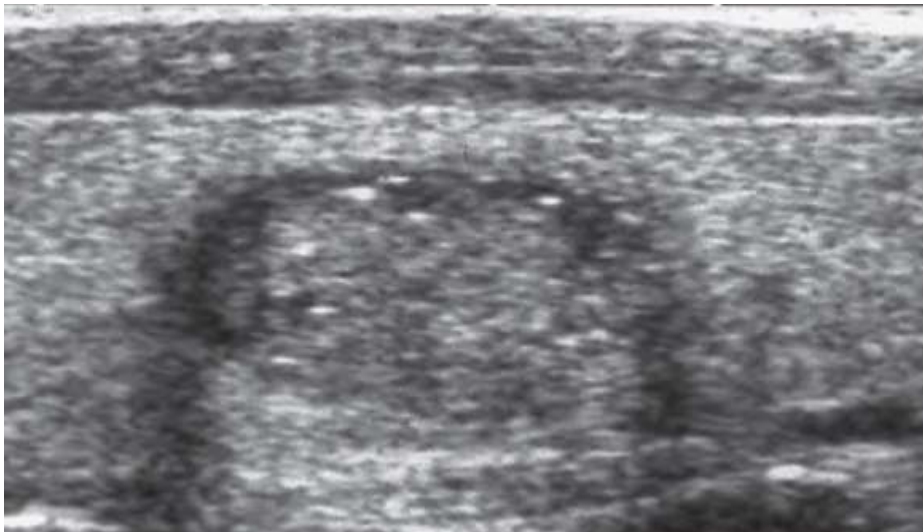
- ❖ Hypoechoogenicity (90% of cases), resulting from closely packed cell content, with minimal colloid substance.
- ❖ Microcalcifications, appearing as tiny, punctate hyperechoic foci, either with or without acoustic shadows . In rare, but usually aggressive cases of papillary carcinomas of childhood, microcalcifications may be the only sonographic sign of the neoplasm, even without evidence of a nodular lesion. .
- ❖ Hypervascularity (90% of cases), with disorganized vascularity, mostly in well-encapsulated forms.
- ❖ Cervical lymph node metastases, which may contain tiny, punctate echogenic foci caused by microcalcifications . These are mainly located in the caudal half of the deep jugular chain.

Occasionally, metastatic nodes may be cystic as a result of extensive degeneration . Cystic nodal metastases show a thickened outer wall, internal nodularity, and septations in most cases, although they may appear purely cystic in younger patients. Cystic lymph node metastases in the neck occur almost exclusively in association with papillary thyroid carcinoma, but occasionally with nasopharyngeal

carcinomas. The overwhelming majority of papillary carcinomas appear as a predominantly solid mass.

**Invasion of adjacent muscles** is infrequently visualized by ultrasound but indicates that the mass is malignant. . A **follicular variant** accounts for 10% of cases of papillary carcinoma and appears similar to a follicular neoplasm on gross pathologic inspection and ultrasound.

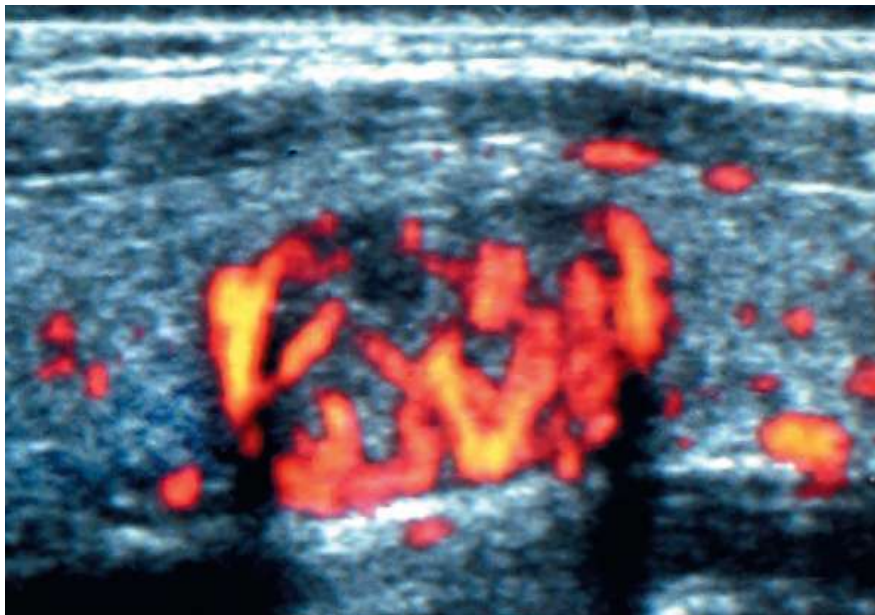**Papillary microcarcinoma** is a rare, nonencapsulated sclerosing tumor measuring 1 cm or less in diameter . Most patient (80%) present with enlarged cervical nodes and a palpably normal thyroid gland.<sup>17</sup> Papillary microcarcinoma can be imaged by high-frequency ultrasound.



*Fig 16.hypoechoic nodules that contain echogenic foci caused by microcalcification;*

## **FOLLICULAR CARCINOMA :<sup>16</sup>**

Follicular carcinoma is the second subtype of well-differentiated thyroid cancer. It accounts for 5% to 15% of all cases of thyroid cancer, affecting women more often than men. The two variants of follicular carcinoma differ greatly in histology and clinical course. The **minimally invasive** follicular carcinomas are encapsulated, and only the histologic demonstration of focal invasion of capsular blood vessels of the fibrous capsule itself permits differentiation from follicular adenoma.



*Fig 17. Power Doppler image shows that nodule is hypervascular and has flow in the center and at the periphery.*

The widely invasive follicular carcinomas are not well encapsulated, and invasion of the vessels and the adjacent thyroid is more easily demonstrated. Both variants of follicular carcinoma tend to spread through the bloodstream rather than the lymphatics, and distant

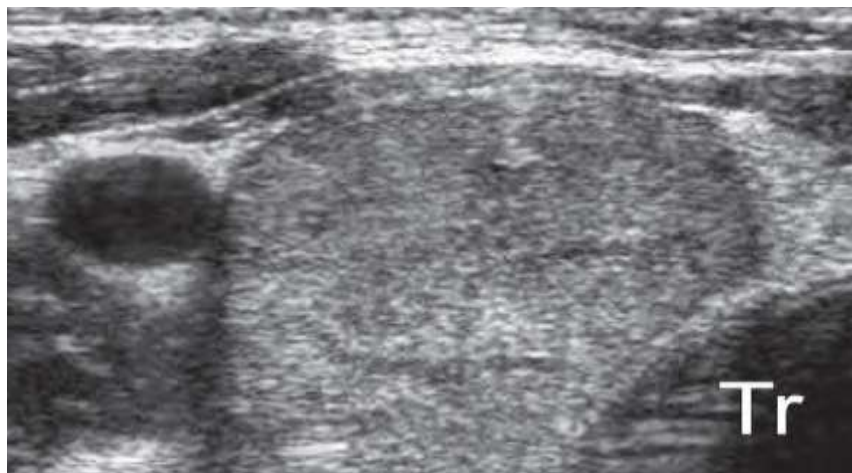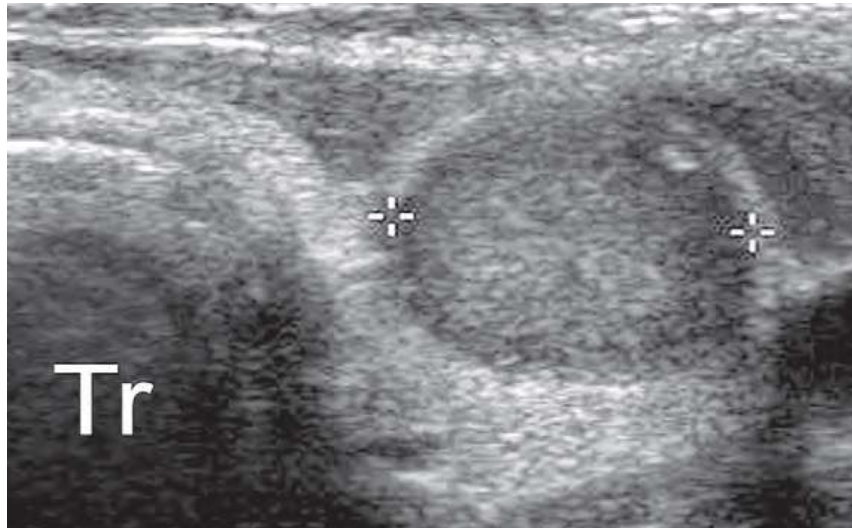
metastases to bone, lung, brain, and liver are more likely than metastases to cervical lymph nodes.

No unique sonographic features allow differentiation of follicular carcinoma from adenoma, which is not surprising, given the cytologic and histologic similarities of these two tumors. Similarly, fine-needle aspiration is not reliable in differentiating benign from malignant follicular neoplasms because the pathologic diagnosis is not based on cellular appearance but rather on capsular and vascular invasion. Therefore, most follicular nodules must be surgically removed for accurate pathologic diagnosis. Features that suggest follicular carcinoma are rarely seen but include irregular tumor margins, a thick irregular halo, and a tortuous or chaotic arrangement of internal blood vessels on color Doppler imaging.

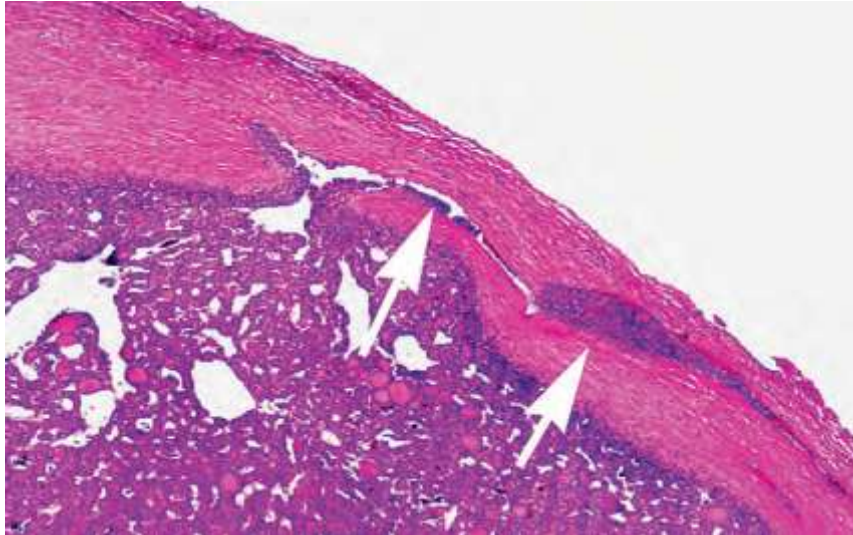
## **FOLLICULAR THYROID CARCINOMA**

### **SONOGRAPHIC FEATURES:**

- ❖ Irregular tumor margins
- ❖ Thick, irregular halo
- ❖ Tortuous or chaotic arrangement of internal blood Vessel



*Fig 18 A, Left lobe, and 18 B, right lobe, of the thyroid show round, homogeneous hypoechoic masses that appear identical except for size differences on transverse images; Tr, tracheal air shadow. The smaller mass was malignant and the larger mass benign*



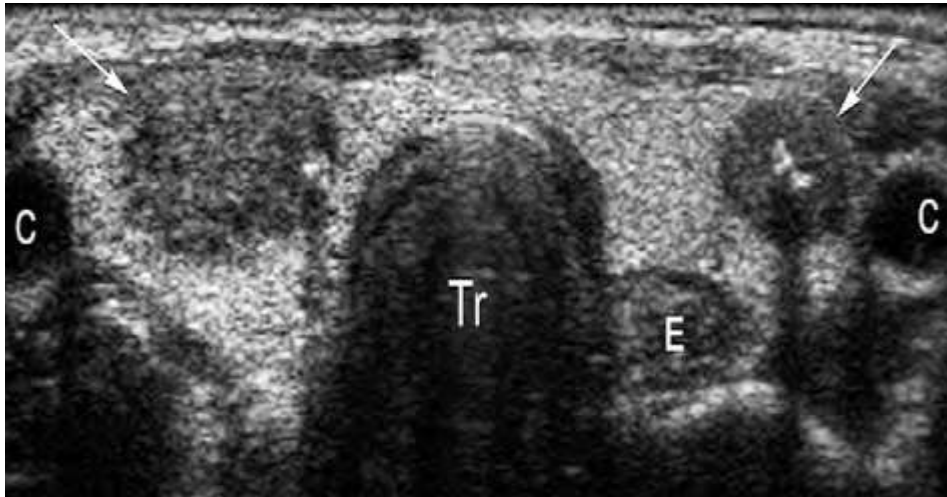
*Fig 19. Microscopic appearance of the capsule shows invasion of the follicular cells into the capsule (arrows). This is one of the microscopic features that allows a pathologic diagnosis of malignancy but is not visible by ultrasound .*

## **MEDULLARY CARCINOMA:**

Medullary carcinoma accounts for about 5% of all malignant thyroid diseases. It is derived from the parafollicular cells, or C cells, and typically secretes the hormone **calcitonin**, which can be a useful serum marker. This cancer is frequently familial(20%) and is an essential component of the **multiple endocrine neoplasia (MEN) type II syndromes**. The disease is multicentric and/or bilateral in about 90% of the familial cases . There is a high incidence of metastatic involvement of lymph nodes. The prognosis for patients with medullary cancer is somewhat worse than for follicular cancer.

The sonographic appearance of medullary carcinoma is usually similar to that of papillary carcinoma and is seen most often as a hypoechoic solid mass. Calcifications are often seen (histologically caused by calcified nests of amyloid substance) and tend to be more

coarse than the calcifications of typical papillary carcinoma. Calcifications can be seen not only in the primary tumor but also in lymph node metastases and even in hepatic metastases.



*Fig 20. Transverse dual image in patient with multiple endocrine neoplasia type II (MEN II) shows bilateral hypoechoic masses (arrows) that contain areas of coarse calcification; C, carotid arteries; Tr, trachea; E, esophagus.*

## **ANAPLASTIC THYROID CARCINOMA.**<sup>15</sup>

Anaplastic thyroid carcinoma is typically a disease of elderly persons; it represents one of the most lethal of solid tumors. Although it accounts for less than 2% of all thyroid cancers, it carries the worst prognosis, with a 5-year mortality rate of more than 95%. The tumor typically presents as a rapidly enlarging mass extending beyond the gland and invading adjacent structures. It is often inoperable at presentation. Anaplastic carcinomas may often be associated with papillary or follicular carcinomas, presumably representing a dedifferentiation of the neoplasm. They tend not to spread via the

lymphatics but instead are prone to aggressive local invasion of muscles and vessels.

Sonographically, anaplastic thyroid carcinomas are usually hypoechoic and often encase or invade bloodvessels and neck muscles . Often these tumors cannot be adequately examined by ultrasound because of their large size. Instead, computed tomography (CT) or magnetic resonance imaging (MRI) of the neck usually demonstrates the extent of disease more accurately.

## **ANAPLASTIC THYROID CARCINOMA:**

### **SONOGRAPHIC FEATURES**

- ❖ Large, hypoechoic mass
- ❖ Encase or invade blood vessels
- ❖ Invade neck muscles

## **LYMPHOMA<sup>18</sup>**

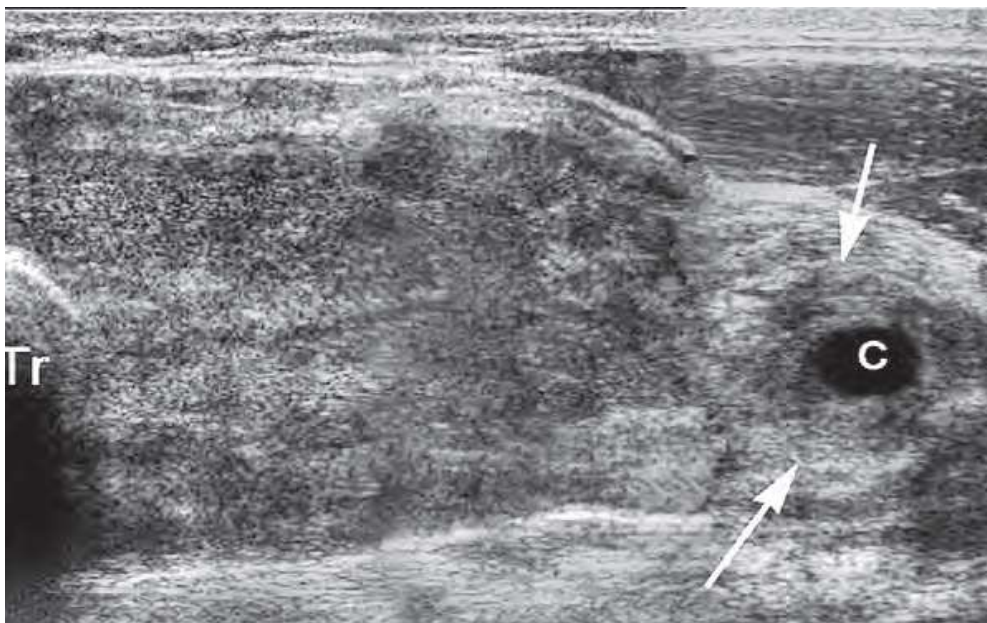
Lymphoma accounts for approximately 4% of all thyroid malignancies. It is mostly of the non-Hodgkin's type and usually affects older women. The typical clinical sign is

a rapidly growing mass that may cause symptoms of obstruction such as dyspnea and dysphagia. In 70% to 80% of patients, lymphoma arises from a preexisting chronic lymphocytic thyroiditis (Hashimoto's thyroiditis) with subclinical or overt hypothyroidism. The prognosis is highly variable and depends on the stage of the disease. Five-year



survival ranges from almost 90% in early-stage cases to less than 5% in advanced, disseminated disease.

Sonographically, lymphoma of the thyroid appears as an extremely hypoechoic and lobulated mass. Large areas of cystic necrosis may occur, as well as encasement of adjacent neck vessels. On color Doppler imaging, both nodular and diffuse thyroid lymphomas may appear mostly hypovascular or may show blood, vessels with chaotic distribution and AV shunts. The adjacent thyroid parenchyma may be heterogeneous as a result of associated chronic thyroiditis.



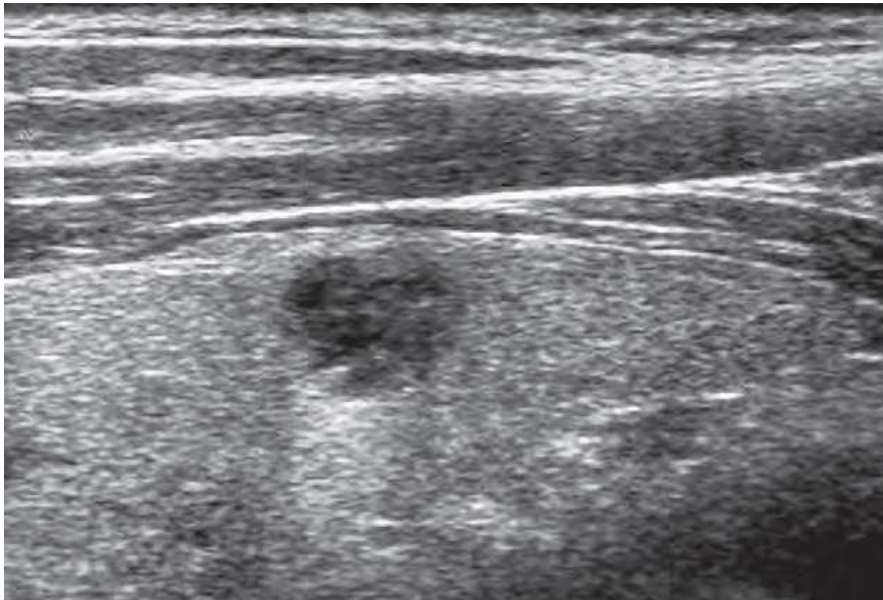
*Fig21. Transverse image of left lobe of the thyroid shows diffuse mass enlarging the lobe and extending into the soft tissues (arrows) surrounding the common carotid artery (c); Tr, tracheal air shadow.*

### **THYROID METASTASES:**

Metastases to the thyroid are infrequent, occurring late in the course of neoplastic diseases as the result of hematogenous spread or

less frequently a lymphatic route. Metastases usually are from **melanoma** (39%), **breast** (21%), and **renal cell** (10%) carcinoma.

Metastases may appear as solitary, well-circumscribed nodules or as diffuse involvement of the gland. On sonography, thyroid tumors are solid, homogeneously hypoechoic masses, without calcifications.



*Fig 22. images show a 1-cm solid mass representing proven thyroid metastasis from renal cell carcinoma.*

## **NODULAR THYROID DISEASE:**

### **SONOGRAPHIC EVALUATION**

- ❖ Determine location of palpable neck mass (e.g., thyroid or extrathyroid).
- ❖ Characterize benign versus malignant nodule features.
- ❖ Detect occult nodule in patient with history of head and neck irradiation or MEN II syndrome.
- ❖ Determine extent of known thyroid malignancy.
- ❖ Detect residual, recurrent, or metastatic carcinoma.
- ❖ Guide fine-needle aspiration of thyroid nodule or cervical lymph nodes.

*The fundamental anatomic features of a thyroid nodule on high-resolution sonography are as follows:*

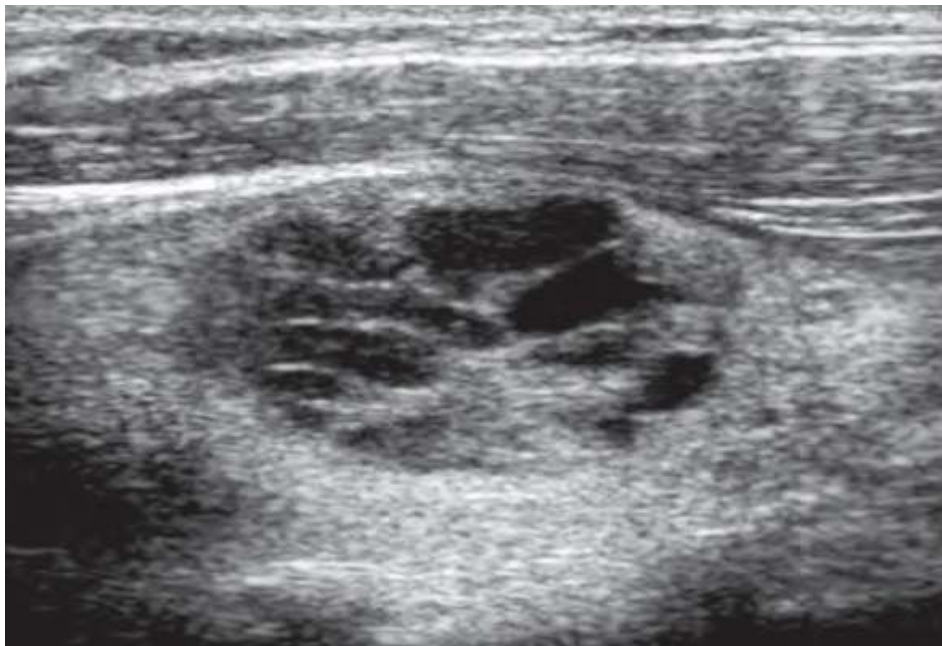- ❖ Internal consistency (solid, mixed solid and cystic, or purely cystic)
- ❖ Echogenicity relative to adjacent thyroid parenchyma
- ❖ Margin
- ❖ Shape
- ❖ Presence and pattern of calcification
- ❖ Peripheral sonolucent halo

- ❖ Presence and distribution of blood flow signals

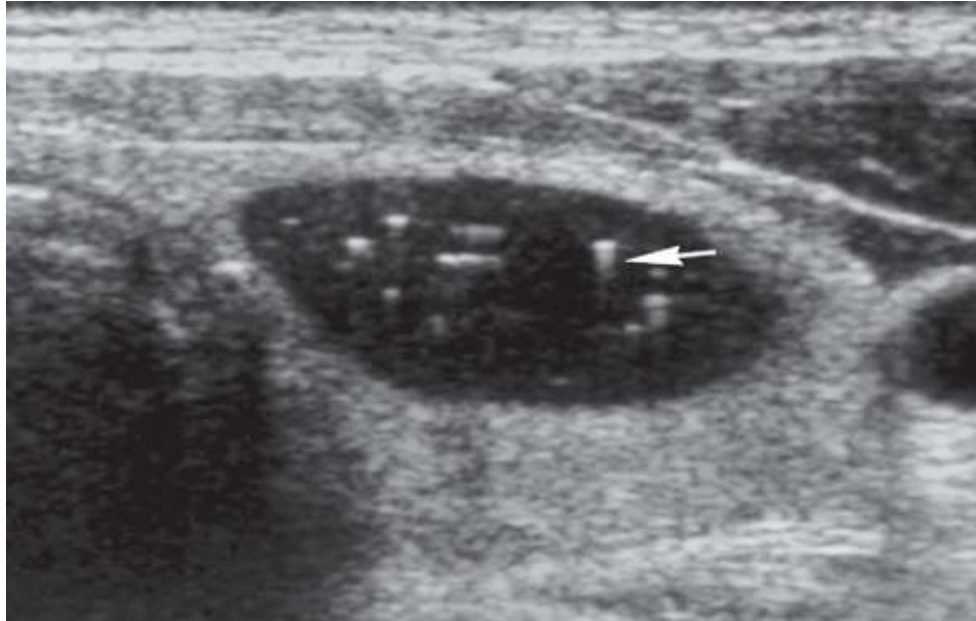
### **INTERNAL CONTENTS :**

Usually, approximately 70% of thyroid nodules are solid, whereas the remaining 30% exhibit various amounts of cystic change. A nodule that has a significant cystic component is usually a benign adenomatous (colloid) nodule that has undergone degeneration or hemorrhage.

All cystic thyroid lesions seen with high-resolution ultrasound demonstrate some wall irregularity and internal solid elements or debris caused by nodule degeneration.



*Fig 23. honeycomb-like or cystic changes, with nodules showing larger cystic spaces indicate a very high probability of a benign process*



***Fig 24. Typical appearance of colloid cysts. Nodules that are mostly cystic are considered benign. These nodules have tiny echogenic foci that are thought to be microcrystals. A few of these foci are associated with comet-tail artifacts .***

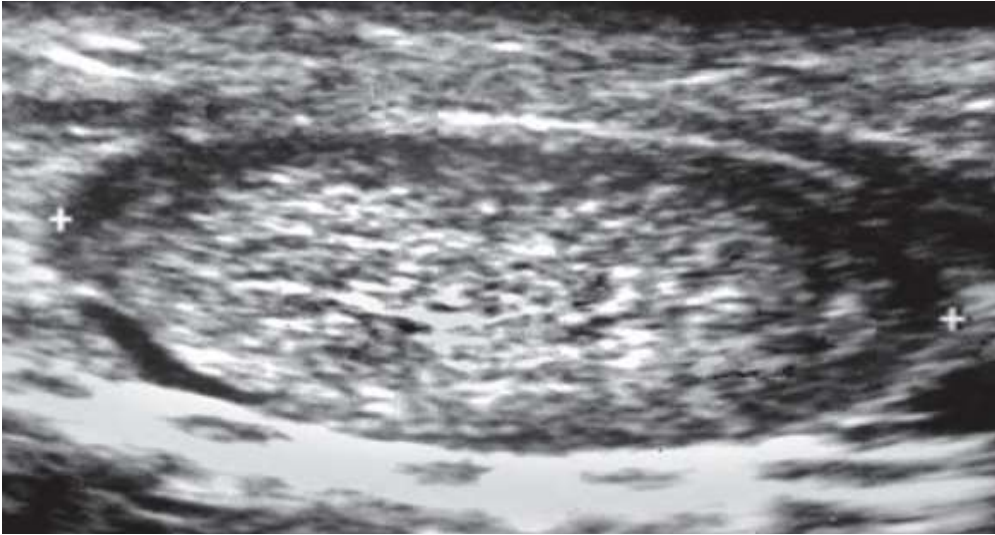
Comet-tail artifacts are frequently encountered in cystic thyroid nodules and are likely related to the presence of microcrystals . These comet-tail artifacts can be located in the cyst walls and internal septations or in the cyst fluid .

When a more densely echogenic fluid is gravitationally layered in the posterior portion of a cystic cavity, the likelihood of hemorrhagic debris is very high. Frequently, patients with hemorrhagic debris present clinically with a rapidly growing, often tender neck mass. The spongiform appearance of thyroid nodules, related to the presence of tiny colloid changes, is an extremely uncommon finding in malignant nodules, particularly when it is associated with other findings such as well-defined margins and

isoechogenicity. This pattern is highly predictive of a benign nodule . Papillary carcinomas may rarely exhibit varying amounts of cystic change and appear almost indistinguishable from benign cystic nodules. In cystic papillary carcinomas, the frequent sonographic detection of a solid elements or projections ( $\geq 1$  cm with blood flow signals and/or microcalcifications) into the lumen can lead to suspicion of malignancy . Cervical metastatic lymph nodes from either a solid or a cystic primary papillary cancer may also demonstrate a cystic pattern; this is likely pathognomonic of malignant adenopathy.

### **SHAPE:**

A taller-than-wide shape, in which the AP diameter is equal or less than its transverse diameter on a transverse or longitudinal plane, is specific for differentiating malignant nodules from benign nodules, because malignant neoplasms (taller than wide) grow across normal tissue planes, whereas benign nodules grow parallel to normal tissue planes.

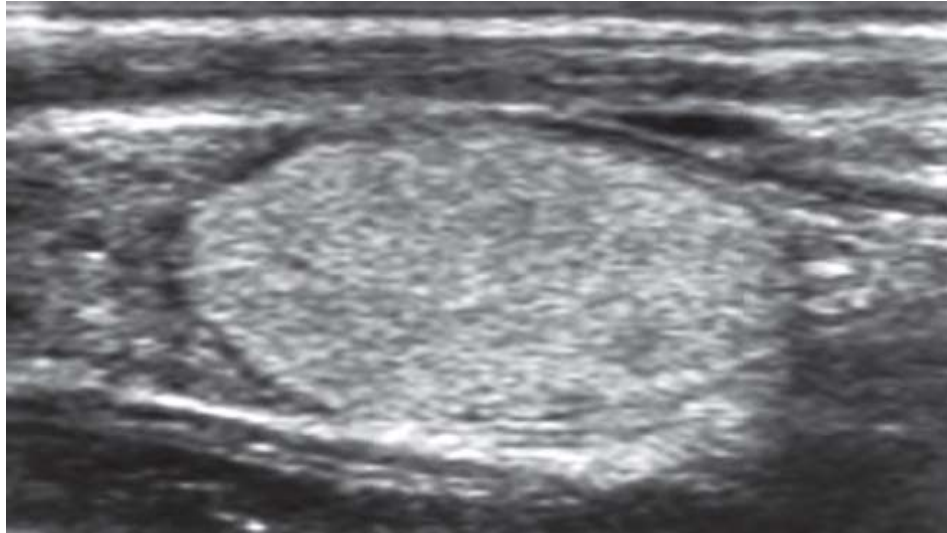


***Fig 25. Hyperplastic nodule.***

Oval homogeneous nodule – follicular adenoma.

### **ECHOGENICITY :**

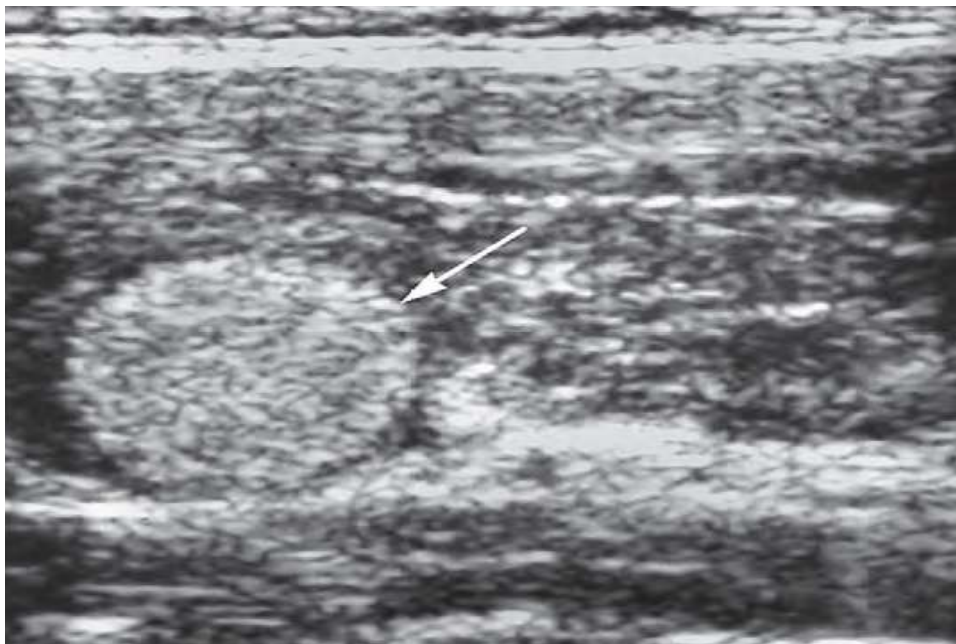
Thyroid cancers are usually hypoechoic relative to the adjacent normal thyroid parenchyma . Many benign thyroid nodules are also hypoechoic. Marked hypoechoogenicity is highly specific for diagnosing malignant nodules, whereas the hypoechoogenicity often found in benign lesions is usually less marked. A predominantly hyperechoic nodule, although relatively uncommon, is more likely to be benign. The isoechoic nodule, visible because of a peripheral sonolucent rim that separates it from the adjacent normal parenchyma, has an intermediate to low risk of malignancy. Isoechoogenicity has low sensitivity but high specificity and positive predictive value for the diagnosis of benign nodules .



*Fig 26. Solitary hyperechoic nodule, which was benign on fine-needle aspiration biopsy*

**HALO :**

A peripheral sonolucent halo that completely or incompletely surrounds a hypoechogenicity often found in benign lesions is usually less marked. A predominantly hyperechoic nodule, although relatively uncommon, is more likely to be benign.



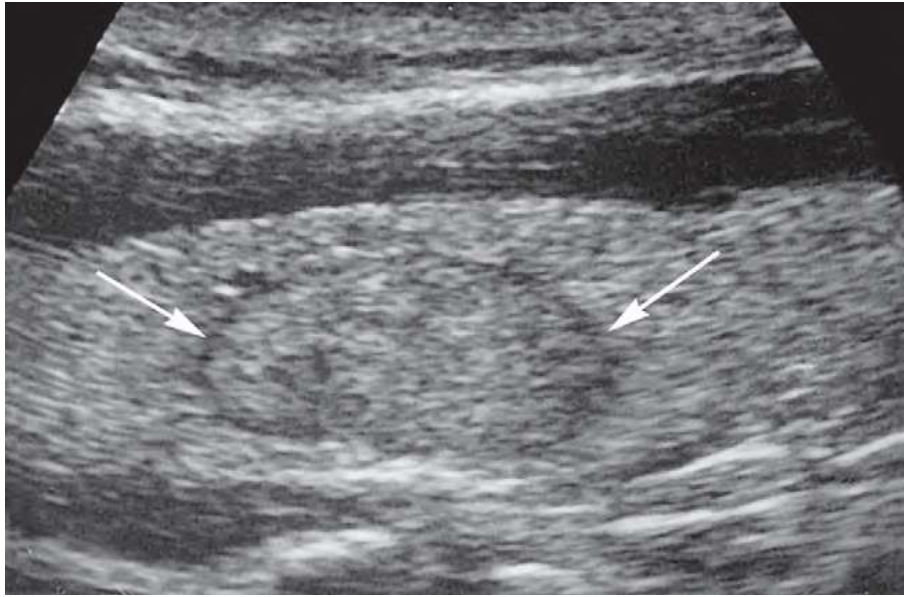
*Fig 27. round, hyperechoic homogeneous mass (arrow with peripheral halo) in patient with Hashimoto's thyroiditis.*



The isoechoic nodule, visible because of a peripheral sonolucent rim that separates it from the adjacent normal parenchyma, has an intermediate to low risk of malignancy. Isoechogenicity has low sensitivity but high specificity and positive predictive value for the diagnosis of benign nodules.

Histologically, it is thought to represent the capsule of the nodule, but hyperplastic nodules that have no capsule often have this sonographic feature. The hypothesis that it represents compressed normal thyroid parenchyma seems acceptable, especially for rapidly growing thyroid cancers, which often have thick, irregular, and incomplete halos that are hypovascular or avascular on color Doppler scans.

**Color and power Doppler imaging** demonstrates that the thin, complete peripheral halo, which is strongly suggestive of benign nodules, represents blood vessels coursing around the periphery of the lesion, the “basket pattern.”



*Fig 28 .Isoechoic nodule with surrounding thin rim of halo( arrows)*

### **MARGIN:**

Benign thyroid nodules tend to have sharp, well-defined margins, whereas malignant lesions tend to have irregular, spiculated, or poorly defined margins. For any given nodule, however, the appearance of the outer margin cannot reliably predict the histologic features because many exceptions to these general trends have been identified, even if the association of spiculated margins with malignant nodules has recently been demonstrated as highly specific.

### **CALCIFICATION:**

Calcification can be detected in about 10% to 15% of all thyroid nodules, but the location and pattern of the calcification have a more predictive value in distinguishing benign from malignant lesions. Peripheral shell (eggshell) calcification, although

rarely present, has traditionally been considered a characteristic of a benign nodule . Thickened and interrupted peripheral calcifications, particularly if associated with hypoechoic halo, have very high sensitivity for the diagnosis of malignant nature. Scattered echogenic foci of calcification with or without associated acoustic shadows are more common. When these calcifications are large and coarse (usually related to fibrosis and degeneration), the nodule is more likely to be a benign nodule, with long disease duration. When the calcifications are fine and punctate, however, malignancy is more likely. Pathologically, these fine calcifications may be caused by psammoma bodies, typically seen in papillary cancers . Medullary thyroid carcinomas often exhibit bright echogenic foci either within the primary tumor or within metastatically involved cervical lymph nodes. The larger echogenic foci are usually associated with acoustic shadowing. Pathologically, these densities are caused by reactive fibrosis and calcification around amyloid deposits, which are characteristic of medullary carcinoma. In the appropriate clinical setting (e.g., MEN II syndrome, increased serum calcitonin level), the finding of echogenic foci within a hypoechoic thyroid nodule or a cervical node can be highly suggestive of medullary carcinoma. There is a strong association between sonographically detected thyroid calcifications and thyroid malignancy, particularly in young patients or those with

a solitary thyroid nodule. The presence of calcifications within a solitary nodule increases the incidence of malignancy. Various sonographic features seen in thyroid nodules, microcalcifications show the highest accuracy (76%), specificity (93%), and positive predictive value (70%) for malignancy as a single sign. However, sensitivity is low (36%) and insufficient to be reliable for detection of malignancy.

### **DOPPLER FLOW PATTERN.**

Most hyperplastic nodules are hypovascular lesions and are less vascular than normal thyroid parenchyma.

On the contrary, most well-differentiated thyroid carcinomas are generally hypervascular, with irregular tortuous vessels and AV shunting .

Poorly differentiated and anaplastic carcinomas are often hypovascular because of the extensive necrosis associated with their rapid growth.

Quantitative analysis of flow velocities is not accurate in differentiating benign from malignant nodules, so the only Doppler feature that may be useful is the distribution of vessels.

The two main categories of vessel distribution are nodules with peripheral vascularity and nodules with internal vascularity (with or without a peripheral component).

80% to 95% of hyperplastic, goitrous, and adenomatous nodules display peripheral vascularity.

70% to 90% of thyroid malignancies display internal vascularity, with or without a peripheral component.

Gray-scale and color Doppler ultrasound findings become highly predictive for malignancy only when multiple signs are simultaneously present in a nodule.

The combination of absent halo sign plus microcalcifications plus intranodular flow pattern achieved a 97.2% specificity for the diagnosis of thyroid malignancy.

In a recent report the presence of at least one malignant sonographic finding (taller-than-wide shape, spiculated margin, marked hypoechogenicity, microcalcification and macrocalcification) had sensitivity of 83.3%, specificity of 74.0%, and diagnostic accuracy of 78.0%.

The presence of other findings (e.g., rim calcification) showed no statistical significance in the differentiation of a malignant nodule from a benign nodule.

Following table shows reliability of sonographic features in differentiation of benign from malignant thyroid nodules.

FEATURE	<i>Pathologic Diagnosis</i>	
	BENIGN	MALIGNANT
<i>Shape</i>		
Wider than tall	+++	++
Taller than wide	+	++++
<i>Internal Contents</i>		
Purely cystic content	++++	+
Cystic with thin septa	++++	+
Mixed solid and cystic	+++	++
Comet-tail artifact	+++	+
<i>Echogenicity</i>		
Hyperechoic	++++	+
Isoechoic	+++	++
Hypoechoic	+++	+++
Markedly hypoechoic	+	++++
<i>Halo</i>		
Thin halo	++++	++
Thick, incomplete halo	+	+++
Absent	+	+++
<i>Margin</i>		
Well defined	+++	++
Poorly defined	++	+++
Spiculated	+	++++
<i>Calcification</i>		
Eggshell calcification	+++	++
Coarse calcification	+++	+
Microcalcification	++	++++
<i>Doppler</i>		
Peripheral flow pattern	+++	++
Internal flow pattern	++	+++
<i>Sonoelastography</i>		
Patterns 1 and 2	++++	+
Patterns 3 and 4	+	+++

### FNAC :

It is recognized that FNAC is the most effective method for diagnosing malignancy in a thyroid nodule. FNAC has had a substantial impact on the management of thyroid nodules because it provides more direct information than any other available

diagnostic technique. It is safe, inexpensive, and results in better selection of patients for surgery.

Fine-needle thyroid aspirates are often classified cytopathologically into the following four categories:

- 1) Negative (no malignant cells)
- 2) Positive for malignancy
- 3) Suggestive of malignancy
- 4) Nondiagnostic

If a nodule is classified in either of the first two categories, the results are highly sensitive and specific. The major limitation of the technique is the lack of specificity in the third group, whose results are suggestive of malignancy. In these cases, surgical excision is required for diagnosis. In addition, up to 20% of aspirates may be nondiagnostic, approximately half of which result from inadequate cell sampling of cystic lesions.

In these cases, repeat FNAC under sonographic guidance can be performed for selective sampling of the solid elements of the mass. In the literature, FNAC of thyroid nodules has a sensitivity range of 65% to 98% and specificity of 72% to 100%.

## **THYROID SONOELASTOGRAPHY :**

A new sonographic technique called **sonoelastography** (or **elastosonography**) has been applied to the study of thyroid nodules, following the results achieved for breast nodules.

Sonoelastography provides information on tissue elasticity, based on the pathologic processes such as cancer alter the physical characteristics of the involved tissue.

Sonoelastographic measurements are performed during the ultrasound examination, using the same ultrasound machine and the same transducer . The ultrasound elastogram is displayed over the typical B-mode gray-scale ultrasound scan in a color scale and classified by using the elasticity score<sup>33,34</sup> .To minimize interobserver and intraobserver variability, the freehand compression applied on the neck region is standardized by real-time measurement displayed to maintain an intermediate level optimal for **elastographic evaluation**. USE is used to assess the biomechanical properties of tissue in the clinical setting. Among different types of USE, strain USE was the first to be introduced into commercially available systems. It is based upon the principle that, under compression, the softer parts of tissues deform easier than the harder parts<sup>47</sup>. The concept of USE was firstly conceived and realized in 1991 by Ophir et al<sup>46</sup>. and gradually developed into a robust US examination method. It has recently gained great interest and attention and has found rapid diffusion in various diagnostic



applications, including the thyroid nodules<sup>48</sup>. As shown by a number of studies, USE of thyroid nodules seems promising in differentiating benign from malignant nodules<sup>49,50,51</sup>. The American Thyroid Association guidelines in 2009 stated that USE is an emerging and promising technique that requires additional validation with prospective studies .

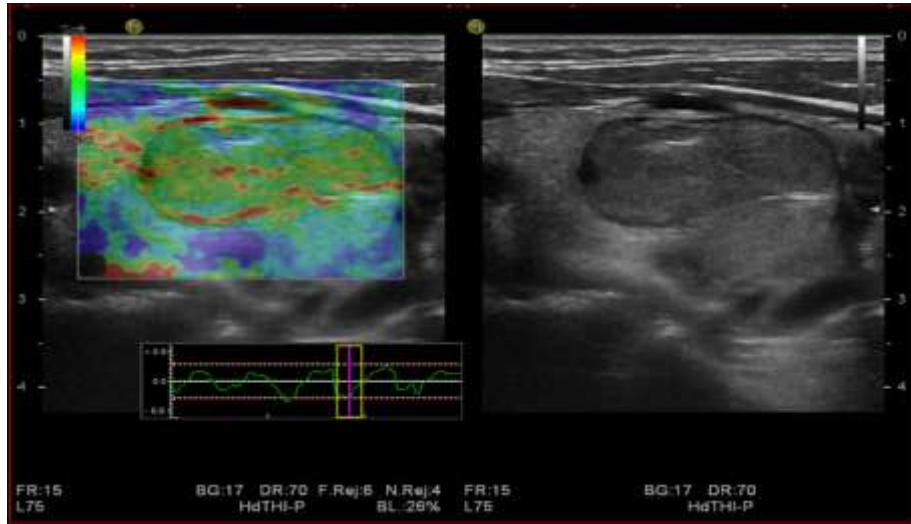
## **PHYSICAL PRINCIPLES AND TECHNIQUE OF STRAIN**

### **USE :**

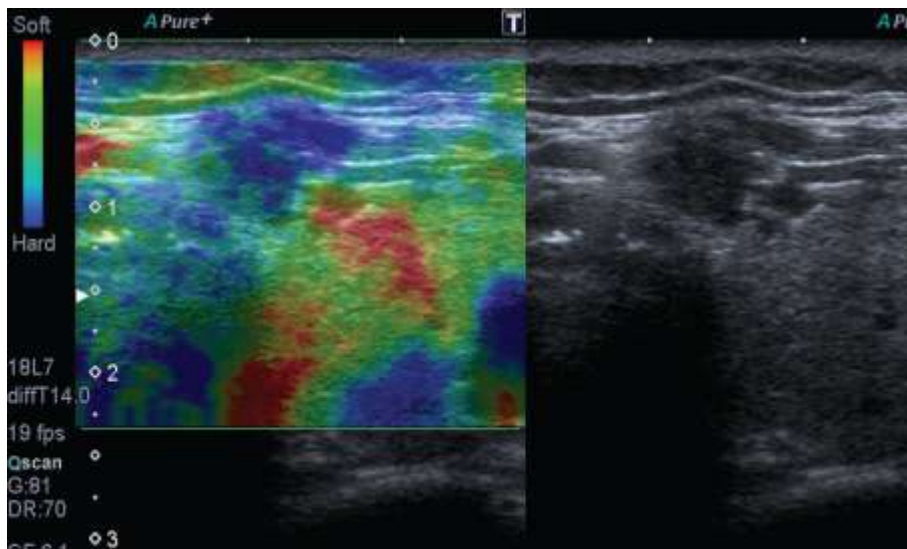
A deformation force is applied to tissue resulting in changes in dimensions and shape, which are then used to calculate the stiffness of the tissue. This is the underlying physical mechanism on which all forms of current commercially available USE methods are based. However, the alternative technologies differ according to the method used to deform tissue and the way they display deformation, leading to 3 main types of USE: strain USE, acoustic radiation force impulse (ARFI), and shear wave USE.

Strain USE detects the local deformation (strain) under slight pressure and displays it as a relative value in comparison to the strain values of the different tissues within the region of interest. Strain USE is also named real-time ultrasound elastography (RTE), or strain elastography (SE), or free-hand elastography and is the most widely available type of USE. The pressure is performed either by the hand held US transducer or by physiological movements (e.g., carotid

pulsation). This results in the elastographic image, also known as elastogram, which is represented as a color coded image superimposed on the B-mode image and displayed next to it on the screen. The quality of the operator's free-hand pressure is visualized on the screen as a sine-wave , allowing the operator to assess the validity of the compression cycles in real-time. For computing strain images without noise, the light and cyclic probe pressure has to be harmonic with a near constant rate of displacement . In general, a rectangular, or elliptic, or rounded region of interest (ROI) is used, large enough to include the entire nodule as well as a large portion of the surrounding thyroid and perithyroid tissue. This technique allows a qualitative and a semiquantitative assessment of nodule elasticity. The qualitative assessment (elastogram) represents a mapping of the amount of tissue strain at each location . Color coding depends on the system and usually blue represents hard, stiff tissue (with lowest elastic strain or no strain), red represents soft tissue (with greatest elastic strain), and green or orange represents intermediate level of stiffness.



*Fig 29. Benign thyroid nodule that appeared soft at SE, with score 2.*



*Fig 30. Malignant thyroid nodule that appeared hard at SE, with score 4.*

## **QUALITATIVE USE SCORING SYSTEMS OF THYROID NODULES:**

Strain elastograms of nodules are qualitatively evaluated with a stepwise scoring system, according to the prevalent color in the nodule. The two principal scoring systems are those classified by Asteria et al.<sup>52</sup> and Rago et al.<sup>53</sup>. The first one, based on the breast strain USE scale of Itoh et al.<sup>54</sup>, includes four different patterns<sup>53</sup>. The thyroid nodules

with scores 1 and 2 are considered benign (Figure [1](#)) and those with scores 3 and 4 are classified as suspicious for malignancy<sup>52</sup>.

A modified Asteria scale was used by Rubaltelli et al. both for thyroid nodules<sup>60</sup> and neck lymph nodes<sup>61</sup>. It consists of a five-step system that divides Asteria score 3 into patterns 3A and 3B, with a scale description as follows.

**Pattern 1:** the entire nodule section is diffusely elastic.

**Pattern 2:** the formation appears to be largely elastic with the inconstant appearance of anelastic areas during the real-time examination.

**Pattern 3:** constant presence of large anelastic areas is seen at the periphery

(**Pattern 3A**) or center (**Pattern 3B**) of the formation.

**Pattern 4:** uniformly displayed anelasticity throughout the whole nodule.

Lesions that present Pattern 1 or 2 are classified as probably benign, while Patterns 3 and 4 are indicative of probable malignancy<sup>60,61</sup>.

## DIAGNOSTIC PERFORMANCE OF USE :

For the differentiation of malignant and benign thyroid nodules, a number of literature reports show encouraging results for SE. The diagnostic performances of the main studies are presented in Table [1](#).

Diagnostic performance in malignancy detection, of SE with color coded scale for elasticity evaluation, in selected studied.

Study	Number of nodules	Sensitivity %	Specificity %	Reference standard
Rago et al., 2007 [29]	92	97	100	Surgery
Asteria et al., 2008 [28]	86	94	81	FNAB or surgery
Tranquart et al., 2008 [60]	108	100	93	FNAB
Hong et al., 2009 [23]	145	88	90	Surgery
Rubaltelli et al., 2009 [32]	51	82	86	FNAB or surgery
Lippolis et al., 2011 [49]	102	89	6	Presurgery of indeterminate cytology (follicular)
Moon et al., 2012 [44]	703	65	58	FNAB or surgery
Azizi et al., 2013 [31]	912	80	70	FNAB or surgery
Ko et al., 2014 [61]	367	89	81	FNAB or surgery
Mehrotra et al., 2013 [62]	146	90	79	FNAB or surgery

## **FUTURE PROSPECTS**

SE is expected to technically evolve in the upcoming years. Volumetric 3D elasticity images with 3D probes are currently being developed and resulting in high-resolution 3D strain-volumetric images . Initial data in thyroid , breast and testis show that in vivo 3D strain imaging is feasible and may have the potential to reduce noise and helps to differentiate cystic and solid lesions . More work has to be done on standardization of the technique. Dedicated thyroid USE protocols are expected to develop in future to overcome the limitations.

## **AIMS AND OBJECTIVES**

### **AIM**

To compare sonography combined with USE findings of thyroid lesion with the cytological results of fine-needle aspiration cytology and determine the accuracy of ultrasound combined USE findings in the diagnosis of thyroid lesions.

### **OBJECTIVE**

Ultrasonographic and USE evaluation of thyroid lesions as benign ,intermediate or malignant. To compare the accuracy of Ultrasonographic findings with fine needle aspiration cytology (FNAC) in the diagnosis, sensitivity, specificity ,PPV,NPV and overall accuracy..

## **MATERIALS AND METHODS**

This is a prospective study with 100 patients. A written “informed consent” was taken from patients before performing Ultrasound , USE and US- FNAC. Ultrasound guided fine needle aspiration cytology will be collected from patients presented for a thyroid lesion after detailed sonographic evaluation.

### **EVALUATION OF PATIENTS**

Detailed sonographic evaluation of thyroid lesion noted under the following headings

- ❖ Location
- ❖ Internal content -solid, cystic, mixed
- ❖ Homogenous or heterogenous Parenchymal interface
- ❖ Echogenicity
- ❖ Posterior Sound Transmission Enhancement, shadow, no change
- ❖ Lateral edge shadowing present or absent.
- ❖ Cystic lesions with septations.

Result of the examination will be interpreted on basis of these findings and diagnosis will be proposed after considering history and physical examination.



## **METHOD OF US- FNAC**

FNAC will be performed by using 10 ml disposable syringe with 24-gauge needle by using a perpendicular puncture and without local anesthesia. After a sample was obtained, the specimen was mounted immediately onto a glass slide. Specimens are fixed with 95% ethanol and will be sent for pathological evaluation.

## **SUBJECT SELECTION`**

### ***Inclusion Criteria***

- 1) Physical examination suggestive of palpable thyroid swelling in lower neck in midline or oneither side.
- 2) Signs and symptoms suggestive of thyroid Disorder(hypo or hyperthyroidism)

### ***Exclusion Criteria***

- 1) Patient not willing for study
- 2) Patient already diagnosed and treated for thyroid disorder
- 3) Pregnancy
- 4) FNAC showing inadequate aspirated material

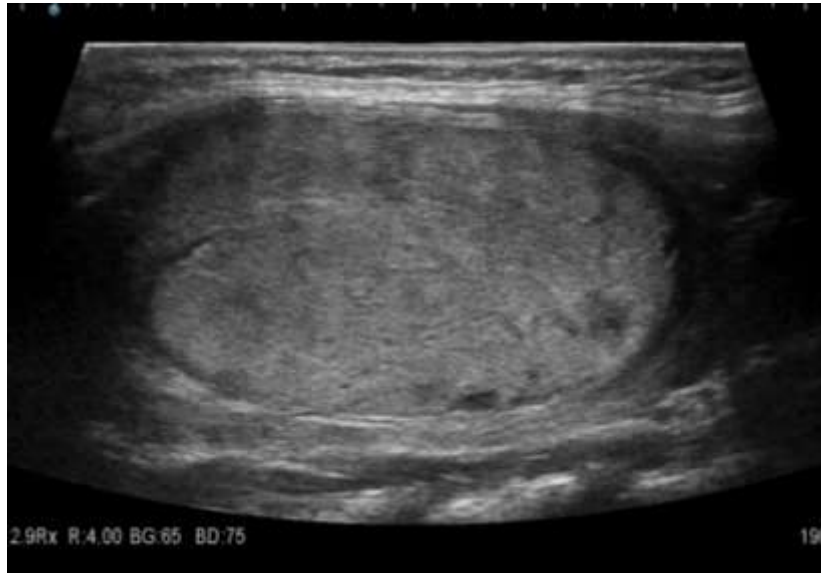
## **ASSESSMENTS OF PARAMETERS:**

- ❖ Ultrasound Findings
  - Echogenecity
  - Margin

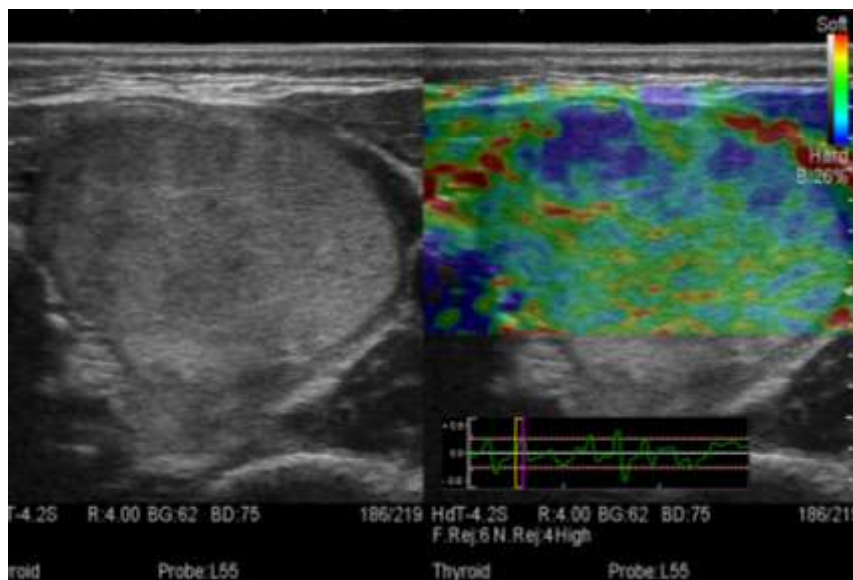
- Calcifications
- Shape
- Consistency -Cystic, solid or mixed
- ❖ Impression
  - Benign
  - Intermediate
  - Malignant
- ❖ USE
  - Benign
  - Malignant
- ❖ FNAC
  - Benign
  - Suspicious for malignancy
  - Malignant
- ❖ Interpretation

## REPRESENTATIVE CASES

### CASE .1

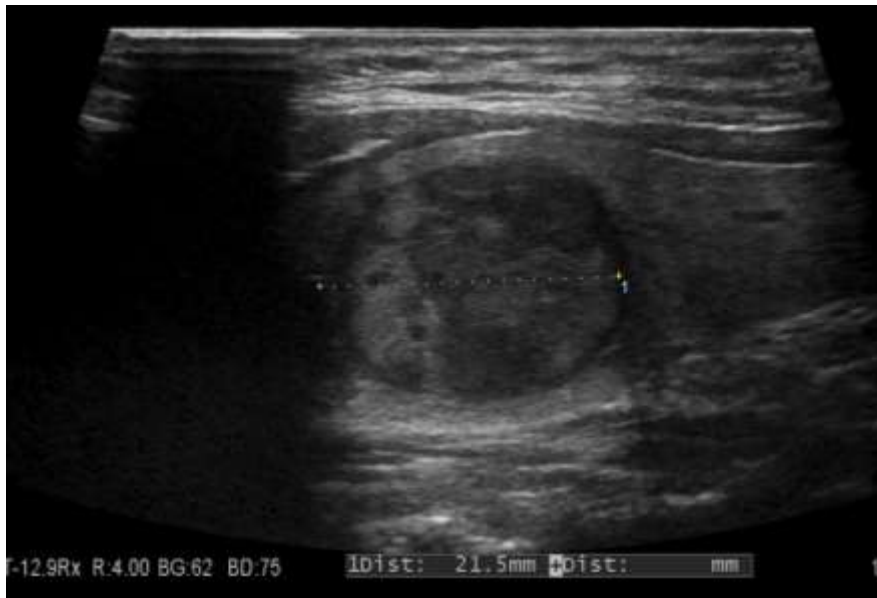


*Fig .31.1 showing benign , welldefined , oval , hyperechoic nodule with thin surrounding halo.*

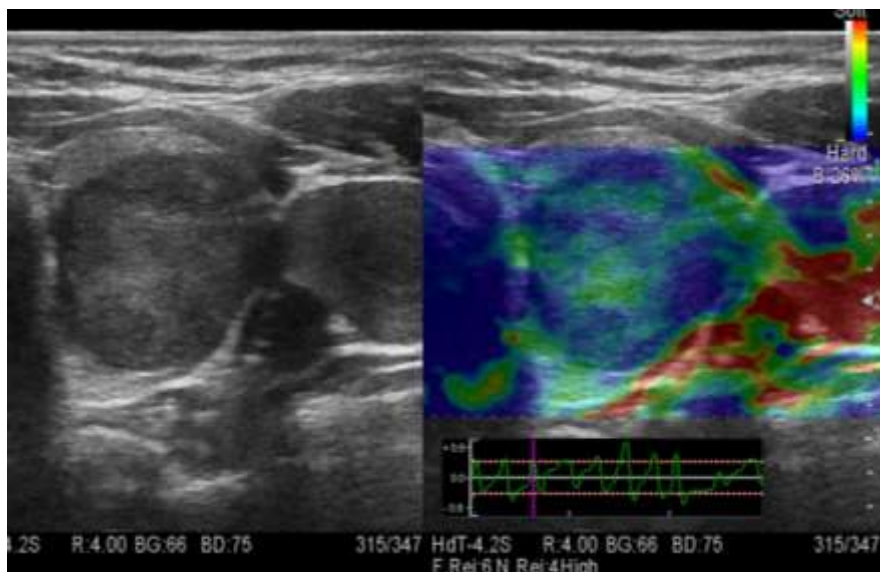


*Figure 31.2 shows predominantly firm elastographic appearance of the same nodule Which was HPE proven hyperplastic nodule*

**CASE .2**

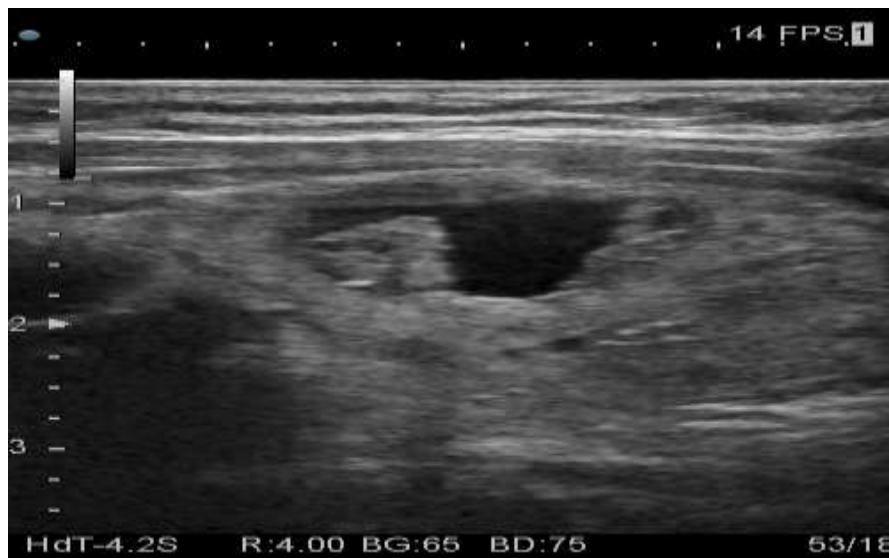

*Fig 31.3 shows welldefined , oval ,heteroechoic nodule with thin surrounding Halo.*

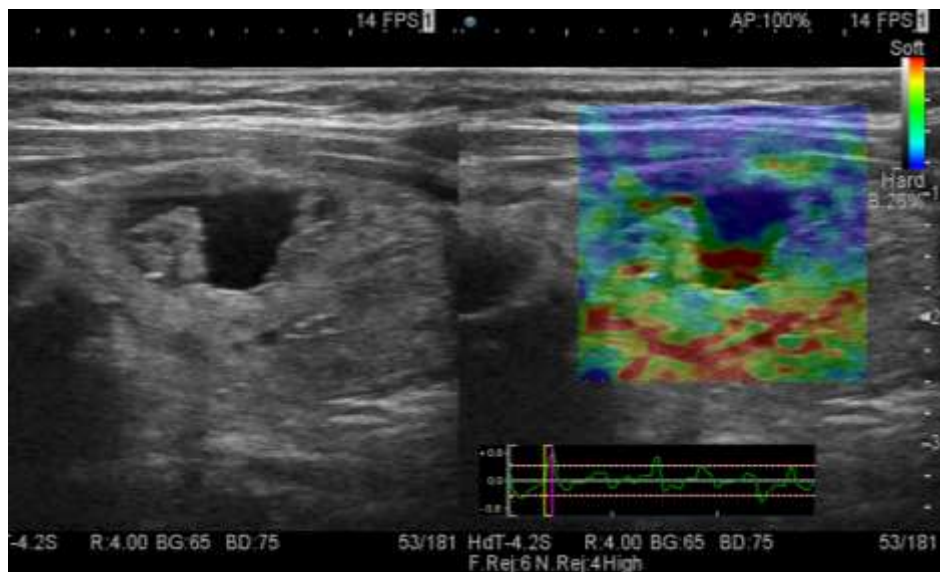


*Fig 31.4 shows predominantly hard elastographic appearance of the same Nodule. FNAC shows papillary carcinoma.*

**CASE .3**

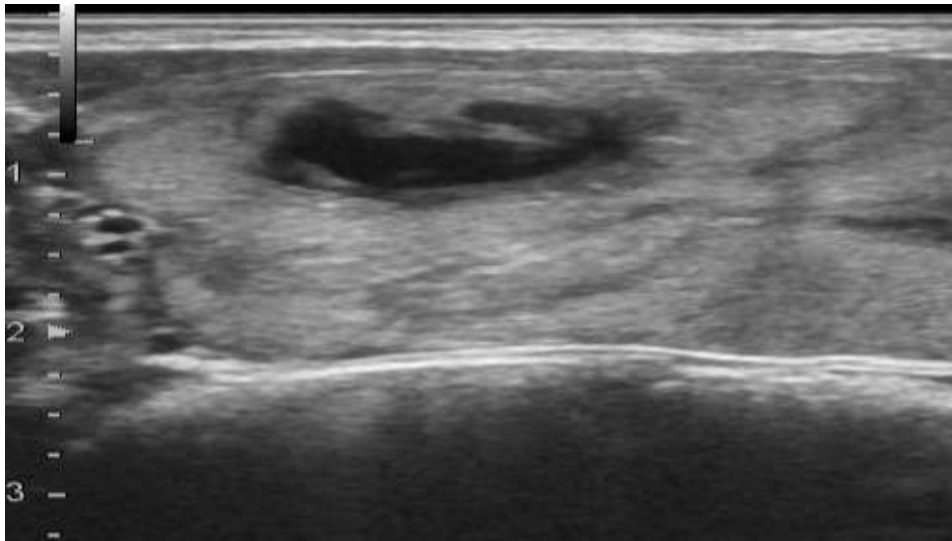


*Fig 31.5 shows cystic nodule in grayscale USG.*

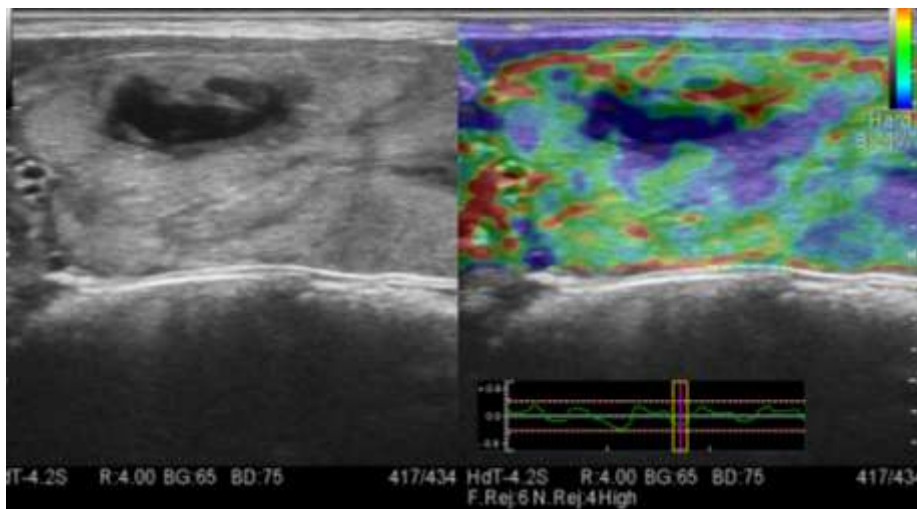


*Fig 31.6 shows hard elastographic appearance of cystic portion with firm nodule.*

**CASE .4**

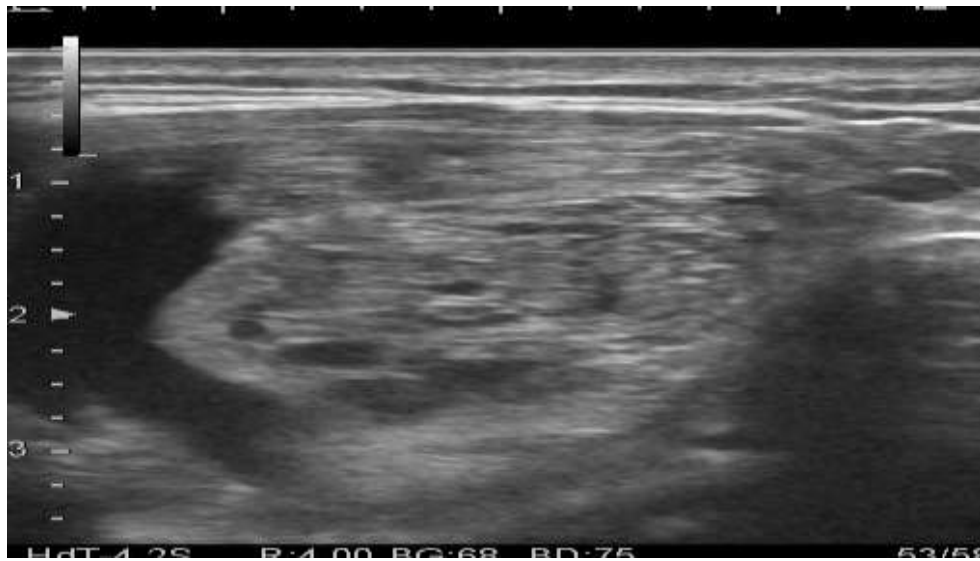

*Fig 31.7 shows benign nodule with cystic change*

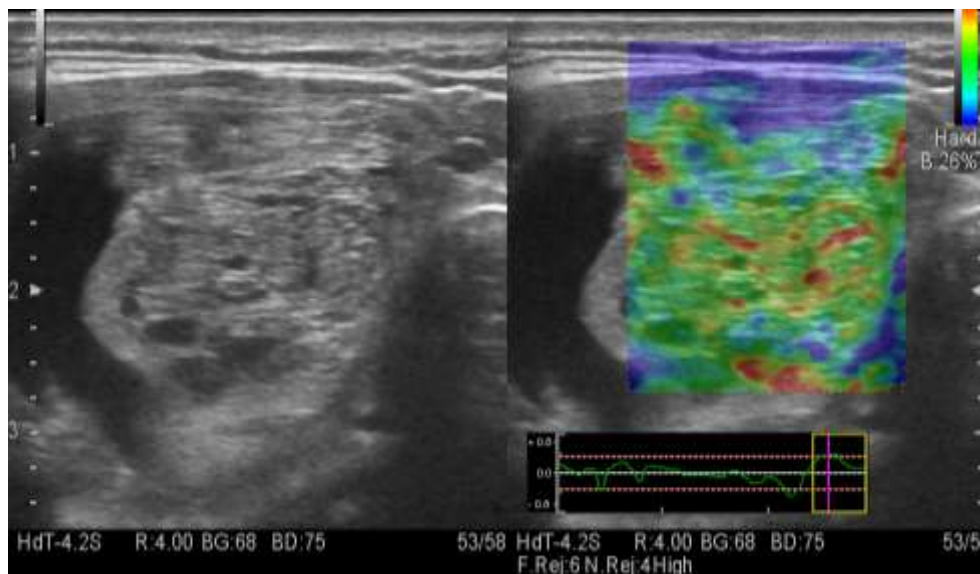


*Fig 31.8 shows predominantly firm nodule in elastography with hard cystic area. FNAC revealed nodular colloid goiter*

**CASE .5**



*Fig 31.9 shows benign nodule with spongiform appearance.*



*Fig 31.10 shows firm elastographic appearance of the same nodule.  
FNAC showed colloid goiter.*

## STATISTICAL ANALYSIS

Total number of patients studied is 100.

Number of female patients : 94.

Number of male patient: 6.

Age of the patient ranges from 14 to 70years .

100 patients with neck swelling who came for thyroid usg included in this study. Thyroid ultrasound , Colour Doppler , thyroid sonoelastography was done for all patients.

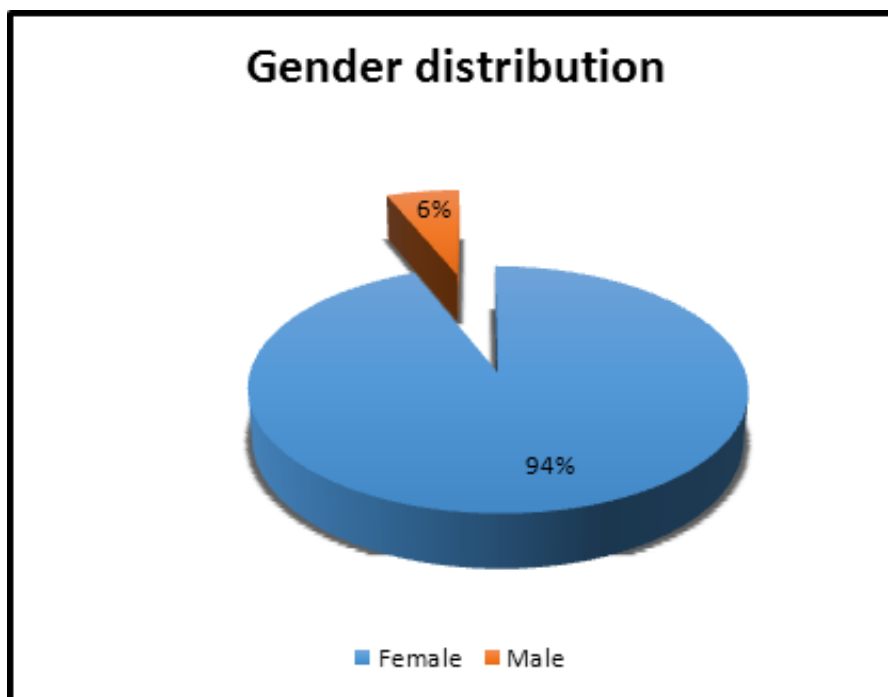
Usg guided FNAC was done from 100 nodules ( suspicious nodules in case on multinodular goiter ). The histopathological reports were collected and correlated with usg gray scale findings ,elastographic finding and combined gray scale with elastographic findings

The collected data were analysed with IBM.SPSS statistics software 23.0 Version. To describe about the data descriptive statistics frequency analysis, percentage analysis were used for categorical variables and the mean & S.D were used for continuous variables. To find the efficacy of the tools with Sensitivity, Specificity, PPV and NPV was used.



*Table 1 . Gender distribution of the patients in this study*

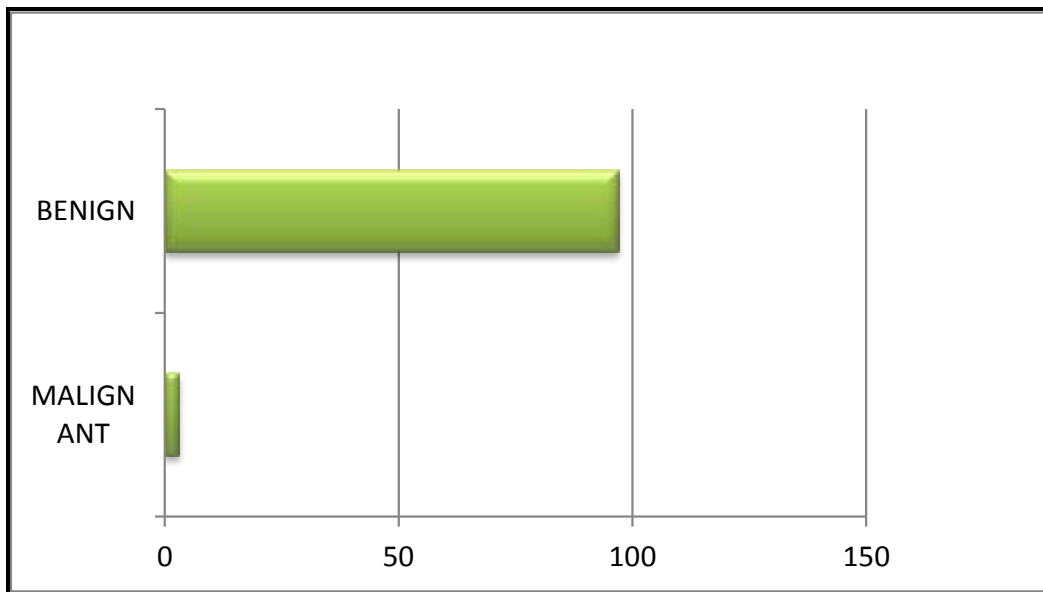
SEX		
	Frequency	Percent
Female	94	94.0
Male	6	6.0
<b>Total</b>	<b>100</b>	<b>100.0</b>



*Fig. 32. Pie chart representation of gender distribution*

*Table 2. Frequency distribution of lesion detected by FNAC*

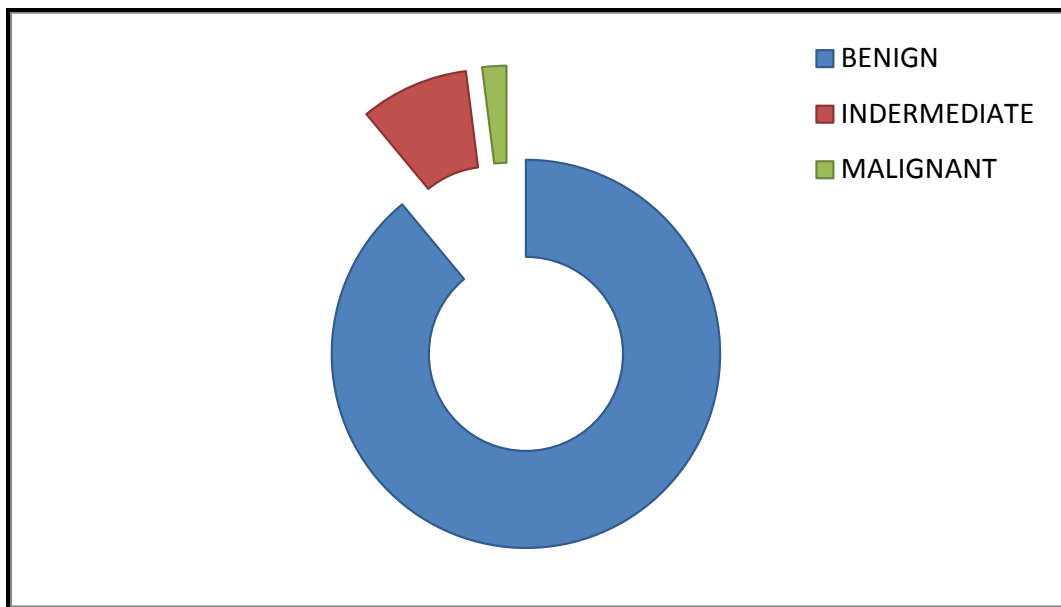
	<b>FREQUENCY</b>	<b>PERCENT</b>
BENIGN	3	3
MALIGNANT	97	97



*Fig . 33 . Bar chart representation of FNAC diagnosis Out of 100 patients , FNAC revealed 3 malignant nodules.*

*Table 3. Frequency and charecterisation of lesion by gray scale findings*

	<b>FREQUENCY</b>	<b>PERCENT</b>
BENIGN	89	89
INDETERMINATE	9	9
MALIGNANT	2	2
<b>TOTAL</b>	<b>100</b>	<b>100</b>



*Fig .34. Frequency distribution of lesion by usg gray scale findings*

**Table 4 : Comparison of gray scale findings and FNAC**

		FNAC		Total
		Malignant	Benign	
Gray Scale Findings	Malignant	3	8	11
	Benign	0	89	89
<b>Total</b>		<b>3</b>	<b>97</b>	<b>100</b>

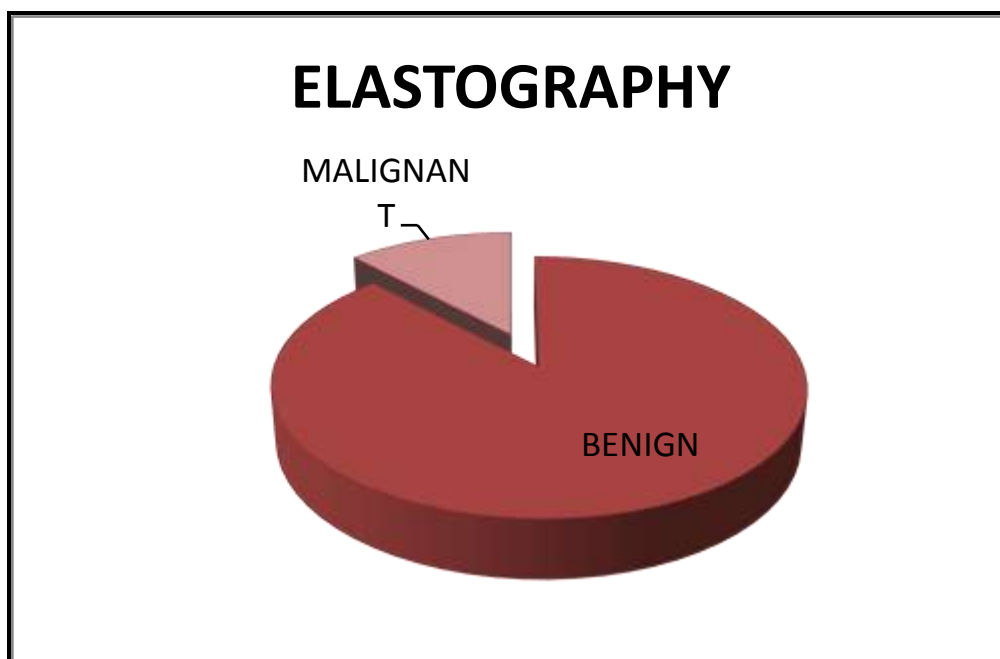
**Tab . 5. Diagnostic performance of gray scale usg in detecting malignant thyroid nodule**

Sensitivity	Specificity	PPV	NPV	Overall Accuracy
100	91.8	27.3	100	95.9

**Table.6. Frequency and charecterisation of lesion by elastography**

	Frequency	Percent
BENIGN	88	88
MALIGNANT	12	12

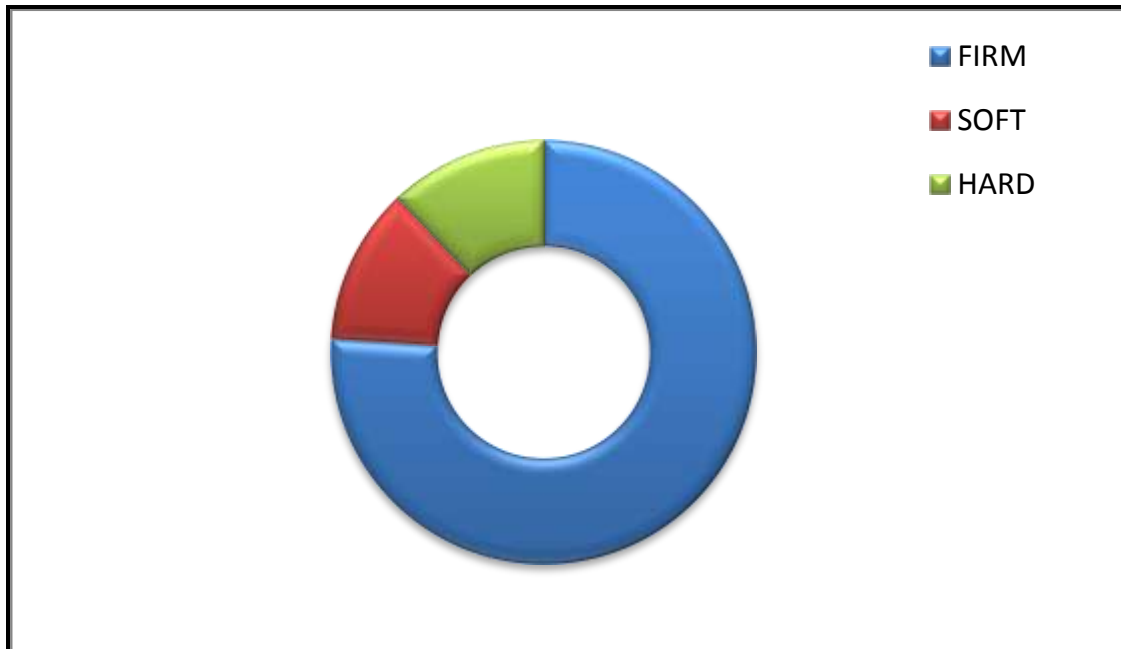
**Fig .35. Pie chart of charecterisation of lesion by elastography**



*Table 7. Frequency and charecterisation of elastographic findings*

	<b>Frequency</b>	<b>Percent</b>
Soft	12	12
Firm	76	76
Hard	12	12
<b>Total</b>	<b>100</b>	<b>100</b>

*Fig .36.Frequency and charecterisation of elastographic findings*



**Table 8 : Comparison of elastographic findings and FNAC**

		FNAC		Total
		Malignant	Benign	
Elastography	Malignant	3	10	13
	Benign	0	87	87
<b>Total</b>		<b>3</b>	<b>97</b>	<b>100</b>

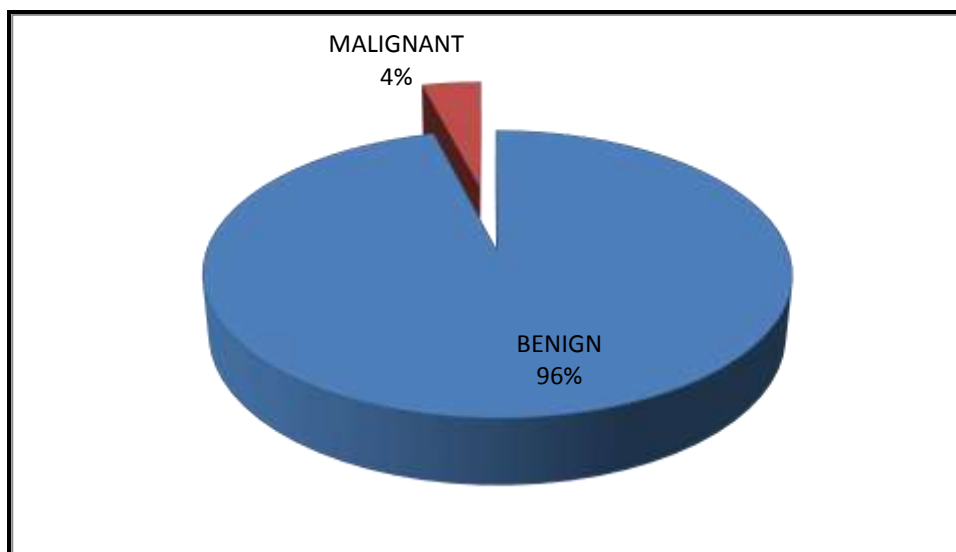
**Tab . 9. Diagnostic performance of elastography in detecting malignant thyroid nodule**

Sensitivity	Specificity	PPV	NPV	Overall Accuracy
100	89.7	23.1	100	94.85

**Table .10. Frequency and charecterisation of lesion by usg – grayscale findings with elastography**

	FREQUENCY	PERCENT
BENIGN	96	96
MALIGNANT	4	4

**Fig .37. Pie chart representing charecterisation of lesion by usg – grayscale findings with elastography**



**Table-11 : Comparision of USG gray scale with elastographic findings and FNAC**

		FNAC		Total
		Malignant	Benign	
USG with elastography	Malignant	3	1	4
	Benign	0	96	96
<b>Total</b>		<b>3</b>	<b>97</b>	<b>100</b>

**Tab . 12. Diagnostic performance of USG grayscale imaging with elastography in detecting malignant thyroid nodule.**

Sensitivity	Specificity	PPV	NPV	Overall Accuracy
100	99	75	100	99.5

**CROSSTABULATION OF GRAY SCALE FINDINGS \* FNAC**

Count		FNAC		
		Malignant	Benign	Total
Gray scale findings	Malignant	3	8	11
	Benign	0	89	89
<b>Total</b>		<b>3</b>	<b>97</b>	<b>100</b>

## CHI-SQUARE TESTS

	Value	df	Asymp. Sig. (2-sided)	Exact Sig. (2-sided)	Exact Sig. (1-sided)
Pearson Chi-Square	25.023a	1	.000		
Continuity Correction <sup>b</sup>	16.529	1	.000		
Likelihood Ratio	14.057	1	.000		
Fisher's Exact Test Linear-by-Linear Association	24.773	1	.000	.001	.001
No. of Valid Cases	100				

a. 2 cells (50.0%) have expected count less than 5. The minimum expected count is .33.

b a. 2 cells (50.0%) have expected count less than 5. The minimum expected count is .33.

## SYMMETRIC MEASURES

	Asymp. Std.		Approx. Tb	Approx. Sig.
	Value	Errors <sup>a</sup>		
Measure of Agreement Kappa	.400	.163	5.002	.000
N of Valid Cases	100			

a. Not assuming the null hypothesis.

b. Using the asymptotic standard error assuming the null hypothesis.

b. Computed only for a 2x2

Computed only for a 2x2 table



**CROSS TABULATION OF ELASTOGRAPHY \* FNAC  
COUNT**

	FNAC		Total
	Malignant	Benign	
Elastography Malignant	3	10	13
Benign	0	87	87
<b>Total</b>	<b>3</b>	<b>97</b>	<b>100</b>

**CHI-SQUARE TESTS**

	Value	df	Asymp. Sig. (2-sided)	Exact Sig. (2- sided)	Exact Sig. (1- sided)
Pearson Chi-Square	20.698a	1	.000		
Continuity Correction <sup>b</sup>	13.527	1	.000		
Likelihood Ratio	12.903	1	.000		
Fisher's Exact Test				.002	.002
Linear-by-Linear Association	20.491	1	.000		
N of Valid Cases	100				

a. 2 cells (50.0%) have expected count less than 5. The minimum expected count is .39.

b. Computed only for a 2x2 table

## SYMMETRIC MEASURES

		Value	Asymp. Std. Error <sup>a</sup>	Approx. Tb	Approx. Sig.
Measure of Agreement	Kappa	.343	.149	4.549	.000
N of Valid Cases		100			

a. Not assuming the null hypothesis.

b. Using the asymptotic standard error assuming the null hypothesis.

## CROSSTABULATION OF USG WITH ELASTOGRAPHY \* FNAC

### CROSSTAB

Count	FNAC Malignant		Benign	Total
	USG With Elastography	Malignant	3	1
	Benign	0	96	96
<b>Total</b>		<b>3</b>	<b>97</b>	<b>100</b>

## CHI-SQUARE TESTS

	Value	df	Asymp. Sig. (2-sided)	Exact Sig. (2-sided)	Exact Sig. (1-sided)
Pearson Chi-Square	74.227 <sup>a</sup>	1	.000		
Continuity Correction <sup>b</sup>	50.691	1	.000		
Likelihood Ratio	22.450	1	.000		
Fisher's Exact Test Linear-by-Linear Association	73.485	1	.000		.000
N of Valid Cases	100				

a. 3 cells (75.0%) have expected count less than 5. The minimum expected count is .12.

b. Computed only for a 2x2 table

**SYMMETRIC MEASURES**

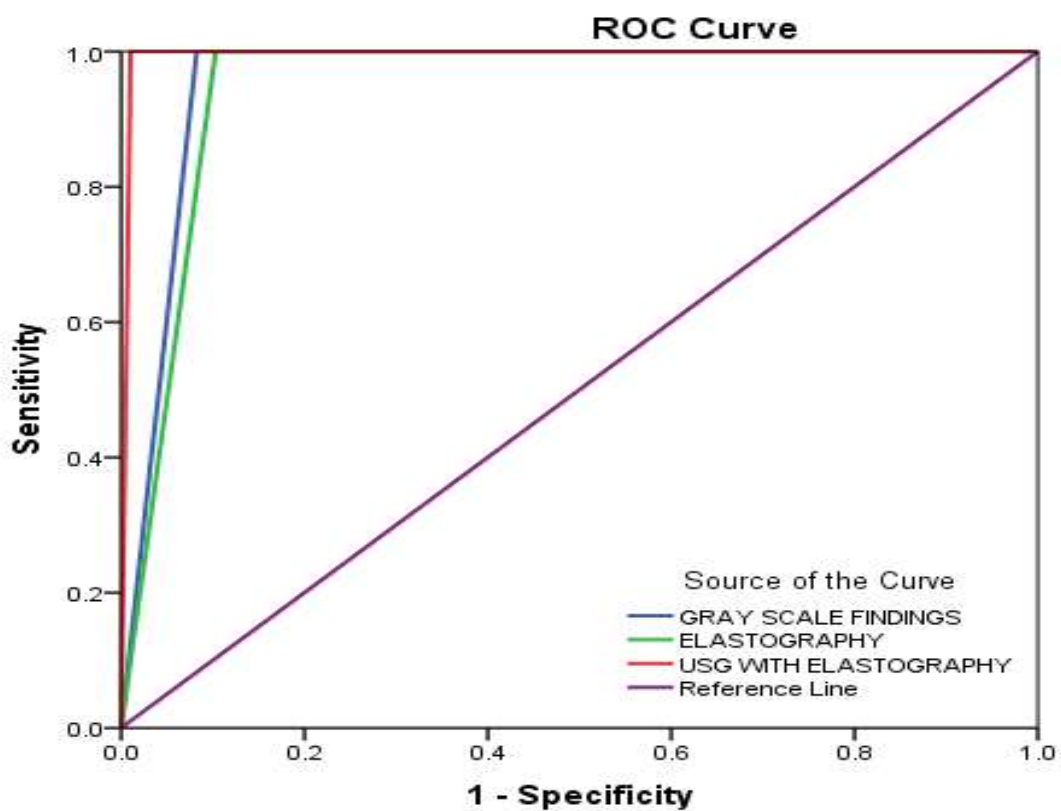
		<b>Value</b>	<b>Asymp. Std. Error<sup>a</sup></b>	<b>Approx. Tb</b>	<b>Approx. Sig.</b>
Measure of Agreement	Kappa	.852	.146	8.615	.000
N of Valid Cases		100			

a. Not assuming the null hypothesis.

b. Using the asymptotic standard error assuming the null hypothesis

Case Processing FNAC	Summary (Listwise)	Valid N
Positive	3	
Negative	97	

Smaller values of the test result variable(s) indicate stronger evidence for a positive actual state. The positive actual state is Malignant.



Diagonal segments are produced by ties.

## AREA UNDER THE CURVE

Test Result Variable(s)	Area	Std. Error <sup>a</sup>	Asymptotic Sig. <sup>b</sup>	Confidence Interval	
				Lower Bound	Upper Bound
Gray scale findings	.959	.022	.007	.915	1.000
Elastography	.948	.026	.008	.897	.999
USG with elastography	.995	.007	.004	.982	1.000

The test result variable(s): GRAY SCALE FINDINGS, ELASTOGRAPHY, USG WITH ELASTOGRAPHY has at least one tie between the positive actual state group and the negative actual state group. Statistics may be biased.

a. Under the nonparametric assumption

b. Null hypothesis: true area = 0.5

**Tab.12.Consolidated table of statistical variables for Gray scale findings , Elastography and Both.**

Diagnostic tools	AUC	Sensi-tivity	Speci-ficity	PPV	NPV	Overall accuracy	Kappa	Kappa P-value
Gray Scale	.959	100	91.8	27.3	100	95.90	0.40	0.0005**
Elastography	.948	100	89.7	23.1	100	94.84	0.34	0.0005**
USG with Elastography	.995	100	99.0	75.0	100	99.50	0.85	0.0005**
** Highly Sig. at P< 0.01 level								

## **RESULTS**

### **DEMOGRAPHIC CHARACTERISTICS**

Table.1& Figure.32 showed the gender frequency of the study. Out of 100 patients 94 were females and 6 were males. Most common presenting symptom is neck swelling. Age of the patients was not associated with malignancy.

### **GRAY SCALE FINDINGS ASSOCIATED WITH BENIGN AND MALIGNANT NODULES**

Table .3 and figure 34 showed frequency distribution and characterization of benign and malignant lesions by USG gray scale findings. Benign lesions are well defined, hyperechoic or isoechoic ,wider than tall, purely cystic or cyst with thin septa and surrounding thin halo. Malignant lesions are taller than wide ,irregular, illdefined, hypoechoic ,solid lesions with microcalcifications.

### **DIAGNOSTIC PERFORMANCE OF GRAY SCALE USG**

Table 2 and figure 33 explained about FNAC results.

3 lesions were malignant and rest of the nodules were benign.

Gray scale findings differentiate 89 benign nodules and 2 malignant nodules. 9 cases were intermediate on grayscale USG.

In this study, sensitivity of grayscale USG in detecting malignant thyroid nodules was 100% but specificity was 91.8% . some lesions were

overlooked compared with FNAC. Table 5 showed the sensitivity and specificity of grayscale USG.

### **DIAGNOSTIC PERFORMANCE OF USE**

Table .6 and figure 35 showed frequency and characterisation of thyroid nodules by Elastography. 88 nodules were benign and 12 were probably malignant on elastography. In this 88 benign nodules ,12 nodules were soft, 76 nodules were firm on elastography.

Table 9 revealed the diagnostic performance of elastography. It showed sensitivity of 100% but specificity was 89.7 % . Here also some lesions were overlooked compared with FNAC. Accuracy of gray-scale US features was mostly higher than that of elastography, but it was not statistically significant.

### **DIAGNOSTIC PERFORMANCE OF USG COMBINED WITH USE**

Table 10 and figure 37 revealed frequency and characterisation of the lesion by both gray scale and elastography. 96 benign nodules and 4 probably malignant nodules were detected by using both techniques.

Table 12 revealed the diagnostic performance of combining usg gray scale and elastography.. It showed sensitivity of 100% but specificity was 99% .Overall accuracy was 99.5%.

According to **Moon WJ, Jung SL, Lee JH, et al.** reports, for the differentiation of benign versus malignant thyroid nodules, sonography

has sensitivity rates of 63% to 94%, specificity of 61% to 95%, and overall accuracy of 78% to 94%.

In another study by Trimboli et al. [47], based on a prospective evaluation of 498 thyroid nodules, the combination of US features with the SE four-class color scale yielded improvement with 97% sensitivity and 97% NPV whereas US alone had 85% sensitivity and 91% negative predictive value. The authors suggest that, by adding SE evaluation, the sensitivity for malignancy of US findings is markedly increased and the selection of nodules that do not need cytology is made more reliable. US and SE combined evaluation improves the diagnostic performance for thyroid cancer detection.

In this study, out of 3 cases of carcinoma detected by fnac, all are detected by combining US AND USE. In this evaluation of 100 thyroid nodules, the combination of US features with the USE yielded improvement with 99% specificity and 99.5% overall accuracy, whereas us alone had 91.8% specificity and 95.9% overall accuracy with a highly significant p value ( $p < 0.01$ ).



## DISCUSSION

This study was conducted to investigate the incremental detection rate of malignant thyroid nodule by grayscale USG in combination with USE.

Elastography has been introduced to evaluate hardness objectively, to improve the diagnostic performance of gray-scale US examination in differential diagnosis of thyroid nodules, and to eventually reduce unnecessary benign biopsies in thyroid nodule. Many previous studies have proved that elastography is useful in differentiating malignant from benign nodules. In our study, our findings were consistent with those other studies.

Elastography is usually performed in thyroid nodules detected at grayscale US, and the high diagnostic performances of combinations of suspicious gray-scale US features are validated through many previous studies as well as in our study.

Accordingly, for elastography to be used widely as an adjunctive diagnostic tool supporting gray-scale US or to be used as a separate diagnostic tool, several conditions should be fulfilled. The diagnostic performance of elastography itself or a combination of elastography and gray-scale US should be superior to that of gray-scale US alone.

## LIMITATIONS

The limitations of SE are a result of technical issues associated with the application and physics of the technique as well as the histological features of the nodules, leading to misinterpretations and pitfalls.

SE in all its forms remains an examiner-dependent method. Nonuniform compressions produce intra- and interobserver variability. Therefore, several compression relaxation cycles are needed to ensure that quality data are obtained.

Another important issue is that prestress compression can result in misleadingly high stiffness results, especially in superficial tissues like the thyroid.

Another technical limitation is the lack of standardization both in the technique application, the type of measurements obtained, the cut-off values, and the color coding. The existence of carotid artery pulsations generates variable tissue deformations leading to potential pitfalls in the SE evaluation.

Besides inherent technical limitations, the histological features of the nodules themselves may lead to pitfalls. Fibrosis within a nodule can be a confounding factor in elasticity imaging. There is no study evaluating fibrosis in thyroid nodules using SE; however, many studies on liver SE have proved a correlation between levels of stiffness and

fibrosis. Fibrosis may be a feature in both benign and malignant nodules and could therefore be a misleading factor. The presence of autoimmune thyroiditis seems not to influence the SE results, whereas calcifications, partially cystic or colloid components, isthmus location, nodule size, and the presence of multinodular goiter are correlated to increased levels of stiffness ..

## CONCLUSION

According to this study , it can be concluded that gray scale USG in combination with elastography is an cost effective , non – invasive and feasible technique to detect malignant thyroid nodule with a high specificity. The study found that US Elastography is a useful complement to gray scale US, enhancing its accuracy in detecting malignant thyroid nodules.

Given the high prevalence of thyroid nodules and the substantial costs related to their workup and management, gray scale USG in combination with elastography could be a valuable tool for a better selection of nodules that need invasive procedures and it can help in identifying patients in need of FNAC or Biopsy .

Gray scale USG in combination with elastography may also be used to guide the follow-up of suspicious lesions negative for malignancy at FNAC.

## REVIWED ARTICLES

- 1) Solbiati L. La tiroide e le paratiroidi [The thyroid and the parathyroid].In: Rizzatto G, Solbiati L, editors. Anatomia Ecografica: quadri normali, varianti e limiti con il patologico. Milan: Masson; 1992. p. 35-45.
- 2) Jarlov AE, Hegedus L, Gjorup T, Hansen JE. Accuracy of the clinical assessment of thyroid size. Dan Med Bull 1991;38:87-89.
- 3) Kerr L. High-resolution thyroid ultrasound: the value of color Doppler. Ultrasound Q 1994;12:21-43.
- 4) Favus MJ, Schneider AB, Stachura ME, et al. Thyroid cancer occurring as a late consequence of head-and-neck irradiation: evaluation of 1056 patients. N Engl J Med 1976;294:1019-1025.
- 5) DeGroot LJ, Reilly M, Pinnameneni K, Refetoff S. Retrospective and prospective study of radiation-induced thyroid disease. Am J Med 1983;74:852-862.
- 6) Grebe SK, Hay ID. Follicular cell-derived thyroid carcinomas. Cancer Treat Res 1997;89:91-140.
- 7) Solbiati L, Cioffi V, Ballarati E. Ultrasonography of the neck. Radiology.Clin North Am 1992;30:941-954.

- 8) Muller HW, Schroder S, Schneider C, Seifert G. Sonographic tissue characterisation in thyroid gland diagnosis: a correlation between sonography and histology. *Klin Wochenschr* 1985;63:706-710.
- 9) Lagalla R, Caruso G, Midiri M, et al. Echo Doppler-couleur et pathologie thyroïdienne. *JEMU* 1992;13:44-47.
- 10) Solbiati L, Ballarati E, Cioffi V. Contribution of color-flow mapping to the differential diagnosis of the thyroid nodules. *Radiological Society of North America*; 1991 [abstract].
- 11) Solbiati L, Volterrani L, Rizzato G, et al. The thyroid gland with low uptake lesions: evaluation by ultrasound. *Radiology* 1985;155: 187-191.
- 12) Schlumberger MJ, Filetti S, Hay ID. Nontoxic goiter and thyroid neoplasia. In: Larsen PR, Kronenberg HM, Melmed S, et al, editors. *Williams textbook of endocrinology*. 10th ed. Philadelphia: Saunders; 2003. p. 457-490.
- 13) Black BM, Kirk Jr TA, Woolner LB. Multicentricity of papillary adenocarcinoma of the thyroid: influence on treatment. *J Clin Endocrinol Metab* 1960;20:130-135.

- 14) Wunderbaldinger P, Harisinghani MG, Hahn PF, et al. Cystic lymphnode metastases in papillary thyroid carcinoma. *AJR Am J Roentgenol* 2002;178:693-697.
- 15) Pilotti S, Pierotti MA. Classificazione istologica e caratterizzazione molecolare dei tumori dell'epitelio follicolare della tiroide. *Argomenti Oncol* 1992;13:365-380.
- 16) Holtz S, Powers WE. Calcification in papillary carcinoma of the thyroid. *Am J Roentgenol Radium Ther Nucl Med* 1958;80: 997-1000
- 17) Solbiati L, Ierace T, Lagalla R, et al. Reliability of high-frequency US and color Doppler US of thyroid nodules: Italian multicenter study of 1,042 pathologically confirmed cases—which role for scintigraphy and biopsy? *Radiological Society of North America*, 1995.
- 18) Hamburger JI, Miller JM, Kini SR. Lymphoma of the thyroid. *Ann Intern Med* 1983;99:685-693.
- 19) Gharib H, Goellner JR. Fine-needle aspiration biopsy of the thyroid: an appraisal. *Ann Intern Med* 1993;118:282-289.
- 20) Hawkins F, Bellido D, Bernal C, et al. Fine-needle aspiration biopsy in the diagnosis of thyroid cancer and thyroid disease. *Cancer* 1987;59:1206-1209.

- 21) Khafagi F, Wright G, Castles H, et al. Screening for thyroid malignancy: the role of fine-needle biopsy. *Med J Aust* 1988;149:302- 303, 6-7.
- 22) Hall TL, Layfield LJ, Philippe A, Rosenthal DL. Sources of diagnostic error in fine-needle aspiration of the thyroid. *Cancer* 1989;63: 718-725.
- 23) Altavilla G, Pascale M, Nenci I. Fine-needle aspiration cytology of thyroid gland diseases. *Acta Cytol* 1990;34:251-256.
- 24) Ravetto C, Spreafico G, Colombo L. [Cytological examination using needle aspiration in the early diagnosis of thyroid neoplasms: comparison of clinical and scintigraphic data]. *Recenti Prog Med* 1977; 63:258-274.
- 25) Sangalli G, Serio G, Zampatti C, et al. Fine-needle aspiration cytology of the thyroid: a comparison of 5469 cytological and final histological diagnoses. *Cytopathology* 2006;17:245-250.
- 26) James EM, Charboneau JW. High-frequency (10 MHz) thyroid ultrasonography. *Semin Ultrasound CT MR* 1985;6:294-309.
- 27) Scheible W, Leopold GR, Woo VL, Gosink BB. High-resolution real-time ultrasonography of thyroid nodules. *Radiology* 1979; 133:413-417.



- 28) Kim EK, Park CS, Chung WY, et al. New sonographic criteria for recommending fine-needle aspiration biopsy of nonpalpable solid nodules of the thyroid. *AJR Am J Roentgenol* 2002;178:687-691.
- 29) Koike E, Noguchi S, Yamashita H, et al. Ultrasonographic characteristics of thyroid nodules: prediction of malignancy. *Arch Surg* 2001;136:334-337.
- 30) Rago T, Vitti P, Chiovato L, et al. Role of conventional ultrasonography and color flow Doppler sonography in predicting malignancy in “cold” thyroid nodules. *Eur J Endocrinol* 1998;138:41-46.
- 31) Moon WJ, Jung SL, Lee JH, et al. Benign and malignant thyroid nodules: ultrasound differentiation—multicenter retrospective study. *Radiology* 2008;247:762-770.
- 32) Alexander EK, Marqusee E, Orcutt J, et al. Thyroid nodule shape and prediction of malignancy. *Thyroid* 2004;14:953-958.
- 33) Rubaltelli L, Corradin S, Dorigo A, et al. Differential diagnosis of benign and malignant thyroid nodules at elastosonography. *Ultraschall Med* 2009;30:175-179.
- 34) Ueno E, Ito A. Diagnosis of breast cancer by elasticity imaging. *Eizo Joho Medical* 2004;36:2-6.

- 35) Ferrari FS, Megliola A, Scorzelli A, et al. Ultrasound examination using contrast agent and elastosonography in the evaluation of single thyroid nodules: preliminary results. *J Ultrasound* 2008;11:47-54.
- 36) Hong Y, Liu X, Li Z, et al. Real-time ultrasound elastography in the differential diagnosis of benign and malignant thyroid nodules. *J Ultrasound Med* 2009;28:861-867.
- 37) Lyshchik A, Higashi T, Asato R, et al. Thyroid gland tumor diagnosis at ultrasound elastography. *Radiology* 2005;237:202-211.
- 38) Rago T, Santini F, Scutari M, et al. Elastography: new developments in ultrasound for predicting malignancy in thyroid nodules. *J Clin Endocrinol Metab* 2007;92:2917-2922.
- 39) Hay ID. Thyroiditis: a clinical update. *Mayo Clin Proc* 1985;60:836-843.
- 40) Adams H, Jones MC. Ultrasound appearances of de Quervain's thyroiditis. *Clin Radiol* 1990;42:217-218.
- 41) Birchall IW, Chow CC, Metreweli C. Ultrasound appearances of de Quervain's thyroiditis. *Clin Radiol* 1990;41:57-59.
- 42) Yeh HC, Futterweit W, Gilbert P. Micronodulation: ultrasonographic sign of Hashimoto thyroiditis. *J Ultrasound Med* 1996; 15:813-819.

- 43) Takashima S, Matsuzuka F, Nagareda T, et al. Thyroid nodules associated with Hashimoto thyroiditis: assessment with ultrasound. *Radiology* 1992;185:125-130.
- 44) Lagalla R, Caruso G, Benza I, et al. [Echo color Doppler in the study of hypothyroidism in the adult]. *Radiol Med* 1993;86:281- 283.
- 45) Castagnone D, Rivolta R, Rescalli S, et al. Color Doppler sonography in Graves' disease: value in assessing activity of disease and predicting outcome. *AJR Am J Roentgenol* 1996;166:203- 207.
- 46) D. S. Cooper, G. M. Doherty, B. R. Haugen et al., "Revised American thyroid association management guidelines for patients with thyroid nodules and differentiated thyroid cancer," *Thyroid*, vol. 19, no. 11, pp. 1167–1214, 2009.
- 47) B. S. Garra, "Elastography: current status, future prospects, and making it work for you," *Ultrasound Quarterly*, vol. 27, no. 3, pp. 177–186, 2011. J. Ophir, I. Céspedes, H. Ponnekanti, Y. Yazdi, and X. Li, "Elastography: a quantitative method for imaging the elasticity of biological tissues," *Ultrasonic Imaging*, vol. 13, no. 2, pp. 111–134, 1991. D. Cosgrove, F. Piscaglia, J. Bamber et al., "EFSUMB guidelines and recommendations on the clinical use of

- ultrasound elastography. Part 2: clinical applications,” *Ultraschall in der Medizin*, vol. 34, no. 3, pp. 238–253, 2013
- 48) C. F. Dietrich and L. Rudd, “The EFSUMB website, a guide for better understanding,” *Medical Ultrasonography*, vol. 15, no. 3, pp. 215–223, 2013.
- 49) V. Cantisani, V. D'Andrea, F. Biancari et al., “Prospective evaluation of multiparametric ultrasound and quantitative elastosonography in the differential diagnosis of benign and malignant thyroid nodules: preliminary experience,” *European Journal of Radiology*, vol. 81, no. 10, pp. 2678–2683, 2012.
- 50) S. H. Park, S. J. Kim, E. K. Kim et al., “Interobserver agreement in assessing the sonographic and elastographic features of malignant thyroid nodules,” *American Journal of Roentgenology*, vol. 193, no. 5, pp. W416–W423, 2009. .
- 51) Y. Hong, X. Liu, Z. Li, X. Zhang, M. Chen, and Z. Luo, “Real-time ultrasound elastography in the differential diagnosis of benign and malignant thyroid nodules,” *Journal of Ultrasound in Medicine*, vol. 28, no. 7, pp. 861–867, 2009.
- 52) C. Asteria, A. Giovanardi, A. Pizzocaro et al., “US-elastography in the differential diagnosis of benign and malignant thyroid nodules,” *Thyroid*, vol. 18, no. 5, pp. 523–531, 2008.

- 53) T. Rago, F. Santini, M. Scutari, A. Pinchera, and P. Vitti, “Elastography: new developments in ultrasound for predicting malignancy in thyroid nodules,” *Journal of Clinical Endocrinology and Metabolism*, vol. 92, no. 8, pp. 2917–2922, 2007.
- 54) A. Itoh, E. Ueno, E. Tohno et al., “Breast disease: clinical application of US elastography for diagnosis,” *Radiology*, vol. 239, no. 2, pp. 341–350, 2006. Bojunga, E. Herrmann, G. Meyer, S. Weber, S. Zeuzem, and M. Friedrich-Rust, “Real-time elastography for the differentiation of benign and malignant thyroid nodules: a meta-analysis,” *Thyroid*, vol. 20, no. 10, pp. 1145–1150, 2010.
- 55) P. Trimboli, R. Guglielmi, S. Monti et al., “Ultrasound sensitivity for thyroid malignancy is increased by real-time elastography: a prospective multicenter study,” *The Journal of Clinical Endocrinology & Metabolism*, vol. 97, no. 12, pp. 4524–4530, 2012.
- 56) P. V. Lippolis, S. Tognini, G. Materazzi et al., “Is elastography actually useful in the presurgical selection of thyroid nodules with indeterminate cytology?” *The Journal of Clinical Endocrinology & Metabolism*, vol. 96, no. 11, pp. E1826–E1830, 2011.

- 57) T. Rago, M. Scutari, F. Santini et al., “Real-time elastosonography: Useful tool for refining the presurgical diagnosis in thyroid nodules with indeterminate or nondiagnostic cytology,” *Journal of Clinical Endocrinology & Metabolism*, vol. 95, no. 12, pp. 5274–5280, 2010.
- 58) V.Cantisani, H. Grazhdani, P. Ricci et al., “Q-elastosonography of solid thyroid nodules: assessment of diagnostic efficacy and interobserver variability in a large patient cohort,” *European Radiology*, vol. 24, no. 1, pp. 143–150, 2014.
- 59) V.Cantisani, P. Lodise, H. Grazhdani et al., “Ultrasound elastography in the evaluation of thyroid pathology. Current status,” *European Journal of Radiology*, vol. 83, no. 3, pp. 420–428, 2014.
- 60) L.Rubaltelli, S. Corradin, A. Dorigo et al., “Differential diagnosis of benign and malignant thyroid nodules at elastosonography,” *Ultraschall in derMedizin*, vol. 30, no. 2, pp. 175–179, 2009.
- 61) L.Rubaltelli, R. Stramare, A. Tregnaghi et al., “The role of sonoelastography in the differential diagnosis of neck nodules,” *Journal of Ultrasound*, vol. 12, no. 3, pp. 93–100, 2009.



## **PATIENT INFORMATION SHEET**

**TITLE: “ STRAIN USG ELASTOGRAPHY WITH GRAY SCALE AND COLOUR DOPPLER IMAGING OF THYROID NODULES – EFFICACY COMPARED WITH FNAC ”**

- ❖ We are conducting a study on thyroid lesions among patients attending Government General Hospital, Chennai and for that your specimen may be valuable to us.
- ❖ The purpose of this study is to diagnose cases of thyroid lesions easily with the help of certain special tests.
- ❖ The privacy of the patients in the research will be maintained throughout the study. In the event of any publication or presentation resulting from the research, no personally identifiable information will be shared.
- ❖ Taking part in this study is voluntary. You are free to decide whether to participate in this study or to withdraw at any time; your decision will not result in any loss of benefits to which you are otherwise entitled.
- ❖ The results of the special study may be intimated to you at the end of the study period or during the study if anything is found abnormal which may aid in the management or treatment.

**Signature of investigator  
(Dr. A. Karpagavalli)**

**Signature of participant**

Date :



## PROFORMA

**Study Title: STRAIN USG ELASTOGRAPHY WITH GRAY SCALE AND COLOUR DOPPLER IMAGING OF THYROID NODULES – EFFICACY COMPARED WITH FNAC ”**

SL.No.

Name :

Age / Sex :

Occupation :

Address :

Presenting Complaints :

Past History (if any) :

Investigations (if any) :

- Ultrasound Findings
  - Shape
  - Internal contents
  - Echogenecity
  - Halo
  - Margin
  - Calcifications
  - Colour Doppler
    - Peripheral flow pattern
    - Internal flow pattern
- Sonoelastography
  - Soft
  - Firm
  - Hard
- Impression
  - Benign
  - Suspicious
  - Malignant
  - FNAC
  - Benign
  - Indeterminate
  - Suspicious for malignancy

## **ABBREVIATIONS**

CT	Computed Tomography
MRI	Magnetic resonance imaging.
USG	Ultrasonogram
USE	Ultrasound elastography
FNAC	Fine Needle Aspiration Cytology
HPE	Histo pathological examination
FNAB	Fine Needle Aspiration Biopsy

**INSTITUTIONAL ETHICS COMMITTEE  
MADRAS MEDICAL COLLEGE, CHENNAI 600 003**

EC Reg.No.ECR/270/Inst./TN/2013  
Telephone No.044 25305301A  
Fax: 011 25363970

**CERTIFICATE OF APPROVAL**

To  
Dr.A. Karpagavalli  
Post Graduate in Radio Diagnosis  
Madras Medical College  
Chennai

Dear Dr.A. Karpagavalli,

The Institutional Ethics Committee has considered your request and approved your study titled **"USG CHARACTERISATION OF THYROID LESIONS AND ITS FNAC CORRELATION" NO. 16012017.**

The following members of Ethics Committee were present in the meeting hold on **03.01.2017** conducted at Madras Medical College, Chennai 3

- |  |                     |
|--|---------------------|
| 1.Dr.C.Rajendran, MD.,   | :Chairperson        |
| 2.Dr.M.K.Muralidharan,MS.,M.Ch.,Dean, MMC,Ch-3                 | :Deputy Chairperson |
| 3.Prof.Sudha Seshayyan,MD., Vice Principal,MMC,Ch-3            | : Member Secretary  |
| 4.Prof.B.Vasanthi,MD., Prof.of Pharmacology.,MMC,Ch-3          | : Member            |
| 5.Prof.A.Rajendran,MS, Prof. of Surgery,MMC,Ch-3               | : Member            |
| 6.Prof.N.Gopalakrishnan,MD,Director,Inst.of Nephrology,MMC,Ch  | : Member            |
| 7.Prof.Baby Vasumathi,MD.,Director, Inst. of O & G             | : Member            |
| 8.Prof.K.Ramadevi,MD.,Director,Inst.of Bio-Che,MMC,Ch-3        | : Member            |
| 9.Prof.R.Padmavathy, MD, Director,Inst.of Pathology,MMC,Ch-3   | : Member            |
| 10.Prof.S.Mayilvahanan,MD,Director, Inst. of Int.Med,MMC, Ch-3 | : Member            |
| 11.Tmt.J.Rajalakshmi, JAO,MMC, Ch-3                            | : Lay Person        |
| 12.Thiru S.Govindasamy, BA.,BL,High Court,Chennai              | : Lawyer            |
| 13.Tmt.Arnold Saulina, MA.,MSW.,                               | :Social Scientist   |

We approve the proposal to be conducted in its presented form.

The Institutional Ethics Committee expects to be informed about the progress of the study and SAE occurring in the course of the study, any changes in the protocol and patients information/informed consent and asks to be provided a copy of the final report.

Member Secretary - Ethics Committee

MEMBER SECRETARY  
INSTITUTIONAL ETHICS COMMITTEE  
MADRAS MEDICAL COLLEGE  
CHENNAI - 600 003

<https://secure.orkund.com/view/30641297-617294-688796#q1bKlUayjfbQMdxNNAx0JHWMYvUSOTM/LTMBTISXITIVyMAzMLCONLAWMT>

**ORKUND**

**Document** [K:thesis final plagia.docx \(D30957106\)](#)  
**Submitted** 2017-10-02 20:34 (+05:0-30)  
**Submitted by** Karpagavalli, A. (karpagambir2015@gmail.com)  
**Receiver** karpagambir2015.mgrmu@analysis.orkund.com  
**Message** Regarding plagiarism checking [Show full message](#)

1% of this approx. 24 pages long document consists of text present in 2 sources.

Sources	Highlights
<input type="checkbox"/>	<b>Rank</b>
<input checked="" type="checkbox"/>	<b>Path/Filename</b>
<input checked="" type="checkbox"/>	Nani Lampung (GH9814) REVIEW OF LITERATURE.doc
<input checked="" type="checkbox"/>	Nani Lampung (GH9814) MATERIALS AND METHODS.doc
<input type="checkbox"/>	<b>Alternative sources</b>
<input type="checkbox"/>	<b>Sources not used</b>

TOPIC: "STRAIN USG ELASTOGRAPHY WITH GRAY SCALE AND COLOUR DOPPLER IMAGING OF THYROID NODULES - EFFICACY COMPARED WITH FNAC."

#### INTRODUCTION

Thyroid nodules are very commonly observed on thyroid ultrasonography. Conventional US has been widely used to determine which nodules should be biopsied. Although conventional US can provide meaningful information in thyroid nodule diagnosis, there has been considerable variation in diagnostic performances. According to the American Thyroid Association guidelines, no single US feature or combination of features is adequately sensitive or specific to identify all malignant nodules. For this reason, fine needle aspiration cytology (FNAC) is required for the nodules with suspicious ultrasound signs. However, FNAC has inherent limitations due to indeterminate and nondiagnostic results. On physical examination, a hard or firm nodule is associated with thyroid malignancy. But, palpation is very subjective and limited in patients with multinodular goiter or small deep-seated nodules. As a consequence, a significant number of patients eventually receive unnecessary thyroid surgery. Therefore, improvement and refinement of noninvasive methods to depict malignancy are needed. In this context, US elastography (USE) has recently been introduced in the clinical workup of thyroid nodules. USE is a US-based technique to assess the biomechanical properties of tissue in the clinical setting. Meanwhile, US-based elastography can provide an objective evaluation of tissue stiffness. There are two kinds of elastography (strain and shear wave elastography) that are currently used in clinical practice. Among

these types of USE, strain USE was the first to be introduced into commercially available systems. Although

## Urkund Analysis Result

**Analysed Document:** K thesis final plagia.docx (D30957106)  
**Submitted:** 10/2/2017 5:04:00 PM  
**Submitted By:** karpagambir2015@gmail.com  
**Significance:** 1 %

Sources included in the report:

Nani Lampung (GH9814) REVIEW OF LITERATURE.doc (D23965494)  
Nani Lampung (GH9814) MATERIALS AND METHODS.doc (D23965497)

Instances where selected sources appear:

6

NAME OF THE PATIENT	AGE	SEX	GRAY SCALE FINDINGS	COLOUR DOPPLER	COLOUR DOPPLER	ELASTOGRAPHY	ELASTOGRAPHY	USG WITH ELASTOGRAPHY	FNAC	FNAC
KANNIYAMMAL	70	F	BENIGN		PERIPHERAL FLOW	PREDOMINANTLY FIRM	BENIGN	BENIGN	NODULAR COLLOID GOITRE	BENIGN
ALAMELU	50	F	BENIGN		PERIPHERAL FLOW	PREDOMINANTLY FIRM	BENIGN	BENIGN	COLOID GOITRE WITH CYSTIC DEGENERATION	BENIGN
LILLY	55	F	INDERMEDIATE		PERIPHERAL AND CENTRAL FLOW	PREDOMINANTLY SOFT	BENIGN	BENIGN	NODULAR COLLOID GOITRE	BENIGN
AMUDHA	36	F	BENIGN		PERIPHERAL AND CENTRAL FLOW	PREDOMINANTLY FIRM	BENIGN	BENIGN	THYROIDITIS	BENIGN
VASU	14	M	BENIGN		PERIPHERAL AND CENTRAL FLOW	PREDOMINANTLY SOFT	BENIGN	BENIGN	THYROIDITIS	BENIGN
SARITHA	27	F	INDERMEDIATE		PERIPHERAL FLOW	PREDOMINANTLY FIRM	BENIGN	BENIGN	COLLOID GOITRE	BENIGN
SAMPOORANAM	35	F	BENIGN		PERIPHERAL FLOW	PREDOMINANTLY FIRM	BENIGN	BENIGN	COLLOID GOITRE	BENIGN
CHITRAKALA	47	F	BENIGN		PERIPHERAL FLOW	PREDOMINANTLY FIRM	BENIGN	BENIGN	NODULAR COLLOID GOITRE	BENIGN
MALARVIZHI	44	F	BENIGN		PERIPHERAL FLOW	PREDOMINANTLY HARD	MALIGNANT	BENIGN	COLOID GOITRE WITH CYSTIC DEGENERATION	BENIGN
KALA	27	F	MALIGNANT		PERIPHERAL AND CENTRAL FLOW	PREDOMINANTLY HARD	MALIGNANT	MALIGNANT	PAPILLARY CARCINOMA	MALIGNANT
MUNIYAMMAL	45	F	BENIGN		PERIPHERAL AND CENTRAL FLOW	PREDOMINANTLY FIRM	BENIGN	BENIGN	NODULAR COLLOID GOITRE	BENIGN
SAVITHA	41	F	BENIGN		PERIPHERAL FLOW	PREDOMINANTLY SOFT	BENIGN	BENIGN	ADENOMATOUS NODULE	BENIGN
MUBINA	58	F	INDERMEDIATE		PERIPHERAL AND CENTRAL FLOW	PREDOMINANTLY FIRM	BENIGN	BENIGN	COLLOID GOITRE WITH THYROIDITIS	BENIGN
MURALIKRISHNA	26	M	INDERMEDIATE		PERIPHERAL AND CENTRAL FLOW	PREDOMINANTLY HARD	MALIGNANT	MALIGNANT	PAPILLARY CARCINOMA	MALIGNANT
VALLIYAMMAL	66	F	INDERMEDIATE		PERIPHERAL AND CENTRAL FLOW	PREDOMINANTLY HARD	MALIGNANT	BENIGN	ADENOMATOUS GOITRE WITH THYROIDITIS	BENIGN
SELVI	34	F	BENIGN		PERIPHERAL FLOW	PREDOMINANTLY FIRM	BENIGN	BENIGN	NODULAR COLLOID GOITRE	BENIGN
KARTHICK	30	M	MALIGNANT		PERIPHERAL AND CENTRAL FLOW	PREDOMINANTLY HARD	MALIGNANT	MALIGNANT	FOLLICULAR NEOPLASM	MALIGNANT
SARALA	42	F	BENIGN		PERIPHERAL FLOW	PREDOMINANTLY FIRM	BENIGN	BENIGN	NODULAR COLLOID GOITRE	BENIGN
BARATHI	35	M	BENIGN		PERIPHERAL AND CENTRAL FLOW	PREDOMINANTLY FIRM	BENIGN	BENIGN	THYROIDITIS	BENIGN
MENAKA	38	F	BENIGN		PERIPHERAL FLOW	PREDOMINANTLY FIRM	BENIGN	BENIGN	NODULAR COLLOID GOITRE	BENIGN
SHAKILA	52	F	INDERMEDIATE		PERIPHERAL AND CENTRAL FLOW	PREDOMINANTLY FIRM	BENIGN	BENIGN	ADENOMATOUS NODULE	BENIGN
MANJULA	47	F	BENIGN		PERIPHERAL FLOW	PREDOMINANTLY FIRM	BENIGN	BENIGN	COLLOID GOITRE	BENIGN
KANMANI	38	F	BENIGN		PERIPHERAL AND CENTRAL FLOW	PREDOMINANTLY FIRM	BENIGN	BENIGN	NODULAR COLLOID GOITRE	BENIGN
KUMARI	40	F	BENIGN		PERIPHERAL FLOW	PREDOMINANTLY FIRM	BENIGN	BENIGN	NODULAR COLLOID GOITRE	BENIGN
DHANALAKSHMI	45	F	BENIGN		PERIPHERAL FLOW	PREDOMINANTLY FIRM	BENIGN	BENIGN	NODULAR COLLOID GOITRE	BENIGN
ELLAMMAL	55	F	BENIGN		PERIPHERAL FLOW	PREDOMINANTLY FIRM	BENIGN	BENIGN	HYPERPLASTIC NODULE	BENIGN

NAME OF THE PATIENT	AGE	SEX	GRAY SCALE FINDINGS	COLOUR DOPPLER	COLOUR DOPPLER	ELASTOGRAPHY	ELASTOGRAPHY	USG WITH ELASTOGRAPHY	FNAC	FNAC
JAYAMANI	35	F	INDERMEDIATE		PERIPHERAL FLOW	PREDOMINANTLY FIRM	BENIGN	BENIGN	NODULAR COLLOID GOITRE	BENIGN
KASI	38	F	BENIGN		PERIPHERAL FLOW	PREDOMINANTLY SOFT	BENIGN	BENIGN	THYROIDITIS	BENIGN
BACKIUM	40	F	BENIGN		PERIPHERAL AND CENTRAL FLOW	PREDOMINANTLY FIRM	BENIGN	BENIGN	ADENOMATOUS NODULE	BENIGN
KANI	44	M	BENIGN		PERIPHERAL FLOW	PREDOMINANTLY FIRM	BENIGN	BENIGN	NODULAR COLLOID GOITRE	BENIGN
MALLIKA	50	F	BENIGN		PERIPHERAL AND CENTRAL FLOW	PREDOMINANTLY SOFT	BENIGN	BENIGN	THYROIDITIS	BENIGN
YOGALAKSHMI	58	F	BENIGN		PERIPHERAL FLOW	PREDOMINANTLY FIRM	BENIGN	BENIGN	NODULAR COLLOID GOITRE	BENIGN
SUSILA	45	F	BENIGN		PERIPHERAL FLOW	PREDOMINANTLY SOFT	BENIGN	BENIGN	NODULAR COLLOID GOITRE	BENIGN
VANI	42	F	BENIGN		PERIPHERAL FLOW	PREDOMINANTLY FIRM	BENIGN	BENIGN	LYMPHOCYTIC THYROIDITIS	BENIGN
VARALAKSHMI	38	F	BENIGN		PERIPHERAL FLOW	PREDOMINANTLY HARD	MALIGNANT	BENIGN	COLOID GOITRE WITH CYSTIC DEGENERATION	BENIGN
SAKTHI	44	M	BENIGN		PERIPHERAL AND CENTRAL FLOW	PREDOMINANTLY FIRM	BENIGN	BENIGN	NODULAR COLLOID GOITRE	BENIGN
KAMALA	50	F	BENIGN		PERIPHERAL FLOW	PREDOMINANTLY FIRM	BENIGN	BENIGN	NODULAR COLLOID GOITRE	BENIGN
VASANTHA	31	F	BENIGN		PERIPHERAL AND CENTRAL FLOW	PREDOMINANTLY FIRM	BENIGN	BENIGN	LYMPHOCYTIC THYROIDITIS	BENIGN
AMBIKA	52	F	BENIGN		PERIPHERAL AND CENTRAL FLOW	PREDOMINANTLY FIRM	BENIGN	BENIGN	HASHIMOTOS THYROIDITIS	BENIGN
PRIYA	39	F	BENIGN		AVASCULAR	PREDOMINANTLY HARD	MALIGNANT	BENIGN	COLOID GOITRE WITH CYSTIC DEGENERATION	BENIGN
YASMIN	42	F	BENIGN		PERIPHERAL FLOW	PREDOMINANTLY FIRM	BENIGN	BENIGN	NODULAR COLLOID GOITRE	BENIGN
HEMALATHA	51	F	BENIGN		PERIPHERAL FLOW	PREDOMINANTLY FIRM	BENIGN	BENIGN	NODULAR COLLOID GOITRE	BENIGN
SURYA	44	F	BENIGN		PERIPHERAL FLOW	PREDOMINANTLY FIRM	BENIGN	BENIGN	NODULAR COLLOID GOITRE	BENIGN
AKILA	43	F	BENIGN		PERIPHERAL FLOW	PREDOMINANTLY FIRM	BENIGN	BENIGN	NODULAR COLLOID GOITRE	BENIGN
JESINTHA	40	F	BENIGN		PERIPHERAL AND CENTRAL FLOW	PREDOMINANTLY FIRM	BENIGN	BENIGN	LYMPHOCYTIC THYROIDITIS	BENIGN
SARANYA	49	F	BENIGN		PERIPHERAL FLOW	PREDOMINANTLY FIRM	BENIGN	BENIGN	NODULAR COLLOID GOITRE	BENIGN
ALLIYAMMAL	38	F	BENIGN		PERIPHERAL FLOW	PREDOMINANTLY FIRM	BENIGN	BENIGN	NODULAR COLLOID GOITRE	BENIGN
SUDHA	55	F	BENIGN		AVASCULAR	PREDOMINANTLY HARD	MALIGNANT	BENIGN	COLOID GOITRE WITH CYSTIC DEGENERATION	BENIGN
THARA	42	F	BENIGN		PERIPHERAL AND CENTRAL FLOW	PREDOMINANTLY FIRM	BENIGN	BENIGN	LYMPHOCYTIC THYROIDITIS	BENIGN
PRABA	53	F	BENIGN		PERIPHERAL FLOW	PREDOMINANTLY FIRM	BENIGN	BENIGN	NODULAR COLLOID GOITRE	BENIGN
NALINI	46	F	BENIGN		PERIPHERAL FLOW	PREDOMINANTLY FIRM	BENIGN	BENIGN	ADENOMATOUS NODULE	BENIGN
FATHIMA	39	F	BENIGN		PERIPHERAL FLOW	PREDOMINANTLY FIRM	BENIGN	BENIGN	NODULAR COLLOID GOITRE	BENIGN

NAME OF THE PATIENT	AGE	SEX	GRAY SCALE FINDINGS	COLOUR DOPPLER	COLOUR DOPPLER	ELASTOGRAPHY	ELASTOGRAPHY	USG WITH ELASTOGRAPHY	FNAC	FNAC
NISHANTHI	42	F	BENIGN		PERIPHERAL FLOW	PREDOMINANTLY FIRM	BENIGN	BENIGN	NODULAR COLLOID GOITRE	BENIGN
RAMYA	55	F	BENIGN		PERIPHERAL AND CENTRAL FLOW	PREDOMINANTLY FIRM	BENIGN	BENIGN	HASHIMOTOS THYROIDITIS	BENIGN
KANNAGI	52	F	BENIGN		PERIPHERAL AND CENTRAL FLOW	PREDOMINANTLY FIRM	BENIGN	BENIGN	NODULAR COLLOID GOITRE	BENIGN
DEEPA	48	F	BENIGN		PERIPHERAL FLOW	PREDOMINANTLY FIRM	BENIGN	BENIGN	NODULAR COLLOID GOITRE	BENIGN
SHAKIRA BANU	50	F	BENIGN		PERIPHERAL FLOW	PREDOMINANTLY FIRM	BENIGN	BENIGN	HYPERPLASTIC NODULE	BENIGN
SHANMUGAVALLI	37	F	BENIGN		PERIPHERAL FLOW	PREDOMINANTLY FIRM	BENIGN	BENIGN	NODULAR COLLOID GOITRE	BENIGN
GAYATHRI	41	F	BENIGN		PERIPHERAL FLOW	PREDOMINANTLY FIRM	BENIGN	BENIGN	NODULAR COLLOID GOITRE	BENIGN
NIRMALA	48	F	BENIGN		PERIPHERAL FLOW	PREDOMINANTLY FIRM	BENIGN	BENIGN	NODULAR COLLOID GOITRE	BENIGN
KALPANA	56	F	BENIGN		PERIPHERAL FLOW	PREDOMINANTLY FIRM	BENIGN	BENIGN	NODULAR COLLOID GOITRE	BENIGN
ARCHANA	44	F	BENIGN		AVASCULAR	PREDOMINANTLY HARD	MALIGNANT	BENIGN	COLOID GOITRE WITH CYSTIC DEGENERATION	BENIGN
LAKSHMI	63	F	BENIGN		PERIPHERAL FLOW	PREDOMINANTLY SOFT	BENIGN	BENIGN	NODULAR COLLOID GOITRE	BENIGN
VINOTHINI	41	F	BENIGN		PERIPHERAL FLOW	PREDOMINANTLY FIRM	BENIGN	BENIGN	NODULAR COLLOID GOITRE	BENIGN
MARYAMMAL	59	F	BENIGN		PERIPHERAL FLOW	PREDOMINANTLY FIRM	BENIGN	BENIGN	NODULAR COLLOID GOITRE	BENIGN
VADIVU	38	F	BENIGN		PERIPHERAL FLOW	PREDOMINANTLY FIRM	BENIGN	BENIGN	NODULAR COLLOID GOITRE	BENIGN
VALLI	49	F	BENIGN		AVASCULAR	PREDOMINANTLY HARD	MALIGNANT	BENIGN	COLOID GOITRE WITH CYSTIC DEGENERATION	BENIGN
MAHESWARI	53	F	BENIGN		PERIPHERAL FLOW	PREDOMINANTLY SOFT	BENIGN	BENIGN	ADENOMATOUS NODULE	BENIGN
PUSPHA	47	F	BENIGN		PERIPHERAL FLOW	PREDOMINANTLY SOFT	BENIGN	BENIGN	NODULAR COLLOID GOITRE	BENIGN
LATHA	40	F	BENIGN		PERIPHERAL FLOW	PREDOMINANTLY FIRM	BENIGN	BENIGN	COLLOID GOITRE	BENIGN
ANDAL	54	F	BENIGN		AVASCULAR	PREDOMINANTLY HARD	MALIGNANT	BENIGN	COLOID GOITRE WITH CYSTIC DEGENERATION	BENIGN
KRISHNAMMAL	61	F	INDERMEDIATE		PERIPHERAL FLOW	PREDOMINANTLY FIRM	BENIGN	BENIGN	COLLOID GOITRE	BENIGN
SIVAKOLUNDHU	58	F	BENIGN		PERIPHERAL FLOW	PREDOMINANTLY FIRM	BENIGN	BENIGN	COLLOID GOITRE	BENIGN
THULASI	35	F	BENIGN		PERIPHERAL FLOW	PREDOMINANTLY FIRM	BENIGN	BENIGN	COLLOID GOITRE	BENIGN
RADHA	38	F	BENIGN		PERIPHERAL AND CENTRAL FLOW	PREDOMINANTLY FIRM	BENIGN	BENIGN	HASHIMOTOS THYROIDITIS	BENIGN
KALA	43	F	BENIGN		AVASCULAR	PREDOMINANTLY HARD	MALIGNANT	BENIGN	COLOID GOITRE WITH CYSTIC DEGENERATION	BENIGN
PREMA	33	F	BENIGN		PERIPHERAL AND CENTRAL FLOW	PREDOMINANTLY FIRM	BENIGN	BENIGN	LYMPHOCYTIC THYROIDITIS	BENIGN
DEVI	48	F	BENIGN		PERIPHERAL AND CENTRAL FLOW	PREDOMINANTLY SOFT	BENIGN	BENIGN	HYPERPLASTIC NODULE	BENIGN



NAME OF THE PATIENT	AGE	SEX	GRAY SCALE FINDINGS	COLOUR DOPPLER	COLOUR DOPPLER	ELASTOGRAPHY	ELASTOGRAPHY	USG WITH ELASTOGRAPHY	FNAC	FNAC
POOCHENDU	47	F	BENIGN		PERIPHERAL FLOW	PREDOMINANTLY FIRM	BENIGN	BENIGN	COLLOID GOITRE	BENIGN
JAYAMMAL	62	F	BENIGN		PERIPHERAL FLOW	PREDOMINANTLY FIRM	BENIGN	BENIGN	COLLOID GOITRE	BENIGN
SRIDEVI	38	F	BENIGN		PERIPHERAL FLOW	PREDOMINANTLY FIRM	BENIGN	BENIGN	HYPERPLASTIC NODULE	BENIGN
VASINI	41	F	BENIGN		PERIPHERAL FLOW	PREDOMINANTLY FIRM	BENIGN	BENIGN	HYPERPLASTIC NODULE	BENIGN
SEKAR	45	F	BENIGN		PERIPHERAL FLOW	PREDOMINANTLY FIRM	BENIGN	BENIGN	COLLOID GOITRE	BENIGN
AYISHA	42	F	BENIGN		PERIPHERAL FLOW	PREDOMINANTLY SOFT	BENIGN	BENIGN	COLLOID GOITRE	BENIGN
KALAIVANI	52	F	BENIGN		PERIPHERAL FLOW	PREDOMINANTLY FIRM	BENIGN	BENIGN	COLLOID GOITRE	BENIGN
CHELLAMMAL	55	F	BENIGN		PERIPHERAL FLOW	PREDOMINANTLY FIRM	BENIGN	BENIGN	LYMPHOCYTIC THYROIDITIS	BENIGN
ARUNA	49	F	BENIGN		AVASCULAR	PREDOMINANTLY HARD	MALIGNANT	BENIGN	COLOID GOITRE WITH CYSTIC DEGENERATION	BENIGN
NEELAVENI	46	F	BENIGN		PERIPHERAL AND CENTRAL FLOW	PREDOMINANTLY FIRM	BENIGN	BENIGN	HYPERPLASTIC NODULE	BENIGN
LATHA	52	F	BENIGN		PERIPHERAL FLOW	PREDOMINANTLY FIRM	BENIGN	BENIGN	COLLOID GOITRE	BENIGN
AARTHI	39	F	BENIGN		PERIPHERAL FLOW	PREDOMINANTLY FIRM	BENIGN	BENIGN	COLLOID GOITRE	BENIGN
SARASU	57	F	BENIGN		PERIPHERAL FLOW	PREDOMINANTLY FIRM	BENIGN	BENIGN	HYPERPLASTIC NODULE	BENIGN
SINDHU	34	F	BENIGN		PERIPHERAL AND CENTRAL FLOW	PREDOMINANTLY FIRM	BENIGN	BENIGN	LYMPHOCYTIC THYROIDITIS	BENIGN
JANAKI	61	F	BENIGN		PERIPHERAL FLOW	PREDOMINANTLY FIRM	BENIGN	BENIGN	HYPERPLASTIC NODULE	BENIGN
KOTHAI NAYAKI	55	F	INDERMEDIATE		PERIPHERAL FLOW	PREDOMINANTLY FIRM	BENIGN	BENIGN	COLOID GOITRE	BENIGN
RAJALAKSHMI	54	F	BENIGN		PERIPHERAL FLOW	PREDOMINANTLY FIRM	BENIGN	BENIGN	COLLOID GOITRE	BENIGN
JULIET	39	F	BENIGN		PERIPHERAL FLOW	PREDOMINANTLY SOFT	BENIGN	BENIGN	COLLOID GOITRE	BENIGN
MADHAVI	36	F	BENIGN		PERIPHERAL FLOW	PREDOMINANTLY FIRM	BENIGN	BENIGN	COLLOID GOITRE	BENIGN
SUGANDHI	44	F	BENIGN		PERIPHERAL FLOW	PREDOMINANTLY FIRM	BENIGN	BENIGN	HYPERPLASTIC NODULE	BENIGN
MANGAI	47	F	BENIGN		PERIPHERAL FLOW	PREDOMINANTLY FIRM	BENIGN	BENIGN	COLLOID GOITRE	BENIGN
MALARKODI	52	F	BENIGN		PERIPHERAL FLOW	PREDOMINANTLY FIRM	BENIGN	BENIGN	HYPERPLASTIC NODULE	BENIGN

NONE OF THE PEAK SYSTOLIC FLOW VELOCITIES EXCEEDS 70 CM/SEC, VELOCITIES EXCEED 70 CM/S

## ஆராய்ச்சி தகவல்தாள்

சென்னை அரசு பொது மருத்துவமனைக்கு வரும் நோயாளிகளிடம் இருக்கும் தைராய்டுகட்டிகளைப் பற்றிய ஒரு ஆராய்ச்சி இங்கு நடைபெற்றுவருகின்றது.

தைராய்டுகட்டிகளிலேயே பற்பல வகைகள் உண்டு. அந்தகட்டிகளை சில சிறப்புப் பரிசோதனைகளின் மூலம் எளிதில்கண்டுபிடித்து ஆராய முடியும் என்பதே இந்த ஆராய்ச்சியின் நோக்கமாகும்.

நீங்களும் இந்த ஆராய்ச்சியில் பங்கேற்க நாங்கள் விரும்புகிறோம். இந்த ஆராய்ச்சியில் உங்களுடைய திசுக்களை எடுத்து சில சிறப்புப் பரிசோதனைக்கு உட்படுத்தி அதன்தகவல்களை ஆராய்வோம். அதனால்தங்களது நோயின் ஆய்வறிக்கையோ அல்லது சிகிச்சையோ பாதிப்புக்குள்ளாகாது என்பதையும் தெரிவித்துக்கொள்கிறோம்.

முடிவுகளை அல்லது கருத்துகளை வெளியிடும் போதோ அல்லது ஆராய்ச்சியின் போதோ தங்களது பெயரையோ அல்லது அடையாளங்களையோ வெளியிட மாட்டோம் என்பதையும் தெரிவித்துக்கொள்கிறோம்.

இந்த ஆராய்ச்சியில் பங்கேற்பது தங்களுடைய விருப்பத்தின் பேரில் தான் இருக்கிறது. மேலும் நீங்கள் எந்நேரமும் இந்த ஆராய்ச்சியில் இருந்து பின்வாங்கலாம் என்பதையும் தெரிவித்துக்கொள்கிறோம்.

இந்த சிறப்புப் பரிசோதனைகளின் முடிவுகளை ஆராய்ச்சியின் போது அல்லது ஆராய்ச்சியின் முடிவின் போது தங்களுக்கு அறிவிப்போம் என்பதையும் தெரிவித்துக்கொள்கிறோம்.

ஆராய்ச்சியாளர் கையொப்பம்

பங்கேற்பாளர் கையொப்பம்

தேதி :

## ஆராய்ச்சி ஒப்புதல்கடிதம்

ஆராய்ச்சி தலைப்பு : அல்ட்ராசவுண்ட் பரிசோதனை மூலம் தைராய்டுகட்டிகளின் வகைகளைகண்டறிதல் பற்றிய ஆய்வு

பெயர் :

தேதி :

வயது :

உள் நோயாளிஎண் :

பால் :

ஆராய்ச்சி சேர்க்கைஎண் :

இந்தஆராய்ச்சியின் விவரங்களும் அதன் நோக்கங்களும் முழுமையாக எனக்கு தெளிவாக விளக்கப்பட்டது.

எனக்கு விளக்கப்பட்டவிஷயங்களை நான் புரிந்து கொண்டு நான்எனது சம்மதத்தைத்தெரிவிக்கிறேன்.

இந்தஆராய்ச்சியில் பிறரின் நிர்ப்பந்தமின்றிஎன் சொந்த விருப்பத்தின் பேரில் தான் பங்கு பெறுகிறேன் மற்றும் நான்இந்தஆராய்ச்சியிலிருந்து எந்நேரமும் பின்வாங்கலாம் என்பதையும் அதனால்எந்த பாதிப்பும் ஏற்படாது என்பதையும் நான் புரிந்து கொண்டேன்.

நான்தைராய்டுகட்டி நோய்கள்குறித்தஇந்தஆராய்ச்சியின் விவரங்களைக்கொண்டதகவல்தாளைப் பெற்றுக்கொண்டேன்.

நான்என்னுடைய சுயநினைவுடன் மற்றும் முழு சுதந்திரத்துடன்இந்த மருத்துவஆராய்ச்சியில் என்னை சேர்த்துக்கொள்ள சம்மதிக்கிறேன்.

எனக்கு தைராய்டுஅல்ட்ராசவுண்ட் பரிசோதனை மற்றும் நுண் ஊசி சதை பரிசோதனைசெய்து கொள்ள சம்மதம் தெரிவிக்கிறேன்.

கையொப்பம்