

**A DISSERTATION ON**

**CLINICAL STUDY ON ABDOMINAL TUBERCULOSIS AND  
ITS EMERGENCIES**

*Submitted to*

**The Tamil Nadu Dr.M.G.R. Medical University**

*In fulfillment of the regulations for  
the award of degree of*

**M.S., DEGREE EXAMINATION  
BRANCH –I M.S., (GENERAL SURGERY)**



**GOVT.KILPAUK MEDICAL COLLEGE**

**THE TAMILNADU DR. M.G.R. MEDICAL UNIVERSITY**

**CHENNAI**

**APRIL 2014**

## **BONAFIDE CERTIFICATE**

This is to certify that the dissertation entitled “**CLINICAL STUDY  
IN ABDOMINAL TUBERCULOSIS AND ITS EMERGENCIES**” is a  
Bonafide record of work done by **DR. B. ASHOK KUMAR** in the  
Department of General Surgery, Government Kilpauk Medical College &  
Hospital, Chennai-10.

**PROF.P.N.SHANMUGASUNDARAM M.S.**

HEAD OF THE DEPARTMENT,

DEPT OF GENERAL SURGERY,

GOVT KILPAUK MEDICAL COLLEGE

CHENNAI-10.

**PROF.P.RAMAKRISHNAN M.D.DLO**

DEAN,

GOVT KILPAUK MEDICAL COLLEGE

CHENNAI-10.

## DECLARATION

I, **Dr. B.ASHOK KUMAR**, solemnly declare that this dissertation, titled **“CLINICAL STUDY ON ABDOMINAL TUBERCULOSIS AND ITS EMERGENCIES”** is a bonafide record of work done by me in the Department of General Surgery, Government Kilpauk Medical College, Chennai-10, during the period from July 2011 to Jun 2013 under the Guidance of my Unit Chief Prof.P.N. SHANMUGASUNDARAM M.S., Government Kilpauk Medical College Hospital, Chennai-600 010.

This dissertation is submitted to the Tamil Nadu Dr.M.G.R. Medical University, Chennai in fulfillment of the University regulations for the award of M.S. (General Surgery) Branch I, General Surgery Examination to be held in APRIL, 2014

Place: Chennai

Date:

(DR. B.ASHOK KUMAR)

## CERTIFICATE BY THE GUIDE

This is to certify that the dissertation titled” **CLINICAL STUDY ON ABDOMINAL TUBERCULOSIS AND ITS EMERGENCIES**” is a bonafide work done by **DR. B.ASHOK KUMAR**, post graduate in M.S. General Surgery, Kilpauk Medical College.Chennai-10 under my direct guidance and supervision to my satisfaction, in partial fulfillment of the requirements for the degree of **M.S. General Surgery**.

Date: PROF.P.N.SHANMUGASUNDARAM M.S.

Place: Professor & Head of the Department  
Department of general surgery  
Govt Kilpauk Medical College & Hospital  
Chennai-10.

## ACKNOWLEDGEMENT

I wish to express my sincere gratitude and thanks to **Prof. P. N. SHANMUGASUNDARAM, M.S.**, Professor & Head of the Department of General Surgery for having helped me at every step in completing this study successfully.

I also wish to express my sincere thanks to my Assistant Professors **DR. B. SATHYA PRIYA, DR.V.KOPPERUNDEVI, DR.K.SRIDEVI, DR. SELLADURAI, DR.MATHUSOOTHANAN** for helping me to complete this study.

I also thank **Professor and Head of the department of Pathology** and all other teachers who helped me to do this study in time.

I am also very grateful to our **Dean PROF.P.RAMAKRISHNAN, M.D., DLO**, for his permission to utilize the clinical material for this study.

I also extend my thanks to all my patients for their full co- operation in successful completion of this study.

## **CONTENTS**

	<b>PAGE NO</b>
<b>(1) INTRODUCTION</b>	<b>1</b>
<b>(2) AIMS OF STUDY</b>	<b>4</b>
<b>(3) REVIEW OF LITERATURE</b>	<b>6</b>
<b>(4) MATERIALS AND METHODS</b>	<b>55</b>
<b>(5) OBSERVATIONS AND ANALYSIS</b>	<b>57</b>
<b>(6) DISCUSSION</b>	<b>67</b>
<b>(7) CONCLUSION</b>	<b>73</b>
<b>(8) ANNEXURES</b>	
<b>(a) BIBLIOGRAPHY</b>	<b>81</b>
<b>(b) PROFORMA</b>	<b>88</b>
<b>(c) MASTER CHART</b>	<b>99</b>

## ABSTRACT

### CLINICAL STUDY ON ABDOMINAL TUBERCULOSIS AND ITS EMERGENCIES.

#### BACKGROUND AND OBJECTIVES:

Abdominal tuberculosis is sixth most common type of extra pulmonary tuberculosis. Abdominal tuberculosis denotes tuberculosis infection of gastrointestinal tract, peritoneum, lymph nodes, and solid organs i.e. spleen, liver, and pancreas. The diagnosis is usually delayed due to non specific symptoms and signs. The clinical study of abdominal tuberculosis was conducted with the aim to evaluate the incidence of abdominal tuberculosis, various sites of presentation, incidence of surgical emergencies due to abdominal tuberculosis.

#### MATERIALS AND METHODS:

The study was conducted in the Department of General surgery in Government Kilpauk medical college Hospital and Government Royapettah Hospital between July 2011- June 2013. 50 patients were included in the study. Data were collected from all patients. Patient's age and sex were noted. Detailed history was obtained. Thorough clinical examination was performed. Every patient had chest x-ray and abdominal x-ray. CT abdomen was performed in inconclusive cases. Tissue diagnosis by histopathological examination had proven positive for all patients. The details of all the patients were collected and analyzed.

#### RESULTS:

Abdominal tuberculosis mostly occurred in the middle age group (21- 40 years). The most common presenting symptoms are abdominal pain and abdominal tenderness is the most common sign elicited. Ileocaecal region is the most commonly affected region in the abdominal tuberculosis. About 26% of patients had associated pulmonary tuberculosis. Surgery is usually indicated in patients with complications of abdominal tuberculosis. The most common surgical

emergency is intestinal obstruction due to either ileocaecal mass or stricture followed by perforation. Limited bowel resection and anastomosis was mostly commonly performed surgery in abdominal tuberculosis followed by adhesiolysis and band release is the most common procedure performed. All the patients are started on anti tuberculous therapy. Anti- tubercular treatment still forms the mainstay of treatment. All patients started on category I anti tubercular treatment.

**KEY WORDS:** abdominal tuberculosis, abdominal pain, intestinal obstruction, limited bowel resection and anastomosis.



# ***INTRODUCTION***

## INTRODUCTION

Abdominal tuberculosis is sixth most common type of extra pulmonary tuberculosis.[1] Abdominal tuberculosis denotes tuberculosis infection of gastrointestinal tract, peritoneum, lymph nodes, and solid organs i.e. spleen, liver, and pancreas.[2]..

Abdominal tuberculosis is a major public health problem in developing countries. The incidence of abdominal tuberculosis is increasing due to increasing incidence of AIDS[3].. it may mimics other gastrointestinal lesions like inflammatory bowel disease, malignancies. The diagnosis is usually delayed due to non specific symptoms and signs.

Abdominal tuberculosis continues to be major cause of mortality and morbidity in our country. We observed the various presentations of abdominal tuberculosis in our hospital and analyzed the pathology in present scenario.

The study was conducted in the Department of general surgery IN  
GOVT KILPAUK MEDICAL COLLEGE AND HOSPITAL AND  
GOVT ROYAPETTAH HOSPITAL BETWEEN JUNE 2011 TO JUNE  
2013.

# AIM OF STUDY

## AIM OF STUDY

1. To study various clinical presentations of abdominal tuberculosis.
2. To study sex and age distribution.
3. To study the site distribution.
4. To study the complications of abdominal tuberculosis.
5. To study incidence of abdominal tuberculosis presenting as acute emergencies.
6. To study the most common surgeries performed in abdominal tuberculosis.

# **REVIEW OF LITERATURE**

## **REVIEW OF LITERATURE**

### **HISTORY:**

Tuberculosis is an ancient disease. There are evidence of spinal tuberculosis found in some Egyptian mummies. Tubercle bacillus DNA has been detected in mummies dated 1550-1080 BC. Susruta, famous Indian surgeon described about tuberculosis that the disease was difficult to cure as early as in 3000 BC. Hippocrates who called tuberculosis stated that treatment for TB was a waste of time and those patients were burden to society.

Description of tuberculosis of gut, mesenteric, nodal and perforation of gut was given by Rokitansky in 1845. The term tubercle was first employed by Francis Sylvan of Leyden (1614-1672). It was Virchow (1821-1902) who described development of caseation in tuberculous tissue .

Robert Koch, on 24th march 1882, cultured and reproduced mycobacterium tuberculosis. This not only facilitated the definitive diagnosis but also for the development of anti tubercular drugs.

In 1911, Edward and sterlin first described the use of X-rays in intestinal tuberculosis. In 1940, Crohn and Yarns and found the existence of hyper plastic tuberculosis with the help of barium studies.

Chemotherapy for tuberculosis became possible with the noble price winning discovery of drug streptomycin in mid 1940s. Because of lower degree of efficacy and resistance to first line of drugs, second line of drugs are used.

### ***EPIDEMIOLOGY:***

Approximately one third of world population is infected with tuberculosis. 3 million deaths occur every year due to tuberculosis. In spite of increased health standards, it is increasing due to increasing incidence of HIV infection, an aging population, emergence of multi-resistant strains of Mycobacterium tuberculosis.

Extra pulmonary TB accounts for 1-3% of total tuberculosis, of which abdominal tuberculosis accounts for 11-16% in non- HIV patients. In HIV patients, incidence is upto 50%. [4]. Gastrointestinal TB is sixth most frequent form of extra pulmonary TB.

Abdominal tuberculosis is most commonly seen in young adults. The peritoneal and nodal form is more common in children. Patient usually



presents with non specific symptoms and signs and may mimic any intra abdominal disease. Therefore a high index of suspicion is needed for an early diagnosis and timely management.

In Abdominal tuberculosis , patient may present with chronic abdominal pain or acute surgical emergencies compelling exploratory laparotomy. Patient may present with ileocaecal mass. The constitutional symptoms such as low grade fever, malaise, night sweats, anemia and weight loss present in only one-third of patient with abdominal tuberculosis.

In 1953, Wig and Bawa emphasized intestinal tuberculosis is the commonest granulomatous lesion and Crohn's disease is rare. In 1998, Wang H.S. et al study showed that rise in intestinal tuberculosis may be due to increased life expectancy, reappearance of formerly silent tuberculosis and relapse in patients who received incomplete antituberculous therapy.

Due to increasing incidence of HIV infection, both the incidence and severity of abdominal tuberculosis are rising. In a study from Mumbai, HIV seroprevalence was found in 16.6 % of abdominal tuberculosis patients. [5].

### ***PATHOGENESIS:***

Mycobacterium tuberculosis causes the abdominal tuberculosis. Abdominal tuberculosis may also occur by drinking milk contaminated with M.bovis. The mode of infection is by direct inhalation of aerosolized bacilli contained in droplet nuclei of expectorated sputum.[6].

**MICROBIOLOGY:** Mycobacterium tuberculosis is an obligatory aerobic, non motile, rod shaped bacterium which stains by gram stain. Mycobacterium tuberculosis is acid and alcoholic fast by ziele-nielsen technique.

The solid medium most widely used for culture is Lowenstein-Jensen medium without starch, as recommended by International union against Tuberculosis(IUAT). This consists of coagulated hens eggs, mineral salts solution, asparagine and malachite green which inhibits other bacteria. It requires incubation period of 4-6 weeks. Liquid culture medium is more sensitive than solid medium and provide faster results.

The basis for virulence of organism is not clearly understood. It seems to be related to their ability to survive and multiply in macrophages. The key cell is the activated CD4+ helper T cells which can develop along two different paths- the Th-1 and Th-2 cells. Th-1 dependent

cytokines activates macrophages resulting in protective immunity and containment of infection. Th-2 cytokines induce delayed hypersensitivity, tissue destruction and progressive disease.

***ROUTE OF INFECTION:***

The mechanisms by which the mycobacterium tuberculosis reaches the abdomen are;

1. Spread through hematogenous route from active primary focus in lung.
2. By means of ingestion of infected sputum from active pulmonary focus.
3. Spread from surrounding organs. (Esophageal spread from mediastinal TB lymphadenopathy).
4. Spread by lymphatic channels from infected lymph nodes.
5. From Fallopian tubes by retrograde spread to involve peritoneum.

### ***PATHOLOGIC FINDINGS:***

The essential pathology is production of a characteristic lesion, the tubercle. Tubercle is an avascular granuloma. It composed of a central zone and peripheral zone. Central zone contains giant cells, with or without caseation and a peripheral zone of lymphocytes and fibroblasts.

Tuberculous granuloma are initially formed in the mucosa or Peyer's patches. Granulomas are mainly in the sub mucosal layer and are seen just beneath the ulcer bed. Tubercular ulcers are relatively superficial and do not penetrate beyond muscularis layer.[7]. They are usually transverse oriented ulcer (girdle ulcer). Healing of these ulcers results in strictures. Stricture may also produced by ischemia due to occlusive arterial changes.[8]. Some sections may not show granuloma but only chronic inflammation.

## ***PATHOLOGY:***

### **GASTROINTESTINAL TUBERCULOSIS:**

Tuberculosis may involve any region of gastrointestinal tract from mouth to anus. Hoon et al[7] classified the involved bowel based on gross morphological appearance into

1. Ulcerative
2. Ulcerohyperplastic
3. Hyperplastic varieties.

### **ULCERATIVE FORM:**

It usually occur secondary to pulmonary tuberculosis. It is seen in 60% of patients. It is highly active form. It is seen in old age individual with poor body resistance. Multiple transverse ulcers are seen commonly in the ileum. Patient usually presents with diarrhea, bleeding PR, loss of weight, loss of appetite.

It is usually due to deprivation of blood supply as a result of end arteritis. During the process of healing , accumulation of collagen

tissues occurs and subsequent circumferential stricture of the lumen(NAPKIN RING) leading to obstruction, perforation, fistula formation.

#### **HYPERTROPHIC FORM:**

It is usually primary GIT tuberculosis. It is seen in approximately 10% of patients. It is less virulent form. The patients are usually young individuals with good resistance. Ileocaecal area and colon are usually involved. There will be inflammatory fibroelastic reaction in the sub mucosa and sub serosa. The patient presents with abdominal mass because the mesentry, bowel, and lymph nodes are matted together due to adhesions. Barium study will show pulled up caecum, obtuse ileocaecal angle.

#### **ULCERO-HYPERTROPHIC FORM:**

It is seen in 30% of patients. Patient will have features of both ulcerative and hypertrophic form. It usually features as ulcers, nodularity, pseudo polyp, hyperplasia and stenosis.

### ***PERITONEAL TUBERCULOSIS:***

There will be enormous thickening of parietal peritoneum with multiple tiny yellowish tubercles. Multiple dense adhesions between bowel loops and bowel and peritoneum and omentum. Dense adhesions in peritoneum and omentum with content inside as small bowel looking like abdominal cocoon.

It may occur in three forms:

1. Wet type (ascites)
2. Encysted (loculated ) type and
3. Fibrotic type with abdominal masses due to mesenteric and omental thickening, with matted bowel loops.

Sometimes, combination of all three types can occur.

### **TYPES:**

1. Acute type- mimics acute abdomen.
2. Chronic tubercular peritonitis.

### **ACUTE TYPE:**

Patient may present with symptoms resembling acute abdomen and such patients are usually subjected to emergency surgery. On

opening the abdomen, straw- coloured fluid with tubercles in the peritoneum, greater omentum and bowel wall will be seen. Fluid should be collected for AFB stain and culture.

#### CHRONIC TUBERCULAR PERITONITIS:

Patient usually presents with abdominal pain, fever, ascites, loss of weight and loss of appetite, abdominal mass. Multiple tubercles presents in the peritoneum and omentum is thickened, fibrosed and rolled up. Tuberculosis may reach the peritoneum from mesenteric lymph nodes, ileocaecal tuberculosis, from fallopian tubes. Chronic tuberculosis may occur in three varieties.

1. Ascitic form
2. Encysted (loculated form)
3. Fibrous type.

#### ASCITIC FORM:

It has insidious onset mode of presentation. Patient usually presents with abdominal distension and abdominal pain is usually absent. male child may presents with congenital hydrocele due to processus vaginalis filled with ascitic fluid. On examination, abdomen distended with dilated veins, rolled up omentum may be felt as abdominal mass and



umbilical herniation due to increased abdominal pressure may be seen. On ascetic fluid tapping, straw coloured fluid will be aspirated from which AFB can be isolated.

#### ENCYSTED (LOCULATED FORM):

Patient presents with localized abdominal swelling. Ascites get loculated because of fibrinous deposition. They may presents with intra abdominal mass mimicking ovarian cyst, retroperitoneal cyst or mesenteric cyst. Intestinal obstruction may develop late in the course of disease.

#### FIBROUS TYPE:

There will be widespread adhesions between the intestine(commonly ileum),abdominal wall, omentum leading to blind loop, malabsorption, intestinal obstruction. Patient presents with recurrent abdominal pain, diarrhea, wasting and doughy abdomen. They respond well to drug treatment.

#### TUBERCULOUS MESENTERIC LYMPHADENITIS:

Patient usually presents with general symptoms (fever, malaise, weight loss). Patient presents with pain in umbilical region and right

iliac fossa mass which is usually matted, nonmobile. Infection to lymph nodes is usually through the Peyer's patches of intestine. Commonly right side group of lymph nodes are involved. Pseudomesenteric cyst may be formed due to collection of caseating material between the layers of the mesentery. Tabes mesenterica is nothing but the massively enlarged mesenteric lymph nodes due to tuberculosis.

#### TUBERCULOSIS OF SOLID ORGANS:

##### SPLENIC TUBERCULOSIS:

Patient presents with hypersplenism or splenic abscess or rarely as solitary splenic tumour[9]. The most common features are fever, left upper quadrant abdominal pain and tenderness. In HIV patients, the multiple hypo echoic lesion in ultrasound is suggestive of disseminated tuberculosis. Preoperatively it is difficult to diagnose and diagnosis is usually made following histopathological examination.

## HEPATIC TUBERCULOSIS:

Hepatic tuberculosis is rare these days. They are typically granulomatous lesion with or without central caseating necrosis, calcified masses, and biliary strictures. It is an incidental finding during laparotomy or in autopsy of immunocompromised individuals.

## PANCREATIC TUBERCULOSIS:

Pancreatic tuberculosis rarely occurs. It occurs more frequently in immunocompromised individuals[10] and often associated with military tuberculosis. Pancreatic tuberculosis is often the result of hematogenous spread or direct spread from adjacent organs. The clinical manifestation depends on the extent of disease. Patient presents with anorexia, low grade fever, weight loss, night sweats, pancreatic mass or abscess or obstructive jaundice. Patient may presents as acute or chronic pancreatitis[11,12]. It is difficult to diagnose and conformation of diagnosis not possible even during surgery. Tuberculosis may be differentiated from carcinoma, lymphoma, sarcoidosis by fine needle aspiration cytology and biopsy.

## CLINICAL FEATURES:

Any patient presenting with abdominal lump, ascites, intestinal obstruction or peritonitis, possibility of abdominal tuberculosis should be considered. Patient usually present with non specific symptoms and may mimic other conditions like inflammatory bowel disease, malignancy. Abdominal tuberculosis is common in young adults. Around two- third of patients are in the age group of 21- 40 yr old. Both male and female are equally affected. Most of the affected patients belong to lower socioeconomic status because of overcrowding, poor sanitation and malnutrition.

## SYMPTOMS:

Symptoms usually depend upon the nature, site and extent of lesion.

<b>SYMPTOMS</b>	<b>PERCENTAGE</b>
ABDOMINAL PAIN	86%
VOMITING	46%
ABDOMINAL DISTENSION	37%
ASCITES	37%
ABDOMINAL MASS	33%
DIARRHEA	22%
CONSTIPATION	24%
HAEMATOCHYZIA	4%

#### 1. ABDOMINAL PAIN:

The most common presenting symptom is abdominal pain and almost present in all patient. It is colicky in intestinal type and dull in mesenteric type. The pain is most commonly located in the right lower quadrant. The colicky type of pain is particularly present in patient with intestinal obstruction.

#### 2. DIARRHOEA:

It is other most common symptom and mostly presents in patients with ulcerative type of tuberculosis.

#### 3. ABDOMINAL DISTENSION:

Patient may present with localized or generalized abdominal distension as seen in ascites, intestinal obstruction.

#### 4. ABDOMINAL MASS:

Patient may present with abdominal mass. It is usually seen in ileocaecal tuberculosis and peritoneal tuberculosis due to rolled up omentum.

#### 5. LOSS OF WEIGHT AND APPETITE:

It presents in about 80% of patients.

#### 6. VOMITING:

It usually suggests intestinal obstruction which may be acute, chronic or acute on chronic.

#### 7. BORBORYGMI:

It usually suggests intestinal luminal compromise.

8. ALTERNATE CONSTIPATION AND DIARRHEA may occur in sub acute intestinal obstruction.

#### 9. BLEEDING:

Bleeding per rectum may occur in colonic or rectal tuberculosis.

#### 10. FEVER:

It presents in 50-70% of patients.

#### SIGNS:

#### GENERAL EXAMINATION:

Most of the patients are malnourished. Patient may present with pallor and lymph node involvement.

## ABDOMINAL EXAMINATION:

Abdomen may be distended or normal. Tenderness may present in right lower quadrant. Mass may be palpable in right iliac fossa due to ileocaecal tuberculosis or due to rolled up omentum in peritoneal tuberculosis. Shifting dullness and fluid thrill may present in patient with ascitis. Rectal examination may reveal fistula, strictures, and fissures. Depending on the site, nature and extent of involvement, patient may present with different types of clinical features.

## OESOPHAGEAL TUBERCULOSIS:

Oesophageal tuberculosis is rare. It accounts for only 0.2% percent of cases of abdominal tuberculosis. [13]. Oesophagus may get involved mainly by extension of disease from thorax mostly from mediastinal lymph nodes and also from lungs or spine. The most common presenting symptoms are difficulty in swallowing and odynophagia. Mid oesophageal ulcers are common. Oesophageal TB may mimic oesophageal carcinoma.[14] In miliary spread from primary TB, a rare form of granular TB may occur in oesophagus.

## GASTRODUODENAL TUBERCULOSIS:

Both stomach and duodenal tuberculosis accounts for 1% of cases of abdominal tuberculosis. It is mostly misdiagnosed as peptic ulcer disease and does not respond to anti-secretory drugs.[15]. It may also mimic carcinoma of stomach. In a largest series of study on duodenal obstruction from India[16], most patients(73%) presented with symptoms of duodenal obstruction. In most of the cases, the obstruction is due to external compression by tuberculous lymph nodes. Other (27%) patients had history of dyspepsia. Two patients presented with hematemesis[16].other complications are perforation, fistulae,[17] excavating ulcers extending into pancreas and obstructive jaundice by compression of common bile duct.

In 80% of duodenal tuberculosis patient, there are no associated pulmonary lesions. Segmental narrowing may be seen in barium studies. It is difficult to demonstrate acid fast bacilli in endoscopy biopsy material. Majority of cases of obstruction requires surgical bypass, but there are studies about successful endoscopic balloon dilatation in obstruction.[18].



## SEGMENTAL COLONIC TUBERCULOSIS:

It constitutes 9.2 % of cases of abdominal tuberculosis. In segmental colonic tuberculosis, colon is involved without involvement of ileocaecal region. The sigmoid colon, ascending and transverse colon are commonly involved [19]. One third of patients presents with multifocal involvement. About 78-90% of patients presents with pain and less than one third of patients presents with hematochezia[20].

In a study by Singh et al, rectal bleeding was reported in 31% of patients and it is massive in 13% of patients[21]. About 4% of patients with lower gastrointestinal bleeding are due to tuberculosis [24]. Fever, anorexia, weight loss and change with bowel habits are other manifestations of colonic tuberculosis. Barium enema and colonoscopy may aid in diagnosis.

## ILEOCAECAL TUBERCULOSIS:

Ileocaecal region is the most common site of abdominal tuberculosis.

It is most commonly involved due to

1. Stasis of luminal content
2. Minimal digestive activity
3. Presence of Peyer's patches
4. Increased rate of fluid and electrolyte absorption.

Patients usually presents with colicky abdominal pain, vomiting and borborygmi. About 35% of patients presents with firm, mobile, palpable mass in right lower quadrant.

Obstruction is the most common complication of ileocaecal tuberculosis. Obstruction is usually due to luminal narrowing by ileocaecal tuberculosis, by strictures or by adhesions. Tuberculosis accounts for about 3-20% of cases of bowel obstruction in India [25]. In a case series of 348 cases of intestinal obstruction conducted by Bhansali and Sethna[25], 54 cases of obstruction are due to tuberculosis.

About 5-9% of small bowel perforations in India are due to tuberculosis[26]. Perforations due to tuberculosis are usually single and more common in ileum proximal to stricture. Air under diaphragm is detected in only half of the cases. Acute tubercular peritonitis may also occur due to ruptured caseating lymph nodes

The other most common complication due to tuberculosis is malabsorption.

Malabsorption may be due to:

1. Bile salts deconjugation,
2. Overgrowth of bacteria in stagnant loop,
3. due to ulceration reducing absorptive surface,
4. Involvement of lymphatics and lymph nodes.

History of abdominal pain in a patient with malabsorption is highly suggestive of abdominal tuberculosis.[27]

## ANO-RECTAL TUBERCULOSIS:

It may mimics carcinoma of rectum. The most common presenting symptoms is bleeding (88%), followed by constitutional symptom(75%) and constipation[28]. The clinical presentation is different from other proximal colonic tuberculosis. Scybalous stool while traversing the strictured segment may cause mucosal trauma leading to rectal bleeding. most of the strictures are within 10 cm from anal verge[21]. The strictures are usually annular type and of variable length with focal areas of deep ulceration. It maybe rarely associated with perianal disease.

Anal tuberculosis is uncommon. Patient may present with multiple fistula. Fistulas are painful and not indurated. Tuberculous anal ulcers are shallow with undermined edges. According to Dhanapat et al, 12 out of 15 multiple fistulas are tuberculous origin [29]. Shukla et al reported that 14% of fistula in ano cases are due to tuberculous origin[30]. All patients presents with anal discharge and perianal swelling presents in one third of patients.

## DIAGNOSIS:

In 1964 Paustian[13] stated that to diagnose abdominal tuberculosis, one or more of the following four criteria to be diagnosed.

1. Acid fast bacilli should be demonstrated in a lesion.
2. Histological evidence of tubercles with caseation necrosis.
3. Gross description of operative specimen with biopsy of mesenteric lymph nodes showing evidence of tuberculosis.
4. Animal inoculation or culture resulting in growth of M.tuberculosis.

Other non specific findings include raised ESR, anemia, and hypoalbuminaemia. The diagnosis should be substantiated by adequate radiological and histopathological studies.

## INVESTIGATIONS:

### LABAROTORY INVESTIGATIONS:

#### BLOOD INVESTIGATIONS:

Hematological investigations are not specific and not much helpful in diagnosis.

1. Differential count showing lymphocytosis.
2. Anemia ( normocytic, normochromic anemia or iron deficiency anemia)
3. Raised ESR,
4. Hypoproteinaemia
5. Low serum iron levels.

#### BACTERIOLOGICAL TESTS:

The diagnosis of tuberculosis at any site is usually confirmed by demonstrating acid fast bacilli on smear or mycobacterial culture from tissue or histologically by the presence of caseating granulomas.

Acid fast bacilli can be demonstrated

1. From sputum, gastric aspirate, peritoneal fluid, pleural fluid, urine and stools.
2. Culture of acid fast bacilli from sputum, gastric content, pleural fluid aspirate, fistula tract secretions and stools.

#### RADIOLOGICAL INVESTIGATIONS:

It is of very much helpful in diagnosis of abdominal tuberculosis.

## X-RAY CHEST:

It is useful to find out primary focus and normal chest X-ray does not rule out abdominal tuberculosis. Sharma et.al [31] reported that out of seventy cases in their study, 22 patients(46%) had evidence of active or healed lesions on chest X-ray. X-rays are mostly positive (80%) in acute complications of acute tuberculosis. In another study by Tandon et al[32], only 25% of patients x-rays are positive and around 75% of patients had no evidence of concomitant pulmonary tuberculosis.

## X-RAY ABDOMEN:

Plain x-ray of the abdomen are most useful in case of complications. In case of obstruction, x-ray abdomen both supine and erect show dilated bowel loops, multiple air fluid levels. Plain x-ray abdomen may show enteroliths proximal to the site of obstruction. It may also calcified lesions in the bowel, lymph node, in the liver (calcified granuloma). Air under diaphragm will be evident in case of perforation.

## BARIUM STUDIES:

These studies are most useful in patients suspected to have intestinal tuberculosis. According to Sharp and Goldman[33], barium meal follow through examination is the best diagnostic test and demonstrates bowel lesions suggestive of tuberculosis in 84% of cases.

Small bowel barium meal:

The features suggestive of abdominal tuberculosis are

1. Accelerated intestinal transit;
2. Flocculation and fragmentation of barium(malabsorption)
3. Hypersegmentation of the barium column(chicken intestine)
4. Stiffened and thickened folds,
5. Luminal narrowing with smooth but stiff contours(hour glass stenosis)
6. Dilated loops and strictures and adherent fixed loops(adhesive peritoneal disease).
7. Displaced bowel loops due to enlarged lymph nodes.



## BARIUM ENEMA:

The features suggestive of abdominal tuberculosis are

### 1. FLEISCHNER OR INVERTED UMBRELLA SIGN:

The ileocaecal valve will become edematous and spasm due to early ileocaecal involvement. The lips of ileocaecal valve will be thickened and wide gaping of valve with narrowing of terminal ileum is characteristic.

### 2. GOOSE NECK DEFORMITY:

Straightening of ileocaecal junction with loss of normal ileocaecal angle and dilated terminal ileum.

### 3. Pulled up caecum, caecum shrunken in size, caecum pulled out of iliac fossa (pulled up caecum) due to fibrosis of mesocolon.

Caecum will be conical shaped.

### 4. Localized stenosis of ileum opposite the ileocaecal valve with dilated terminal ileum and rounded off smooth caecum- “purse string stenosis.

### 5. Thickening of folds and contour irregularity of the terminal ileum.

### 6. String sign- it indicates stenosis. Persistent narrow stream of barium.

7. Steirlin' sign: hurrying of barium due to rapid flow and lack of barium in inflamed segment. It indicates acute inflammation superimposed on a chronically involved segment.
8. Ulcers and strictures in the terminal ileum and caecum- napkin lesions.

For evaluation of abdominal tuberculosis, enteroclysis followed by barium enema may be the best tool.

#### ULTRASONOGRAPHY:

Because barium meal do not detect lesions in the peritoneum, ultrasound is very useful in detecting peritoneal tuberculosis.

1. Free or loculated fluid with septa may be seen. Fluid collections in pelvis with septa may mimic ovarian cyst.
2. Interloop ascitis- localized fluid collection between bowel loops due to local exudation from inflamed bowel.(club sandwich or sliced bread sign).
3. Thickened mesentery, bowel loops, omentum, peritoneum may be seen.
4. Lymphadenopathy can be visualized. Lymph node enlargement may be discrete or matted. The echogenecity is mixed heterogenous.

Calcification of nodes can be seen as discrete reflective lines. Both calcification and caseation are highly suggestive of tuberculosis.

5. Concentric uniform mural thickening can be seen.
6. Pseudokidney sign: pulled up caecum presenting as mass in subhepatic region.
7. Bowel loops radiates from its mesenteric root- stellate sign may be seen.

#### COMPUTED TOMOGRAPHY (CT) SCAN:

CT scan is very useful and reliable investigation. CT scan may show symmetric circumferential thickening of caecum and terminal ileum in early disease. Gross bowel wall thickening, adherent bowel loops, regional lymph nodes and mesenteric thickening may be seen as mass in advanced stage disease. Ileocaecal valve thickening may be seen.

Enlarged mesenteric nodes often with cold abscess may be seen. Nodules in the peritoneum and solid organs like liver may be seen. It is commonly used in complications of tuberculosis like perforation, abscess and obstruction.

The most common manifestation of abdominal tuberculosis in CT scan is abdominal lymphadenopathy. mesenteric, peri-portal, peri-pancreatic and upper para-aortic lymph nodes are most commonly involved. There are

four patterns of lymph nodes enhancement on contrast enhanced CT- peripheral rim enhancement, non-homogenous enhancement, homogenous enhancement and homogenous non-enhancement. Patient from endemic areas with nodal calcification on CT scan in the absence of a known primary tumour is highly suggestive of tubercular aetiology.

Ascitic fluid in tuberculosis is of high attenuation value(25-45 HU) due to high cellular and protein content of fluid. CT guided aspiration of fluid can be done. Peritoneal tuberculosis can be seen as smooth peritoneum with minimal thickening and marked enhancement.

Mesentery will be thickened and seen as patchy or diffuse increase in density. Omentum will be thickened and it is seen as omental cake appearance in CT scan. Omental line- due to long standing inflammation a fibrous wall can be seen covering the omentum[34].

Splenomegaly or splenic calcification have been more commonly seen in tuberculous peritonitis. Hepatic and splenic involvement may appear as tiny low density foci in CT scan. Macro nodular form of hepatosplenic tuberculosis will be seen as multiple low attenuation (15-50 HU) ,1-3 cm round lesions which may show peripheral

enhancement after i.v. contrast administration. Pancreatic tuberculosis will appear as hypodense necrotic regions within enlarged pancreas.

#### COLONOSCOPY:

It is the easiest and most direct method to establish the diagnosis.

Colonoscopy shows mucosal nodules of variable sizes (2 to 6 mm) and ulcers of length 4-8 cm in length which are pathognomic of tuberculosis.

The nodules are more often seen in caecum and have a pink surface with no friability. Ulcers large or small may be seen in the inter

nodular area. strictures can be seen. Pseudopolypoid edematous folds and edematous and deformed ileocaecal valve are other findings suggestive of

tuberculosis. Biopsies can be taken from the edge of the ulcers for

histopathology and culture. Only one third of patients caseation (33-38%)

will be seen. Granulomas are seen in 8- 48% of patients [21]. According to

Bhargava et al[35] that routine culture of biopsy tissue increase the

diagnostic yield. Both the biopsy and culture can help to establish the

diagnosis in over 60% of cases.

In difficult cases, capsule endoscopy is useful to see small intestinal

(tubercular) pathology.

## IMMUNOLOGICAL TESTS:

Chawla et al[36] in their study reported that an optical density(OD) of 0.81 on ELISA and fluorescent coefficient of 2.56 on SAFA as cut off gave positivity of 92 and 83 % respectively. Even after the therapy, ELISA remains positive. Because the response to mycobacterium is variable and its reproducibility is poor, the significance of immunological tests is not clearly identified in clinical practice. The PCR assay of endoscopically biopsied tissue or ascitic fluid is a valuable tool for detection of mycobacterial sequences. PCR can detect 1-2 organism or 8 fg of mycobacterial DNA. The advantages of PCR over culture is detection of mycobacterium within 3 days. PCR amplification can be used to detect mycobacterium even in the formalin preserved tissues. Positive PCR signifies infection but need not be active disease. The PCR resolves the foremost challenge faced by the clinicians for the diagnose of abdominal tuberculosis.

## ASCITIC FLUID EXAMINATION:

In tuberculosis, the ascitic fluid is exudate, straw coloured with protein content  $> 3$  g/ dl. Lymphocytes will be predominant with total count as high as 4000/mm<sup>3</sup>. Serum ascitic fluid albumin gradient is  $< 1.1$ . acid fast bacilli will be seen in only  $< 3\%$  cases. LDH is more than 90 units/ litre. Specific gravity  $> 1.016$ . adenosine deaminase(ADA) is an enzyme involved in catabolism of purine bases. ADA converts adenosine to inosine. It is more in T lymphocytes. ADA level will be increased in tuberculosis due to stimulation of T cells by mycobacterial antigens. Bhargava et al in their study reported that serum ADA level  $> 54$ U/L, ascitic fluid ADA level  $> 36$  U/L and ascitic fluid to serum ADA ratio  $> 0.985$  is highly suggestive of tuberculosis[37]. Interferons levels are higher in ascitic fluid. Both the ADA and interferons levels can increase the sensitivity and specificity.

## LAPAROSCOPIC FINDINGS:

Bhargava et al[38] in their study of 87 patients with high protein ascites, 38 patients were diagnosed to have tuberculosis. They

reported that visual appearance is more helpful than histology, culture or animal inoculation.

In 85-90 % of biopsies, caseating granulomas are found. Peritoneal tuberculosis is grouped into three categories based on laparoscopic findings:

1. The peritoneum will be thickened, hyperemic and lost its shiny luster. Multiple yellowish white tubercles of uniform size ( 4-5 mm) are diffusely distributed on the peritoneum. Tubercles can be seen over omentum, liver and spleen.
2. Peritoneum may be thickened without tubercles.
3. Fibroadhesive peritonitis with thickened peritoneum and multiple adhesions fixing the viscera.

#### COMPLICATIONS:

The complications of abdominal tuberculosis are

1. Obstruction -20%
2. Malabsorption, blind loop syndrome
3. Perforations
4. Intra abdominal abscess



5. Faecal fistula
6. Hemorrhage
7. Cold abscess formation
8. Dissemination of tuberculosis to other areas of abdomen

(1) OBSTRUCTION:

This is the most common complications of abdominal tuberculosis. it can occur in 20% of patients. Obstruction may occur due to

1. Healing of encircling ulcer can form constriction due to collagenous tissue.
2. The thickened bowel wall may encroach upon lumen through scar tissue.
3. The intra peritoneal adhesions may constrict the intestine.
4. Mesentery gets retracted and pulling up caecum leading to shortening of right colon.

obstruction may be managed by stricturoplasty or resection and anastomosis.

There are reports suggesting that obstructing lesions may relieve with antitubercular drugs alone without surgery. Long

strictures(>12 cm) and multiple areas of involvement are indications of surgery based on the study by anand et al.

(2) PERFORATION:

Tubercular perforations are more common in terminal ileum and are mostly associated with distal strictures. Incidence is about 11% of cases. Free perforations are uncommon. It is postulated that hypersensitivity reaction of lymphoid tissue to M. tuberculosis may lead to ulceration and perforation. The perforation may be managed by simple closure or segmental resection. Simple closure of ulcer is often associated with high incidence of leak and fistula formation than resection and anastomosis.

(3) FISTULAS:

The fistula may develop between the bowel loops or between the bowel loop and abdominal wall or female adnexal organ or urinary bladder. It occurs in about 1-33% of patients. The

fistulas are usually managed by excision and repair of fistulous tract depending upon the site of fistula.

#### (4) MALABSORPTION:

The malabsorption may be due to

1. bile salts deconjugation,
2. overgrowth of bacteria in stagnant loop,
3. due to ulceration reducing absorptive surface,
4. involvement of lymphatics and lymph nodes.

History of abdominal pain in a patient with malabsorption is highly suggestive of abdominal tuberculosis.

#### MANAGEMENT

Anti tubercular therapy is sufficient and surgery usually not indicated unless complications develop. All patients should receive anti tubercular drugs for at least 6 months. In a study conducted by Balasubramaniam et al in Chennai a randomized comparison of 6 months short course chemotherapy and 12 months course of ethambutol and streptomycin cure rate was 99 and 94 in patients in respective groups.

In the era of anti tubercular drugs, the more radical procedures became popular in an attempt to eradicate the disease locally. However most of the procedures are not well tolerated by the malnourished patients. The management of abdominal tuberculosis can be discussed under three headings:

1. General measures
2. Anti tubercular drugs
3. Surgical management.

#### 1. GENERAL MEASURES:

Most of the patients have loss of weight and loss of appetite due to tuberculosis itself, and malnourished due to malabsorption . these patients should be supplemented with diet containing high calorie, proteins, vitamins and minerals. Iron supplementations should be advised.

#### 2.ANTI TUBERCULAR TREATMENT:

The drugs for management of abdominal tuberculosis is same of that of pulmonary tuberculosis. The tuberculosis, like other chronic infection is difficult to treat due to

1. Even in more favourable conditions, the bacilli grow slowly dividing once in 1-2 days. The bacilli may remain dormant for many years in less favourable conditions like closed caseous lesions (persisters). Only rifampicin is effective against these persisters.

2. The caseation makes the penetration of drugs more difficult as it tends to block the blood vessels supplying the necrotic areas.

3. The bacilli remain viable and divide inside macrophages. Isoniazid, rifampicin and pyrazinamide penetrate poorly into macrophages.

4. Resistance to anti-tubercular drugs.

#### ANTI-TUBERCULAR DRUGS:

The drugs used for abdominal tuberculosis are classified into two major categories.

##### 1. FIRST LINE DRUGS

These antitubercular drugs have high efficacy and low toxicity profile.

1. Isoniazid (Bactericidal)

2. Rifampicin ( " )

3. Pyrazinamide ( " )

4. Streptomycin ( " )
5. Ethambutol (Bacteriostatic)

#### SECOND LINE DRUGS:

These drugs have low anti tubercular efficacy and high toxicity. They are used only in resistant cases. The second drugs are

1. Thiacetazone (Bacteriostatic)
2. Ethionamide ( " )
3. Para aminosalicylic acid ( " )
4. Cycloserine ( " )
5. Amikacin (Bactericidal)
5. Capreomycin ( " )
6. Kanamycin ( " )
7. Clofazamine ( " )

Newer drugs are:

Ciprofloxacin, Ofloxacin, Sparfloxacin, Clarithromycin,  
Azithromycin, Rifabutin,  
Rifapentine  
Amoxicillin + clavalanic acid.

**Dosages of commonly used antitubercular drugs**

Drug	Adults		Twice Weekly dosage	Children
	Daily dosage			
	Below 50 Kg	Above 50 Kg		
Rifampicin	450 mg	600 mg	10mg/kg 600-900 mg	10mg/kg to a max of 600mg
Isoniazid	300 mg	450 mg	10 mg/kg to a max. of 1gm	5mg/kg
Pyrazinamide	1500 mg	1500 mg	35 mg/kg to a max 3500 mg	25mg/kg
Streptomycin	0.75g	1 gm	15mg /kg	15mg/kg max 0.75 gm.
Ethambutol	800 mg	1200 mg	30mg/kg to a max. 2400mg	15 mg/kg
PAS	10 gm	12 gm	12 – 15 gm	200 mg /kg
Thiacetazone	150 mg	150 mg	Not recommended	2.5 mg/kg

**CHEMOTHERAPEUTIC REGIMENS:**

Drugs are usually used in combinations in order to

1. To delay the development of resistance
2. To achieve maximum benefit with minimum toxicity.
3. To prolong the effective therapy.

The standard drug regimen is isoniazid, rifampicin, Ethambutol and streptomycin for 2 months followed by isoniazid and Ethambutol for rest of the period.( the duration of treatment is

12-18 months) as recommended by Tubercular research institute, ICMR.

Many studies compared the short course chemotherapy and standard regimen and concluded that no regimen is superior over the other. In short course chemotherapy, a daily 6 months regimen of Rifampicin, Isoniazid, Ethambutol and pyrazinamide for 2 months followed by Rifampicin and Isoniazid for 4 months was given and studies have concluded that short course chemotherapy is as effective as standard regimen.

#### **SURGICAL MANAGEMENT:**

The indications for surgery are

1. Complications due to abdominal tuberculosis.
2. Failure of medical therapy.
3. As a diagnostic procedure.
4. Emergency surgical intervention may be required in some instances due to complications
  - A. Perforation due to tubercular ulcer.
  - B. Severe intestinal hemorrhage.



C. Intra abdominal abscess due to mesenteric abscess or contained perforation.

5. INTESTINAL OBSTRUCTION resulting from stricture formation.

6. Shortening of mesentery causing obstruction due to kinking of bowel.

7. Bowel adhesions

8. external and internal fistula

9. localized Hyperplastic TB diminishing caliber of lumen.

Surgery is also indicated when the diagnosis is in doubt or malignancy cannot be ruled out.

#### SURGICAL PROCEDURES:

The various surgical procedures for management of abdominal tuberculosis and its complications are

1. Ileoplasty/ ileocecoplasty

2. 'U' anastomosis

3. Limited local resection

4. Right hemicolectomy

5. ileotransverse colostomy

6. Closure of perforation

## 7. Approach to Intestinal Adhesion.

### 1. ILEOPLASTY:

Pujari suggested the following criteria for stricturoplasty

- 1.the degree of proximal dilatation and hypertrophy.
- 2.the reduction of lumen size > 60%.

It is similar to Heineke-mikulicz technique nothing but correction of stricture involving ileum or ileocaecal region.

After the abdomen is opened, a longitudinal incision of length about 5cm is made along the antimesenteric border with the centre of incision over the strictured segment. Biopsy should be taken from the strictured segment. Bowel is then closed transversely in two layers. Mesenteric lymph nodes are taken for biopsy.

### ADVANTAGES OF ILEOPLASTY:

- a.Large functional part of ileum is preserved and no part of gut is excised.
- b. Eliminates short bowel syndrome and blind loop syndrome.
- c. Safe, simple, effective in anemic, hypoproteinemic and chronically ill patients.
- d. Procedure can be carried out in patients with active tuberculosis enteritis who have not had antituberculous treatment earlier.
- e. Biopsy can be taken from the edge of incision for IIPe.

## 2. 'U' ANASTOMOSIS:

It is done in case of long strictures. The stricture is cut across and side to side U shaped anastomosis is done. It is technically similar to Finney's pyloroplasty.

## 3. LIMITED LOCAL RESECTION:

Dutta and Gupta and Sharma and Mehta advocated this procedure for management for ileocaecal tuberculosis.

The main aim of this procedure is to avoid malabsorption and blind loop syndrome which may arise due to extensive resection and long bypass segment.

The procedure includes mobilization of ileocaecal region and resection of bowel segment about 5 cm on either side and ileocolic anastomosis.

### ADVANTAGES:

1. It is easier to perform through smaller incision.
2. As it requires only limited mobilization, injury to duodenum, ureter and kidney can be avoided.

3. It can be suitably performed in emergency especially when the patient is hypoproteinemic, anaemic.
4. It leaves only small raw area for peritonealisation.

#### RIGHT HEMICOLECTOMY:

It was surgery of choice before the more conservative procedures were described. It is mostly performed when malignancy cannot be safely excluded.

#### ADVANTAGES:

1. It is easier to perform anastomosis between the ileum and transverse colon because of same diameter of lumen.
2. Eradicates the local disease and reduces the rate of recurrence.
3. Reduces the occurrence of intussusception due to anastomosis between the two mobile segments.

#### DISADVANTAGES:

1. Removal of more functional bowel.
2. More of radical surgery.

## PERFORATION CLOSURE:

The perforation due to tuberculosis is not rare. They are usually associated with tuberculous stricture. simple suture of perforation with drainage of peritoneal cavity can be done as advocated by prakash et al in 1975. Multiple ileal perforations are treated by resection and anastomosis and drainage tubes are not indicated.

Enterocutaneous fistulas can be managed by fistulous tract resection, intestinal anastomosis and along with anti tubercular therapy.

## POST OPERATIVE MANAGEMENT:

1. Intravenous fluids and electrolytes.
2. Decompression by nasogastric aspiration
3. Antitubercular therapy.
4. Antibiotics and analgesics.

## POST OPERATIVE COMPLICATIONS:

The post operative morbidity and mortality is very high if surgery is performed for emergency conditions like perforation,

obstruction and peritonitis. Mortality rate may be as high as 20% after emergency surgery.

The following complications are reported after surgery.

EARLY: Faecal fistula,

Wound dehiscence,

Toxemia following peritonitis due to perforations.

LATE: Malabsorption and blind loop syndrome in bypass surgeries,

Obstruction due to adhesions.

# ***MATERIALS AND METHODS***

## MATERIALS AND METHODS

The clinical study of abdominal tuberculosis was conducted with the aim to evaluate the incidence of abdominal tuberculosis, various sites of presentation, incidence of surgical emergencies due to abdominal tuberculosis.

The study was conducted in the department of general surgery in Government Kilpauk medical college hospital and Government Royapettah hospital between July 2011- June 2013.

50 patients were included in the study pooled from surgical outpatient clinic or emergency department.

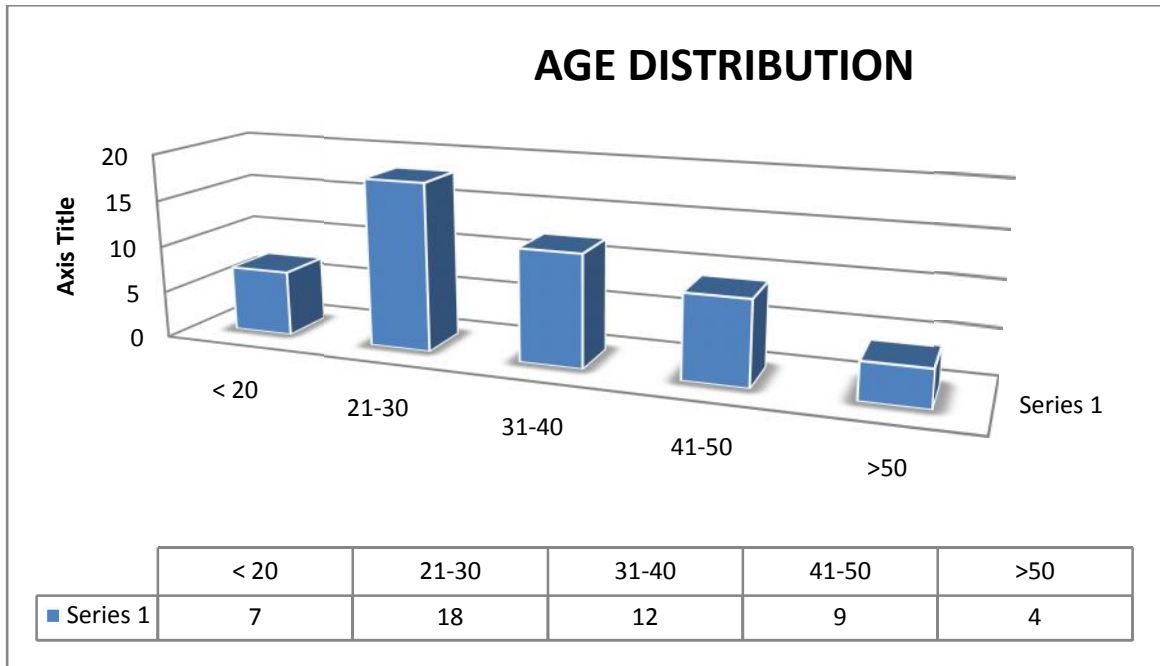
Data were collected from all patients. Patient's age and sex were noted. Detailed history was obtained. Thorough clinical examination was performed. Every patient had chest x-ray and abdominal x-ray. All basic blood investigations were done. CT abdomen was performed in inconclusive cases. CT abdomen and colonoscopy was not performed in those who underwent surgical emergencies. Tissue diagnosis by histopathological examination had proven positive for all patients. The details of all the patients were collected and analyzed.



# ***OBSERVATION AND ANALYSIS***

## OBSERVATION AND ANALYSIS

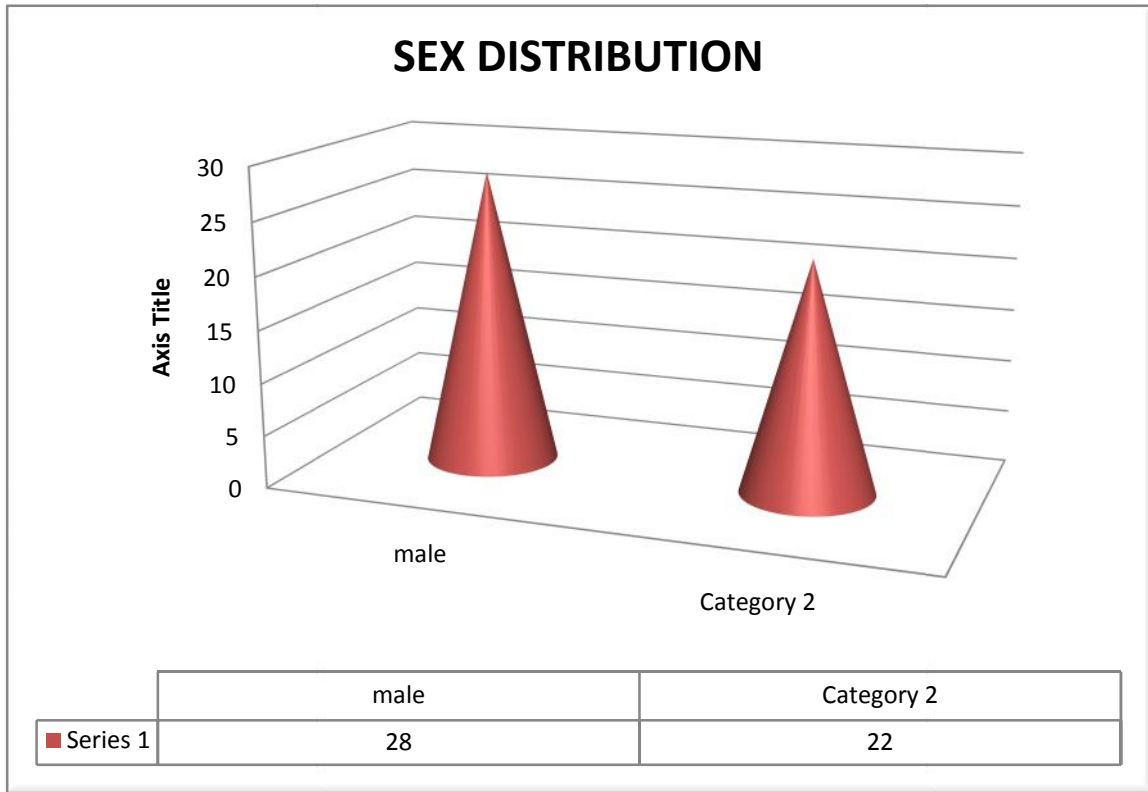
### 1.AGE DISTRIBUTION:



The present series include 50 patients. The youngest patient was 16 year old and the oldest being was 65 year old. The average age of the patient in the series was 32.5% . Age incidence of present series is similar to reported by J.D. Wig et al and Ramesh c. Bharathi et al.

## 2.SEX DISTRIBUTION:

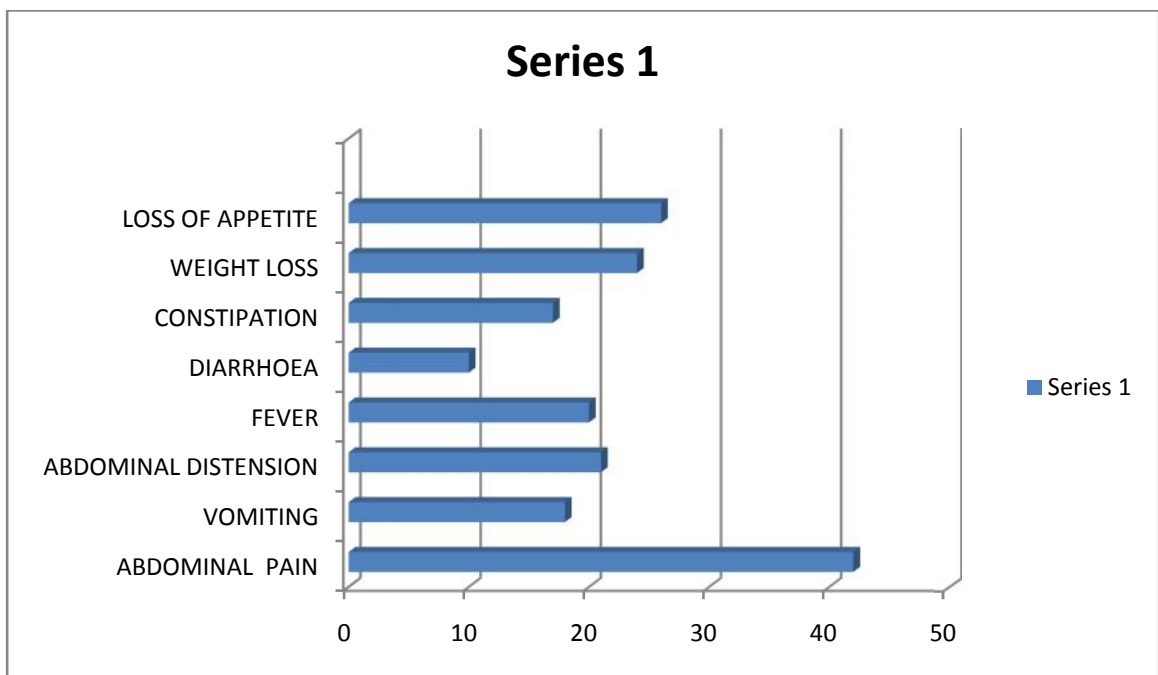
The present study included 28 male patients and 22 female patients.



The male to female ratio was 1.2:1. Addison et al reported high incidence in male. M.ismail et al reported equal incidence in both male and female.

## CLINICAL PRESENTATION:

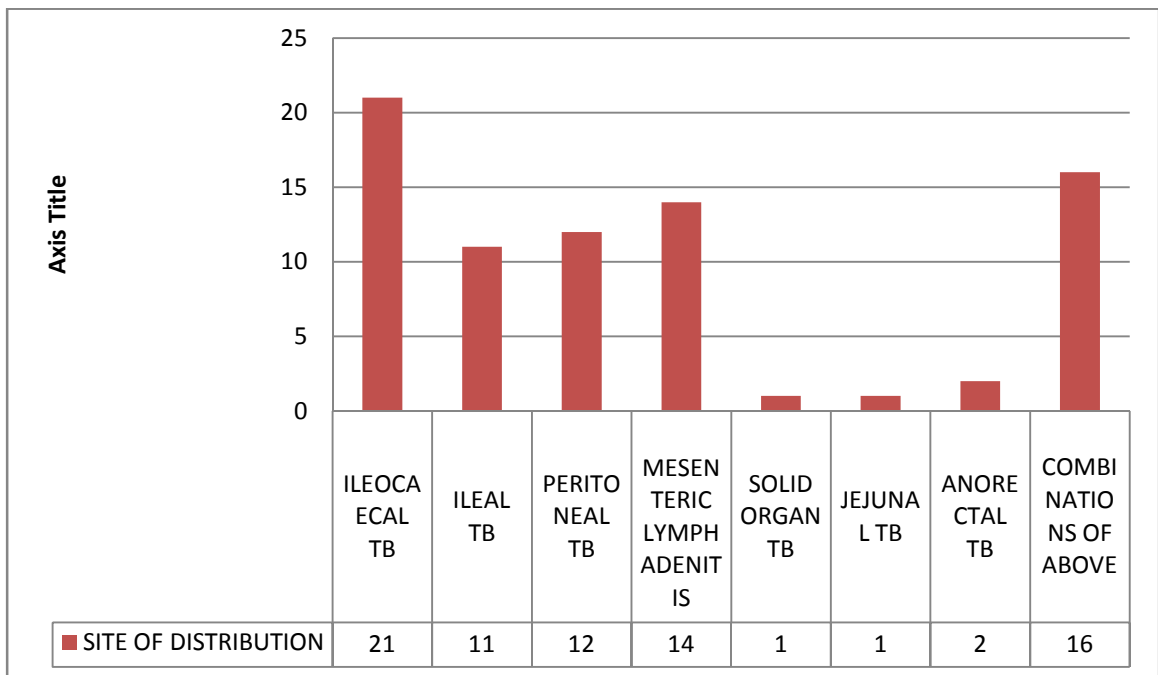
The patient in these series are presented with symptoms ranging from abdominal pain to constitutional symptoms like loss of weight, loss of appetite, fever. The frequency of symptoms are



In the present study, the most common symptoms is abdominal pain (84%) similar to results reported in Das p.Shukla H.S. et al and Bhansali k. et al. other common symptoms are fever, vomiting, bowel disturbances, loss of weight and loss of appetite.

#### 4.SITES OF ABDOMINAL TUBERCULOSIS:

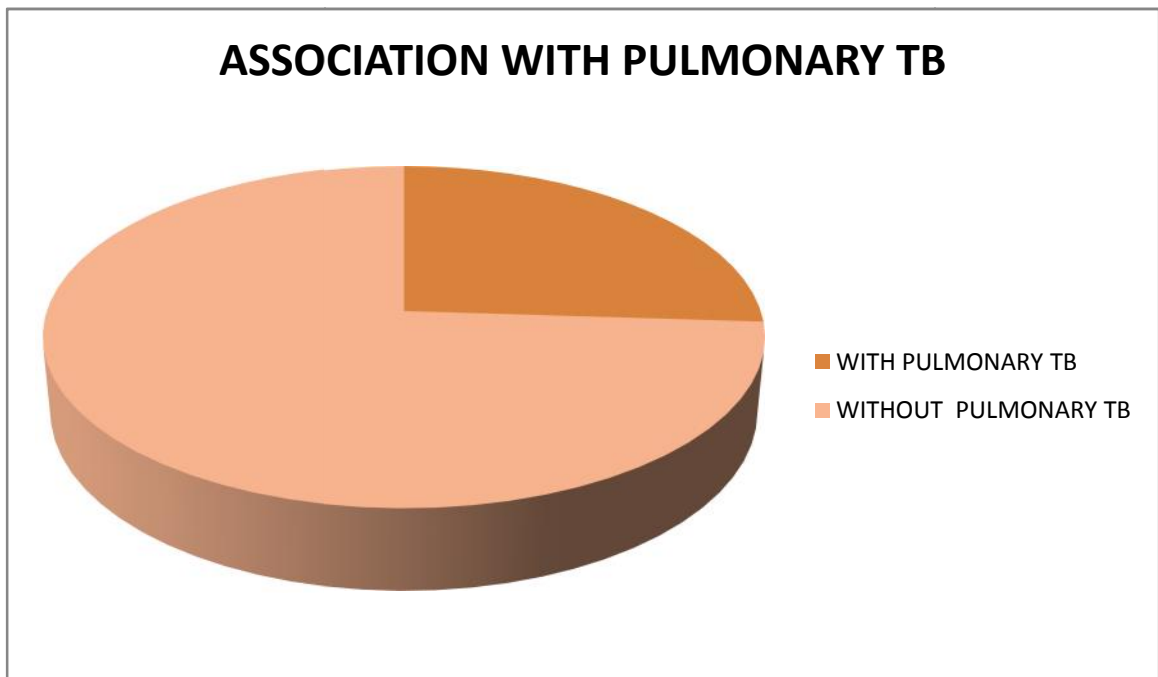
The ileocaecal junction was most commonly affected in abdominal tuberculosis with 42% of patients followed by terminal ileum.



Ileocaecal region is the most commonly affected region in abdominal tuberculosis similar to reports from Chalya et.al. about 42% of patients presented with ileocaecal tuberculosis, followed by mesenteric lymphadenitis and peritoneal tuberculosis.

## 5. ASSOCIATED PULMONARY TUBERCULOSIS:

In our study associated pulmonary tuberculosis presents in 13 out of 50 patients that is 26%.



## 6. INVESTIGATIONS:

x-ray chest PA view taken in all patients. About 13 patients showed evidence of pulmonary tuberculosis.

PLAIN X-RAY ABDOMEN ERECT in emergency conditions showed multiple air fluid level in 11 patients and air under diaphragm in 6 patients.

ESR done in all patients and elevated in 29 patients indicating the ongoing inflammation. Mantoux test was performed in 30 patients and strongly positive in 17 patients.

#### CT-ABDOMEN:

CT abdomen was taken in 24 patients. Majority of patients CT picture showed signs of abdominal tuberculosis like lymphadenopathy, irregular soft tissue densities, ascites, bowel wall thickening.

#### COLONOSCOPY:

Colonoscopy was performed in 18 patients with symptoms of abdominal mass, altered bowel habits, and biopsy confirmed tubercles and characteristic feature of caseating granuloma.

#### LAPAROSCOPY:

Laparoscopy was performed in 8 patients and confirmed by peritoneal biopsy.

## 7. SURGICAL TREATMENT:

Surgical treatment was offered to those patients presented with acute emergency conditions like obstruction and perforation. 18 patients underwent emergency surgery.

Emergency surgery for intestinal obstruction was performed in 11 patients. Of which resection and anastomosis was performed in 3 cases. Adhesiolysis done in 6 cases. Resection and ileostomy was performed in 1 case. Right hemicolectomy done in 1 case.

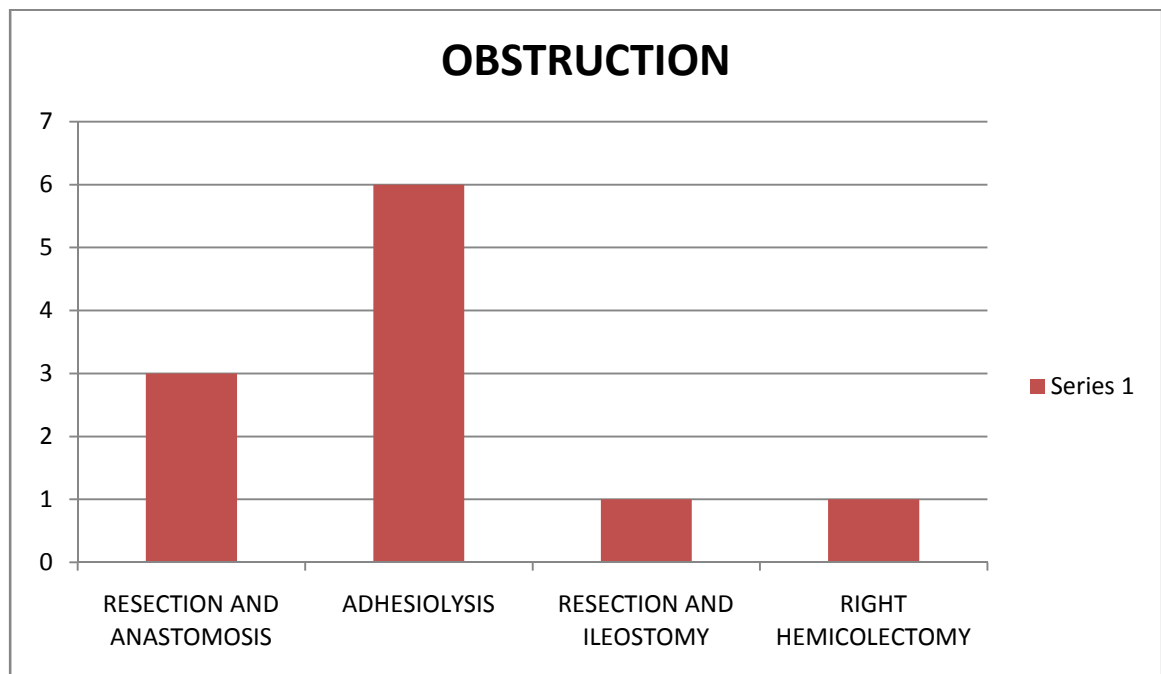


TABLE: EMERGENCY SURGERY IN INTESTINAL OBSTRUCTION



Emergency surgery for perforation was performed in 6 cases. Of which 3 patients underwent primary closure and biopsy. 2 cases underwent resection and anastomosis. One case underwent resection with ileostomy. One patient underwent emergency appendicectomy for appendicular perforation.

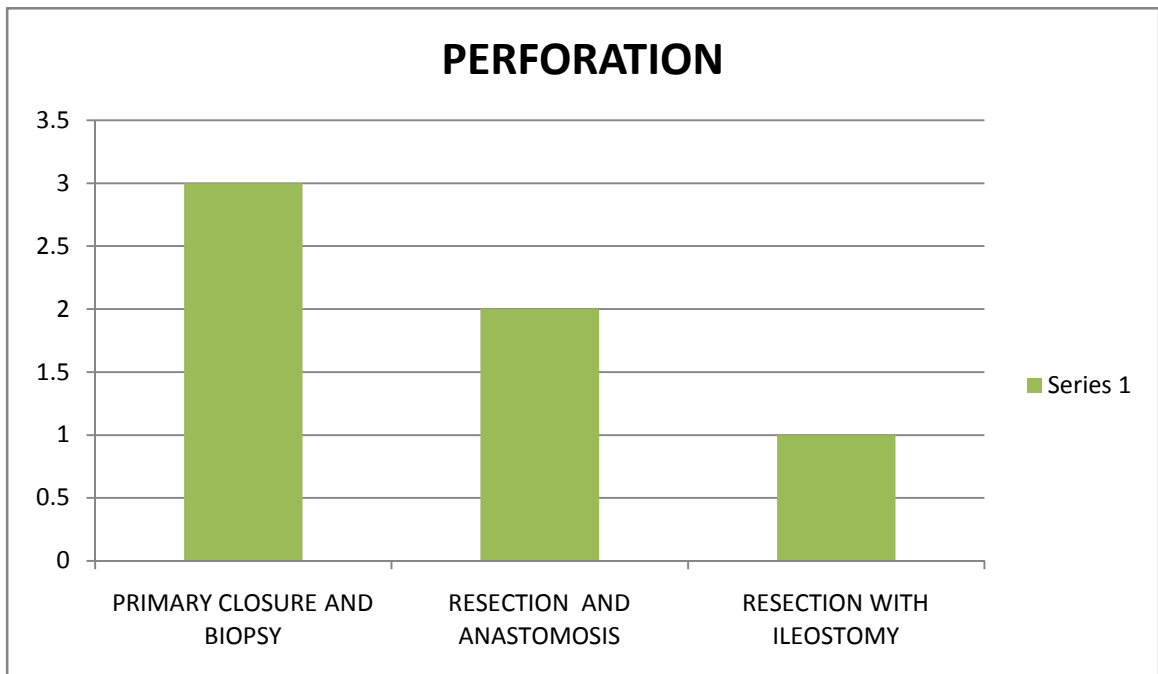
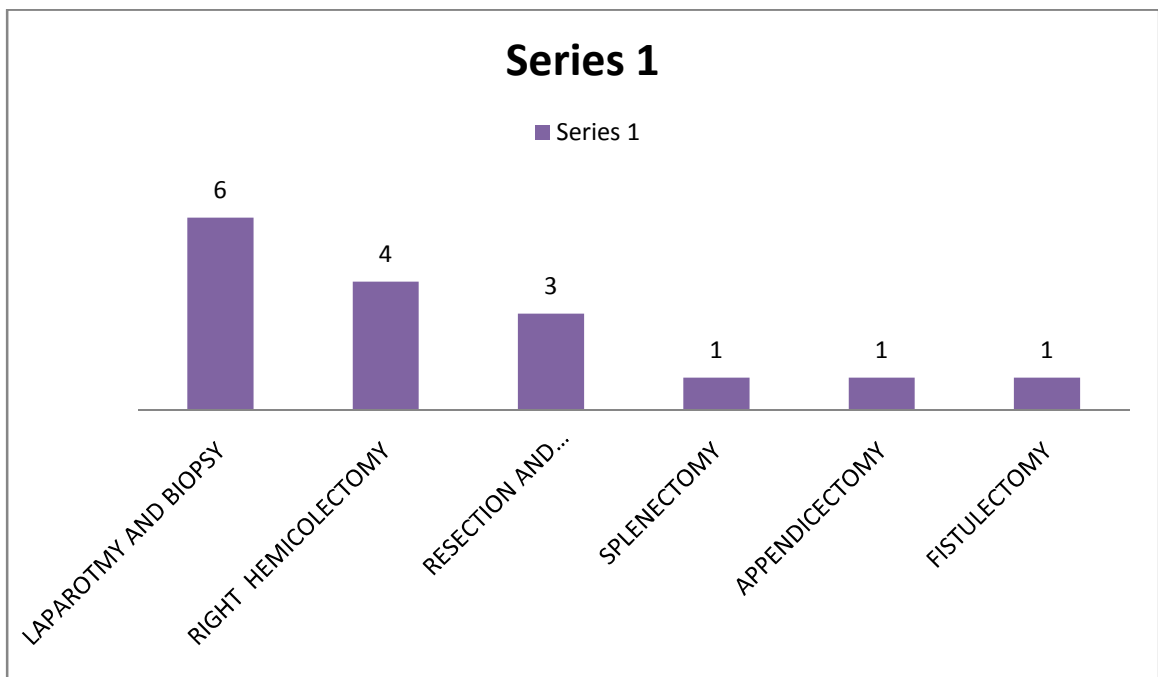


FIG: SURGERIES IN PERFORATION.

Elective surgery was performed in 16 patients of whom 6 patients were underwent laparotomy and biopsy alone. Right hemicolectomy was done in 4 patients. Resection and anastomosis was done in 3 patients. One patient underwent splenectomy for splenic tuberculosis. Two patients underwent fistulectomy for perianal fistula.



# ***DISCUSSION***

## DISCUSSION

### 1.AGE DISTRIBUTION:

SL NO	AGE IN YEARS	J.D. Wig et al 1979	RAMESHC. BHARATHI et al 1996	PRESENT STUDY
1.	< 20 YEARS	11(15.06%)	28(21.3%)	7(14.0%)
2.	20-30 YEARS	37(50.7%)	51(38.6%)	18(36%)
3.	31-40 YEARS	15(20.5%)	24(18.6%)	12(24.0%)
4.	41-50 YEARS	6(8.2%)	5(3.8%)	9(18.0%)
5.	> 50 YEARS	4(5.5%)	3(2.2%)	4(8.0%)
	TOTAL	73	132	50

In our present study, most of abdominal tuberculosis presented in the age group of 21-30 and 31-40 which were 36.0% and 24% respectively. Age incidence of present series is similar to reported by J.D. Wig et al and Ramesh c. Bharathi et al. other studies by Sharma et.al 1972 and B.K.Bhansali et.al,1968 also reported similar age incidence.

## 2.SEX DISTRIBUTION:

In our study , the male to female ratio is 1.2:1. 28 patients (56%) were male and 22 patients (44%) were female with slight male preponderance. Addison et al reported high incidence in male. M.Ismail et al reported equal incidence in both male and female.

## 3.CLINICAL PRESENTATION:

SL NO	SYMPTOMS	DAS P.SHUKLA H.S.et al	BHANSALI S.K. et al 1978	PRESENT STUDY
1.	Abdominal pain	94%	100%	84%
2.	vomiting	69.6%	29.9%	36%
3.	Abdominal distension	45%	–	42%
4.	fever	42.2%	49.2%	40%
5.	Diarrhea	16%	21%	24%
6.	constipation	48%	55%	34%
7.	Weight loss	35.6%	25.6%	48%
8.	Loss of appetite	–	42.9%	52%

In the present study, the most common symptoms is abdominal pain (84%) similar to results reported in Das p.Shukla H.S. et al and Bhansali k. et al. other common symptoms are fever, vomiting, bowel disturbances, loss of weight and loss of appetite.

#### 4.SITE OF INVOLVEMENT:

SL NO	SITE OF INVOLVEMENT	CHALYA et al 2013	PRESENT STUDY
1.	Ileocaecal TB	57.5%	42%
2.	Ileal TB	34.0%	22%
3.	Peritoneal TB	41.4%	24%
4.	Jejunal TB	5.7%	2%
5.	Nodal TB	3.9%	28%
6.	Solid visceral TB	2.7%	2%
7.	Ano-rectal TB	2.3%	4%

Ileocaecal region is the most commonly affected region in the abdominal tuberculosis similar to reports from Chalya et.al. about 42% of patients presented with ileocaecal tuberculosis, followed by mesenteric lymphadenitis and peritoneal tuberculosis.

## 5.ASSOCIATION OF PULMONARY TUBERCULOSIS:\

In our present study, 13 out of 50 (26%) patients had associated pulmonary tuberculosis which is comparable to reports by bhansali et al (24.8%) and Das p.Shukla et al (27.8%). This indicates that abdominal tuberculosis is not always secondary to pulmonary tuberculosis.

## 6.SURGICAL MANAGEMENT:

SL NO	SURGICAL PROCEDURE	CHALYA et al	PRESENT STUDY
1.	RELEASE OF ADHESIONS	124(58.5%)	6(17.6%)
2.	BOWEL RESECTION AND ANASTOMOSIS	56(26.4%)	8(23.5%)
3.	RIGHT HEMICOLECTOMY	14(6.6%)	5(14.7%)
4.	PERFORATION CLOSURE	12(5.7%)	3(8%)
5.	ILEOSTOMY	1(0.5%)	2(5.8%)
6.	LAPAROTOMY AND BIOPSY	8(3.8%)	6(17.6%)
7.	SPLENECTOMY	4(1.9%)	1(2.9%)
8.	APPENDICECTOMY	6(2.8%)	1(2.9%)

Surgery was indicated in those patients with complications mostly due to intestinal tuberculosis. In present study, 18 patients underwent emergency surgery. 11 patients were operated for intestinal obstruction and 6 patients for peritonitis due to hollow viscus perforation. 16 patients underwent elective surgery. Antitubercular therapy is the mainstay of the treatment along with improvement of nutrition. All the patients started on category I antitubercular therapy under RNTCP GUIDELINES.



## ***CONCLUSIONS***

## CONCLUSIONS

1. Abdominal tuberculosis mostly occurred in the middle age group(21- 40 years)
2. The most common presenting symptoms is abdominal pain and abdominal tenderness is the most common sign elicited.
3. Ileocaecal region is the most commonly affected region in the Abdominal tuberculosis.
4. About 26% of patients had associated pulmonary tuberculosis.
5. Surgery is usually indicated in patients with complications of abdominal tuberculosis.

6. The most common surgical emergency is intestinal obstruction due to either ileocaecal mass or stricture followed by perforation.
  
7. Most of the patients are diagnosed using CT ABDOMEN and colonoscopy guided biopsy.
  
8. Limited bowel resection and anastomosis was mostly commonly performed surgery in abdominal tuberculosis followed by adhesiolysis and band release is the most common procedure performed.
  
9. All the patients are started on anti tuberculous therapy. Anti-tubercular treatment still form the mainstay of treatment. All patients started on category I anti tubercular drugs based on RNTCP guidelines.

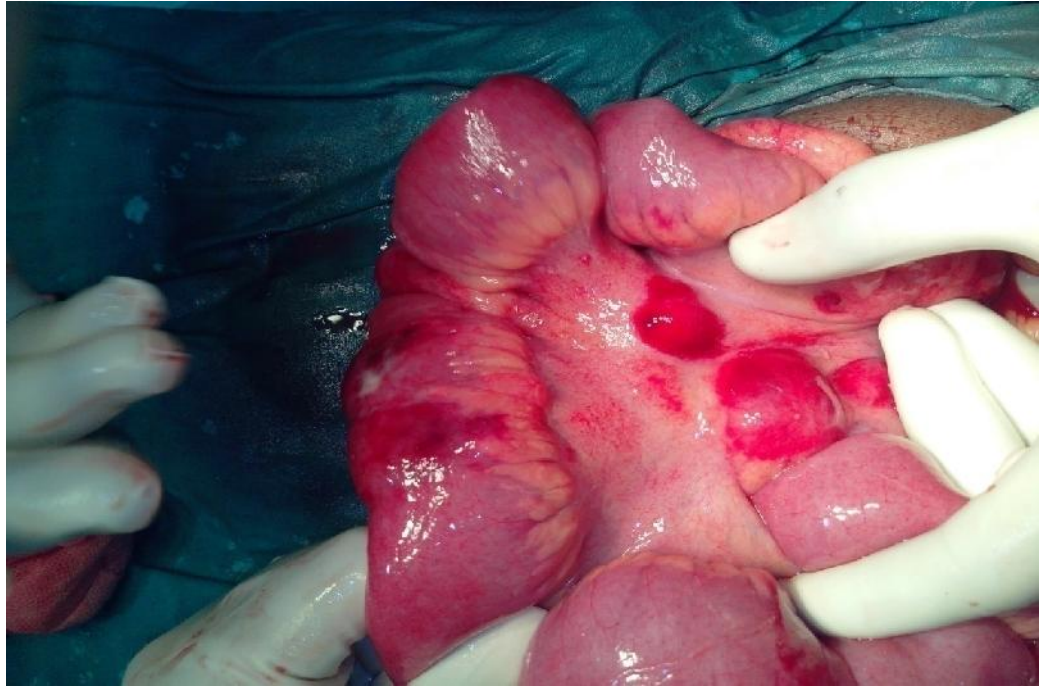

FIG 1: MULTIPLE MESENTERIC LYMPHADENITIS.

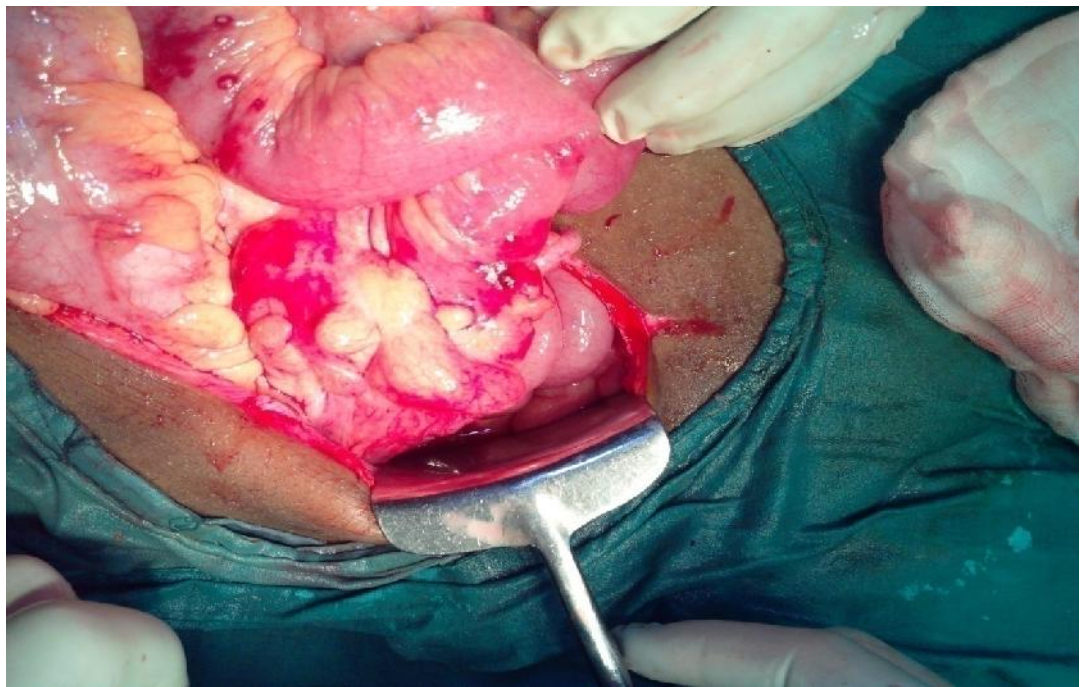


FIG 2: ILEOCAECAL MASS

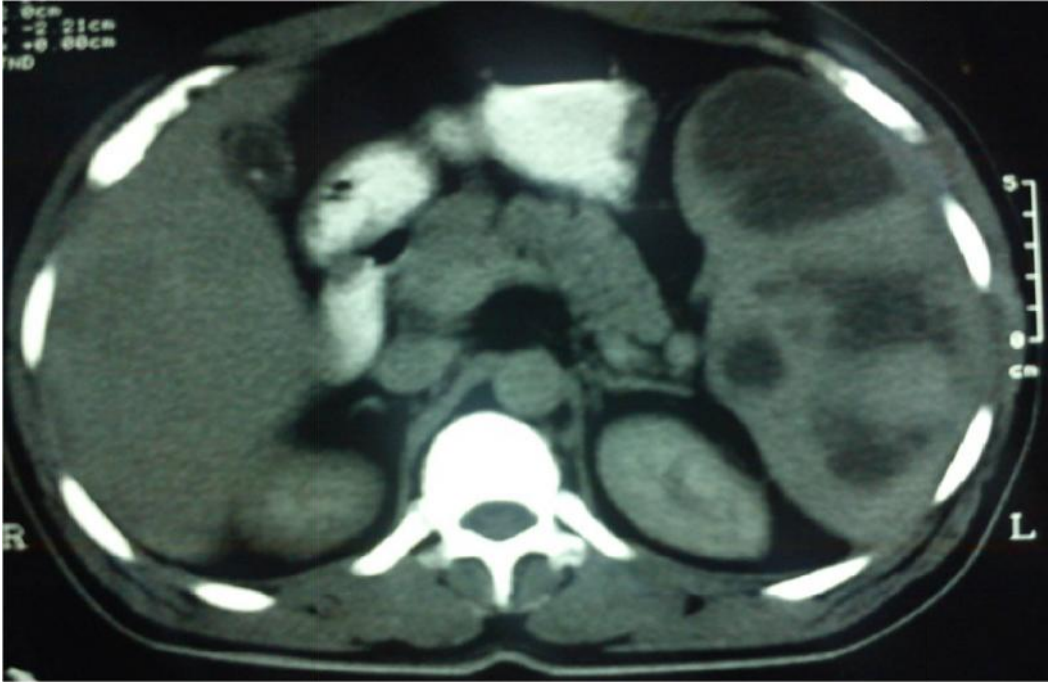


FIG 3: CT ABDOMEN SHOWING MULTIPLE SPLENIC ABSCESS

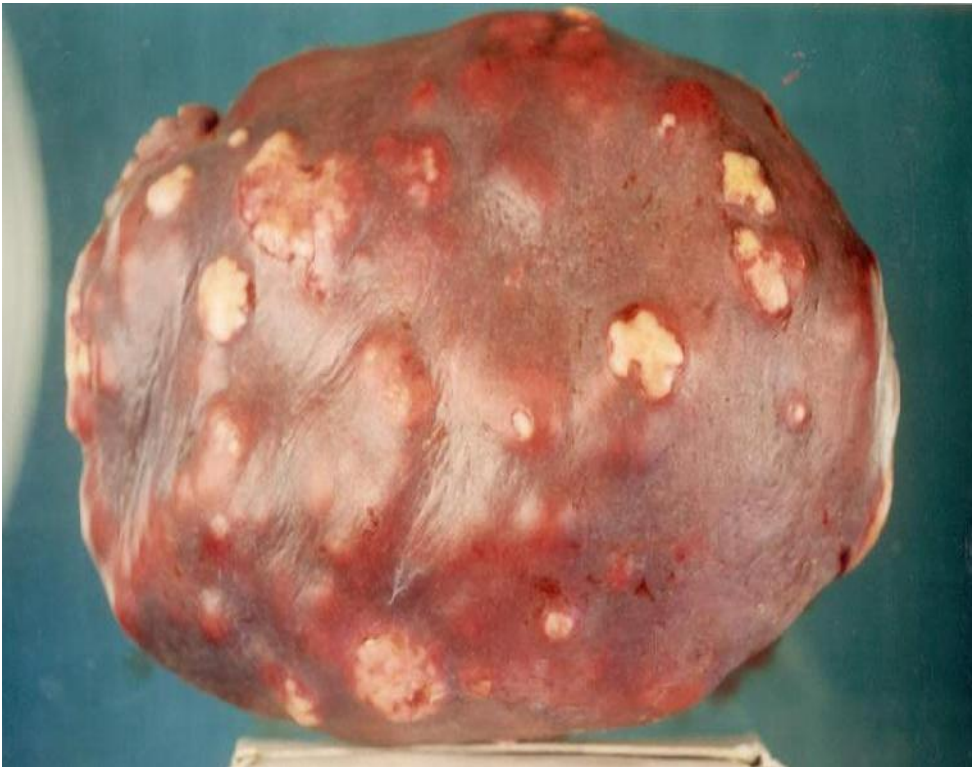

FIG 4: GROSS SPECIMEN OF SPLENIC ABSCESS.



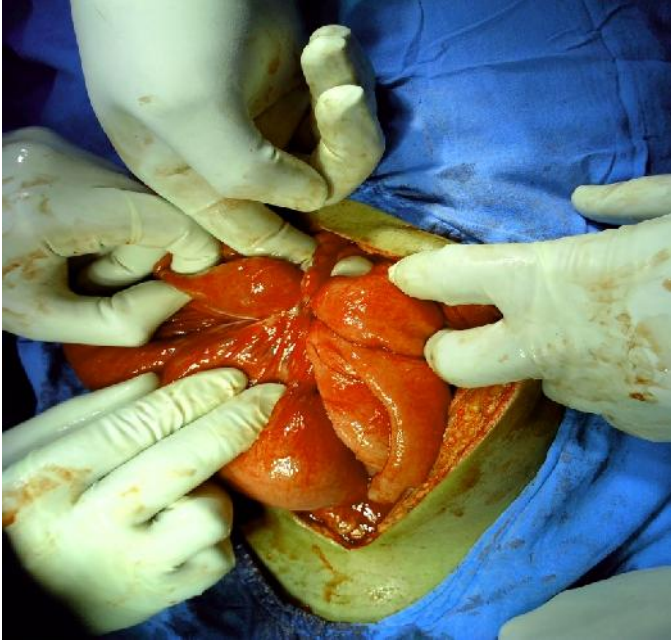

FIG 5: ADHESIONS BETWEEN SMALL BOWEL AND PERITONEUM.

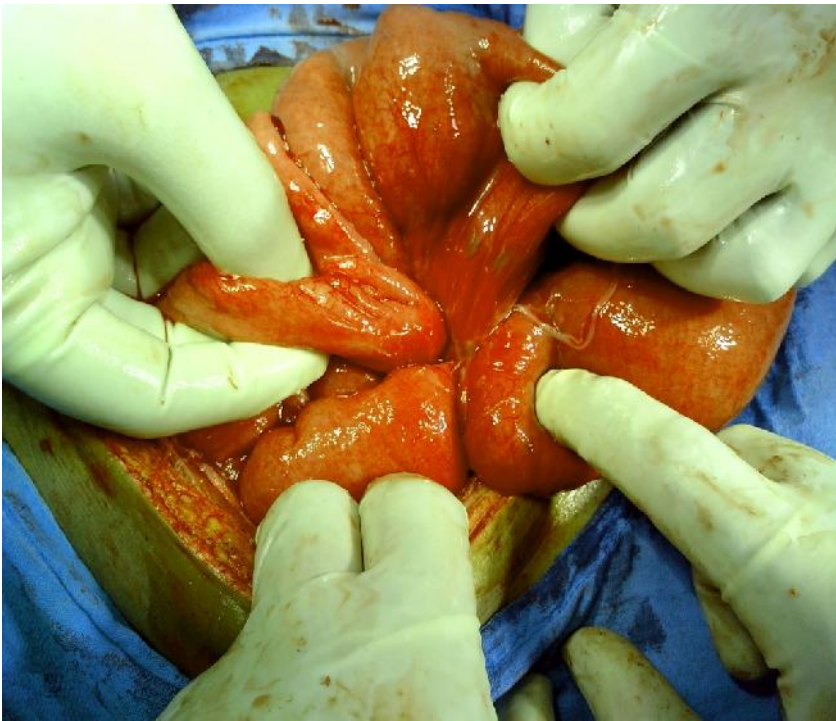

FIG 6: INTER LOOP ADHESIONS.

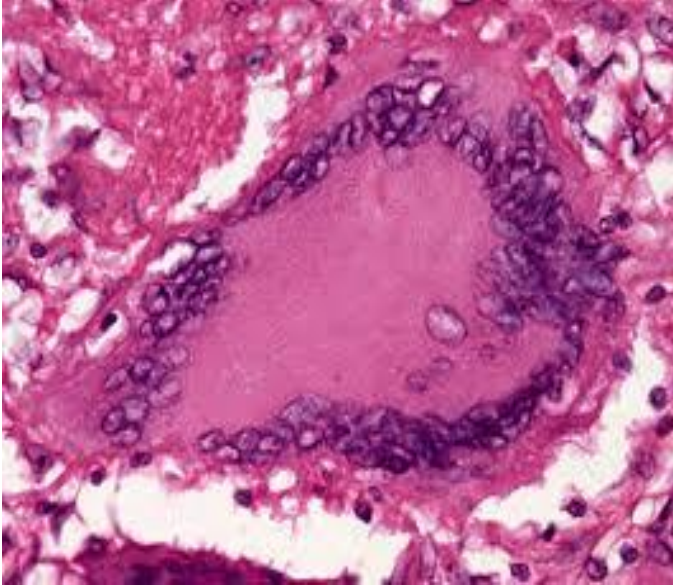


FIG 7: HISTOLOGY SHOWING CASEATION WITH EPITHELOID CELLS, LANGHANS CELLS.

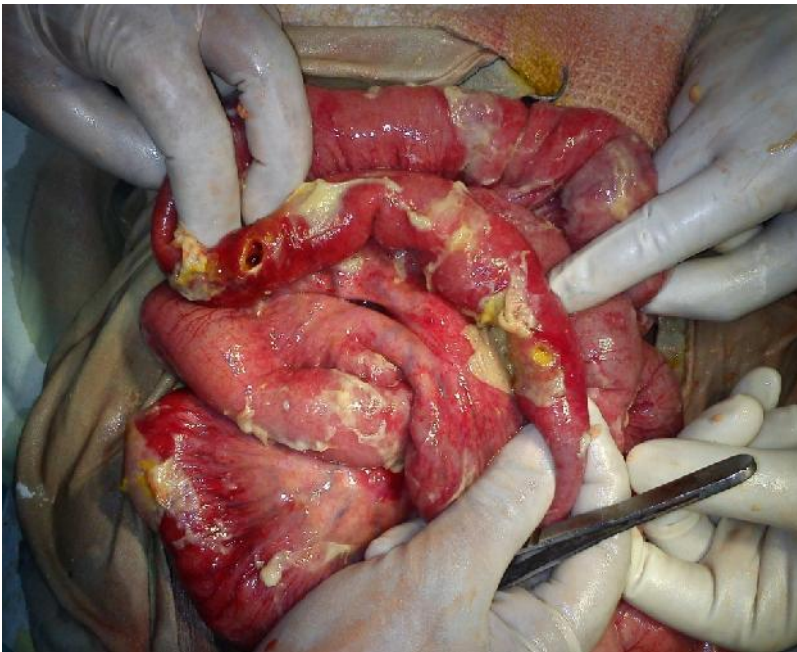


FIG 8: MULTIPLE TUBERCULOUS PERFORATION

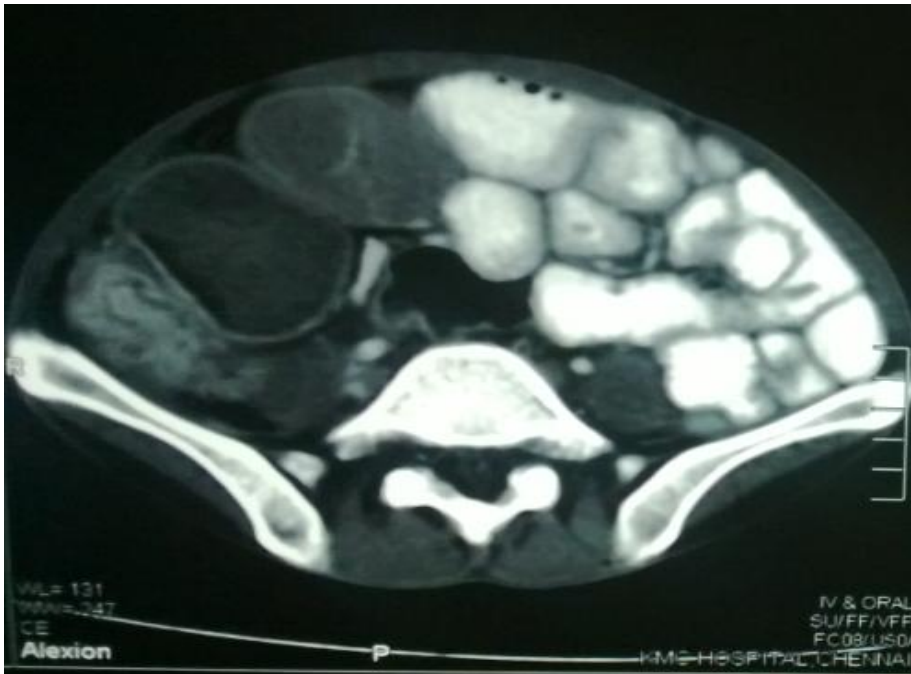

FIG 9: CECT ABDOMEN SHOWING ILEOCAECAL MASS

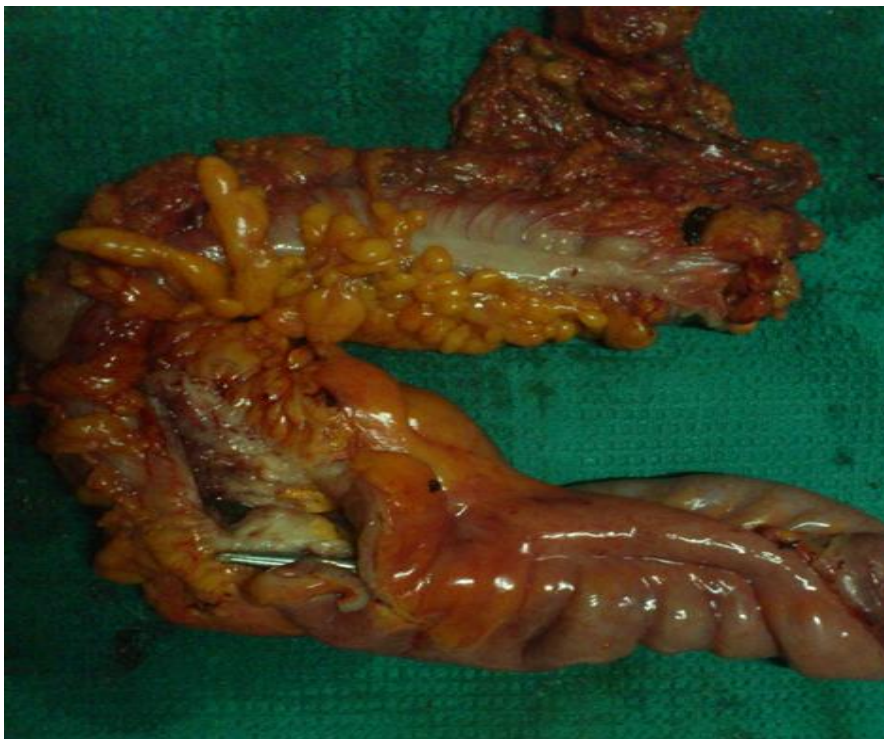

FIG 10: RIGHT HEMICOLECTOMY SPECIMEN



# ***BIBLIOGRAPHY***

## REFERENCES

1. Peda veerraju E. Abdominal tuberculosis. In : Textbook of pulmonary and extrapulmonary tuberculosis. 3<sup>rd</sup> edition. New Delhi: interprint 1998 p.250-2.
2. Addison N.V. & J.M. Findlay. Abdominal Tuberculosis. Current Surgical practice vol. 3 page, 48-61(1982).
3. Goldman KP. AIDS and tuberculosis. *Tubercle* 1988; 69: 71-2.
4. Tan K-K, Chen K, Sim R: The spectrum of abdominal tuberculosis in a developed country: a single institution's experience over 7 years. *J Gastrointest Surg* 2009, 13:142–147.
5. Rathi PM, Amarapurakar DN, Parikh SS, Joshi J, Koppikar GV, Amarapurkar AD, *et al.* *Impact of human immunodeficiency virus infection on abdominal tuberculosis in western India. J Clin Gastroenterol* 1997;24 : 43-8.
6. Sharma MP, Bhatia V: Abdominal tuberculosis. *Indian J Med Res* 2004,120:305–315.
7. Tandon HD, Prakash A. Pathology of intestinal tuberculosis and its distinction from Crohn's disease. *Gut* 1972; 13 :260-9.

8. Kapoor VK. Abdominal tuberculosis. *Postgrad Med J* 1998;74 : 459-6.
9. Sheen-chen SM, Chou FF, Wan YL, Eng HL. Tuberculosis presenting as Solitary splenic tumour. *Tuber Lung Dis* 1995; 76: 30-3.
10. Brusko G, Melvin VS, Fromekes JJ, Ellison EC, pancreatic TB *Ann surg* 1995; 61:513-15.
11. Levine R, Tenner S, Steinberg W, Ginsberg A, Bomm M, Huntingroti D. Tuberculous abscess of pancreas. Case report and review of the Literature. *Dig Dis Sci* 1992;37: 1141-4
12. Varsheney S, Johnson CD. Tuberculosis of the pancreas. *Postgrad Med J*. 1995; 71:564-6
13. Paustian FF. Tuberculosis of the intestine. In: Bockus HL, editor. *Gastroenterology, vol.11, 2nd ed. Philadelphia :W.B. Saunders Co.;* 1964 p.311.
14. Tassios P, Ladas S, Giannopoulos G, Larion K, Katsogridakis J, Chalarelakis G, *et al.* Tuberculous esophagitis. Report of a case and review of modern approaches to diagnosis and treatment. *Hepatogastroenterology* 1995; 42 : 185-8.
15. Ali W, Sikora SS, Banerjee D, Kapoor VK, Saraswat VA, Saxena R, *et al.* Gastroduodenal tuberculosis. *Aust NZ J Surg* 1993; 63 : 466-7.
16. Gupta SK, Jain AK, Gupta JP, Agrawal AK, Berry K. Duodenal tuberculosis. *Clin Radiol* 1988; 39 : 159-61.
17. Berney T, Badaoui E, Totsch M, Mentha G, Morel P. Duodenal tuberculosis presenting as acute ulcer perforation. *Am J Gastroenterol* 1998; 93 : 1989
18. Vij JC, Ramesh GN, Choudhary V, Malhotra V. Endoscopic balloon dilation of tuberculous duodenal strictures. *Gastrointest Endosc* 1992; 38 : 510-1.

19. Chawla S, Mukerjee P, Bery K. Segmental tuberculosis of the colon: a report of ten cases. *Clin Radiol* 1971; 22 :104-9.
20. Arya TVS, Jain AK, Kumar M, Agarwal AK, Gupta JP. Colonic tuberculosis : a clinical and colonoscopic profile. *Indian J Gastroenterol* 1994; 13 (Suppl) A
21. Singh V, Kumar P, Kamal J, Prakash V, Vaiphei K, Singh K. Clinicocolonoscopy profile of colonic tuberculosis. *Am J Gastroenterol* 1996; 91 : 565-8.
22. Shaikh MS, Dholia KR, Jalbani MA: Prevalence of intestinal tuberculosis in cases of acute abdomen. *Pakistan J Surg* 2007, 23:52–56.
23. Chowdhary GN, Dawar R, Misra MC. Coexisting carcinoma and tuberculosis of stomach. *Indian J Gastroenterol* 1999; 18 : 179-80
24. Kapoor VK. Abdominal tuberculosis : the Indian contribution. *Indian J Gastroenterol* 1998; 17 : 141-7.
25. Bhansali SK, Sethna JR. Intestinal obstruction : a clinical analysis of 348 cases. *Indian J Surg* 1970; 32 : 57-70.
26. Dorairajan LN, Gupta S, Deo SV, Chumber S, Sharma L. Peritonitis in India – a decade’s experience. *Trop Gastroenterol* 1995; 16 : 33-8.
27. Ranjan P, Ghoshal UC, Aggarwal R, Pandey R, Misra A, Naik S, et al. Etiological spectrum sporadic malabsorption syndrome in Northern Indian adults at a tertiary hospital. *Indian J Gastroenterol* 2004; 23 : 94-8.

- 28.Puri AS, Vij JC, Chaudhary A, Kumar N, Sachdev A, Malhotra V, *et al.* *Diagnosis and outcome of isolated rectal tuberculosis. Dis Colon Rectum* 1996; 39 : 1126-9.
- 29.Dandapat MC, Mukherjee LM, Behra AN. *Fistula in ano. Indian J Surg* 1990; 52 : 265-8.
- 30.Shukla HS, Gupta SC, Singh C, Singh PA. *Tubercular fistula in ano. Br J Surg* 1988; 75 : 38-9.
- 31.Kapoor VK, Chattopadhyay TK, Sharma LK. *Radiology of abdominal tuberculosis. Australas Radiol* 1988; 32 : 365-7.
- 32.Tandon RK, Sarin SK, Bose SL, Berry M, Tandon BN. *A clinico-radiological reappraisal of intestinal tuberculosis– changing profile? Gastroenterol Jpn* 1986; 21 : 17-22.
- 33.Sharp JF, Goldman M. *Abdominal tuberculosis in East Birmingham: A 16 year study. Postgrad Med J* 1987; 63:539-42.
- 34.HK Ha, Ji Jung, MS Lee, Choi BG, Lee MG, Kim YH. *CT differentiation of tuberculosis peritonitis and peritoneal carcinomatosis. Am J Roentgenol* 1996; 167: 743-8.
- 35.Bhargava DK, Kushwaha AKS, Dasarathy S, Shriniwas, Chopra P. *Endoscopic diagnosis of segmental colonic tuberculosis. Gastrointest Endosc* 1992; 38 : 571-4.
- 36.Chawla TC, Sharma A, Kiran U, Bhargava DK, Tandon BN. *Serodiagnosis of intestinal tuberculosis by enzyme immunoassay and soluble antigen fluorescent antibody tests using a saline extracted antigen. Tubercle* 1986; 67 :55-60.
- 37.Sathar MA, Simjer AE, Coovadia YM, Soni PN, Moola SA, Insam B, *et al.* *Ascitic fluid gamma interferon concentrations and adenosine deaminase activity in tuberculous peritonitis. Gut* 1995; 36 : 419-21.

38. Dwivedi M, Misra SP, Misra V, Kumar R. Value of adenosine deaminase estimation in the diagnosis of tuberculous ascites. *Am J Gastroenterol* 1990; 85 : 1123-5.
39. Balasubramanian R, Ramachandran R, Joseph PE, Nagarajan M, Thiruvengadam KV, Tripathy SP, *et al.* Interim results of a clinical study of abdominal tuberculosis. *Indian J Tuberc* 1989; 36 : 117-21.
40. Arif AU, Shah LA, Ullah A, Sadiq MD: The frequency and management of intestinal tuberculosis; a hospital based study. *J Postgrad Med Instit* 2008, 22.
41. Balasubramanian R, Nagarajan M, Balambal R, Tripathy SP, Sundararaman R, Venkatesan P. Randomised controlled clinical trial of short course chemotherapy in abdominal tuberculosis: a five-year report. *Int J Tuberc Lung Dis* 1997; 1 : 44-51.
42. Pimparkar BD, Donde UM. Intestinal tuberculosis II. Gastrointestinal absorption studies. *J Assoc Physicians India* 1974; 22 : 219-28.
43. Gondal SH, Gulshan S, Naseeb U: Intestinal Tuberculosis as an abdominal emergency. *Pak Postgrad Med J* 2000, 11:103–105.
44. Baloch NA, Baloch MA, Baloch FA: A study of 86 cases of abdominal tuberculosis. *J Surg Pak* 2008, 13:30–32.
45. Chalya *et al.*: Clinicopathological profile and surgical treatment of abdominal tuberculosis: a single centre experience in northwestern Tanzania. *BMC Infectious Diseases* 2013 13:270.

46. Anand BS, Nanda R, Sachdev GK. Response of tuberculous stricture to antituberculous treatment. *Gut* 1988; 29 :62-9
47. Pujari BD. Modified surgical procedures in intestinal tuberculosis. *Br J Surg* 1979; 66 : 180-1.
48. Bhansali SK. Abdominal tuberculosis. Experiences with 300 cases. *Am J Gastroenterol* 1977; 67 : 324-37.

# **PROFORMA**



## PROFORMA

Name of the Patient:

Address:

Occupation:

Income:

Age:

IP. No:

Sex:

Date of admission:

Religion:

Date of operation:

Marital status:

Date of discharge:

Socio economic status:

Pain abdomen

Vomiting

Fever

Cough

Mass per abdomen

Constipation

Diarrhoea

Loss of appetite

Loss of weight

## **HISTORY OF PRESENT ILLNESS**

### **COMPLAINTS DURATION**

Pain abdomen:

Site:

Duration:

Nature: Aching / Burning / stabbing / Constricting/Throbbing/colicky

Mode of onset: Insidious/ Sudden

Intensity

Radiation

Shifting

Periodicity

Relieving factors

Aggravating factors

Progress: Steady / gradually worsening / gradual

Declining/Fluctuating / associated with appearance of swelling.

### **VOMITING**

**COLOUR:**

Contents: food particles / Digested food / clear acidic

Fluid/Bilious/coffee ground /Feculent

Frequency:

Induced / spontaneous:

Duration:

### **FEVER**

Duration:

Degree (grade): High / low / moderate

Type: Intermittent / Continuous

Evening rise:

Night sweats:

## COUGH

Productive / non-productive:

Blood stained:

Foul smelling:

## MASS ABDOMEN

Site:

Onset:

Duration:

Progress: Steady / rapid / reduction in size

Regression:

Single / Multiple:

History of alternate diarrhoea /Constipation: Associated

Symptoms:

Loss of appetite: Yes / No

Abdominal distension: onset, duration, progression, associated factors, pain,

Relieving factors.

Bowel disturbances: Frequency/Tenesmus/constipation /diarrhoea

Loss of weight: Yes/No.

## **HISTORY OF PAST ILLNESS:**

H/o pulmonary tuberculosis.

H/o Tuberculous Lymphadenitis.

H/o Diabetes

H/o Similar Illness

H/o any other Illness H/o any other surgery

**Drug History:** ATT, Steroids, Insulin

**HISTORY OF TREATMENT:** Regular / Irregular

**PERSONAL HISTORY**

Diet

Appetite

Bowel habits

Micturition

Sleep

Smoking

Alcoholism

Menstrual history

Any other Habits

**FAMILY HISTORY**

H/o Tuberculosis in family members

H/o similar illness in family members H/o DM / HTN

H/o Malignancies.

**GENERAL PHYSICL EXAMINATION:**

Built: Well / Moderate / Poor

Nourishment: Well / Moderate / Poor

Jaundice: Mild / Deep

Anemia: Mild / Moderate / Severe

Tongue:

Cyanosis: Yes / No

Clubbing of fingers: Yes / No.

Pedal edema: Yes / No, Pitting / Non pitting

Signs of dehydration: Yes / No.

Lymphadenopathy: Yes / No

Group involved: Cervical /Axillary/Inguinal/Popliteal /Supratrochlear

Tender / Non tender

Consistency: Soft / firm / Rubbery / Hard/ Matted / discrete

Mobility: Yes/No

### **Vital signs**

Pulse:

Rate

Rhythm

BP:

Temp:

R.R:

Volume

### **SYSTEMIC EXAMINATION**

Abdomen Inspection

Shape: Flat / Scaphoid / Distended

Skin and subcutaneous tissue

Visible veins: Yes / No/ Type of flow

Umbilicus: Shape / size / site

Movement with respiration

Visible pulsation: Yes / No

Visible Peristalsis: Yes / No/ Type

Hernial Sites

External genitalia

All quadrants of abdomen if moving equally with respiration: Yes / No

Scars: No/Site/Nature of Healing

Sinuses: No/ Site/ Surrounding skin/Nature of discharge

Fistulae: No / Site / Nature of Discharge

Flanks:

Mass

Site, Size, Shape, Number, Surface, Borders, Extent

Movements with respiration

Leg lifting test

Head raising test

**Palpation:**

Feel of abdomen - soft / doughy/ guarding / Rigidity-localized /generalized

Tenderness: present / absent / Site

Mass:

Local rise of temp:

Tenderness

Site

Size

Shape

Number

Extent: Vertical/ Horizontal

Surface: Smooth /Nodular / granular / Bosselated

Borders: Regular / Irregular / Diffuse

Movement with respiration

Independent mobility: Restricted /Free- Horizontal / Vertical

Pulsations: Transmitted / Expansile

Plane of the swelling:

Consistency: Soft / firm / Hard / Cystic / Varying

Leg lifting test / Head rising test

Knee — Elbow position

Bimanually palpable: Yes / No

Ballottability: Yes /No

Compressibility:

Involvement of abdominal wall

Any other mass

**Liver:** Tenderness /Extent /Surface /Borders /Consistency

**Spleen:** Tenderness /Extent/ Surface/Border/ Splenic notch /Consistency

**Examination of back & spine**

Renal angle: Fullness- Yes / No

Tenderness: Yes / No

Spine: Deformity - Yes / No

Tenderness: Yes/No

Para spinal Rigidity: Yes / No

**Percussion:**

Over the swelling

Liver dullness

Splenic dullness

Free fluid: Yes/No

Fluid thrill/ shifting dullness/Horse shoe dullness /puddle's sign

Bladder: Yes/No

Renal Angle: Resonant/ dull

Auscultation: Bowel sounds: Yes / No

Frequency/ character

Genital examination:

Supraclavicular Lymph nodes:

Per rectal/Vaginal examination:

Mass/Bulge

Tenderness

Wall/Lumen

Nature of finger stain

**R.S:** Foci of pulmonary TB

**CNS:**

**CVS:**

**Bones & Joints:**

**PROVISIONAL DIAGNOSIS:**

**INVESTIGATIONS:**

Blood:

HB%:

TC:

DC:

ESR:

**BLOOD SUGAR:**

**UREA:**

**CREATININE:**

**MANTOUX TEST:**

**ECG:**

Screening / X-Ray chest:

X-Ray abdomen Erect:

Barium Meal Examination:

Barium enema:

Ultrasonography:



Ascitic fluid analysis: Staining for AFB

Colonoscopy:

LAPAROSCOPY:

**TREATMENT**

Conservative

Surgery - Elective / Emergency

Operative finding;

Surgery done:

Histopathological Report:

Final Diagnosis:

FOLLOW UP:

SL NO	NAME	AGE	SEX	IP NO	SYMPTOMS											COLONOSC	LAPAROS	CT ABDOM	S.AFB+VE	MANAGEMENT
					ABD PAIN	VOMITING	ABD DISTEN	FEVER	DIARRHOE	CONSTIPAT	LOW	LOA	CXR	X RAY ABD	EREC					
1	GANESH	37	M	4810/11	YES	YES	YES	YES			YES	YES		NO	YES			YES	NO	SURGERY
2	ELUMALAI	24	M	1300284	YES					YES	YES	YES		NO		YES		YES	NO	CONSERVATIVE
3	MALLIGA	17	F	1031/12	YES		YES			YES				YES	YES	YES		NO	NO	SURGERY
4	THANGAM	26	F	4284/12	YES				YES		YES			NO				YES	NO	SURGERY
5	RAJA	34	M	5986/11	YES			YES			YES	YES		NO	YES			YES	NO	SURGERY
6	RAVI	42	M	4384/11	YES	YES	YES			YES			+	YES		YES		NO	YES	SURGERY
7	MANGALAI	16	F	1301845	YES			YES				YES		NO				NO	NO	CONSERVATIVE
8	THULASI	23	F	10519/12			YES				YES	YES		NO	YES			YES	NO	SURGERY
9	KARIKALAN	33	M	4470/11	YES					YES	YES	YES	+	NO	YES	YES		NO	YES	CONSERVATIVE
10	POOVARAS	19	M	6982/12	YES					YES				NO		YES	YES	NO	NO	CONSERVATIVE
11	VENKATES	27	M	1300973	YES		YES	YES		YES	YES	YES		YES	YES	YES		YES	NO	SURGERY
12	RAJAMMA	46	F	7583/11	YES								+	NO	YES			NO	NO	CONSERVATIVE
13	SATHISH	21	M	4870/12	YES	YES	YES		YES	YES				NO	YES			YES	NO	SURGERY
14	GEETHA	32	F	1300482			YES	YES		YES	YES	YES		YES		YES		YES	NO	SURGERY
15	PRAVEEN	28	M	5980/12	YES	YES		YES					+	NO				NO	YES	SURGERY
16	POONGAV	22	F	5012/11			YES			YES	YES	YES		NO	YES	YES		YES	NO	CONSERVATIVE
17	PADMINI	42	F	4720/12	YES	YES	YES	YES		YES				YES				NO	NO	SURGERY
18	RAJENDRA	27	M	1233/12						YES				NO	YES	YES		NO	NO	CONSERVATIVE
19	NITHYANAI	37	M	1847/11	YES	YES	YES			YES	YES	YES	+	NO	YES			YES	YES	CONSERVATIVE
20	ANBARASA	23	M	3240/11	YES			YES						NO		YES		NO	NO	CONSERVATIVE
21	RANIAMM	51	F	20978/12	YES									YES	YES			NO	NO	SURGERY
22	JAYANTHI	31	F	10142/11		YES					YES	YES		NO				NO	NO	CONSERVATIVE
23	UMADEVI	29	F	10048/12	YES			YES	YES		YES	YES	+	YES				YES	YES	SURGERY
24	ANUPRIYA	18	F	24634/12	YES	YES		YES						NO	YES			NO	NO	SURGERY
25	KARTHICK	28	M	21840/12	YES								+	NO	YES			NO	NO	CONSERVATIVE
26	RAMACHAI	60	M	13100269	YES	YES		YES						YES				NO	NO	SURGERY
27	AROKIAMA	27	F	25148/12	YES		YES			YES	YES	YES		NO	YES	YES		YES	NO	SURGERY
28	SAMPATH	41	M	24240/11										NO				NO	NO	SURGERY
29	SEBASTIN	39	M	25210/12	YES					YES			+	NO		YES		YES	YES	CONSERVATIVE
30	DAVID	28	M	12024/12	YES			YES			YES	YES		NO	YES			NO	NO	CONSERVATIVE
31	VIJAYALAK	27	F	13154/11	YES					YES				NO		YES		NO	NO	CONSERVATIVE
32	SRINIVASA	17	M	1301201	YES	YES	YES	YES		YES	YES	YES	+	YES	YES	YES		YES	YES	SURGERY

33 SUMATHI	31 F	11982/12	YES									NO			YES	NO	NO	SURGERY
34 SHAKILA	43 F	22058/11	YES	YES	YES	YES		YES	YES	YES		YES				YES	NO	SURGERY
35 CHANDRAI	29 M	24245/12	YES	YES			YES					NO			YES	YES	NO	CONSERVATIVE
36 VEDANAYA	54 M	24470/11	YES				YES		YES	YES		NO	YES			NO	NO	SURGERY
37 KALAIARAS	31 F	14563/11			YES							NO	YES			YES	NO	CONSERVATIVE
38 DILIPKUMAR	48 M	25092/11	YES		YES			YES	YES	+		YES				NO	YES	SURGERY
39 THAMARAI	25 F	14897/12	YES	YES			YES	YES	YES			NO	YES	YES	YES	YES	NO	SURGERY
40 GUNASEKA	17 M	14042/11	YES				YES					NO	YES			NO	NO	SURGERY
41 RAMALING	36 M	26005/12	YES	YES			YES	YES	YES			YES		YES		YES	NO	SURGERY
42 VALLIAMM	27 F	1300947	YES					YES	YES			NO	YES			NO	NO	SURGERY
43 SRIDHAR	43 M	15980/11	YES		YES	YES			YES			YES				NO	NO	SURGERY
44 DIVYA	28 F	1301024	YES	YES	YES		YES			+		YES	YES	YES		YES	YES	SURGERY
45 VEERAPPAN	32 M	1300984	YES				YES		YES	YES		YES	YES	YES		YES	NO	SURGERY
46 SELVI	44 F	25157/11	YES									NO				NO	NO	SURGERY
47 PORSELVI	19 F	1300482	YES	YES			YES	YES	YES	+		NO	YES	YES	YES	YES	YES	SURGERY
48 CHINNAYA	48 M	17020/12	YES				YES					NO	YES			YES	NO	SURGERY
49 MARIYAPPAN	36 M	25140/11	YES		YES		YES			+		YES		YES	YES	YES	YES	SURGERY
50 PACHAIYAN	62 M	16074/12	YES	YES	YES		YES	YES	YES			YES	YES			NO	NO	SURGERY

Originality

GradeMark

PeerMark

thesis

BY 22111103 . M.S. GENERAL SURGERY ASHOK KUMAR B . BASKAR

turnitin

13%  
SIMILAR--  
OUT OF 0

A Dissertation On

## CLINICAL STUDY ON ABDOMINAL TUBERCULOSIS AND ITS EMERGENCIES

10

Submitted to

The Tamil Nadu Dr.M.G.R. Medical University

In fulfillment of regulations for the award of degree of

M.S., DEGREE EXAMINATION

BRANCH -I M.S., (GENERAL SURGERY)



## Match Overview

1 match

1	www.scribd.com Internet source	4%
2	M SHARMA. "Abdomin... Publication	1%
3	www.tulipgroup.com Internet source	1%
4	global-help.org Internet source	1%
5	www.pneumonologia.gr Internet source	<1%
6	lrsitbrd.nic.in Internet source	<1%
7	www.annalsgastro.gr Internet source	<1%
8	www.biomedcentral.com Internet source	<1%



- Class Portfolio
- Peer Review
- My Grades
- Discussion
- Calendar

NOW VIEWING: HOME > THE TAMIL NADU DR. M.G.R. MEDICAL UNIVERSITY

**Welcome to your new class homepage!** From the class homepage you can see all your assignments for your class, view additional assignment information, submit your work, and access feedback for your papers.

Hover on any item in the class homepage for more information.

### Class Homepage

This is your class homepage. To submit to an assignment click on the "Submit" button to the right of the assignment name. If the Submit button is grayed out, no submissions can be made to the assignment. If resubmissions are allowed the submit button will read "Resubmit" after you make your first submission to the assignment. To view the paper you have submitted, click the "View" button. Once the assignment's post date has passed, you will also be able to view the feedback left on your paper by clicking the "View" button.

Assignment Inbox: The Tamil Nadu Dr. M.G.R. Medical University				
	Info	Dates	Similarity	
Medical		Start 13-Nov-2013 12:50PM Due 31-Dec-2013 11:59PM Post 13-Nov-2013 3:00PM	13%	<input type="button" value="Resubmit"/> <input type="button" value="View"/> <input type="button" value="Download"/>